

Necrolytic migratory erythema-like dermatitis with malabsorption¹

Richard E. Ranchoff, M.D.
Gary R. Kantor, M.D.
Peter H. Slugg, M.D.
Wilma F. Bergfeld, M.D.
Kenneth J. Tomecki, M.D.

The authors describe a case of malabsorption and annular, erosive, scaling dermatitis exhibiting the clinical features of necrolytic migratory erythema. The cutaneous manifestations of malabsorption are discussed.

Index terms: Case reports • Erythema • Malabsorption syndromes

Cleve Clin Q 52:81-85, Spring 1985

Malabsorption may present or be associated with cutaneous disease.¹⁻³ Dermatoses are non-specific and often represent nutritional or vitamin deficiencies.

Necrolytic migratory erythema (NME), one of the "figurate" erythemas described by Becker et al⁴ and named by Wilkinson,⁵ is characterized histopathologically by superficial epidermal necrolysis. NME frequently occurs with pancreatic glucagonoma. However, Goodenberger et al⁶ described 2 patients with intestinal malabsorption and the clinical and histopathologic findings of NME. Elevated serum glucagon levels and glucagonoma were not present in their patients.

¹ Departments of Dermatology (R.E.R., G.R.K., W.F.B., K.J.T.) and Internal Medicine (P.H.S.), The Cleveland Clinic Foundation. Submitted for publication May 1984; revision accepted Nov 1984.

0009-8787/85/01/0081/05/\$2.25/0

Copyright © 1985, The Cleveland Clinic Foundation

We describe a patient with malabsorption and an annular, erosive, exfoliative dermatitis clinically compatible with NME. Histopathologic findings were nonspecific, and pancreatic glucagonoma was not present.

Case report

A 51-year-old white man presented to the Department of Dermatology of The Cleveland Clinic Foundation in June 1983 with a six-month history of red-to-purple annular patches on the arms, which rapidly progressed to a generalized dermatitis. The patient had a 13.6-kg (30-pound) weight loss, anorexia, fatigue, and occasional fever and chills. There was no personal or familial history of allergy, atopy, eczema, psoriasis, or other skin disease. Past surgical procedures included a Billroth I gastroduodenostomy in 1978 for peptic ulcer disease and repair of a hiatal hernia and a cerebral aneurysm in 1980. Medical history included a history of ethanol abuse and viral hepatitis in 1978 and symptoms of the dumping syndrome after the Billroth I procedure. On admission, he was taking hydroxyzine pamoate (25 mg, three times a day), Pragmatar ointment (twice a day), and oilated Aveeno baths (each day). He drank a six pack of beer each day since he was 19 years old and smoked one and a half packs of cigarettes a day for 40 years.

The physical examination revealed a cachectic, pale, slightly lethargic man who appeared older than his stated age. The skin examination revealed several discrete and confluent erythematous annular scaling plaques, many of which were serpiginous, on the buttocks, perineum, groin, thighs, and distal extremities (*Fig. 1*). There were large erosions on the trunk with secondary hyperpigmentation. There was no glossitis or cheilitis. The remainder of the physical examination was normal.

Laboratory studies disclosed the following values: white blood cell count, $12,000 \times 10^6/L$; hemoglobin, 11.7 g/dL;

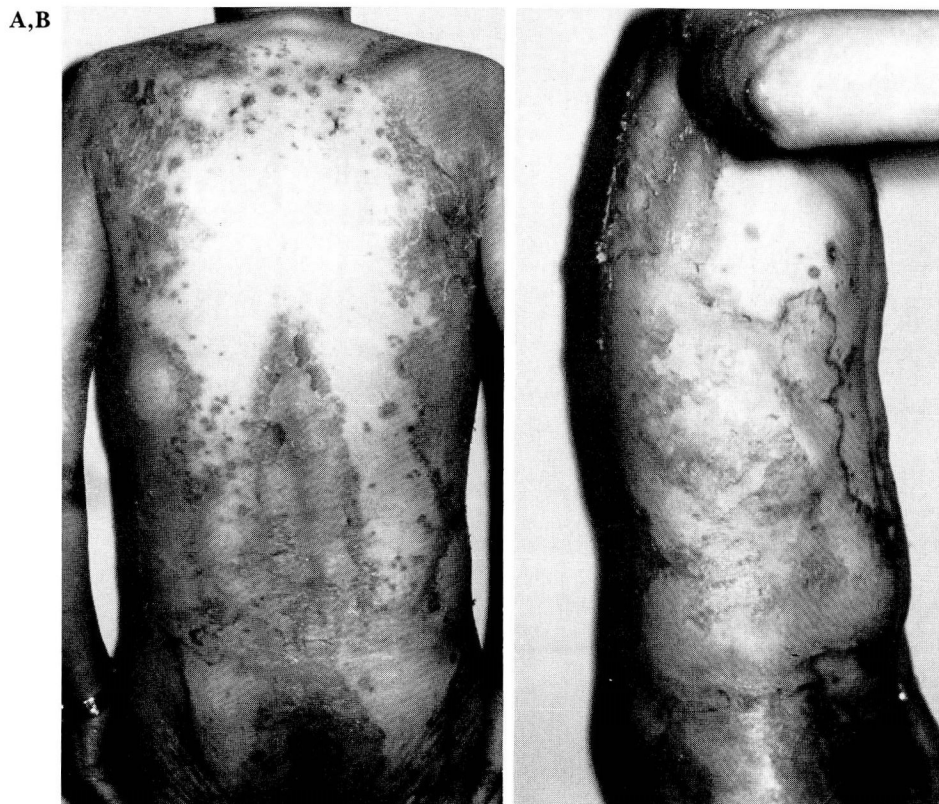

Fig. 1. A and B. Discrete and confluent erythematous annular erosive scaling plaques, many of which are serpiginous, on the trunk, buttocks, and extremities.

hematocrit, 34.5%; and mean corpuscular volume, 112.6. The automated chemistry profile was grossly abnormal with total protein, 4.7 g/dL (normal, 6–8 g/dL); albumin, 2.0 g/dL (normal, 3.5–5.0 g/dL); calcium, 7.1 mg/dL (normal, 9.0–10.5 mg/dL); cholesterol, 111 mg/dL (normal, 150–240 mg/dL); total bilirubin, 1.9 mg/dL (normal, 0.2–1.0 mg/dL); alkaline phosphatase, 615 U/L (normal, 20–110 U/L); lactic dehydrogenase, 312 U/L (normal, 100–225 U/L); serum glutamic oxaloacetic transaminase, 182 U/L (normal, 7–40 U/L); serum glutamic pyruvate transaminase, 44 IU (normal, 0–30 IU); and gamma glutamyl transpeptidase, 535 IU (normal, 0–50 IU). Other abnormal laboratory data included: positive antihepatitis B core antigen and positive antihepatitis B surface antigen (consistent with the recovery phase of hepatitis B viral infection), antinuclear antibody positive at a titer of 1:80; thyroxine (T₄), 4.4 µg/dL (normal, 5.2–11.3 mg/dL); triiodothyronine (T₃) uptake, 1.21 (normal, 0.9–1.18); and corrected T₄, 5.3 mg/dL (normal, 5.2–11.3 mg/dL). A serum protein electrophoresis showed hypoalbuminemia. The partial thromboplastin time was 27 seconds, and the prothrombin time was 14 seconds with a control of 12 seconds. Urinalysis showed pyuria and 10^5 *Staphylococcus aureus* grew in urine culture. Normal or negative laboratory findings included: Westergren sedimentation rate, serum protein electrophoresis, serum amylase and lipase, four-hour glucose tolerance test, serum magnesium, serum folic acid, serum ferritin, anti-DNA, pemphigus antibody, and the rapid plasma reagin test for syphilis. Serum

zinc and plasma citrulline and arginine levels were not obtained. A potassium hydroxide (KOH) preparation of scale from affected skin was negative for hyphae. Cultures of affected skin showed a mixture of gram-positive and gram-negative species, none of which was significant.

The chest radiograph showed early emphysematous lung changes. Flat plate and upright views of the abdomen were normal. Computed tomography (CT) of the abdomen suggested fatty infiltration of the liver and revealed a normal pancreas. Results of the barium enema examination and liver-spleen scan were normal.

Biopsies of affected skin showed platelike parakeratosis and mild spongiosis. There was mild edema with a scant monomorphic perivascular infiltrate within the papillary dermis (Fig. 2). Periodic acid Schiff (PAS) and digested PAS stains were negative. Direct immunofluorescent biopsy of affected skin was nonspecific and showed diffuse, amorphous deposits of IgG (2+), IgA (2+), IgM (2+), C3 (2+), and fibrinogen (2+) in the stratum corneum. Direct immunofluorescence of perilesional skin was negative.

The patient received crystalloid fluids administered intravenously, intensive topical skin care with oiled Aveeno whirlpool baths each day, Lubriderm lotion with 1% hydrocortisone and 0.5% menthol three times a day, and zinc oxide three times a day applied to the erosions, resulting in slow improvement. Hospitalization was complicated by hemorrhage from three ulcers in the duodenum. Biopsy of the duodenum showed no evidence of malignancy, and the

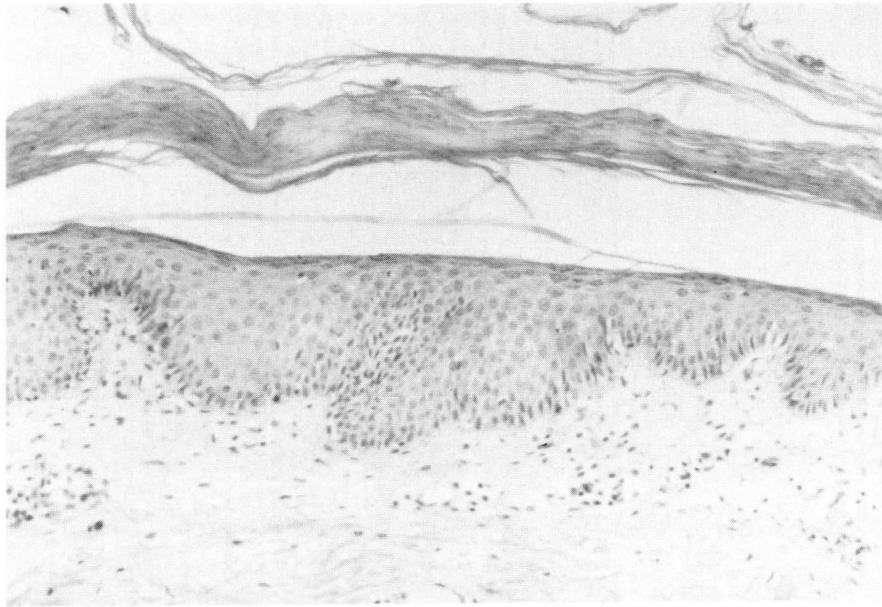


Fig. 2. Platelike parakeratosis and mild spongiosis of the epidermis with mild edema and a monomorphic perivascular infiltrate in the papillary dermis (hematoxylin-eosin stain, $\times 20$).

patient was given cimetidine (300 mg every six hours). Serum gastrin levels were not obtained.

Fasting glucagon levels on admission and two weeks later were 89 pcg/mL and 84 pcg/mL, respectively (normal, 50–200 pcg/mL). Beta subunit human chorionic gonadotropin was normal. Celiac angiography showed no hypervascular “blush” in the pancreas and no evidence of glucagonoma. Malabsorption testing included a 72-hour fecal fat analysis revealing total lipids of 92.1 g/72 hours; total dry weight, 220 g/72 hours; fecal weight, 922 g; and total lipids, 41.9% dry weight (normal, $\leq 25\%$). Serum carotene was 20 $\mu\text{g/dL}$ (normal, 50–250 $\mu\text{g/dL}$) and serum transferrin was 63 pcg/dL (normal, 170–700 pcg/dL). Tests for d-xylose absorption and serum vitamin A levels were normal. An upper gastrointestinal series was consistent with the patient’s previous surgeries and duodenal ulcer. A small bowel biopsy showed normal duodenal mucosa. Idiopathic steatorrhea (malabsorption) was diagnosed and was treated empirically with pancreatic enzyme supplementation. During this time, his skin improved, with only residual hyperpigmentation, a few persistent erosions, and a slight scale. The patient was discharged on his 22nd hospital day. Discharge medications were ferrous sulfate (325 mg three times a day) and pancrelipase (one capsule with meals). Six weeks after discharge, the patient reported minimally scaling plaques and secondary hyperpigmentation. His diarrhea lessened, and his appetite improved.

The patient failed to return for follow-up and died in November 1983 from unknown causes. An autopsy was not performed.

Discussion

Dermatologic disorders in patients with malabsorption can be classified into five categories:

a) changes of general malnutrition; *b)* vitamin deficiencies; *c)* changes related to hypocalcemia; *d)* miscellaneous and incidental; and *e)* eczema, exfoliative dermatitis, and psoriasis.

The skin changes of general malnutrition are nonspecific. These include pallor, loss of elasticity, thinness, follicular hyperkeratosis, hyperpigmentation, xerosis, fine scaling and fissuring, purpura, and ecchymosis. Hair changes include thinning, effluvium, alteration in hair color, and hypertrichosis. The nails become brittle and dystrophic.

Vitamin deficiencies (*Table*) may result from the loss of fat-soluble vitamins (A, D, E, K) in the stool. Vitamin A deficiency (phrynodema) is characterized by xerosis and follicular papules with keratotic plugs. Vitamin D deficiency may cause hypocalcemia, whereas vitamin E deficiency has no specific clinical signs. Vitamin K deficiency produces purpura and ecchymosis. Less common vitamin deficiencies are niacin deficiency (pellagra), characterized by stomatitis and a photosensitive dermatitis, which, when on the neck, is called Casal’s necklace; cyanocobalamin (vitamin B12) deficiency (pernicious anemia), characterized by redness, soreness, ulceration, and atrophy of the buccal and tongue mucosa, pigmentary changes, and poikiloderma; and folic acid deficiency, which shows pigmentary

Table. Cutaneous and mucocutaneous manifestations of vitamin deficiencies in idiopathic steatorrhea

Vitamin	Cutaneous and mucocutaneous manifestations
A	Xerosis, follicular papules with keratotic plugs
D	Xerosis, scaling, hyperpigmentation
E	No specific signs
K	Purpura, ecchymosis
Niacin	Stomatitis, photosensitive dermatitis
B12	Pigmentary changes, poikiloderma, redness, soreness, ulceration of the tongue and buccal mucosa
Folic acid	Pigmentary changes, scaling papules, sore tongue

changes similar to those seen with vitamin B12 deficiency, scaling papules, and a sore tongue. As many as 83% of patients with idiopathic steatorrhea have folic acid deficiency⁷; our patient's serum folic acid level was normal. Riboflavin, pyridoxine (vitamin B6), ascorbic acid (vitamin C), and biotin deficiency syndromes are not seen in idiopathic steatorrhea.¹

Hypocalcemia may cause xerosis, scaling, and hyperpigmentation of the skin. The nails become brittle with transverse ridges and are susceptible to yeast infections. Hair changes include sparsity, thinness, dryness, and effluvium. The relationship between vitamin D and calcium absorption in patients with steatorrhea is complex and not entirely clear.

Miscellaneous skin disorders include porphyria (induced by altered intestinal flora) and prurigo nodularis.¹

A high incidence of eczema is found in idiopathic steatorrhea and sprue, but not in other malabsorption syndromes. Exfoliative dermatitis and psoriasis have been described in patients with steatorrhea.¹

Our patient had malabsorption evidenced by steatorrhea, low serum carotene, and low transferrin levels, along with an annular, erosive, and exfoliative dermatitis with hyperpigmentation on the buttocks, perineum, groin, thighs, and distal extremities, which was compatible with the clinical diagnosis of NME. Other features of glucagonoma were weight loss, diarrhea, hypocholes-

terolemia, and anemia. However, an evaluation for glucagonoma, including duodenal biopsy and upper gastrointestinal roentgenography, a glucose tolerance test, serum glucagon levels, abdominal CT, and celiac angiography resulted in negative findings. This patient's NME-like dermatitis may represent an unusual variant of exfoliative dermatitis, previously associated with malabsorption.

The differential diagnosis of our patient's dermatitis includes pemphigus foliaceus, subcorneal pustular dermatosis, seborrheic dermatitis, chronic benign familial pemphigus (Hailey-Hailey disease), toxic epidermal necrolysis, chronic mucocutaneous candidiasis, pustular psoriasis, necrolytic migratory erythema, acrodermatitis enteropathica, kwashiorkor,⁸ citrullinemia (argininosuccinate synthetase deficiency)² and arginine deficiency.¹⁰ Biopsies of affected skin for histology and direct immunofluorescence biopsies, indirect immunofluorescence, and KOH preparation did not support any of these entities. Serum zinc and amino acid levels were not determined. Acquired zinc or amino acid deficiencies cannot be excluded in this patient.

Our patient's NME-like dermatitis improved markedly during hospitalization. The temporal relationship of pancreatic enzyme supplementation and clearing of the patient's dermatitis support the association of malabsorption and the cutaneous disease. Other possibilities include improved nutrition as a result of a balanced hospital diet, intensive topical skin care, and improved hydration.

Malabsorption has many cutaneous manifestations, including an NME-like dermatitis. The dermatitis lessens with correction of the malabsorption.

Kenneth J. Tomecki, M.D.
Department of Dermatology
The Cleveland Clinic Foundation
9500 Euclid Ave.
Cleveland OH 44106

References

1. Wells GC. Skin disorders in relation to malabsorption. *Br Med J* 1962; 2: 937-943.
2. Briggaman RA, Crounse RG. Skin application of nutrition to clinical specialties. [In] Schneider HA, Anderson CE, Cour-sin DB, eds. *Nutritional Support of Medical Practice*. New York, Harper & Row, 1977, pp 263-279.

3. Cooke WT, Peeney ALP, Hawkins CF. Symptoms, signs, and diagnostic features of idiopathic steatorrhea. *Q J Med* 1953; **22**: 59–77.
4. Becker SW, Kahn D, Rothman S. Cutaneous manifestations of internal malignant tumors. *Arch Dermatol Syphil* 1942; **45**: 1069–1080.
5. Wilkinson DS. Necrolytic migratory erythema with carcinoma of the pancreas. *Trans St. Johns Hosp Dermatol Soc* 1973; **59**: 244–250.
6. Goodenberger DM, Lawley TJ, Strober W, et al. Necrolytic migratory erythema without glucagonoma: report of two cases. *Arch Dermatol* 1979; **115**: 1429–1432.
7. Doig A, Girdwood RH. The absorption of folic acid and labelled cyanocobalamin in intestinal malabsorption, with observations on the faecal excretion of fat and nitrogen and the absorption of glucose and xylose. *Q J Med* 1960; **29**: 333–374.
8. Swenson KH, Amon RB, Hanifin JM. The glucagonoma syndrome: a distinctive cutaneous marker of systemic disease. *Arch Dermatol* 1978; **114**: 224–228.
9. Thoene J, Batshaw M, Spector E, et al. Neonatal citrullinemia: treatment with keto-analogues of essential amino acids. *J Pediatr* 1977; **90**: 218–224.
10. Kline JJ, Hug G, Schubert WK, Berry H. Arginine deficiency syndrome: its occurrence in carbamyl phosphate synthetase deficiency. *Am J Dis Child* 1981; **135**: 437–442.