

# Contrast two-dimensional echocardiography in the diagnosis of adult congenital heart disease<sup>1</sup>

Robert Detrano, M.D., Ph.D.  
Ernesto E. Salcedo, M.D.  
John Yiannikas, M.D.  
Douglas S. Moodie, M.D.

The use of contrast two-dimensional echocardiography in diagnosing adult congenital heart disease is assessed using illustrative examples. The technique of contrast injection and visualization is described. The clinical applications in evaluating septal abnormalities, corrected transposition of the great vessels, persistent left superior vena cava, and tricuspid valve abnormalities are discussed. Applications during catheterization of the left side of the heart are discussed. The routine use of this method in the diagnosis of adult congenital heart disease should be limited to a qualitative assessment of intracardiac structure and function.

**Index terms:** Heart defects, congenital, diagnosis • Heart, ultrasound studies

Cleve Clin Q 52:229-238, Summer 1985

The discovery that the injection of normal saline or indocyanine green in a peripheral vein produces strong intracardiac echocardiographic reflections<sup>1</sup> has led to the use of contrast two-dimensional echocardiography to obtain a minimally invasive angiogram.

Many reports have demonstrated the value of M-mode contrast echocardiography in the diagnosis of congenital heart disease and these have been reviewed by Seward et al<sup>2</sup> and Tajik and Seward.<sup>3</sup> We present our experience with two-dimensional contrast echocardiography in the diagnosis of adult congenital heart disease.

## Mechanism and technique

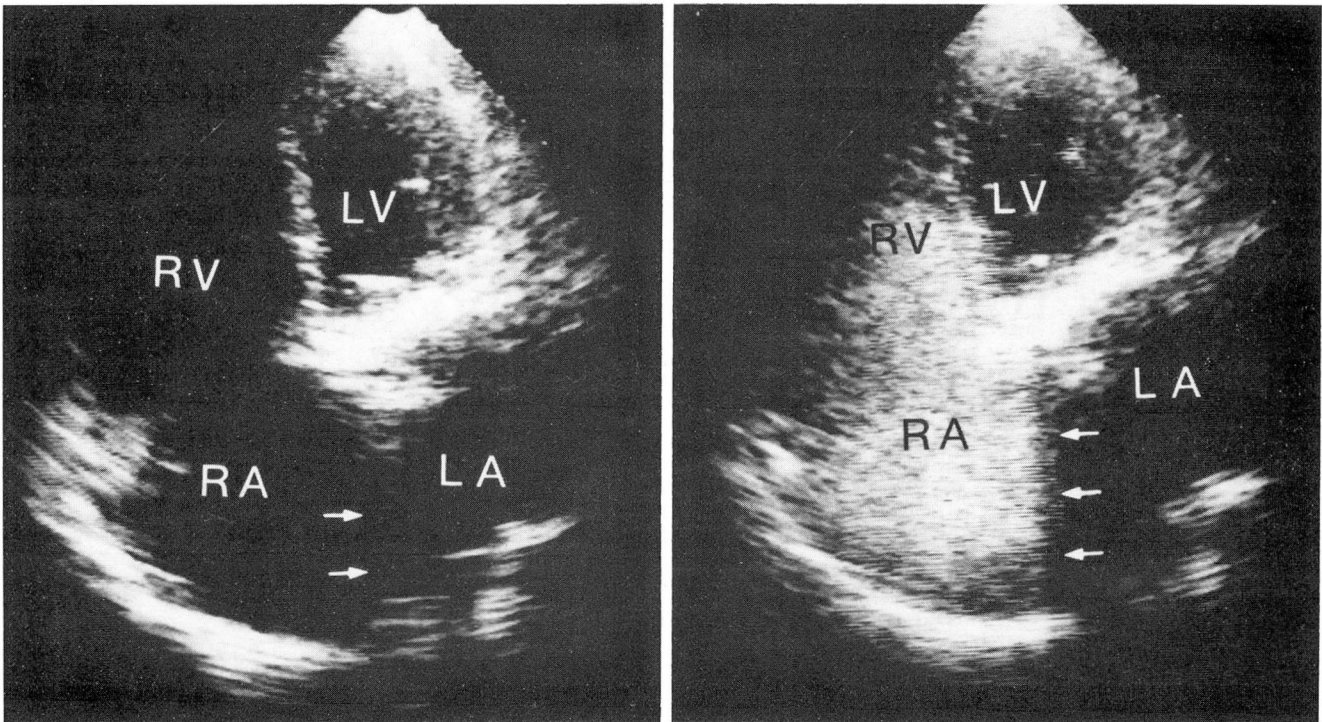
When a bolus of liquid, injected through a peripheral vein, arrives in the right cardiac chambers, it produces

<sup>1</sup> Department of Cardiology, The Cleveland Clinic Foundation. Submitted for publication Dec 1984; accepted Mar 1985. lp

0009-8787/85/02/0229/10/\$3.50/0

Copyright © 1985, The Cleveland Clinic Foundation

A, B



**Fig. 1.** A. Apical four-chamber view in a patient with an enlarged right atrium, demonstrating septal dropout (arrows).  
B. Same view after injection of contrast agent clearly demonstrates the presence of an intact atrial septum (arrows).  
LA = left atrium, LV = left ventricle, RA = right atrium, and RV = right ventricle.

highly echogenic interfaces that are readily detectable echocardiographically. These echoes result from microscopic bubbles of gas dissolved in the injected liquid.<sup>4,5</sup> The echocardiographic contrast can thus be seen and followed in a way similar to angiographic contrast agents.

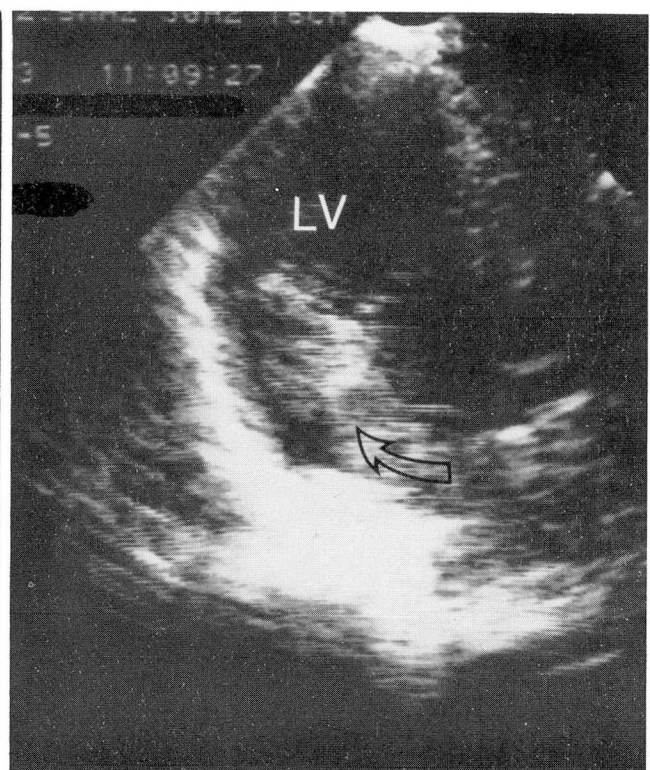
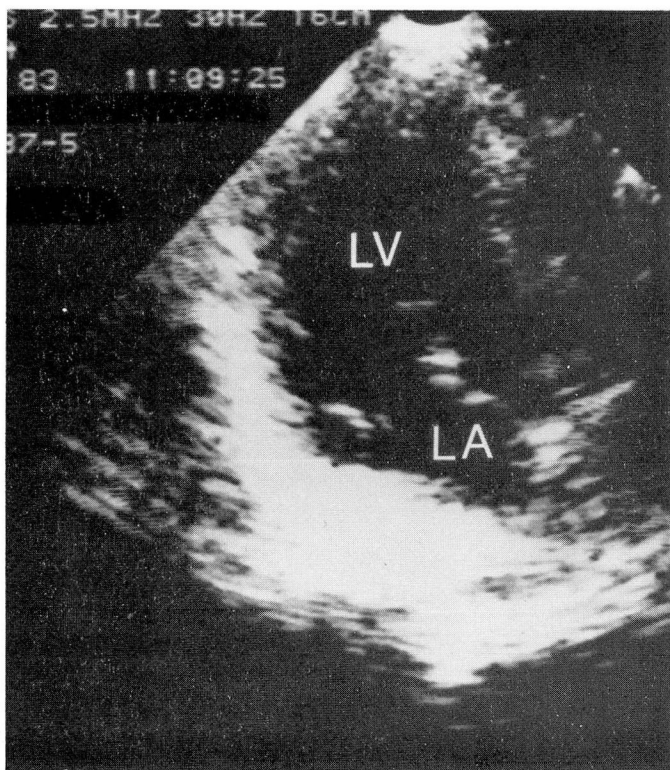
Any nontoxic solution can serve as a contrast agent. Dextrose in water and saline are com-

monly employed because they are inexpensive. Indocyanine green provides more microbubbles because of its surfactant properties.<sup>5</sup> Dissolved carbon dioxide produces an even better contrast effect.<sup>6-8</sup> This agent has been employed without complications to evaluate pericardial effusions,<sup>9</sup> and direct coronary injections have been safely performed.<sup>10</sup>

Contrast two-dimensional echocardiography is performed after completing the routine two-dimensional study when additional structural anatomic information is required or when there is a question of an intracardiac shunt. The following methodology is employed in our laboratory. A venipuncture is made with a #19- or #21-gauge short angiocatheter in an antecubital vein and the catheter is connected to a three-way stopcock. The sector scanner is initially placed in the apical region and an optimal apical four-chamber view is obtained. Appropriate gain settings are made. While recording on videotape, a rapid (1-2 second) hand injection of 10 mL of freshly diluted indocyanine green is made and is immediately followed by a flush with 10 mL of normal saline through the other port of the stopcock.

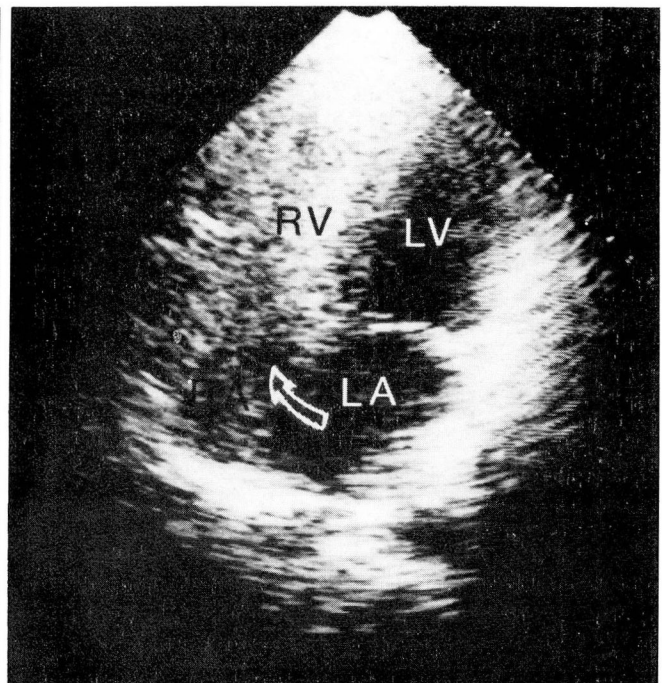
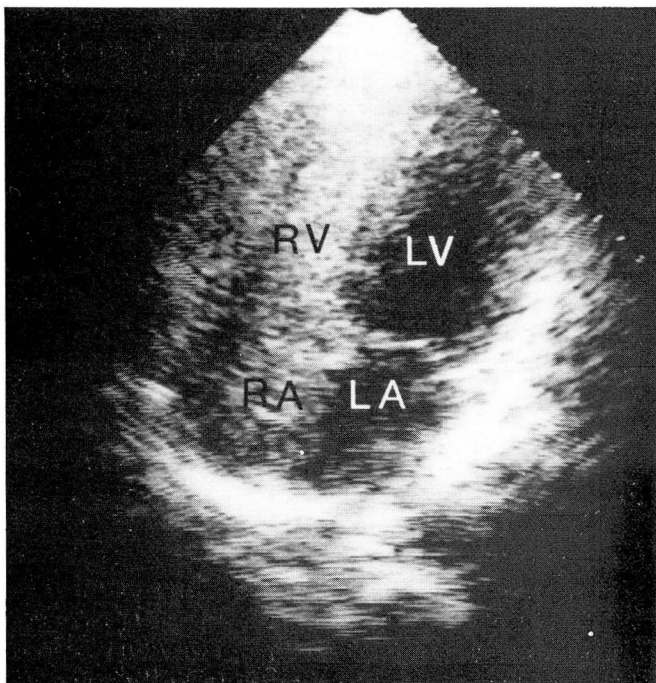
Table. Adult congenital heart diseases confirmed by contrast two-dimensional echocardiography
Septal abnormalities and shunts
Atrial septal defects
Right-to-left shunts
Left-to-right shunts
Patent foramen ovale
Atrial septal aneurysms
Ventricular septal defects with right-to-left shunt
Corrected transposition of the great vessels
Persistent left superior vena cava
Abnormalities of the tricuspid valve
Ebstein's anomaly
Tricuspid atresia





A, B

**Fig. 2. A.** Apical two-chamber view in a patient with an atrial septal defect before arrival of contrast agent.  
**B.** Same view after contrast agent has passed from the right to the left atrium.  
 LA = left atrium, and LV = left ventricle.

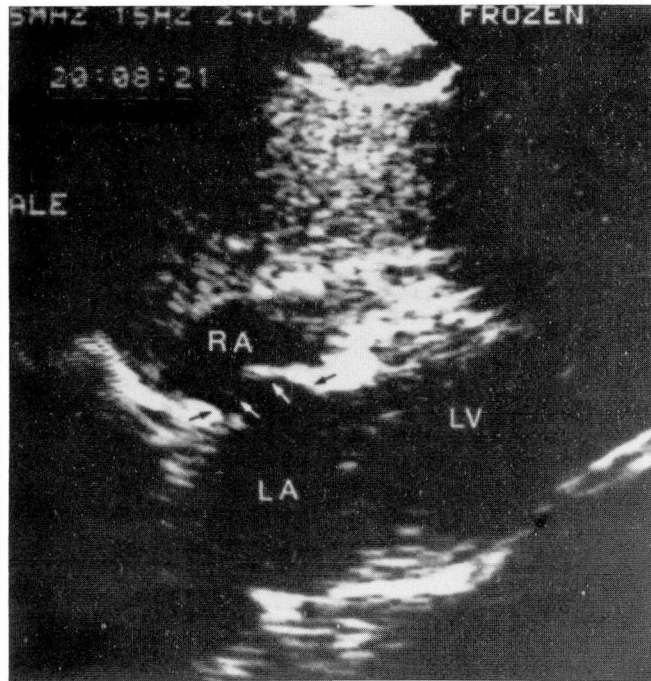
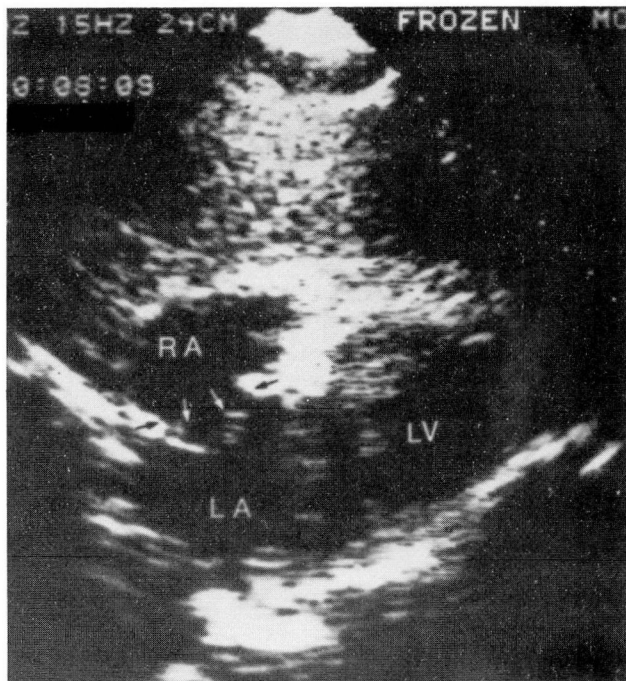


A, B

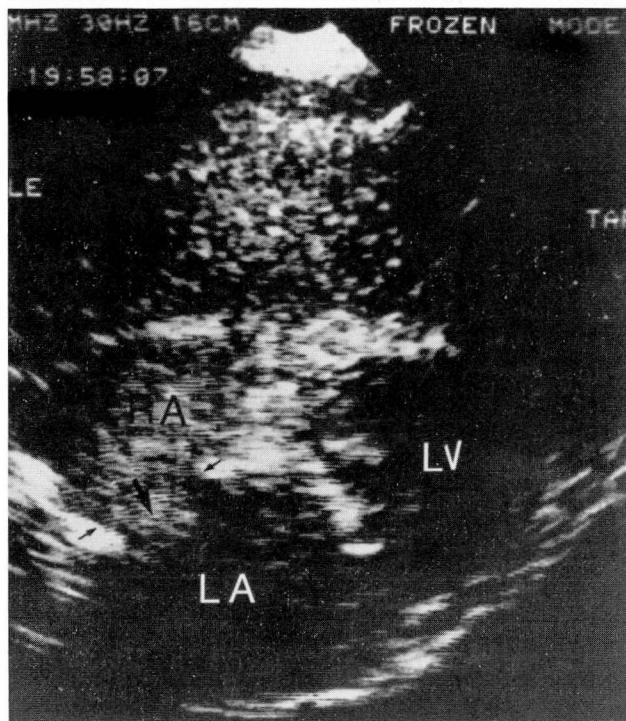
**Fig. 3. A.** Apical four-chamber view, showing right atrium and right ventricle filling with contrast agent.  
**B.** Same view shows unopacified blood passing through the septal defect (arrow) causing negative contrast effect.  
 LA = left atrium, LV = left ventricle, RA = right atrium, and RV = right ventricle.



A, B



C



**Fig. 4.** A and B. Subcostal four-chamber view, showing an atrial septal aneurysm as it undulates between right atrium and left atrium during the cardiac cycle.

C. Same view showing the aneurysm, well demarcated by contrast agent in the right atrium.

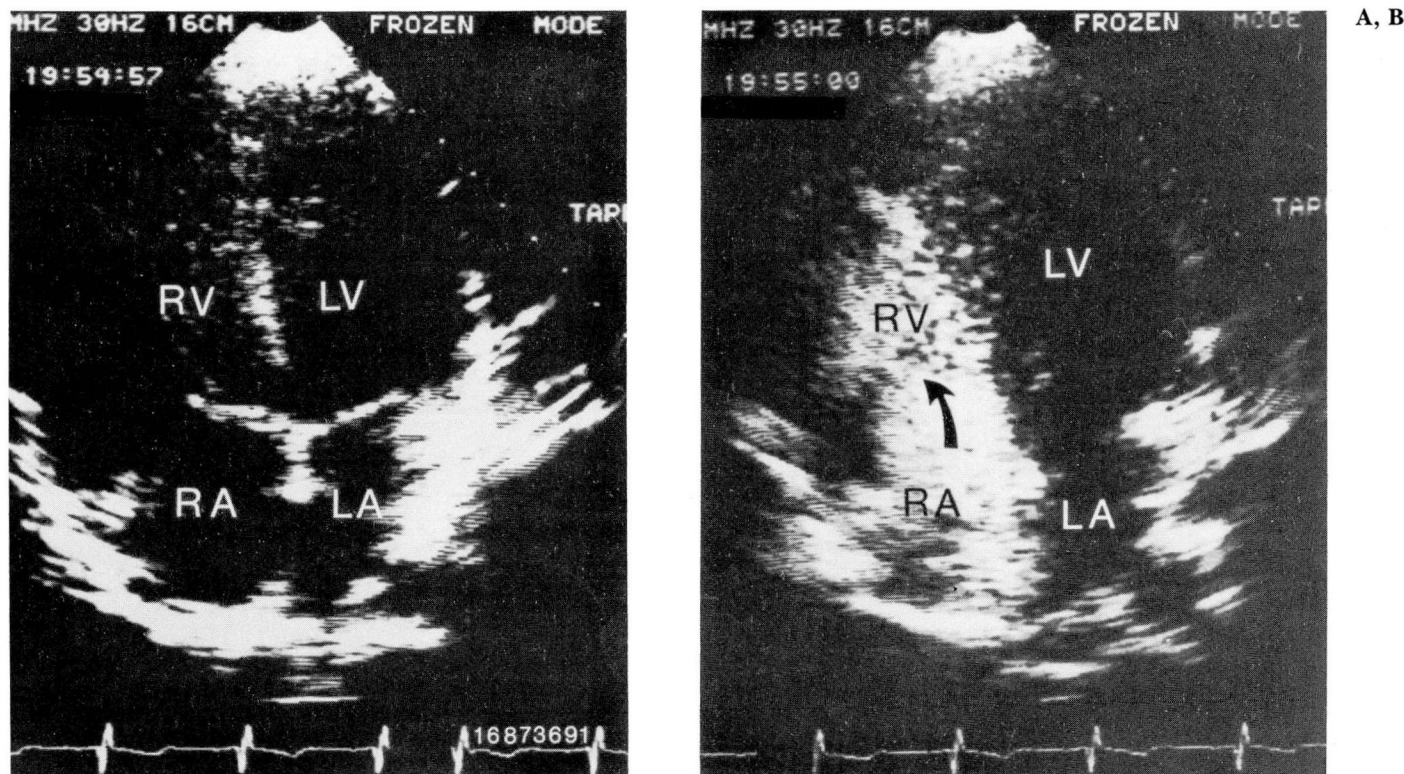
LA = left atrium, LV = left ventricle, and RA = right atrium.

A second injection is made in a similar way with the sector plane along the left parasternal long-axis view. A simultaneous M-mode recording at the level of the mitral valve may be obtained from this view to facilitate the timing of appearance of the echocardiographic contrast material.

### Clinical applications

The *Table* summarizes the adult congenital heart diseases whose diagnoses are most often made or confirmed with the use of contrast two-dimensional echocardiography. A brief discussion of each of these abnormalities follows.





**Fig. 5.** A. Apical four-chamber view in a patient who appeared to have a ventricular septal defect before arrival of contrast agent. B. As the contrast agent arrives in the right side of the heart (arrow), the ventricular septum is proved to be intact. LA = left atrium, LV = left ventricle, RA = right atrium, and RV = right ventricle.

### *Shunts and other septal abnormalities*

Two-dimensional contrast echocardiography is an excellent tool for the detection of right-to-left shunts. When no shunt exists, microbubbles injected in a systemic vein do not appear in the left atrium or ventricle since they are filtered in the pulmonary capillaries. Therefore, the appearance of echocontrast in the left side of the heart proves that a right-to-left shunt exists. This method can also distinguish between intrapulmonary and intracardiac right-to-left shunts because intrapulmonary shunts (pulmonary arteriovenous fistulas) result in a delay of six to eight cardiac cycles<sup>11</sup> before contrast appears in the left side of the heart, whereas intracardiac right-to-left shunts produce an almost immediate transfer of contrast to the chambers of the left side of the heart.

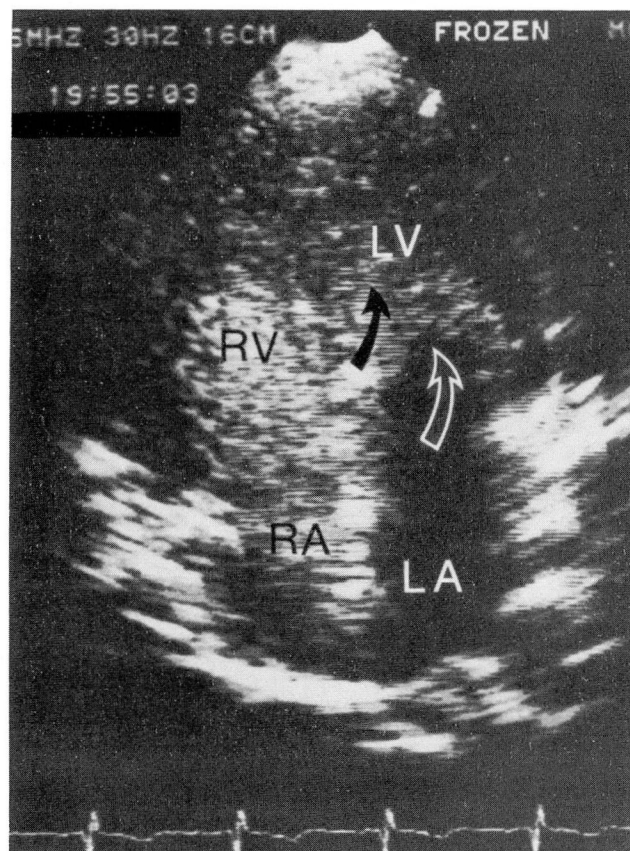
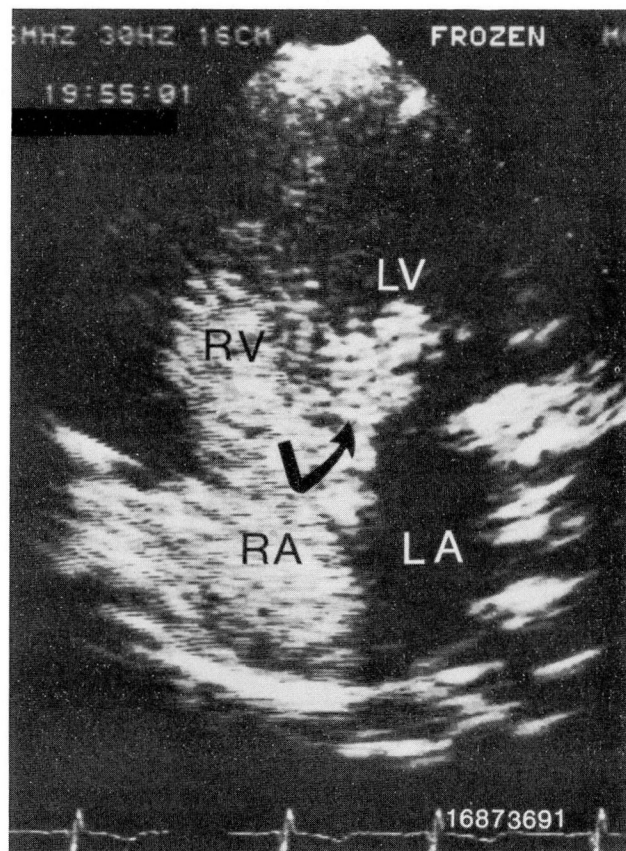
Not only the presence and location of right-to-left shunt lesions, but also their physiologic importance can be assessed with this method. Pironi et al<sup>12</sup> have shown that intravenously injected microbubbles are visualized in the aortas

of subjects with ventricular septal defects only when right ventricular pressures approach systemic levels. This allows patients with these lesions to be followed for signs of increasing pulmonary vascular resistance or the development of pulmonic stenosis without the necessity of cardiac catheterization.

Perhaps the most common application of contrast echocardiography to adult congenital heart disease is in distinguishing between atrial septal defect and artifactual atrial septal dropout in patients with suspected or known pulmonary hypertension. In fact, conventional two-dimensional echocardiography using the apical four-chamber view frequently fails to visualize the entire atrial septum because of septal dropout. The subcostal four-chamber view sometimes improves the visualization of this structure, but is not feasible in many patients. Contrast echocardiography clarifies the presence, integrity, and anatomical shape of the interatrial septum. A dense cloud of echoes fills the right atrium and delineates the surface of the septum if present (Fig. 1). Right-to-left shunts through a septal



A, B



**Fig. 6. A and B.** Apical four-chamber view shows contrast material from the right to the left ventricle through a ventricular septal defect (black arrows). The open arrow shows the mitral valve. LA = left atrium, LV = left ventricle, RA = right atrium, and RV = right ventricle.

defect are easily detected when contrast echoes enter the left from the right atrium (*Fig. 2*). Not only the presence, but the location of the interatrial shunt (ostium primum, secundum, sinus venosus) can be determined with this technique. The sensitivity and specificity of this method approach 100% in infants.<sup>13</sup> Excellent sensitivities and specificities have also been reported in adults.<sup>14-17</sup> Left-to-right shunting can be detected by a negative contrast or washout effect of contrast echoes in the right atrium caused by unopacified blood entering from the left atrium (*Fig. 3*). The combination of positive and negative contrast echocardiography has been found to be 96% sensitive for the detection of an atrial septal defect regardless of the direction of the shunt and 87% sensitive for the detection of an oximetrically demonstrable left-to-right shunt through such a defect by some investigators,<sup>18</sup> though others have been unable to confirm these results.

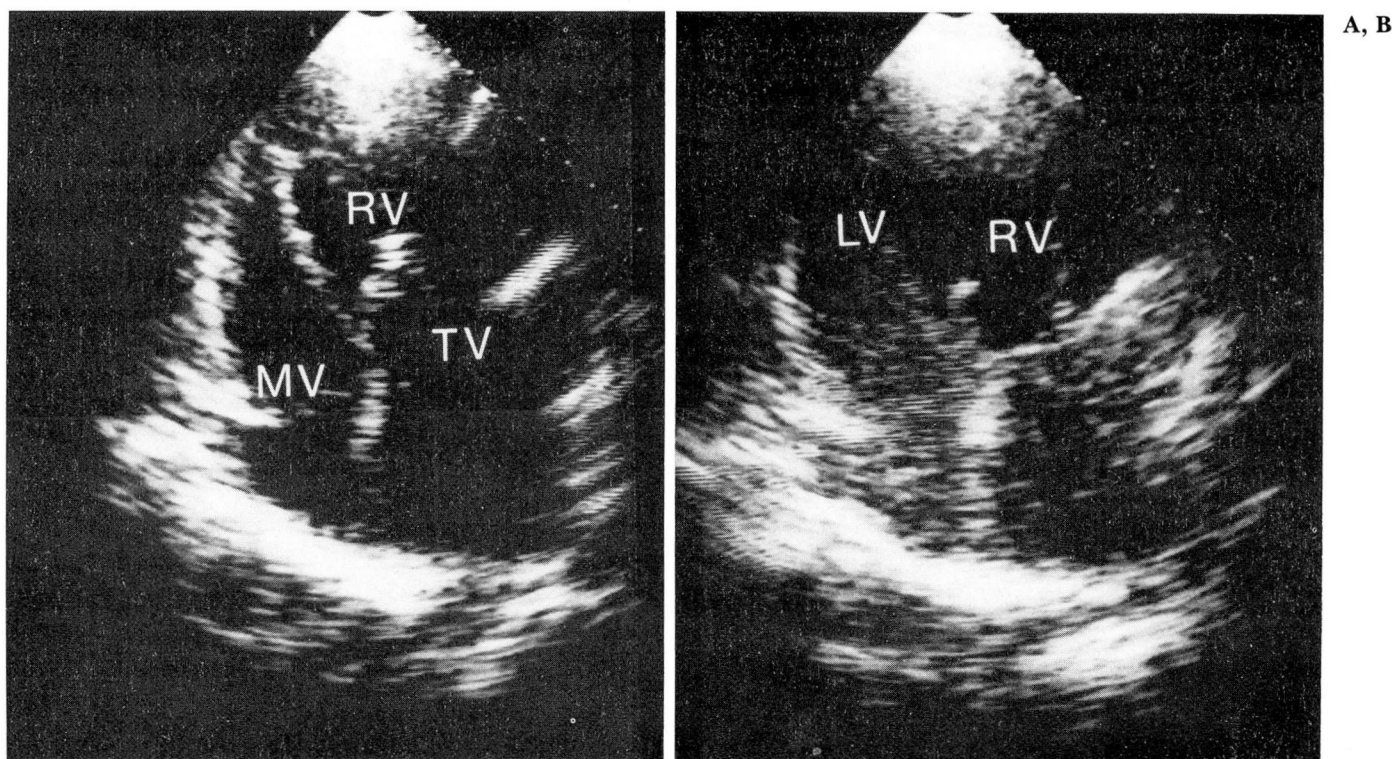
Some clinicians have indicted patent foramen

ovale as a possible cause of paradoxical embolus.<sup>19-21</sup> Contrast echocardiography during a Valsalva maneuver successfully establishes the diagnosis of patent foramen ovale<sup>22</sup> and this maneuver also enhances right-to-left shunting of echoes through small atrial septal defects.<sup>23</sup>

Aneurysms of the interatrial septum are rare, but their recognition is clinically important since they have been associated with thromboembolic complications.<sup>24</sup> With two-dimensional echocardiography, an aneurysm of the interatrial septum appears as a membrane undulating between the left and right atria. An injection of contrast agent facilitates its recognition, size, and the eventual presence of an associated atrial septal defect (*Fig. 4*).

Adults with undiagnosed congenital ventricular septal defect often have significant pulmonary hypertension at the time of presentation. Detection of a defect and determination of shunt direction is critical for the management of these





**Fig. 7. A.** Four-chamber apical view of a patient with corrected transposition of the great vessels, showing the tricuspid valve's position close to the apex.

**B.** Same view after arrival of contrast agent in the right atrium and morphological left ventricle.  
 LV = left ventricle, MV = mitral valve, RV = right ventricle, and TV = tricuspid valve.

patients. While the ventricular septum is usually readily recognized with conventional two-dimensional echocardiography, significant echo drop-out does occur at times in its membranous portion. Contrast echocardiography delineates the septal contours and spillage of contrast echoes from the right into the left ventricle, indicates a ventricular septal defect with a right-to-left shunt (Fig. 5 and 6). One group of investigators has reported successful detection of both right-to-left and left-to-right shunts through ventricular septal defects<sup>25</sup> using both positive and negative contrast effects.

Other intracardiac shunts reportedly diagnosed by two-dimensional contrast echocardiography include partial anomalous pulmonary venous return,<sup>26</sup> superior vena cava drainage into the left atrium,<sup>27</sup> and ruptured sinus of Valsalva.<sup>28</sup>

#### *Corrected transposition of the great vessels*

By carefully identifying each valve, great vessel, and muscular structure, conventional two-

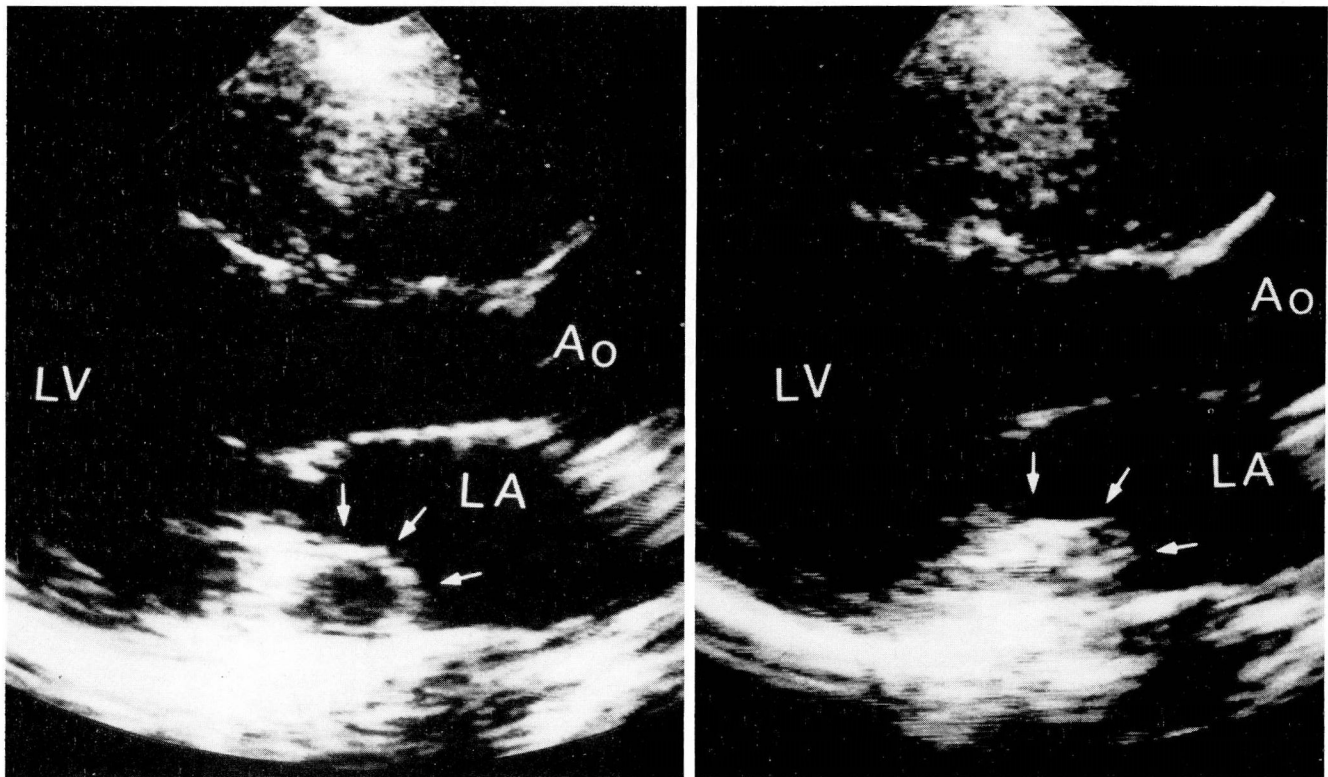
dimensional echocardiography usually permits the correct recognition, morphologically, of the left and right ventricles. The position of the tricuspid valve closer to the cardiac apex thereby permits the recognition, anatomically, of the right ventricle. However, this does not differentiate between the venous and the systemic ventricle. This differentiation is crucial in the diagnosis of corrected transposition of the great vessels. For this reason, standard two-dimensional echocardiography may not provide sufficient information to make this diagnosis. When contrast echoes from a peripheral injection arrive in the right atrium and then pass into the left ventricle, anatomically recognized by the attachment of the right atrioventricular valve, the diagnosis of corrected transposition is easily made (Fig. 7).

#### *Persistent left superior vena cava*

Two-dimensional contrast echocardiography has been most helpful in this diagnosis. The best views are parasternal long axis and apical four chamber. The dilated coronary sinus appears as



A, B



**Fig. 8. A.** Parasternal long axis view showing dilated coronary sinus (arrows) of a patient with a persistent left superior vena cava.

**B.** Same view as injection of contrast agent in the left arm enters the coronary sinus (arrow).

Ao = aorta, LA = left atrium, and LV = left ventricle.

an elliptical structure at the level of the atrioventricular groove near the posterior leaflet of the mitral valve. Echocardiographic contrast agent injected into a left arm vein fills this chamber with microbubbles (*Fig. 8*), but when injected into a right arm vein, microbubbles are seen only in the right atrium and ventricle. Two-dimensional contrast echocardiography has shown this anomaly to be common, especially among patients with other congenital heart lesions.<sup>29,30</sup>

#### *Abnormalities of the tricuspid valve*

Standard two-dimensional echocardiography using the apical four-chamber view readily documents the characteristic downward displacement of the tricuspid valve in Ebstein's anomaly. Two-dimensional contrast studies assist in the evaluation of the presence and degree of tricuspid insufficiency in patients with Ebstein's anomaly. The subcostal transducer position is ideal for the visualization of the regurgitation of contrast echoes from the right atrium into the inferior vena cava. Though a method of semiquantitative

assessment of the degree of tricuspid regurgitation has been devised by timing the delay of clearance of the contrast echoes from the inferior vena cava, this technique is poorly suited to the regurgitation seen in Ebstein's anomaly because of the large right atrium, which receives the regurgitant flow of blood.

Tricuspid atresia is another congenital defect for which two-dimensional contrast echocardiography can play a role.<sup>31</sup> The absence of a direct communication between the right atrium and ventricle is readily detected by following the course of the contrast echoes. The presence of a ventricular septal defect can also be ascertained.

#### *Left-sided injections*

The use of contrast echocardiography to study the left side of the heart is not new. In fact, the first application of this method was in the study of the aortic root.<sup>32</sup> Left-sided injections never gained popularity because they necessitate catheterization of the arterial circulation. However, when contraindications prohibit the use of radio-



opaque contrast agent or ionizing radiation, two-dimensional contrast echocardiography can be used for positioning catheters, ventriculography, and estimation of the degree of valvular incompetence.<sup>33,34</sup> Another obvious clinical application of contrast echocardiography during cardiac catheterization is in evaluating the existence and direction of intracardiac shunts. This technique enables the invasive cardiologist to limit the number of contrast injections and to complete a study with minimal risk from high dye loads. The method has been used successfully at our institution in the visualization of coronary artery fistulous connections to the right side of the heart.

### Conclusion

Contrast echocardiography has utility in the noninvasive diagnosis of various congenital heart defects in the adult. Its proved usefulness is presently limited to obtaining qualitative information concerning the presence, absence, location, and direction of intracardiac shunts and to the clarification of right-sided intracardiac anatomy and in some special circumstances to the morphology of the left side of the heart. It is especially and most frequently helpful in determining the existence and direction of intracardiac shunts in patients with suspected or known pulmonary hypertension. Newer applications, such as the measurement of intracardiac flow velocities,<sup>35</sup> are of unproved utility in patients with congenital heart disease.

### Acknowledgment

We thank Paula LaManna for her secretarial assistance in preparing this manuscript.

Ernesto E. Salcedo, M.D.  
Department of Cardiology  
The Cleveland Clinic Foundation  
9500 Euclid Ave.  
Cleveland OH 44106

### References

- Valdes-Cruz LM, Pieroni DR, Roland JMA, Varghese PJ. Echocardiographic detection of intracardiac right-to-left shunts following peripheral vein injections. *Circulation* 1976; **54**:558-562.
- Seward JB, Tajik AJ, Spangler JG, Ritter DG. Echocardiographic contrast studies: initial experience. *Mayo Clin Proc* 1975; **50**:163-192.
- Tajik AJ, Seward JB. Contrast echocardiography. *Cardiovasc Clin* 1978; **9**:317-341.
- Kremkau FW, Gramiak R, Carstensen EL, Shah PM, Kramer DH. Ultrasonic detection of cavitation at catheter tips. *AJR* 1970; **110**:177-183.
- Meltzer RS, Tickner EG, Sahines TP, Popp RL. The source of ultrasound contrast effect. *JCU* 1980; **8**:121-127.
- Meltzer RS, Serruys PW, Hugenoltz PG, Roelandt J. Intravenous carbon dioxide as an echocardiographic contrast agent. *JCU* 1981; **9**:127-131.
- Meltzer RS, Tickner EG, Popp RL. Why do the lungs clear ultrasonic contrast? *Ultrasound Med Biol* 1980; **6**:263-269.
- Gioffre PA, Pizzoto F, Romeo F, Martuscelli E, Scibilia G, Reale A. Ecoangiografia con anidride carbonica (abst). *Cong It Cardiol (Bari)* 1979; **6**:123.
- Oppenheimer MJ, Durant TM, Stauffer HM, Stewart GH III, Lynch PR, Barrera F. *In vivo* visualization of intracardiac structures with gaseous carbon dioxide: cardiovascular respiratory effects and associated changes in blood chemistry. *Am J Phys* 1956; **186**:325-334.
- Tambe A, McLaughlin WR, Zimmerman HA. Double contrast medium technic for coronary blood flow studies (abst). *Am J Cardiol* 1968; **21**:117.
- Shub C, Tajik AJ, Seward JB, Dines DE. Detecting intrapulmonary right-to-left shunt with contrast echocardiography: observations in a patient with diffuse pulmonary arteriovenous fistulas. *Mayo Clin Proc* 1976; **51**:81-84.
- Pieroni DR, Varghese PJ, Freedom RM, Rowe RD. The sensitivity of contrast echocardiography in detecting intracardiac shunts. *Cathet Cardiovasc Diagn* 1979; **5**:19-29.
- Serruys PW, Varn den Brand M, Hugenoltz PG, Roelandt J. Intracardiac right-to-left shunts demonstrated by two-dimensional echocardiography after peripheral vein injection. *Br Heart J* 1979; **42**:429-437.
- Kronik G, Hutterer B, Mösslacher H. Diagnose atrialer Links-rechts Shunts mit Hilfe der Zweidimensionalen Kontrastechokardiographie. *Z Kardiol* 1981; **70**:138-145.
- Fraker TD Jr, Harris PJ, Behar VS, Kisslo JA. Detection and exclusion of interatrial shunts by two-dimensional echocardiography and peripheral venous injection. *Circulation* 1979; **59**:379-384.
- Bourdillon PDV, Foale RA, Rickards AF. Identification of atrial septal defects by cross-sectional contrast echocardiography. *Br Heart J* 1980; **44**:401-409.
- Weyman AE, Wann LS, Caldwell RL, Hurwitz RA, Dillon JC, Feigenbaum H. Negative contrast echocardiography: a new method for detecting left-to-right shunts. *Circulation* 1979; **59**:498-505.
- Gullace G, Savoia MT, Ravizza P, Knippel M, Ranzi C. Detection of atrial septal defect with left-to-right shunt by inferior vena cava contrast echocardiography. *Br Heart J* 1982; **47**:445-453.
- Cheng TO. Paradoxical embolism: a diagnostic challenge and its detection during life. *Circulation* 1976; **53**:565-568.
- Laughlin RA, Mandel SR. Paradoxical embolization: case report and review of the literature. *Arch Surg* 1977; **112**:648-650.
- Kronik G, Mösslacher H. Positive contrast echocardiography in patients with patent foramen ovale and normal right heart hemodynamics. *Am J Cardiol* 1982; **49**:1806-1809.
- Tada T, Nakashima A, Sadak A, Shira M, Ohtas L, Kusukawa R. A simple method for enhancing interatrial right-to-left shunt in the diagnosis of small atrial septal defects using contrast echocardiography. *Japanese Journal of Cardiology* 1981; **11**:573-579.
- Nanda NC, Gramiak R. *Clinical Echocardiography*. St. Louis, CV Mosby, 1978, p 425.
- Yoshida H, Funahoshi T, Nakay S, Maeda T, Tariguchi



- N. Subxyphoid echocardiographic visualization of membranous septal defect with an aid of contrast technique. *Japanese Journal of Cardiology* 1981; **11**:563-571.
25. Danilowicz D, Kronzon I. Use of contrast echocardiography in the diagnosis of partial anomalous pulmonary venous connection. *Am J Cardiol* 1979; **43**:248-252.
26. Tomoe A, Yoshida Y, Ogata H, Chen HC, Fukuda M. Peripheral contrast echocardiographic findings of anomalous drainage of the right superior vena cava into the left atrium. *Tohoku Journal of Experimental Medicine* 1980; **130**:353-358.
27. Nakamura K, Suzuki S, Satomi G. Detection of ruptured aneurysm of sinus of Valsalva by contrast two-dimensional echocardiography. *Br Heart J* 1981; **45**:219-221.
28. Stewart JA, Fraker TD, Slosky DA, Wise NKW, Kisslo JA. Detection of persistent left superior vena cava by two dimensional contrast echocardiography. *JCU* 1979 **7**:357-360.
29. Snider AR, Ports TA, Silverman NH. Venous anomalies of the coronary sinus: detection by M-mode, two dimensional and contrast echocardiography. *Circulation* 1979; **60**:721-727.
31. Koiwaya Y, Watanabe K, Orita Y, Nakamura M, Hirata T. Contrast two-dimensional echocardiography in diagnosis of tricuspid atresia. *Am Heart J* 1981; **101**:507-510.
32. Gramiak R, Shah PM. Echocardiography of the aortic root. *Invest Radiol* 1968; **3**:356-366.
33. Elkayam U, Kawanishi D, Reid CL, Chandraratna PAN, Gleicher N, Rahimtoola SH. Contrast echocardiography to reduce ionizing radiation associated with cardiac catheterization during pregnancy. *Am J Cardiol* 1983; **52**:213-214.
34. Meltzer RS, Serruys PW, McGhie J, Hugenholtz PG, Roelandt J. Cardiac catheterization under echocardiographic control in a pregnant woman. *Am J Med* 1981; **71**:481-484.
35. Shiina A, Kondo K, Nakasone Y, Tsuchiya M, Yaginuma T, Hosoda S. Contrast echocardiographic evaluation of changes in flow velocity in the right side of the heart. *Circulation* 1981; **63**:1408-1416.