

Chronic active hepatitis induced by nitrofurantoin¹

Thomas L. Young, M.D.
Edgar Achkar, M.D., F.A.C.P.
Ralph Tuthill, M.D.
D. Roy Ferguson, M.D., F.A.C.P.

In 2 women who had received nitrofurantoin for two to five years, autoimmune chronic hepatitis developed, leading to severe hepatic necrosis and, in one case, cirrhosis. Treatment consisted of withdrawal and, in one case, institution of steroids and azathioprine. Both patients demonstrated symptomatic and biochemical improvement despite chronic histological changes. Nitrofurantoin is a cause of "lupoid" chronic active hepatitis which could lead to severe and irreversible histological changes.

Index terms: Hepatitis, chronic active, chemically induced • Nitrofurantoin, adverse effects

Cleve Clin Q 52:253-256, Summer 1985

Hepatic injury is rarely induced by nitrofurantoin; the most frequent pattern is cholestatic injury, which quickly remits after cessation of treatment.^{1,2} In 1980, Sharp et al³ described 5 patients with chronic active hepatitis, 2 of whom died as the result of nitrofurantoin therapy. We wish to report two cases which show the development of chronic active hepatitis and severe hepatic necrosis during nitrofurantoin therapy.

Case reports

Case 1. A 71-year-old black woman was admitted for evaluation of jaundice, epigastric pain, nausea, and malaise. Three months earlier, she had noticed scleral icterus, acholic stools, and darkening of her urine. She had no history of jaundice or hepatitis, denied ingestion of alcohol, and had not had a transfusion. However, she had been taking 100 mg of nitrofurantoin a day for two years for recurrent urinary tract infections. Previous liver function tests were normal, and 10 months prior to admission, her alkaline phosphatase and SGOT were within

¹ Departments of Gastroenterology and Pathology, The Cleveland Clinic Foundation. Submitted for publication Oct 1984; accepted Mar 1985. sjh

0009-8787/85/02/0253/04/\$2.00/0

Copyright © 1985, The Cleveland Clinic Foundation

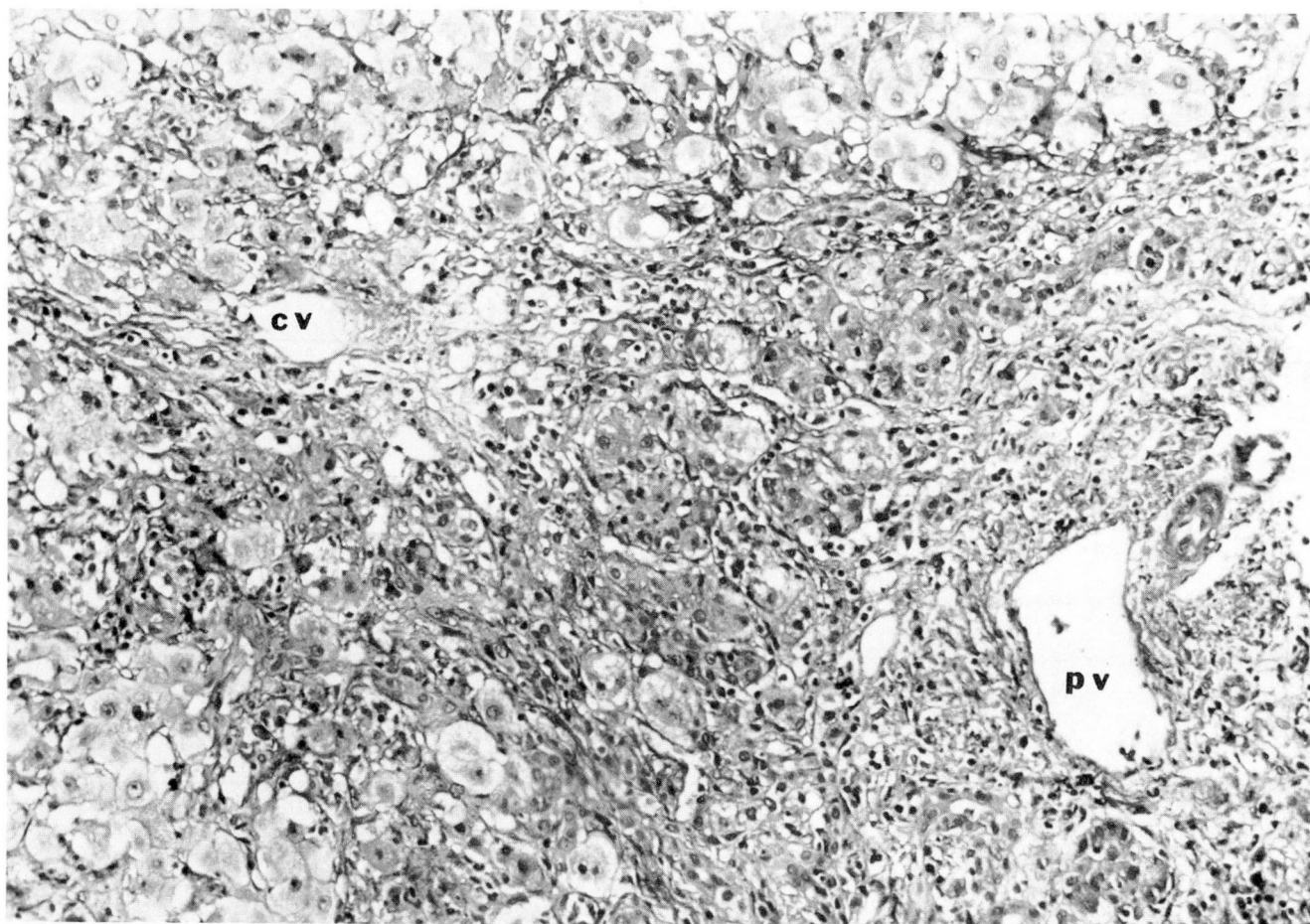


Fig. 1. Case 1. Severe chronic active hepatitis. Necrosis is seen bridging the portal (*pv*) and central veins (*cv*) (hematoxylin and eosin stain, $\times 200$).

normal limits. On admission, she was afebrile, with no hepatomegaly, splenomegaly, or stigmata of liver disease.

Laboratory data included an SGOT of 1,828 IU (normal, 7–40); total bilirubin, 16 mg/dL (normal, 0.2–1); alkaline phosphatase, 580 IU (normal, 20–110); and prothrombin time, 21 seconds with a control of 12. Tests for hepatitis B surface antigen and core antibody were negative. Serum protein electrophoresis showed a gamma globulin level of 3.55 g/dL (normal, 0.7–1.7); an antinuclear antibody test was positive with a titer of 1/320, anti-smooth muscle antibody was present at 1/10, lupus erythematosus (LE) preparation was positive, and serum complement was reduced with CH50 to 66 U (normal, 70–190). Ultrasonography of the gallbladder demonstrated a solitary stone, but no bile duct dilatation.

Three days after admission, peritoneoscopy demonstrated a small liver containing nodules of varying sizes in both lobes. A stone was seen within the lumen of the gallbladder and manipulated with a probe. The spleen was not enlarged. Liver biopsy revealed severe acute hepatitis becoming chronic. There were areas of necrosis bridging the portal

tracts and central veins (*Fig. 1*), multilobular necrosis with extensive areas of collapsed parenchyma, and a moderately dense lymphocytic and plasmacytic infiltrate. Immunoperoxidase stains for hepatitis B and core antigens were negative, and no hyalin bodies or PAS globules were seen. Isolated groups of hepatocytes with a rounded, expansive appearance were seen, consistent with cirrhosis.

On admission, nitrofurantoin was discontinued and prednisone (40 mg/day) and azathioprine (50 mg/day) were started. At the time of discharge nine days later, laboratory findings were: total bilirubin, 18 mg/dL; SGOT, 765 IU; and alkaline phosphatase, 410 IU. Three weeks later, all symptoms had lessened, and biochemical tests showed dramatic improvement (bilirubin, 10.5 mg/dL; SGOT, 207 IU; and alkaline phosphatase, 363 IU). On follow-up three months later, at which time she was taking 50 mg of azathioprine and 10 mg of prednisone daily, her serum bilirubin was 3 mg/dL; SGOT, 150 IU, and alkaline phosphatase, 200 IU. After one year of treatment, she was feeling well; SGOT was 41 IU; alkaline phosphatase, 86 IU; and bilirubin, 0.7 mg/dL.

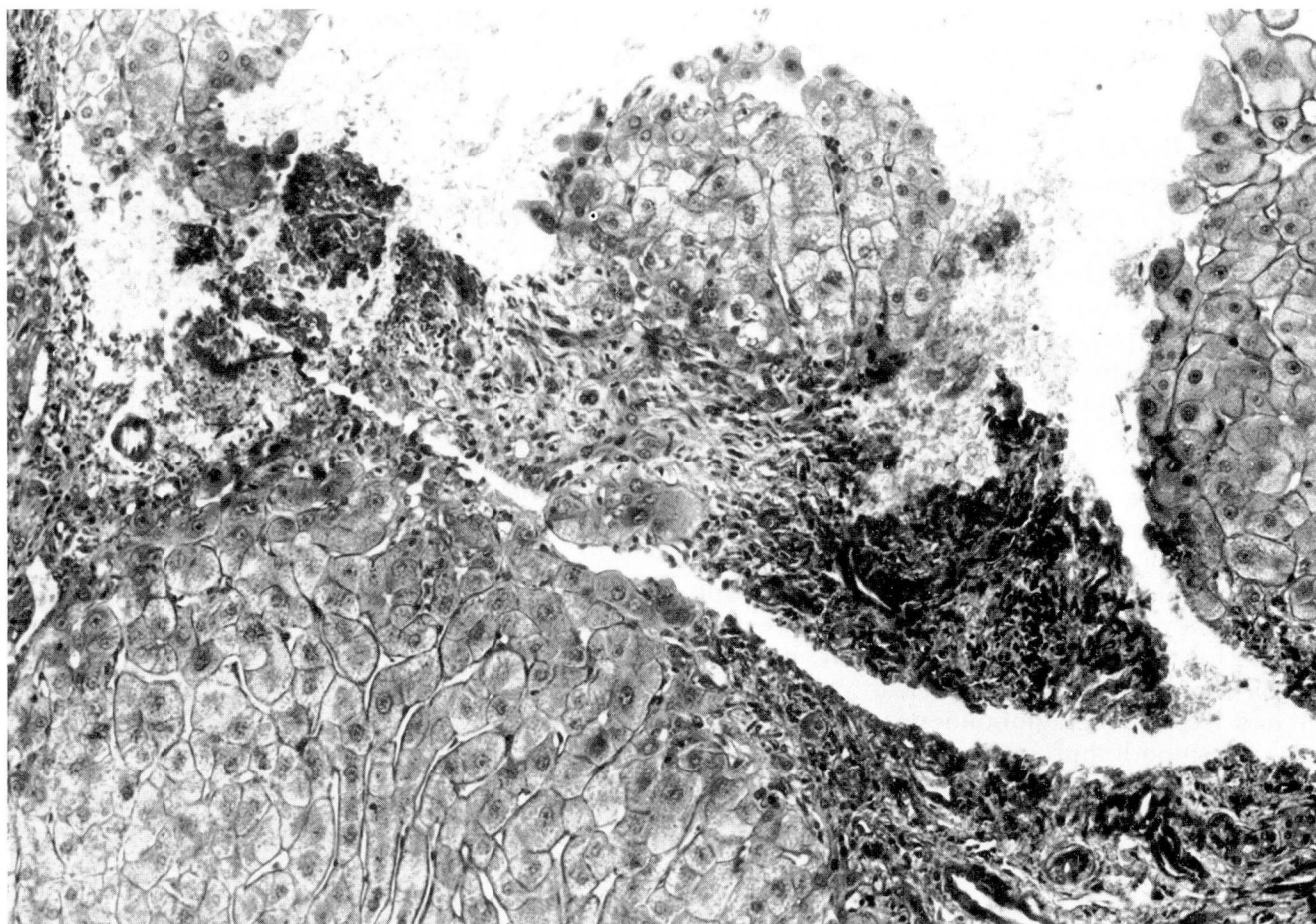


Fig. 2. Case 2. Subsiding chronic active hepatitis. Fibrosis bridging the portal tract is seen, along with mild chronic inflammation (hematoxylin and eosin stain, $\times 200$).

Case 2. This 61-year-old white woman had been on 100–200 mg of nitrofurantoin a day for five years because of chronic pyelonephritis. She presented in 1970 complaining of nausea, fatigue, and jaundice. She denied any ingestion of alcohol, and there was no history of transfusion or exposure to hepatitis. Liver biopsy showed massive necrosis and collapse. Within two weeks after discontinuation of nitrofurantoin, she felt better and was anicteric. No further nitrofurantoin was given.

In April 1977, she was hospitalized for recurrent pyelonephritis, whereupon nitrofurantoin was reinstituted. Several weeks later, she complained of nausea and abdominal pain; jaundice developed, and she was rehospitalized in August. Laboratory findings included an SGOT of 1,200 IU (normal, 7–40); alkaline phosphatase, 400 IU (normal, 30–85); total bilirubin, 10.5 mg/dL (normal, 0.2–1); prothrombin time, 16 seconds with a control of 12; and albumin, 3.4 mg/dl (normal, 3.5–5). Serum protein electrophoresis was normal, and an antinuclear antibody test was positive with a titer of 1:160. Nitrofurantoin was withdrawn. The patient was discharged after 14 days with improved symptoms, total bilirubin, 8.5 mg/dL; SGOT, 1,010 IU; and alkaline phosphatase, 285 IU. Six months later, she was

feeling well; total bilirubin was 1.1 mg/dL; alkaline phosphatase, 180 IU; and SGOT, 75 IU. Percutaneous liver biopsy revealed fibrosis bridging portal tracts (*Fig. 2*) with isolated hepatocytes and mild lymphocytic inflammation, consistent with subsiding chronic active hepatitis. No hyalin bodies or PAS globules were seen. Three years later, she was still well; bilirubin was 1.1 mg/dL; alkaline phosphatase, 83 IU; and SGOT 44 IU.

Discussion

Nitrofurantoin is widely used in the treatment of urinary tract infections.⁴ Hepatic injury, though rare, can range from a self-limiting acute cholestatic reaction associated with short-term use⁵ to chronic active hepatitis⁶ progressing to severe hepatic necrosis and even death.³ Development of autoimmune chronic active hepatitis following long-term nitrofurantoin therapy is rare; however, the five cases reported by Sharp et al,³ as well as their review of 15 previous cases,

revealed a high incidence of antinuclear antibody (71%), anti-smooth muscle antibody (91%), and hypoalbuminemia (87%) along with histological changes suggesting "lupoid" or autoimmune chronic active hepatitis. All patients were women. Two patients who continued to take nitrofurantoin after the onset of jaundice died, while cirrhosis developed in 4. Autoimmune chronic active hepatitis particularly affects women and tends to progress to cirrhosis, usually over a two- to three-year period.⁷ This appears to be one of the multi-system immune processes which may present as thyrotoxicosis, Hashimoto's disease, pulmonary fibrosis, Sjögren's disease, or renal tubular acidosis. The appearance resembles that of SLE, hence the term "lupoid" hepatitis.⁸ Abnormal humoral immunity is manifested as hypergammaglobulinemia and positive reactions for antinuclear, smooth muscle, and rarely anti-mitochondrial antibodies.⁹ Our patients were not tested for antimitochondrial antibody; however, both were positive for antinuclear antibody, and I had hypergammaglobulinemia, and was positive for smooth muscle antibody and SLE as well as reduced complement. The pattern of injury with nitrofurantoin is similar to that induced by oxyphenisatin and methyl dopa.¹⁰ While the histological features do not differ from those of chronic active hepatitis due to other causes, certain possibilities can be ruled out by the absence of specific features such as alcoholic hyalin, PAS globules, and immunoperoxidase stain for hepatitis B surface antigen.

Continued intake of nitrofurantoin appears to be the key factor in perpetuating the hepatic response; thus the first step is to discontinue it. Withdrawal of nitrofurantoin has been shown to result in the return of serum transaminase to normal limits within two to six weeks.¹¹ Our first patient continued to take it for approximately three months after the onset of jaundice; liver biopsy revealed evidence of massive multilobular hepatic necrosis with early cirrhosis. The role of steroids and azathioprine is difficult to deter-

mine. We used them successfully in one patient, but simply discontinuing nitrofurantoin might have led to improvement (though this was not evident during the first few days after withdrawal). Sharp et al³ reported that 3 of their 5 patients were treated with a similar regimen and results were comparable to ours. Our second patient exhibited both symptomatic and biochemical relapse when inadvertently rechallenge with nitrofurantoin.

Edgar Achkar, M.D.
Department of Gastroenterology
The Cleveland Clinic Foundation
9500 Euclid Ave.
Cleveland OH 44106

References

1. Goldstein LI, Ishak KG, Burns W. Hepatic injury associated with nitrofurantoin therapy. *Am J Dig Dis* 1974; **19**:987-998.
2. Engel JJ, Vogt TR, Wilson DE. Cholestatic hepatitis after administration of furan derivatives. *Arch Intern Med* 1975; **135**:733-735.
3. Sharp JR, Ishak KG, Zimmerman HJ. Chronic active hepatitis and severe hepatic necrosis associated with nitrofurantoin. *Ann Intern Med* 1980; **92**:14-19.
4. Mandell SC. Urinary tract antiseptics. [In] Gilman AG, Goodman LS, Gilman A, eds. *The Pharmacological Basis of Therapeutics*. New York, Macmillan, 1980, p 1121.
5. Jokela S. Liver disease due to nitrofurantoin. *Gastroenterology* 1967; **53**:306-311.
6. Strömberg A, Wengle B. Chronic active hepatitis induced by nitrofurantoin (letter). *Br Med J* 1976; **2**:174-175.
7. Mackay IR. The concept of autoimmune liver disease. *Bull NY Acad Med* 1976; **52**:453-465.
8. Runyon BA, LaBrecque DR, Anuras S. The spectrum of liver disease in systemic lupus erythematosus. Report of 33 histologically-proved cases and review of the literature. *Am J Med* 1980; **69**:187-194.
9. De Groote J, Desmet VJ, Gedigk P, et al. A classification of chronic hepatitis. *Lancet* 1968; **2**:626-628.
10. Maddrey WC, Boitnott JK. Drug-induced chronic liver disease. *Gastroenterology* 1977; **72**:1348-1353.
11. Klemola H, Penttilä O, Runeberg L, Tallqvist G. Anicteric liver damage during nitrofurantoin medication. *Scand J Gastroenterol* 1975; **10**:501-505.