

# Pulmonary immunohistology<sup>1</sup>

Raymond R. Tubbs, D.O.

Conventional histopathology has been the basis for pathologic classification of most lung disease. In recent years, new immunohistologic methods based upon both immunofluorescent and immunoenzymatic techniques have expanded the scope and precision of diagnostic pathology and provided new insights into the pathobiology of disease. Pertinent methodology and principles and practice of interpretation are reviewed.

**Index terms:** Fluorescent antibody technic • Immunoenzyme technics • Lung diseases • Lung neoplasms

**Cleve Clin Q** 52:473-482, Winter 1985

Morphologists have traditionally depended upon conventional light microscopy, special stain histochemistry, and, more recently, ultrastructural features to recognize special cell types in the lung and to recognize typical architectural and cytologic features of specific neoplasms. During the past 5-10 years, a new technology, immunohistology, has emerged. Immunohistologic techniques are diverse, and serve to supplement and corroborate diagnostic impressions based on conventional histopathology. Immunohistology is not designed as a primary mode of diagnosis, since diagnoses based solely on such information may be misleading.

Specimen procurement and methodology, expressed cellular phenotypic antigens of different cell types in the pulmonary and pleural parenchyma, and selected diagnostic applications are reviewed.

<sup>1</sup> Department of Pathology, The Cleveland Clinic Foundation. Submitted for publication Apr 1985; accepted May 1985. ht

0009-8787/85/04/0473/10/\$3.50/0

Copyright © 1985, The Cleveland Clinic Foundation

Table. Pulmonary cellular antigens

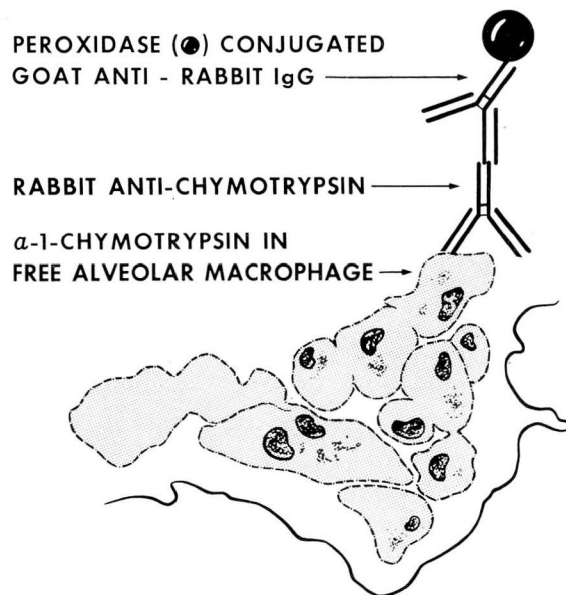
Cell Type	Expressed Cellular Antigens											Acceptable Processing Method					
	PKK-1 AE1/3	MGFII	VIII R:Ag	Desmin	AT	CT	Mur	LeuM5	T11/ T3	T4/ Leu3	T8/ Leu2	Leu14	NKH-1	NSE	Paraffin Section		
															Frozen Section	B5 Solution	Pronased Formalin
Bronchial epithelium	+	+	-	-	-	-	-	-	-	-	-	-	-	-	+	+	+
Bronchial APUD cells	P	V	-	-	-	-	-	-	-	-	-	-	-	+	-	+	-
Pneumocytes	+	+	-	-	V	V	-	-	-	-	-	-	-	-	+	+	+
Pleural mesothelium	+	-	-	-	-	-	-	-	-	-	-	-	-	-	+	+	+
Free alveolar macrophages	-	-	-	-	+	+	+	+	-	V	-	-	-	-	+	+	+
Lymphocytes	-	-	-	-	-	-	-	-	+	-	-	-	-	-	+	-	-
Total T cells	-	-	-	-	-	-	-	-	+	+	-	-	-	-	+	-	-
Helper/inducer T	-	-	-	-	-	-	-	-	+	+	-	-	-	-	+	-	-
Cytotoxic/suppressor T	-	-	-	-	-	-	-	-	+	-	+	-	-	-	+	-	-
B cells	-	-	-	-	-	-	-	-	-	-	-	+	-	-	+	-	-
NK cells	-	-	-	-	-	-	-	-	-	-	-	-	+	-	+	+	-
Endothelium	-	-	+	-	-	-	-	-	-	-	-	-	-	-	+	+	-
Smooth muscle	-	-	-	+	-	-	-	-	-	-	-	-	-	-	+	-	-

Abbreviations: AE1/3 & PKK = cytokeratins; MGFII = milk fat globule II; VIII R:Ag = factor VIII related antigen; AT = alpha-1-antitrypsin; CT = alpha-1-chymotrypsin; Mur = muramidase; NSE = neuron specific enolase; + = present; - = absent; V = variable; P = perinuclear granule.

\* Best or only choice; others are acceptable as indicated (+).

† LeuM5 requires frozen sections; AT, CT, and Mur are best evaluated in B5 but can also be detected in Hollande's and pronased formalin tissue.

## PULMONARY IMMUNOHISTOLOGY INDIRECT TECHNIQUE

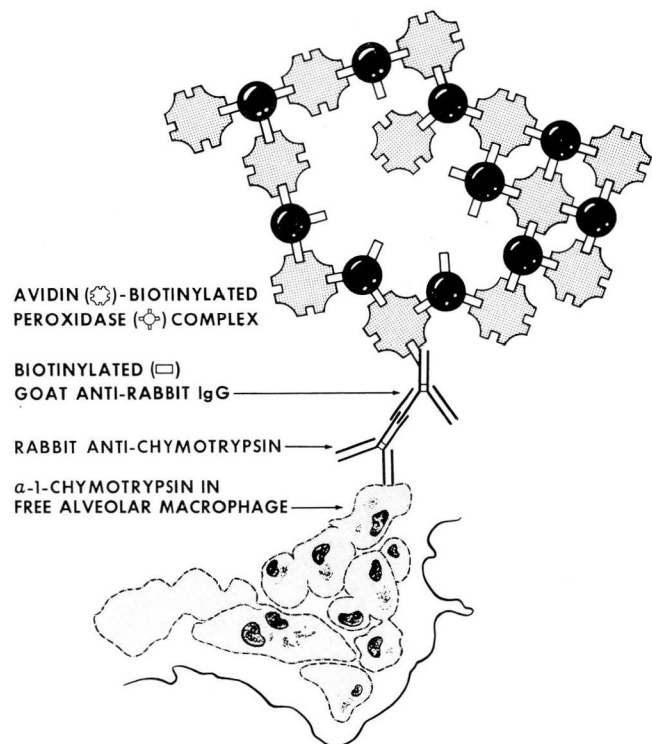


**Fig. 1.** Diagram of indirect immunoperoxidase technique. In this system, rabbit antibody to alpha-1-chymotrypsin is used to label its corresponding antigen in the cytoplasm of a free alveolar macrophage. The secondary reagent, peroxidase-conjugated goat anti-rabbit IgG, is then overlaid on the section. After washing, a color reaction product is developed with either aminoethylcarbazole (giving a red reaction product), or p-phenylenediamine/pyrocatechol (brown-black reaction product). The sections are then counterstained with hematoxylin and mounted.

### Specimen procurement

Conventional processing of tissue using acid or metallic precipitating or cross-linking fixatives frequently destroys many cellular antigens. This destructive process most notably affects differentiation antigens expressed by mononuclear cells, and alters to some degree the nonspecific adhering qualities of antibodies used in procedures. For this reason, it is desirable to develop a processing protocol for lung biopsy specimens to ensure preservation of cellular and extracellular antigens (see the paper by Gephardt, pp 447-471 in this issue). Such a protocol should include, at the very minimum, procurement of frozen tissue, which may or may not be processed

## PULMONARY IMMUNOHISTOLOGY ABC - PO TECHNIQUE

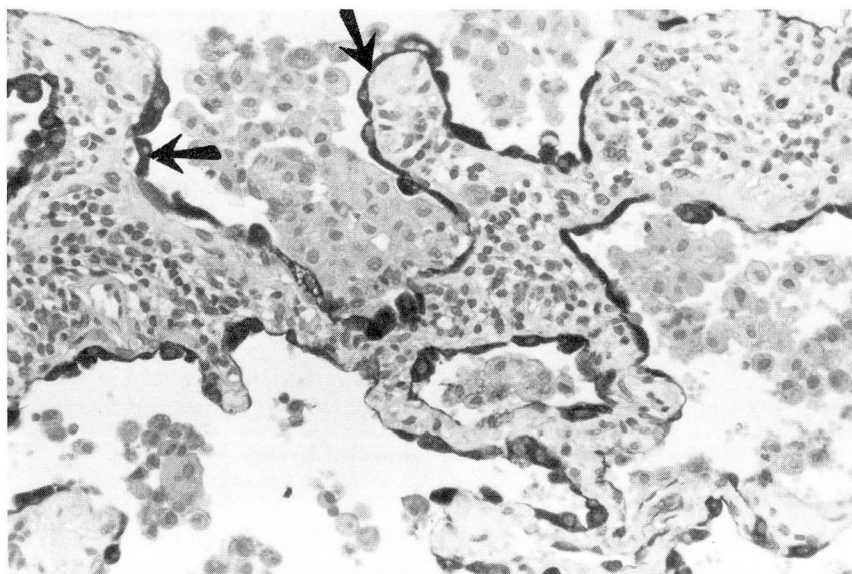


**Fig. 2.** Diagram of avidin biotinylated peroxidase complex technique (ABC-PO). The primary antibody is the same as that used in Figure 1, rabbit anti-alpha-1-chymotrypsin. A soluble preformed complex of avidin D and biotinylated peroxidase is linked to the rabbit primary antibody by the molecular bridge, biotinylated goat anti-rabbit IgG. Unbound avidin in the preformed soluble complex of ABC-PO is linked to the exposed biotin molecules in the secondary antibody. After washing, the color reaction product is developed in the same manner as in Figure 1, and slides are hematoxylin counterstained and mounted.

and can be stored in the frozen state if not used immediately for diagnosis. Such tissue is best preserved when the surface tension of the freezing medium is as close as possible to that of the hydrated tissue, preserving structural integrity. Best results are achieved when the tissue is frozen in isopentane that has been precooled in liquid nitrogen to approximately  $-150^{\circ}\text{C}$ . At this temperature, the isopentane becomes somewhat viscous on visual inspection, and freezing the tissue in this way will ensure the best morphologic preservation. The tissue is then stored in a freezer at  $\leq -70^{\circ}\text{C}$  until sectioning.

Fixative solutions accomplish their designed purpose in several ways. Solutions such as formalin work as cross-linking agents, whereas other





**Fig. 3.** Photomicrograph, desquamative interstitial pneumonitis, immunostained for cytokeratins using monoclonal antibody AE1/3 (arrows), and counterstained with hematoxylin. The pneumocytes lining the septae are positive (arrows), but the free alveolar macrophages are negative.

acidic solutions (e.g., Bouin's or Hollande's) or metallic fixatives (e.g., Zenker's solution, mercuric chloride, B5 solution) fix tissue by precipitation. Cross-linking and precipitation produce molecular changes in antigens, especially in the three-dimensional configuration of the antigen, which, for many molecules, is the important structure conferring antigenicity and reactivity with antibody. However, the severity of such changes induced by fixation is apparently not uniform. The *Table* summarizes the preferred specimen fixation or processing method as a reflection of the ability to detect optimally the cellular antigen being evaluated. It is recommended, therefore, that the protocol include procurement of frozen tissue and tissue fixed in formalin, Hollande's (or Bouin's) solution, and B5. If it is not possible to have multiple fixatives available, the use of Hollande's or Bouin's solution as the primary fixative of choice will generally be adequate for those antigens that do not absolutely require frozen tissue sections.

### Methodology

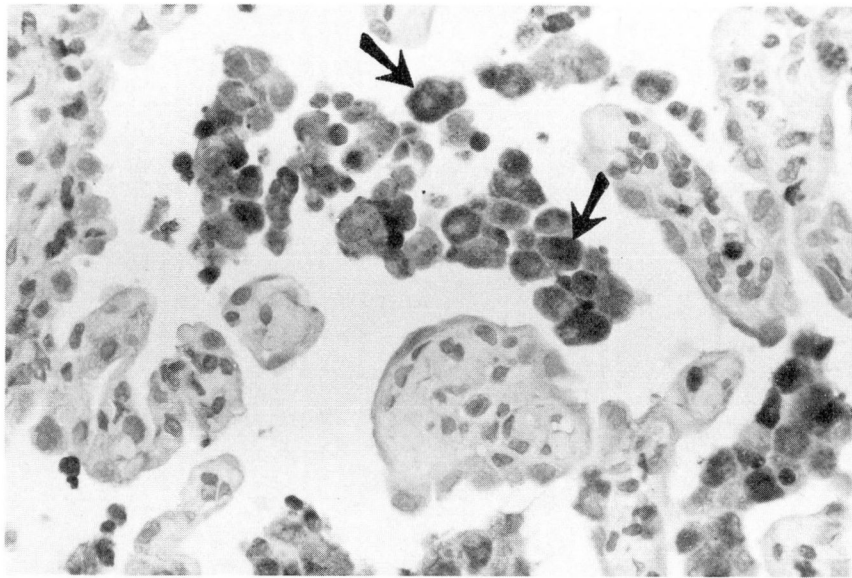
A plethora of immunocytologic and immunohistologic techniques is available to give a profile of antigens in the pulmonary parenchyma. Only a brief overview will be provided here. The reader is referred to other general review articles

on immunohistology for a more thorough treatment of methodology.<sup>1-3</sup>

Both immunofluorescent and immunoenzymatic methods are applicable to pulmonary antigens. The detection marker consists of either a fluorescent or enzyme/substrate/chromogen colored label. Immunofluorescent methods depend upon the labeling of reagents with a fluorescent compound, excitation of the fluorescent label, and visual detection of the emitted fluorescence. Enzyme immunohistologic methods depend on the development of a color reaction product occurring in the tissue when reagents labeled with enzyme produce the colored product in the chromogen in the presence of the appropriate substrate. Although many enzymes can be used as labels, peroxidase has been the most useful in our experience.

Numerous immunohistologic methods have been employed in the study of diseases of the lung. These include direct techniques (immunofluorescent or immunoperoxidase procedures employing antibodies directly labeled with fluorescent or enzymatic compounds), the indirect immunoperoxidase procedure using labeled secondary antibodies (*Fig. 1*), and peroxidase-antiperoxidase and protein A-labeled reagents for indirect and modified peroxidase-antiperoxidase procedures.<sup>1-3</sup> A number of biotin-avidin tech-





**Fig. 4.** Photomicrograph, desquamative interstitial pneumonitis, immunostained for muramidase and counterstained with hematoxylin. The pneumocytes are negative but the free alveolar macrophages are positive (arrows).

niques have also been developed that depend on the extraordinary and essentially irreversible affinity of avidin for biotin (disassociation constant  $1 \times 10^{-9}$ ). For detection of extracellular immune complexes and entrapped immunoglobulins, we prefer the direct immunofluorescent or immunoperoxidase procedure. For detection of cellular antigens, the avidin-biotinylated peroxidase complex (ABC-PO) technique has been the most useful in our experience. The ABC-PO procedure depends upon, in sequence, the reaction of a primary antibody with its appropriate tissue antigen, and then the linking of a soluble, preformed complex of avidin-biotinylated peroxidase to the primary antibody with a biotinylated secondary reagent.<sup>2</sup> This complex procedure is diagrammed in *Figure 2*.

### Pulmonary and pleural cellular antigens

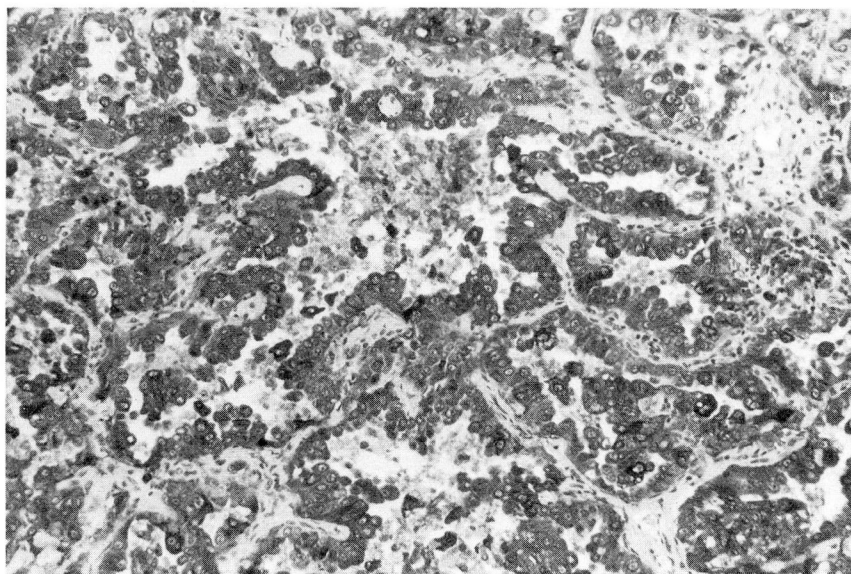
The *Table* summarizes the cellular antigens that can be recognized by individual or combinations of antibodies, and *Figures 3–8* illustrate some specific applications of pulmonary immunohistology. Epithelial elements are best recognized by antibody to cytokeratins (AE1/3 or PKK-1; *Figure 3*). Pneumocytes also display cytokeratins, and sometimes express alpha-1-antitrypsin and alpha-1-chymotrypsin. Pleural mesothelium is also labeled with these anticytokeratin

antibodies, and usually lacks milk fat globule II (MFGII). Alveolar macrophages express alpha-1-antitrypsin and alpha-1-chymotrypsin cytoplasmic enzymes as well as muramidase (*Fig. 4*).

Mononuclear cells are evaluable only in frozen tissue sections. The total T cell population is recognized by the antibody to the sheep erythrocyte receptor (T11 or Leu5) or other Pan-T markers (Leu4/T3). Inducer/helper subpopulations of T cells are identified with T4/Leu3 monoclonal antibodies, and cytotoxic/suppressor T cells with T8/Leu2. The suppressor fraction of T8+ cells can be identified with Leu15, although the latter antibody also labels a subpopulation of natural killer (NK) large granular lymphocytes. The most reproducible staining of B cells without cross-contaminating identification of macrophages is achieved with Leu14. Although several antibodies to large granular lymphocytes that are responsible in part for natural killer activity are available, the most complete labeling of the NK population without cross-labeling of other types is achieved with the NKH-1 antibody. It is emphasized that these monoclonal antibodies to lymphocytes recognize antigens and do not directly measure function in a labeled subpopulation.

Endothelium can be recognized by the expression of Factor VIII-related antigen, or by monoclonal antibodies specifically developed against





**Fig. 5.** Photomicrograph, undifferentiated large-cell carcinoma, immunostained for carcinoembryonic antigen and counterstained with hematoxylin. Intense, predominantly uniform cytoplasmic staining is present, although some individual cells are more intensely stained.

human endothelium. Smooth muscle is best identified with monoclonal antibody to desmin using frozen tissue sections. The neuroendocrine or "APUD" cell of the lung is probably best recognized by the neuron-associated enolase antibody.

### Specific applications

Optimal visual presentation of immunohistologic studies requires color photomicrographs, which are not presented with this paper due to editorial restrictions. Representative black and white photomicrographs are included (*Figs. 3–8*).

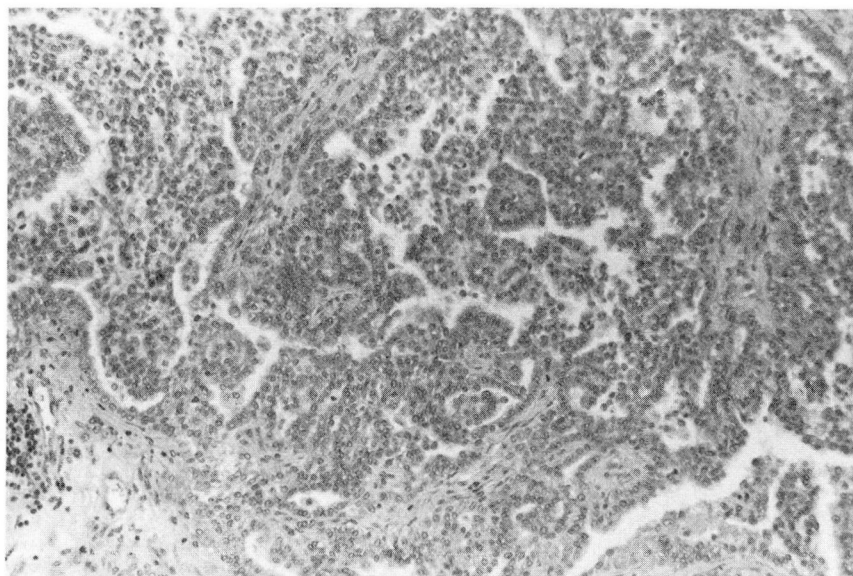
It is generally acknowledged that all types of immunologic reactions can occur in lung disease.<sup>4</sup> Characterization of the cellular immunotypes associated with entrapped inflammatory cells occurring principally as a consequence of Type IV reactions can be accomplished with immunohistologic techniques. Type II and III reactions mediated by autoantibody or immune complexes are probably more unusual in the lung, but when they occur, immunohistologic techniques can be used to detect entrapped septal basement membrane antibody or immune complexes of immunoglobulin and complement.<sup>5–7</sup>

Immunohistologic techniques may be used to clarify the origin and help classify neoplasms in the lung, both metastatic and primary tumors

(*Figs. 5–8*). At this time, there is little that can be offered to help subclassify bronchogenic carcinoma, except that "neuron-specific" enolase and Leu-7 may be helpful in recognizing undifferentiated small-cell carcinoma and distinguishing it from other malignant small-cell tumors such as malignant lymphoma or neuroblastoma.<sup>8</sup> However, in nearly all instances, such diagnoses can be readily made by conventional light microscopy.

On occasion, metastasis to the lung may become a problem in differential diagnosis, or where additional confirmatory evidence may simply be desirable. Metastatic papillary or follicular carcinoma can be shown to be of thyroid origin with the use of thyroglobulin immunostaining.<sup>9</sup> Immunostaining for calcitonin may also be helpful in confirming a diagnosis of metastatic medullary carcinoma of thyroid.<sup>10</sup> Malignant melanoma, whether primary or secondary, can be easily recognized by the expression of cytoplasmic S-100 protein<sup>11</sup> in the absence of expression of cytokeratins peculiar to carcinomas, and by melanoma-specific monoclonal antibodies (*Fig. 8*). Renal cell carcinoma metastatic to the lung can be readily confirmed if frozen section material is available, by documenting the expression of tumor antigens defined by the specific monoclonal antibody Uro-2.<sup>12</sup> Prostatic adenocarcinoma can be identified specifically as to tis-





**Fig. 6.** Photomicrograph, mesothelioma, immunostained for carcinoembryonic antigen and counterstained with hematoxylin. The tumor cells are negative.

sue of origin using prostate-specific antigen.<sup>13</sup> Other developmental monoclonal antibodies show highly selective reactivity or specificity with breast carcinoma, and progress is being made in development of other monoclonal antibodies with specificity for colon and bladder carcinoma. Also, immunohistologic studies for oncofetal antigens such as carcinoembryonic antigen (CEA) may predict serum or plasma markers useful in clinical monitoring.<sup>14</sup>

Sarcomas involving lung can be of either primary or secondary origin. There is much to be learned about the immunohistology of intermediate filaments. However, at this time desmin seems to be a very useful marker for recognizing sarcomas of muscular origin (leiomyosarcoma and rhabdomyosarcoma).<sup>15</sup> Malignant fibrous histiocytoma is very often characterized by the cytoplasmic expression of alpha-1-chymotrypsin.<sup>16</sup> Caution should be exercised in the application of antibodies to intermediate filaments. In fixed tissue specimens, there is often striking nonspecific adherence of immunoglobulin reagents. Frozen sections are preferred for this evaluation.

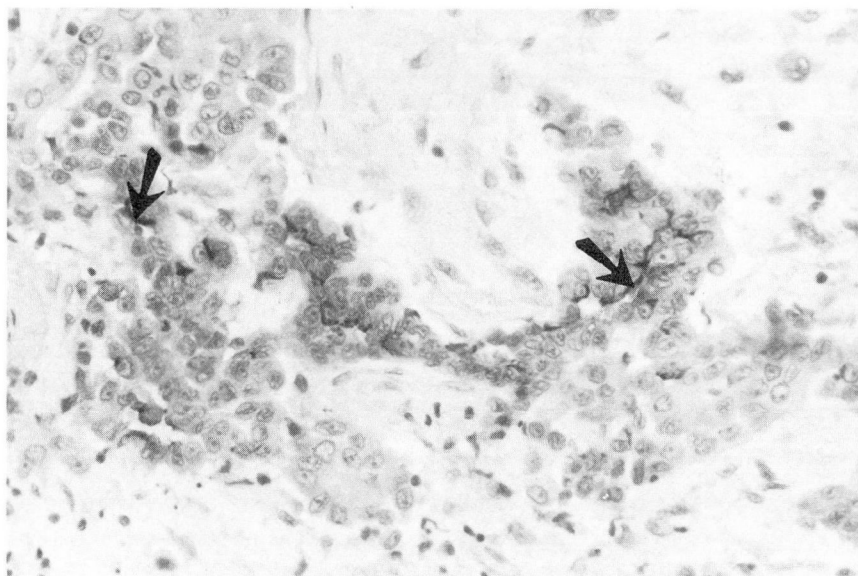
Immunohistologic techniques may also be used to document the cytoplasmic expression of polypeptide hormones associated with ectopic hormone production. Specific applications include carcinoid tumors and undifferentiated small-cell carcinomas associated with ectopic secretion of

adrenocorticotrophic hormone or other hormonal expression.

Much recent literature has been devoted to the diagnosis of pulmonary mesotheliomas and the role of immunohistology in the differential diagnosis of mesothelioma *vs* undifferentiated large-cell carcinoma (Figs. 6 and 7).<sup>17-27</sup> At one time, the dictum "CEA - /keratin + = mesothelioma" or "CEA + /keratin - or trace = carcinoma" appeared to be a useful supportive criterion to make this distinction. However, it has subsequently become clear that such a simplistic approach to the subclassification of these tumors is unrealistic. "Cytokeratin" is not a single antigen but a family of at least 19 related intermediate (10 nm) filaments.<sup>25</sup> Even polyclonal antibodies can be produced to the different molecular-weight subtypes of keratin, and these antibodies have differing avidity and specificity. Furthermore, monoclonal antibodies against cytokeratins are probably epitope-specific, reacting with only portions of a given subtype antigen.

The nature of the material used for study is extremely important; undifferentiated carcinomas in frozen tissue or fixed in formalin solution and pronase-digested show a diffuse generalized cytoplasmic expression of the antigen mimicking exactly that seen in mesotheliomas. While it is true that in Bouin's-fixed material or in non-pronase-digested formalin-fixed material (as opposed to frozen sections or pronase-digested, for-





**Fig. 7.** Photomicrograph, mesothelioma, immunostained for milk fat globule II (mouse monoclonal antibody MFGII) and counterstained with hematoxylin. Surface staining of the neoplastic cells is identified (arrows).

malin-fixed sections) carcinomas usually only show focal positive staining, the potential for misinterpreting the information is great.

Caution should also be exercised in the interpretation of CEA immunostains. Many carcinomas involving the pleura are devoid of CEA, particularly poorly differentiated variants. Some promising results have been reported by Battifora, who found human milk fat globule II (MFGII) in carcinoma, but deletion of this antigen from reactive mesothelium and mesotheliomas.<sup>22</sup> Conversely, Marshall et al have reported MFGII in both carcinomas and mesotheliomas.<sup>23</sup> Much information still needs to be obtained with regard to the differential expression of these antigens. It is strongly recommended that conventional mucin histochemical and electron microscopic findings and clinical history, including occupational exposure and radiography, should be evaluated in conjunction with immunohistologic findings to resolve the differential diagnostic dilemma.

Malignant lymphomas of the lung, albeit unusual, can also be evaluated immunohistologically. Such information can help to establish clonal excess of the neoplastic process and determine T or B cell origin of the neoplasm.<sup>28-35</sup> Immunoglobulins and most differentiation antigens are best profiled in frozen tissue sections or in fresh cell suspensions. Both cytocentrifuge preparations and frozen tissue sections are useful in this setting. Only a few antigens peculiar to

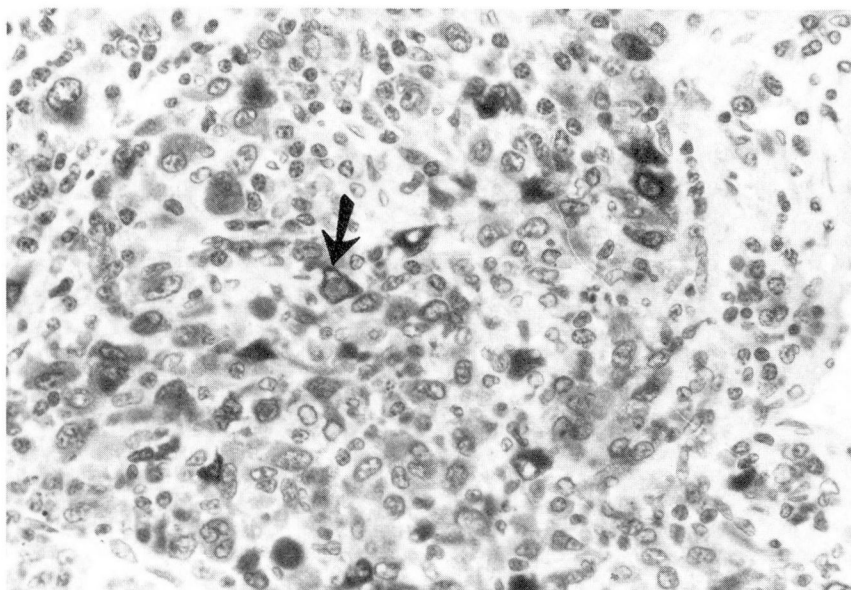
lymphocytes survive fixation and paraffin in processing.<sup>33-35</sup> These markers are of particular value in the differential diagnosis of pulmonary pseudolymphoma *vs* malignant non-Hodgkin's lymphoma. Since most non-Hodgkin's lymphomas are B cell in origin, and show restricted immunoglobulin light-chain expression as reflected in clonal excess, immunohistologic techniques can be used to confirm the presence of B cell non-Hodgkin's lymphoma. Alternatively, these findings, in conjunction with evaluation of T cell subpopulations, can be helpful in confirming the diagnosis of pseudolymphoma or benign lymphoid hyperplasia.

Infectious agents sometimes present a differential diagnostic challenge in the lung, especially the diagnosis of viral pneumonitis. Most of the commercially available antibodies to viruses yield unreliable information, in our experience. This may relate to the complexity of different serotypes of the virus, or other unidentified factors. More recently, in-situ hybridization using biotinylated nucleotide probes of complementary DNA material offer promise in the recognition of viral pneumonias.<sup>36</sup> However, this technology is very new, and great care should be exercised in its application at this time.

## Conclusions

Immunohistology is a useful adjunct to diagnosis in classification of disease processes in the lung. Of great import is the knowledgeable selec-





**Fig. 8.** Photomicrograph, amelanotic melanoma presenting as isolated pulmonary mass. The neoplasm has been immunostained for S-100 protein and counterstained with hematoxylin. Individual malignant cells show cytoplasmic S-100 staining (arrow).

tion and procurement of tissue that will ensure optimum conditions for detection of the desired antigen. Most of the cell-associated antigens in the lung can readily be profiled using immunohistologic techniques currently available. The specific applications include detection of immunoglobulin entrapment and entrapment of immune complexes in autoimmune illnesses, and providing corroborative information to support histopathologic impressions in the differential diagnosis of primary and secondary neoplasms involving the lung.

## References

1. Falini B, Taylor CR. New developments in immunoperoxidase techniques and their application. *Arch Pathol Lab Med* 1983; **107**:105-117.
2. Sheibani K, Tubbs RR. Enzyme immunohistochemistry: technical aspects. *Sem Diag Pathol* 1984; **1**:235-250.
3. Mukai K, Rosai J. Application of immunoperoxidase techniques in surgical pathology. [In] Fenoglio CM, Wolff M, eds. *Progr Surg Pathol*, Vol. I. New York: Masson Publishing, 1980.
4. Caldwell JL, Kaltreider HB. Pulmonary and cardiac diseases. [In] Fudenberg HH, Stites DP, Caldwell JL, Wells JV, eds. *Basic and Clinical Immunology*. 3rd ed. Los Altos, Lange, 1980.
5. Gephardt GN, Ahmad M, Tubbs RR. Pulmonary vasculitis (Wegener's granulomatosis). Immunohistochemical study of T and B cell markers. *Am J Med* 1983; **74**:700-704.
6. Churg A, Franklin W, Chan KL, Kopp E, Carrington CB. Pulmonary hemorrhage and immune-complex deposition in the lung. Complications in a patient with systemic lupus erythematosus. *Arch Pathol Lab Med* 1980; **104**:388-391.
7. Inoue T, Kanayama Y, Ohe A, et al. Immunopathologic studies of pneumonitis in systemic lupus erythematosus. *Ann Int Med* 1979; **91**:30-34.
8. Bunn PA, Linnoila I, Minna JD, Carney D, Gazdar AF. Small cell lung cancer, endocrine cells of the fetal bronchus, and other neuroendocrine cells express the Leu7 antigenic determinant present on natural killer cells. *Blood* 1985; **65**:764-768.
9. Albores-Saavedra J, Nadji M, Civantos F, Morales AR. Thyroglobulin in carcinoma of the thyroid: An immunohistochemical study. *Hum Pathol* 1983; **14**:62-64.
10. DeLellis R, Wolfe H. Calcitonin immunohistochemistry. [In] DeLellis RA, ed. *Diagnostic Immunohistochemistry*. New York, Masson, Inc, 1981, pp 61-74.
11. Nakajima T, Kameya T, Watanabe S, Hirota T, Sato Y, Shimamoto Y. An immunoperoxidase study of S-100 protein distribution in normal and neoplastic tissues. *Am J Surg Pathol* 1982; **6**:715-727.
12. Cordon-Cardo C, Bander NH, Fradat Y, et al. Immunoanatomic dissection of the human urinary tract by monoclonal antibodies. *J Histochem Cytochem* 1984; **32**:1035-1040.
13. Nadji M, Tabei SZ, Castro A, Chu TM, Morales AR. Prostatic origin of tumors: An immunohistochemical study. *Am J Clin Pathol* 1980; **73**:735-739.
14. Goslin RH, O'Brien MJ, Skarin AT, Zamcheck N. Immunocytochemical staining for CEA in small cell carcinoma of lung predicts clinical usefulness of the plasma assay. *Cancer* 1983; **52**:301-306.
15. Gabbiani G, Kapanci Y, Barazzzone P, Franke WW. Immunochemical identification of intermediate-sized filaments in human neoplastic cells. A diagnostic aid for the surgical pathologist. *Am J Pathol* 1981; **104**:206-216.
16. duBoulay CEH. Demonstration of alpha-1-antitrypsin and alpha-1-chymotrypsin in fibrous histiocytomas using the immunoperoxidase technique. *Am J Surg Pathol* 1982; **6**:559-564.
17. Corson JM, Pinkus GS. Mesothelioma: Profile of keratin proteins and carcinoembryonic antigen. An immunoperoxidase study.

- dase study of 20 cases and comparison with pulmonary adenocarcinomas. *Am J Pathol* 1982; **108**:80-87.
18. Schlegel R, Banks-Schlegel S, Pinkus GS. Immunohistochemical localization of keratin in normal human tissues. *Lab Invest* 1980; **42**:91-96.
19. Wang NS, Huang SN, Gold P. Absence of carcinoembryonic antigen-like material in mesothelioma. An immunohistochemical differentiation from other lung cancers. *Cancer* 1979; **44**:937-943.
20. Whitaker D, Shilkin KB. Carcinoembryonic antigen in tissue diagnosis of malignant mesothelioma. *Lancet* 1981; **1**:1369.
21. LaRocca PJ, Rheinwald JG. Coexpression of simple epithelial keratins and vimentin by human mesothelium and mesothelioma *in vivo* and in culture. *Cancer Res* 1984; **44**:2991-2999.
22. Battifora H. Recent progress in the immunohistochemistry of solid tumors. *Sem Diag Pathol* 1984; **1**:251-271.
23. Marshall RJ, Herbert A, Braye SG, Jones DB. Use of antibodies to carcinoembryonic antigen and human milk fat globule to distinguish carcinoma, mesothelioma, and reactive mesothelium. *J Clin Pathol* 1984; **37**:1215-1221.
24. Holden J, Churg A. Immunohistochemical staining for keratin and carcinoembryonic antigen in the diagnosis of malignant mesothelioma. *Am J Surg Pathol* 1984; **8**:277-279.
25. Cooper D, Schermer A, Sun TT. Biology of disease. Classification of human epithelia and their neoplasms using monoclonal antibodies to keratins: Strategies, applications, and limitations. *Lab Invest* 1985; **52**:243-256.
26. Walts AE, Said JW, Shintaku IP, Sassoon AF, Banks-Schlegel S. Keratins of different molecular weight in exfoliated mesothelial and adenocarcinoma cells—An aid to cell identification. *Am J Clin Pathol* 1984; **81**:442-446.
27. Said JW, Nash G, Banks-Schlegel S, Sassoon AF, Murakami S, Shintaku IP. Keratin in human lung tumors. Patterns of localization of different-molecular-weight keratin proteins. *Am J Pathol* 1983; **113**:27-32.
28. Foon KA, Schroff RW, Gale RP. Surface markers on leukemia and lymphoma cells: Recent advances. *Blood* 1982; **60**:1-19.
29. Warnke RA, Gatter KC, Falini B, et al. Diagnosis of human lymphoma with monoclonal antileukocyte antibodies. *N Engl J Med* 1983; **309**:1275-1281.
30. Reinherz EL, Kung PC, Goldstein G, Levey RH, Schlossman SF. Discrete stages of human intrathymic differentiation: Analysis of normal thymocytes and leukemic lymphoblasts of T-cell lineage. *Proc Natl Acad Sci* 1980; **77**:1588-1592.
31. Pinkus GS, Said JW. Characterization of non-Hodgkin's lymphomas using multiple cell markers. Immunologic, morphologic, and cytochemical studies of 72 cases. *Am J Pathol* 1979; **94**:349-380.
32. Stein H, Bonk A, Tolksdorf G, Lennert K, Rodt H, Gerdes J. Immunohistologic analysis of the organization of normal lymphoid tissue and non-Hodgkin's lymphomas. *J Histochem Cytochem* 1980; **28**:746-760.
33. Tubbs RR, Fishleder A, Weiss RA, Savage RA, Sebek BA, Weick JK. Immunohistologic cellular phenotypes of lymphoproliferative disorders. Comprehensive evaluation of 564 cases including 257 non-Hodgkin's lymphomas classified by the International Working Formulation. *Am J Pathol* 1983; **113**:207-221.
34. Tubbs RR, Sheibani K. Immunohistology of lymphoproliferative disorders. *Sem Diag Pathol* 1984; **1**:272-284.
35. Epstein AL, Marder RJ, Winter JN, Fox RI. Two new monoclonal antibodies (LN-1, LN-2) reactive in B5 formalin-fixed, paraffin-embedded tissues with follicular center and mantle zone human B lymphocytes and derived tumors. *J Immunol* 1984; **133**:1028-1036.
36. Myerson D, Hackman RC, Nelson JA, Ward DC, McDougall JK. Widespread presence of histologically occult cytomegalovirus. *Hum Pathol* 1984; **15**:430-439.

Raymond R. Tubbs, D.O.  
Department of Pathology  
The Cleveland Clinic Foundation  
9500 Euclid Avenue  
Cleveland, OH 44106