

# Noninvasive diagnosis of clinically suspected deep venous thrombosis<sup>1</sup>

Marian E. McCandless, R.N.  
Jess R. Young, M.D.  
Claudia L. Swift, R.N.

One hundred ten patients with clinically suspected deep venous thrombosis (DVT) were investigated by both venography and noninvasive testing (segmental air plethysmography and Doppler ultrasonography). The noninvasive tests were normal in all limbs that were normal by venography. The tests detected proximal venous thrombi (popliteal, femoral, or iliac) in 47 of the 50 limbs (94%) with venographically documented thrombi, but in only six of 16 limbs (37%) with calf DVT. Severe extrinsic compression could not be distinguished from acute DVT, but remote DVT usually could be distinguished from acute DVT. An abnormal noninvasive test is a useful finding on which therapeutic decisions can be based. A negative noninvasive test will not exclude calf vein thrombi or nonocclusive proximal vein thrombi.

**Index term:** Thrombophlebitis

**Cleve Clin Q** 52:555-560, Winter 1985

Pulmonary embolism is a common preventable cause of hospital deaths.<sup>1</sup> Since over 90% of pulmonary emboli arise from deep venous thrombosis (DVT) in the legs,<sup>2</sup> the diagnosis and treatment of leg thrombi are of great value in the prevention of pulmonary embolism.

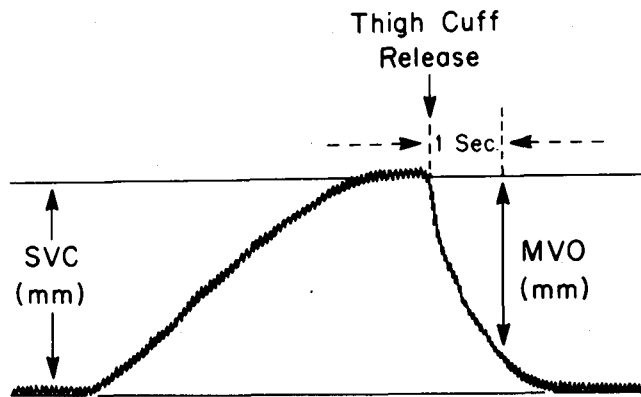
Clinical diagnosis of DVT is inaccurate. The venogram will be normal in about half the patients with signs and symptoms suggestive of DVT, and more than half the patients with thrombi demonstrated by venography will not be diagnosed clinically.<sup>3</sup>

Venography is a highly accurate method of diagnosing DVT. However, it is invasive, expensive,<sup>4</sup> and often uncomfortable for the patient. Because the contrast medium is

<sup>1</sup> Vascular Laboratory, Department of Peripheral Vascular Disease, The Cleveland Clinic Foundation. Submitted for publication Feb. 1985; accepted March 1985.

0009-8787/85/04/0555/06/\$2.50/0

Copyright © 1985, The Cleveland Clinic Foundation



**Figure.** Venous volume displacement curve obtained from normal limb.

irritating, it can produce thrombophlebitis in a small number of patients.<sup>5</sup> Painful sloughs of tissue can result if there is extravasation of the contrast medium, especially in a patient with arterial insufficiency.<sup>6</sup> Contrast media can also cause allergic reactions. Finally, venography is technically impossible in some patients because of marked edema of the legs or feet, or because the veins are not accessible.

Inaccuracy of clinical diagnosis and problems with venography have prompted the development of various noninvasive techniques. The purpose of this study was to evaluate the accuracy of our noninvasive laboratory methods using segmental air plethysmography (Pulse Volume Recorder®, Life Sciences, Inc, Greenwich, CT) in combination with Doppler ultrasonography in diagnosing DVT.

## Materials and Methods

### Patients

One hundred ten consecutive patients presenting with clinically suspected DVT were investigated by both venography and noninvasive testing. All examinations were performed as soon as possible after DVT was suspected clinically. Those venograms and noninvasive studies completed within 48 hours of each other were analyzed. Eighty-three of the 110 patients underwent venography following noninvasive testing. Twenty-seven patients had venography prior to noninvasive testing, but results were withheld from the vascular laboratory personnel until noninvasive testing was completed. Patients ranged

in age from 14 to 81 years, with a mean of 54.3 years. There were 65 men and 45 women. Seventy-eight patients were studied in the hospital and 32 in the outpatient department.

### Venography

Unilateral or bilateral ascending venography was performed in each patient according to the method of Rabinov and Paulin.<sup>7</sup> The deep system was visualized from the arch of the foot to the pelvis.

### Pulse volume recorder (PVR)

This method is described by Raines et al.<sup>8</sup> The iliofemoral, popliteal, and deep veins of the calf were examined for thrombi by applying three cuffs on the leg, one each at the thigh, calf, and ankle levels. The calf cuff was connected to the monitoring port of the PVR. The thigh cuff was connected to the occlusion port of the PVR at a pressure of 50 mmHg to occlude venous outflow without impeding arterial flow. The same procedure was followed at the calf and ankle level. Volume change was recorded on a strip chart, both during the steady rise in pressure and with the release of the proximal venous tourniquet. The segmental venous capacitance (SVC) was defined as the height in mm from the initial baseline to the plateau (*Fig*). The maximum venous outflow (MVO) was defined by measuring 5 mm (1 sec) along the time axis from the point of thigh cuff release. A perpendicular line was dropped from this point until it intersected the downslope recording. This distance in mm from the plateau to the point of intersection of this perpendicular line with the downslope was termed the MVO. During a Valsalva maneuver, the presence or absence of respiratory waves at the calf level was documented by PVR tracings.

To try to diagnose the presence or absence of DVT, the height of the SVC and the MVO at the thigh and calf levels were noted, as well as the presence or absence of respiratory waves. A comparison of these features in the two legs was most important. Whenever abnormal findings were obtained during the first examination, a second examination was performed with the patient's knee flexed to 30 degrees and the hip in mild external rotation. If a marked discrepancy between the two limbs persisted, this was interpreted as being diagnostic of DVT. In patients with equivocal findings, the results of the Dop-

pler ultrasound examination helped make the diagnosis.

### *Doppler ultrasound*

The Doppler examination was done with a MedaSonic 5.3-MHz portable flow meter. Doppler sounds were checked over the common femoral, superficial femoral, popliteal, anterior tibial, and posterior tibial veins. These deep veins were checked for the following: audibility, spontaneity, augmentation with distal compression, augmentation with release of proximal compression, competency of valves with proximal compression, pulsatility, and obliteration of signals with the Valsalva maneuver. The venous Doppler signals of the two legs were always compared. Care was taken to ensure that the deep veins, not the superficial veins, were examined. Characteristically, deep venous signals are low pitched while superficial venous signals are high pitched. The greater saphenous vein was the only superficial vein examined by Doppler ultrasound. When the deep system was patent, the greater saphenous signal was diminished bilaterally and equally. When a thrombus was present in the deep system, the greater saphenous vein signal often became louder because of increased blood flow, indicating that the greater saphenous vein was acting as a major collateral in the affected leg.<sup>9</sup>

If either the PVR or the Doppler examination was positive, the study was interpreted as a positive test for DVT.

### **Results**

The venographic and vascular laboratory results for the 110 patients studied are shown in the *Table*. The vascular laboratory studies were interpreted as normal in all limbs with normal venograms, a specificity of 100%. Fifty patients had limbs that were demonstrated by venography to have proximal vein thrombosis (PVT), indicating involvement of the popliteal, femoral, or iliac veins. The vascular laboratory studies were interpreted as abnormal in 47 of the 50 limbs with PVT, a sensitivity of 94%. Thirty-five of the 47 limb studies interpreted as abnormal were positive by both PVR tracings and Doppler ultrasound. Eight of the 47 limb studies interpreted as abnormal were positive by Doppler ultrasound signals alone. Four of the 47 limb studies interpreted as abnormal were positive by PVR trac-

**Table.** Comparison of venogram and vascular laboratory findings in 110 patients suspected of having deep vein thrombosis

Vascular Lab	Venogram				
	Normal	PVT	Calf DVT	Ext. Comp.	CVI
Normal	36	3	10	0	0
Abnormal	0	47	6	3	5
Total	36	50	16	3	5

PVT = proximal vein thrombosis; DVT = deep venous thrombosis; Ext. Comp. = external compression; CVI = chronic venous insufficiency.

ings alone. No correlation could be drawn between size or location of the thrombus and the sensitivity of the Doppler ultrasound or PVR tracings.

Of the three limbs with PVT that were interpreted as normal by vascular laboratory studies, nonocclusive thrombi were present in two limbs and a reduplicated popliteal vein with thrombus in only one vein was present in one limb.

Only six of the 16 patients with calf vein thrombi had abnormal vascular laboratory findings, a sensitivity of 37%. Five limb studies were abnormal by Doppler ultrasound and normal by PVR tracings, and one study was abnormal by PVR tracings alone.

Three patients whose venograms demonstrated external venous compression had vascular laboratory studies interpreted as positive for either deep venous thrombosis or external compression. In one patient, the popliteal vein was compressed by a Baker's cyst; this study was positive by PVR tracings alone. The other two patients had external iliac vein compression, one by tumor and one by hematoma. One of these patients had abnormal PVR and Doppler studies, while the other had abnormal Doppler signals alone.

Five patients had venographic evidence of chronic venous insufficiency secondary to a remote DVT with no evidence of acute venous thrombosis. The vascular laboratory findings were abnormal in all five. Two of the five had significant PVR (SVC and MVO) changes and all had some abnormalities on the Doppler examination, changes suggesting acute DVT. However, all five patients had normal PVR respiratory waveforms, an unexpected finding in acute

DVT and more compatible with chronic insufficiency. On the basis of the vascular laboratory findings, four of the five cases were correctly diagnosed as chronic venous insufficiency and one was misdiagnosed as acute DVT.

## Discussion

### *Results of study*

The role of noninvasive laboratory studies in the management of patients with suspected deep venous thrombosis is still evolving. Venography will most likely remain the standard diagnostic method, but the problems of expense, discomfort, allergy, irritation of veins, and extravasation of contrast medium remain. Even when available, venography cannot always be performed on short notice, or the test may be inadequate for technical reasons.

The results of our study indicate that noninvasive laboratory methods, using the Pulse Volume Recorder in combination with Doppler ultrasonography, can detect proximal vein thrombosis in a specific and sensitive manner. The vascular laboratory studies were normal in all limbs that were normal by venography. We detected proximal venous thrombi in 47 of the 50 limbs with venographically documented PVT. Eight of the 47 limb studies were interpreted as positive by Doppler ultrasound alone. Four studies were interpreted as positive by abnormal PVR waveforms alone. These findings emphasize the importance of doing both procedures.

The major limitation of noninvasive laboratory studies is that the tests are relatively insensitive to calf vein thrombi. We detected thrombi in only six of 16 limbs that had calf DVT detected by venography. A few studies have reported a higher degree of accuracy with Doppler ultrasonography in diagnosing calf vein thrombi. Sumner and Lambeth<sup>10</sup> emphasized the interpretation of spontaneous and augmented signals in the posterior tibial veins and reported a sensitivity of 91% and a specificity of 84%. Barnes et al<sup>11</sup> paid particular attention to the diminished augmentation of the posterior tibial venous flow velocity at the ankle after release of compression of the calf and reported a sensitivity of 94% and a specificity of 78% in calf DVT. In the present study only five of 16 thrombi occurring below the knee involved the posterior tibial vein. Most involved another vein, were single, and were small. In spite of attempting to follow the advice

of these investigators, we have been unable to improve our diagnostic accuracy in calf vein thrombosis. Our results are more in accord with the experience of other investigators<sup>3,12-14</sup> who report a sensitivity in detection of calf DVT of 22 to 65%.

At this time there is no unanimous opinion as to what should be done with patients who have thrombi confined to the calves. Some<sup>15</sup> believe that they should not be treated because of a negligible risk of clinically significant pulmonary embolism. However, since about 20% of calf vein thrombi extend to the proximal veins,<sup>16</sup> we treat these patients with anticoagulants. Patients at high risk of bleeding during anticoagulant therapy can be monitored noninvasively, treating with anticoagulants or caval interruption only those with propagation of thrombi to the proximal veins.

The decision regarding further diagnostic and therapeutic steps for the patient suspected of having a DVT who has negative noninvasive tests remains difficult. Wheeler<sup>1</sup> reported experience using impedance plethysmography in 1,464 consecutive patients suspected of having DVT. In 1,074 patients with negative noninvasive testing and no treatment, no patient died, the incidence of nonfatal pulmonary embolism was 1%, and an additional patient returned with subsequent signs and symptoms of DVT. However, based on the experience that we are reporting, a patient with negative noninvasive testing would have a 6% chance of having a proximal vein thrombosis and a 63% chance of having a calf DVT. Therefore it is still our practice to do venography on those patients who clinically are strongly suspected of having DVT.

### *Vascular laboratory technic*

The accuracy of the testing procedures used in this study suffers when the tests are performed in a hurried manner or by inexperienced technologists. Because of this the use of noninvasive laboratory studies to diagnose DVT probably should be limited to centers with sufficient patient volume to sharpen the technologists' skills and sufficient resources and commitment to provide adequate quality control.

Various situations can cause false-negative or false-positive noninvasive studies. As mentioned previously, thrombi in the calf are difficult to detect. A duplicated superficial femoral vein in



the thigh or a nonocclusive venous thrombus can cause false-negative studies in patients with proximal DVT. External compression of a major vein can affect both venous inflow and outflow, and at times cannot be distinguished from DVT. Pulsation of venous sounds, seen in patients with congestive heart failure, severe bradycardia, and fluid overload, can make the study difficult to interpret. An "abnormal" study resulting from compression from ascites, pregnancy, or a kidney transplanted in the iliac fossa can at times be interpreted correctly by repositioning the patient from side to side. Abdominal compression must be substituted for the Valsalva maneuver in patients unable to perform the maneuver. Patients unable to relax their leg muscles must be repositioned by flexing the knee. Ventilators and abdominal, groin, and leg incisions can present a challenge for an adequate noninvasive examination.

The differentiation of acute DVT from chronic venous insufficiency can be difficult in the vascular laboratory. Continuous Doppler signals, or slightly phasic sounds with the Valsalva maneuver, can be present in both acute DVT and chronic venous insufficiency. In addition, the greater saphenous vein Doppler signal may be louder in the involved leg in both conditions. However, respiratory waves on the PVR recording usually disappear with acute DVT and reappear as the collateral circulation develops in chronic venous insufficiency. The finding of valvular incompetence usually indicates chronic venous insufficiency. The absence of a Doppler signal over a deep vein, the lack of augmentation of Doppler signals with distal compression, and the attenuation in augmentation of the signal with release of proximal compression are usually reliable signs of acute DVT. If the patient has had previous venous studies in the vascular laboratory, comparison of findings can also help to clarify the diagnosis.

Severe compression of a proximal vein can give findings that cannot be distinguished from acute DVT. If trauma and hematoma can be eliminated as the cause of the compression, we believe that anticoagulants should be used in patients with severe venous compression because of the danger of subsequent venous thrombosis.

Early in our experience we abandoned the "Venous Evaluation Points" scoring system for the Pulse Volume Recorder as described by

Raines et al<sup>8</sup> because of the lack of correlation of our findings with venography. Although our criteria for the diagnosis of deep venous thrombosis by PVR have thus been liberalized, the specificity has not been adversely affected. We realize that some of the interpretation is subjective and dependent on the experience of the technicians. We are in the process of retrospectively analyzing all of the data in our studies to see if more objective criteria can be formulated.

## Conclusions

Our results indicate that every patient with abnormal venous tests in our noninvasive laboratory will have venographically demonstrable deep venous thrombus, severe external compression, or chronic venous insufficiency. Severe compression could not be distinguished from acute DVT, but remote DVT usually could be distinguished from acute DVT. There were no false-positive noninvasive tests. An abnormal noninvasive result is therefore a useful finding on which therapeutic decisions can be based. However, a negative or equivocal result does not exclude calf vein thrombosis or nonocclusive proximal vein thrombosis. If other diagnostic measures such as venography or radionuclide scanning are available, therapeutic decisions in patients with clinical suspicion of DVT should not be made on the basis of a negative noninvasive test.

## References

1. Wheeler HB. A modern approach to diagnosing deep venous thrombosis. *J Cardiovasc Med* 1980; **5**:217-221.
2. Sevitt S, Gallagher N. Venous thrombosis and pulmonary embolism: A clinico-pathological study in injured and burned patients. *Brit J Surg* 1961; **48**:475-489.
3. Richards KL, Armstrong JD, Tikoff G, Hershgold EJ, Booth JL, Rampton JB. Noninvasive diagnosis of deep venous thrombosis. *Arch Intern Med* 1976; **136**:1091-1096.
4. Hull R, Hirsh J, Sackett DL, Stoddart G. Cost effectiveness of clinical diagnosis, venography, and noninvasive testing in patients with symptomatic deep vein thrombosis. *N Engl J Med* 1981; **304**:1561-1567.
5. Bynnum LJ, Wilson JE, Crotty CM, Curry TS, Smithson HL. Noninvasive diagnosis of deep venous thrombosis by phleboreography. *Ann Intern Med* 1978; **89**:162-166.
6. Gordon JJ. Evaluation of suspected deep venous thrombosis in the arteriosclerotic patient. *Am J Roentgenol* 1978; **131**:531-533.
7. Rabinov K, Paulin S. Roentgen diagnosis of venous thrombosis in the leg. *Arch Surg* 1972; **104**:134-144.

8. Raines JK, Jaffrin MY, Rao S. A noninvasive pressure-pulse recorder: Development and rationale. *Med Instrum* 1973; **7**:245-250.
9. Barnes RW. Current status of noninvasive tests in the diagnosis of venous disease. *Surg Clin N Amer* 1982; **62**:489-500.
10. Sumner DS, Lambeth A. Reliability of Doppler ultrasound in the diagnosis of acute venous thrombosis both above and below the knee. *Am J Surg* 1979; **138**:205-210.
11. Barnes RW, Russell HE, Wu KK, Hoak JC. Accuracy of Doppler ultrasound in clinically suspected venous thrombosis of the calf. *Surg Gynec Obstet* 1976; **143**:425-428.
12. Hanel KC, Abbott WM, Reidy NC, et al. The role of two noninvasive tests in deep venous thrombosis. *Ann Surg* 1981; **194**:725-730.
13. Flanigan DP, Goodreau JJ, Burnham SJ, Bergan JJ, Yao JS. Vascular-laboratory diagnosis of clinically suspected acute deep-vein thrombosis. *Lancet* 1978; **2**:331-334.
14. Benedict KT, Wheeler HB, Patwardhan NA. Impedance plethysmography: Correlation with contrast venography. *Radiology* 1977; **125**:695-699.
15. Lemoine JR. Proximal versus distal deep-vein thrombosis and the risk of embolism. *Practical Cardiol* 1985; **2**:174-181.
16. Kakkar VV, Corrigan T, Spindler J, et al. Efficacy of low doses of heparin in prevention of deep-vein thrombosis after major surgery: A double-blind, randomised trial. *Lancet* 1972; **2**:101-106.

Vascular Laboratory  
Department of Peripheral Vascular Disease  
The Cleveland Clinic Foundation  
9500 Euclid Avenue  
Cleveland, OH 44106