

# Digital subtraction angiography in the diagnosis of arrhythmogenic right ventricular dysplasia<sup>1</sup>

Dean M. Pollock, M.D.  
Lon W. Castle, M.D.  
Robert Detrano, M.D.  
Richard Sterba, M.D.

Arrhythmogenic right ventricular dysplasia (ARVD) is a pathologic entity consisting of abnormal structure and function of the right ventricular myocardium, causing arrhythmias and heart failure. The diagnosis is based on electrocardiographic or electrophysiologic evidence that the arrhythmia arises in the right ventricle, as well as angiographic evidence of abnormal right ventricular contraction. The authors used intravenous digital subtraction techniques in making this diagnosis in 2 patients and suggest the use of these techniques for patients with right ventricular tachycardia to rule out ARVD.

**Index terms:** Angiography • Heart ventricle • Myocardial diseases • Subtraction technic

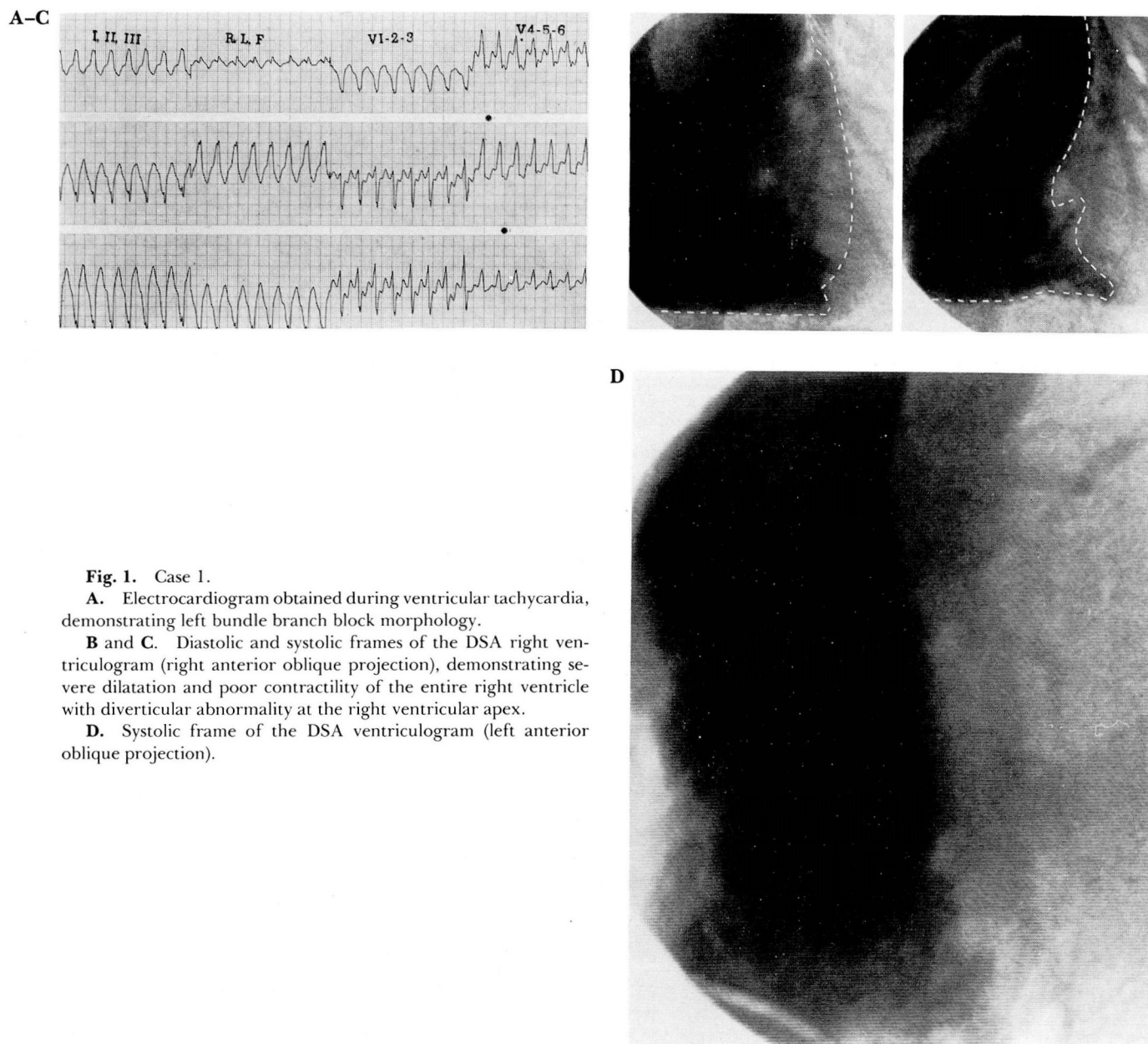
**Cleve Clin Q** 52:569-571, Winter 1985

Arrhythmogenic right ventricular dysplasia (ARVD) is a recently described pathologic entity in which the right ventricular myocardium is partially or completely replaced by fibrous or fatty tissue.<sup>1</sup> The usual clinical manifestation is ventricular arrhythmias, though congestive heart failure may predominate if the involvement is extensive.<sup>1</sup> The diagnosis of ARVD is based on electrocardiographic (or electrophysiologic) evidence that the ventricular arrhythmias arise in the right ventricle, along with angiographic evidence of generalized or localized right ventricle dysfunction. We have used intravenous digital subtraction angiography (DSA) to confirm the diagnosis of ARVD in 2 patients. DSA was performed using a commercially available unit (Philips DVI I) after a power injection of Renografin-76 into a peripheral vein, as previously described.<sup>2</sup>

<sup>1</sup> Department of Cardiology, The Cleveland Clinic Foundation. Submitted for publication June 1985; accepted July 1985.

0009-8787/85/04/0569/03/\$1.75/0

Copyright © 1985, The Cleveland Clinic Foundation



**Fig. 1.** Case 1.

**A.** Electrocardiogram obtained during ventricular tachycardia, demonstrating left bundle branch block morphology.

**B and C.** Diastolic and systolic frames of the DSA right ventriculogram (right anterior oblique projection), demonstrating severe dilatation and poor contractility of the entire right ventricle with diverticular abnormality at the right ventricular apex.

**D.** Systolic frame of the DSA ventriculogram (left anterior oblique projection).

## Case reports

**Case 1.** A 38-year-old man presented with a two-month history of recurrent, sustained, exertional ventricular tachycardia requiring cardioversion on multiple occasions. There was no other personal or family history of cardiac disease. The physical examination, chest radiograph, echocardiogram, and left heart catheterization were normal. The electrocardiogram revealed nonspecific ST and T wave changes in the right precordial leads. Electrophysiologic testing showed that sustained ventricular tachycardia with a left bundle branch block configuration (Fig. 1A) was easily inducible. Earliest activation during ventricular tachycardia was near the right ventricular apex. DSA documented gen-

eralized dilatation and hypokinesis of the right ventricle (Figs. 1, B-D). His arrhythmia responded to treatment with amiodarone and quinidine.

**Case 2.** A 73-year-old man presented in November 1981 with recurrent syncope and dyspnea on exertion. He had required cardioversion from ventricular tachycardia on one previous occasion. The physical examination was normal, with the exception of multiple extra systoles and the presence of  $S_3$  and  $S_4$ . The chest radiograph showed cardiomegaly. The electrocardiogram showed first-degree atrioventricular block; Q waves in leads II, III, and AVF; and wide, bizarre QRS complexes (probably representing post-



excitation potentials) (Fig. 2). Holter monitoring documented frequent runs of nonsustained ventricular tachycardia with left bundle branch block morphology. At catheterization, right and left heart pressures were normal, the cardiac index was 2.0 L/min, the coronary arteries were normal, and there was generalized, moderate impairment of left ventricular contractility with localized dyskinesia at the apex. DSA showed severe dilatation and hypokinesis of the entire right ventricle with apical dyskinesia. The levophase showed mild impairment of left ventricular contractility. His arrhythmia was controlled for 27 months with amiodarone, however, the congestive heart failure worsened. In February 1984, amiodarone was discontinued because of tremors. One month later, he died of intractable congestive heart failure with a terminal ventricular arrhythmia. Autopsy documented typical histologic changes of ARVD.

## Discussion

The diagnosis of ARVD requires angiographic evidence of right ventricular dysfunction. Two-dimensional echocardiography has been used in the diagnosis of ARVD,<sup>3</sup> Uhl's anomaly,<sup>4</sup> and in differentiating these conditions from Ebstein's anomaly.<sup>1,3,4</sup> However, poor spatial resolution and inadequate ultrasound penetration of pulmonary or chest wall structures often preclude the attainment of diagnostic right ventricular images. Likewise, radionuclide ventriculography, which also has been used in the assessment of Uhl's anomaly,<sup>4</sup> may not provide sufficiently detailed images to make a specific diagnosis. Standard right ventricular angiography has, therefore, been required in most cases.<sup>1</sup>

Digital subtraction right ventriculography provides images comparable to standard angiograms with lower doses of contrast media and radiation.<sup>2</sup> It is a less invasive procedure which may be less costly and has been used to visualize abnormalities of right heart structures and function.<sup>2</sup>

In patients with left bundle branch block pattern ventricular tachycardia, the diagnosis of ARVD should be considered.<sup>5</sup> Since many patients with ARVD are young,<sup>1</sup> and ischemic heart disease is an unlikely substrate for their arrhythmia, left heart catheterization may not be necessary.<sup>6</sup> In any age group, DSA can be a sufficient alternative to conventional angiography for the evaluation of ventricular function. We have successfully combined the clinical history of left bundle branch block pattern ventricular tachycardia with right ventricular dysfunction demonstrated by DSA to make the diagnosis of ARVD. We

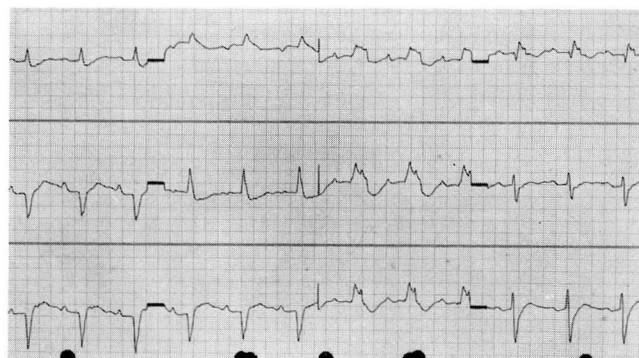


Fig. 2. Case 2. Electrocardiogram shows wide, bizarre QRS complexes which represent delayed postexcitation potentials and are best seen in the right precordial leads V<sub>1-4</sub>.

would suggest DSA as a possible screening technique for patients with left bundle branch block pattern ventricular tachycardia, in the absence of coronary artery disease, to rule out ARVD.

## Acknowledgment

We thank Susan Withrow and Jo Rolph for their technical and secretarial assistance.

Lon W. Castle, M.D.  
Department of Cardiology  
The Cleveland Clinic Foundation  
9500 Euclid Ave.  
Cleveland, OH 44106

## References

1. Marcus FI, Fontaine GH, Guiraudon G, et al. Right ventricular dysplasia: a report of 24 adult cases. *Circulation* 1982; **65**:384-398.
2. Moodie DS, Buonocore E, Yiannikas J, Gill CC, Pavlicek WA. Digital subtraction angiography in congenital heart disease in pediatric patients. *Cleve Clin Q* 1982; **49**:159-171.
3. Baran A, Nanda NC, Falkoff M, Barold SS, Gallagher JJ. Two-dimensional echocardiographic detection of arrhythmogenic right ventricular dysplasia. *Am Heart J* 1982; **103**:1066-1067.
4. Child JS, Perloff JK, Francoz R, et al. Uhl's anomaly (parchment right ventricle): clinical, echocardiographic, radionuclide, hemodynamic and angiographic features in 2 patients. *Am J Cardiol* 1984; **53**:635-637.
5. Reiter MJ, Smith WM, Gallagher JJ. Clinical spectrum of ventricular tachycardia with left bundle branch morphology. *Am J Cardiol* 1983; **51**:113-121.
6. Benson DW Jr, Benditt DG, Anderson RW, et al. Cardiac arrest in young, ostensibly healthy patients: clinical, hemodynamic, and electrophysiologic findings. *Am J Cardiol* 1983; **52**:65-69.