

# Cardiac amyloidosis in a patient with Ehlers-Danlos syndrome type IV<sup>1</sup>

John H. Wilson, M.D.  
Douglas S. Moodie, M.D.

**A patient with typical clinical features of Ehlers-Danlos syndrome Type IV was found to have systemic amyloidosis that was proved by cardiac biopsy. The various types and subtypes of Ehlers-Danlos syndrome are reviewed, along with the associated cardiac anomalies.**

**Index terms:** Amyloidosis • Ehlers-Danlos syndrome

**Cleve Clin Q** 53:205-211, Summer, 1986

Although a variety of cardiac abnormalities, some of which may be causally related, has been described in the different types of Ehlers-Danlos syndrome, cardiac amyloidosis has not, to our knowledge, previously been reported. We report a case of biopsy-proved cardiac amyloidosis in a patient with Type IV Ehlers-Danlos syndrome and review the cardiac abnormalities previously reported in this and other varieties of the Ehlers-Danlos syndrome.

## Case report

The patient was first examined at our institution at the age of 35. He had been diagnosed as having Ehlers-Danlos syndrome Type IV four years previously at another insti-

tution. The diagnosis was based on clinical symptoms; fibroblast culture to assess production of type III collagen had not been performed. Since the age of four, he had been troubled with discoloration of the skin, easy bruising, and recurrent hematomas. Three of his four children were normal; the fourth, a son, also bruised easily. The patient's parents and five siblings all were apparently normal. He had a history of pericarditis. Over the previous four months he had begun to be troubled with bilateral leg edema, which had not responded to treatment with compression stockings.

Physical examination revealed a 35-year-old man with a thin face (*Fig. 1*). His blood pressure was 130/75 mm Hg; the pulse was 82 and regular. The skin was thin and multiple ecchymoses were present. Auscultation of the heart revealed a Grade I/VI middle to late systolic murmur. No gallops were present. The lungs were clear. There was moderate leg edema bilaterally and a bluish-brown discoloration of the skin of the lower legs. A stasis ulcer was present on the right leg over the anterior tibial region. The remainder of the physical examination was unremarkable. Ophthalmic examination was normal.

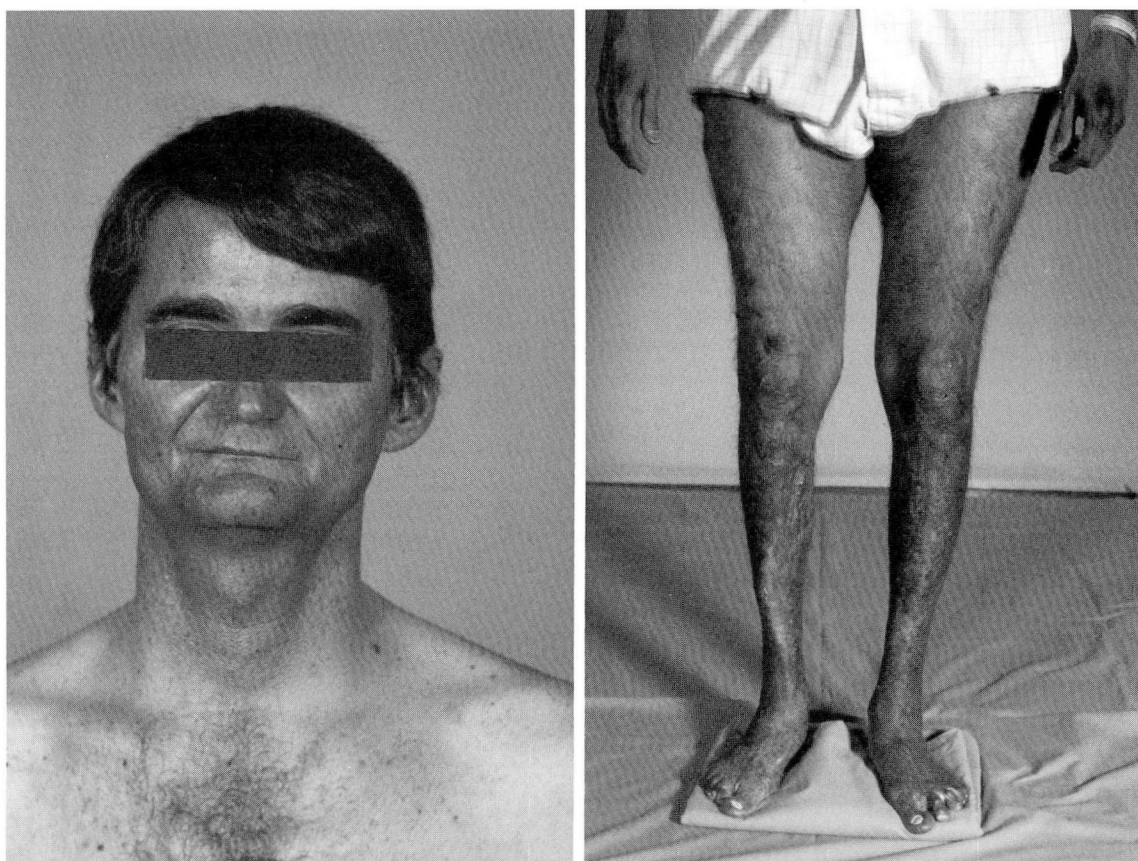
The patient was admitted for further evaluation. A Doppler study was negative for deep venous thrombosis of the legs. His bilirubin level was elevated to 3.3 mg/dL. Serum protein electrophoresis revealed a minimal polyclonal elevation of the gamma globulins. Ultrasound study of the liver and gallbladder was normal. A bone scan showed no defects. The ejection fraction was 26% on the right and 37% on the left (normal: right = 52-57%; left = 59-75%). An electrocardiogram showed low voltage and nonspecific ST segment changes (*Fig. 2*). Chest radiographs showed blunting of the left costophrenic angle. Echocardiography revealed no evidence of mitral prolapse. There was abnormal septal motion and mild dilation of the left atrium and the right ventricle. The study was technically difficult and ventricular wall thickening was not clearly demonstrated. Cardiac magnetic resonance imaging showed thickening of the right and left ventricular walls, enlarged papillary muscles, and dilated atria (*Fig. 3*). A diagnosis of cardiomyopathy was made; the

<sup>1</sup> Department of Cardiology, The Cleveland Clinic Foundation. Submitted for publication Nov 1985; accepted Feb 1986. ht

0009-8787/86/02/0205/07/\$2.75/0

Copyright © 1986, The Cleveland Clinic Foundation

A, B



**Fig. 1.** A. Photograph of patient showing typical facies of Ehlers-Danlos syndrome Type IV.  
B. Photograph of patient showing multiple ecchymoses and skin changes typical for Ehlers-Danlos Type IV (acrogeria).

patient was started on treatment with Lasix (furosemide), digoxin, nitrates, and compression stockings, and was then discharged.

Two months later he returned unimproved. Hydralazine 75 mg t.i.d. was added to his regimen. At that time an S3 beat was present. The patient underwent cardiac catheterization, which revealed a cardiac index of 1.6 L/min/m<sup>2</sup>, as calculated by the Fick method. The right atrial pressures were elevated and mean pressure was 19–20 mm Hg. The right ventricular pressure was 30/18 mm Hg. The pulmonary artery pressure was 29/18 mm Hg with a mean of 23 mm Hg. The mean wedge pressure was 18 mm Hg. A right ventricular endocardial biopsy revealed cardiac amyloidosis.

The patient has been followed up for one and one-half years and has been troubled with ascites and worsening renal function. He was treated briefly with colchicine but did not benefit from it.

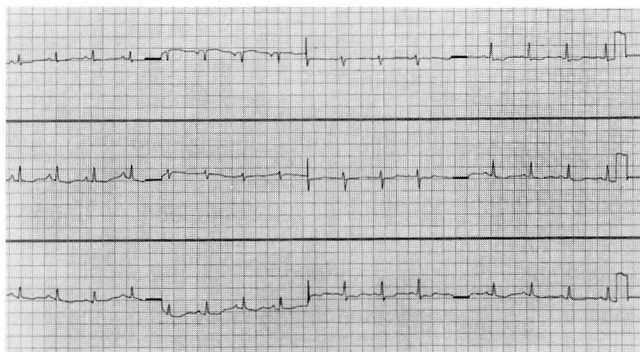
## Discussion

Ehlers-Danlos syndrome is the name applied to a group of genetic disorders of connective tissue that share certain clinical features. At present, at

least eight distinct types are recognized. Four other types, which may represent distinct syndromes, have been reported<sup>1-5</sup> (*Table*). It is recognized that as many as half of patients do not fit clearly into one category and are identified as having Ehlers-Danlos syndrome, type unclassified.<sup>1</sup> The features of Ehlers-Danlos syndrome are abnormalities of the skin, including hyperelasticity and fragility, hypermobility of the joints, abnormal scar formation, and easy bruising. Not all features are present in any one type and no single feature is shared by all types. Several of the types involve defective collagen synthesis and specific defects have been identified in some (*Table*).

Type IV, the ecchymotic type, is probably the most lethal of these disorders because of the tendency for spontaneous rupture of the gastrointestinal tract<sup>6</sup> and major blood vessels.<sup>7</sup> It is caused by abnormal synthesis of type III collagen,



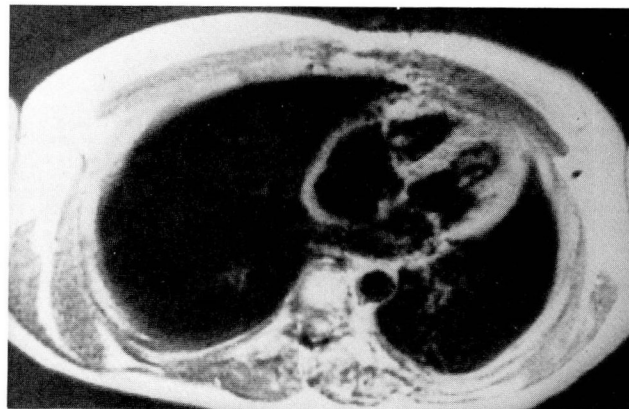


**Fig. 2.** Patient's electrocardiogram, demonstrating low voltage and nonspecific ST segment and T wave changes.

Leads: I avR V1V4  
II avL V2V5  
III avF V3V6

which is a major structural component of the skin, blood vessels, wall of the gastrointestinal tract, and uterus. Several different abnormalities of type III collagen production have been reported in Type IV Ehlers-Danlos syndrome, ranging from no synthesis<sup>8,9</sup> to normal synthesis but with impaired release.<sup>10</sup>

Clinically the disorder is characterized by severe bruising with minimal trauma. The skin is thin and translucent, and often extremely fragile. Wound healing and scar formation are usually normal. A typical facial appearance with a thin face and prominent eyes has been described,<sup>11-13</sup> and was seen in our patient (*Fig. 1*). Life expectancy is shortened because of the tendency to rupture of the gastrointestinal tract and of major blood vessels, both systemic<sup>7</sup> and pulmonary.<sup>14</sup> Other manifestations of weakened vascular walls, such as major artery aneurysms<sup>15</sup> and hematomas,<sup>16</sup> are also common. One patient with a coronary artery aneurysm has been reported.<sup>17</sup> Joints are usually not hyperextensible. The skin does not demonstrate unusual elasticity, as it does in some of the other types. Two patients with multiple pneumothoraces have been reported.<sup>18,19</sup> Mitral valve prolapse has been reported in one kindred with Type IV Ehlers-Danlos syndrome<sup>20</sup> and may be causally related. Type III collagen, which is present in the normal mitral valve, has been reported to be absent in a patient with mitral valve prolapse (without stigmata of Ehlers-Danlos syndrome).<sup>21</sup> Both an autosomal dominant<sup>22</sup> and an autosomal recessive<sup>11</sup>



**Fig. 3.** Magnetic resonance image demonstrating typical features of cardiac amyloidosis: a thickened, but not dilated, left ventricle with prominent papillary muscles and marked thickening of the right ventricular wall. Both atria are enlarged.

mode of inheritance have been reported. Pope et al<sup>12</sup> have proposed three and Byers et al<sup>22</sup> have proposed four distinct subtypes of Ehlers-Danlos syndrome Type IV based on inheritance, biochemical defect present, and ultrastructural findings.

This patient presented with a typical clinical picture of cardiac amyloidosis, which usually presents as congestive failure.<sup>23-26</sup> Peripheral edema and ascites are common,<sup>27</sup> as are pericardial effusions.<sup>28</sup> The typical electrocardiographic features of cardiac amyloidosis are low voltage, left axis deviation, and atrial fibrillation.<sup>23,24,27</sup> Of these, only low voltage was seen in this case. Typical echocardiographic features of cardiac amyloidosis include a thickened but not dilated left ventricle with abnormal contractility and a characteristic sparkling appearance to the thickened myocardium. Left atrial enlargement, as well as right atrial and right ventricular enlargement, can occur.<sup>28,29</sup> Our patient exhibited some but not all of these features. Catheterization demonstrated elevated left and right ventricular pressures and a low cardiac output, features consistent with cardiac amyloidosis.<sup>30</sup> Cardiac magnetic resonance imaging demonstrates characteristic, although probably not diagnostic, findings of thickened ventricles and papillary muscles without ventricular dilation.<sup>31</sup> All these findings were present in our patient (*Fig. 3*). The myocardial biopsy was diagnostic, showing the typical pattern of cardiac amyloid.

A number of cardiac abnormalities have been

Table. Types and clinical features of the Ehlers-Danlos syndromes

Type	Clinical features	Skin hypermobility	Joint hypermobility	Skin fragility	Bruising	Biochemical defect	Inheritance	Cardiac features
I (gravis)	1. marked skin hyperelasticity 2. defective scars 3. tissue fragility 4. joint hypermobility 5. bruising 6. fragile skin 7. molluscous pseudotumors	marked	marked	marked	marked	unknown	autosomal dominant	1. atrial septal defect (2-5%) <sup>1</sup> 2. mitral prolapse <sup>1</sup> 3. dilation of aortic root <sup>1</sup>
II (mitis)	same as I but milder	moderate	moderate	moderate	moderate	unknown	autosomal dominant	1. atrial septal defect <sup>1</sup> 2. mitral prolapse <sup>1</sup> 3. dilation of aortic root <sup>1</sup> mitral prolapse <sup>1</sup>
III (benign hypermobility)	1. joint hypermobility 2. mild cutaneous manifestations	variable	marked	minimal	minimal	unknown	autosomal dominant	
IV (ecchymotic)	1. thin skin 2. easy bruising 3. arterial & visceral rupture 4. hypermobility absent or limited to digits	minimal	limited to digits	marked	marked	abnormal Type III collagen synthesis	autosomal dominant & autosomal recessive types	mitral prolapse in 1 kindred <sup>18</sup>
V (X-linked)	1. hyperextensible skin 2. poor scar formation 3. minimal joint hypermobility	marked	minimal	moderate	moderate	? defective lysyl oxidase	X-linked	1. mitral prolapse <sup>1</sup> 2. atrial septal defect <sup>21</sup>

VI (ocular)	1. joint hypermobility & dislocations 2. ocular abnormalities (microcornea, global ruptures) 3. scoliosis	marked	marked	moderate	moderate	abnormal lysyl hydroxylase	autosomal recessive	1. mitral prolapse? <sup>1</sup> 2. aortic rupture? <sup>1</sup>
VII (arthroclasis multiplex congenita)	1. joint hypermobility & dislocations 2. short stature	minimal	marked	moderate	moderate	procollagen peptidase deficiency?	autosomal dominant?	none
VIII (periodontitis-associated)	1. extensive scarring 2. advanced periodontal disease	minimal	moderate	moderate	minimal	unknown	autosomal dominant	mitral prolapse? <sup>1</sup>
IX* (x-linked cutis laxa)	1. bladder diverticula 2. mild skin hyperextensibility 3. emphysema 4. occipital "horns"	mild	fingers only	—	—	defective collagen cross-linking due to decreased lysyl oxidase activity (abnormal cellular handling of copper)	X-linked	cor pulmonale <sup>2</sup>
X* (defective fibronectin)	1. moderate skin hypermobility 2. hypermobile small joints 3. abnormal platelet aggregation	moderate	small joints	—	—	defective fibronectin	probably autosomal recessive	1. dilated aortic root <sup>1,3</sup> 2. mitral prolapse <sup>1,3</sup>
XI* (Marfanoid hypermobility syndrome)	1. Marfanoid habitus 2. scoliosis 3. hypermobile joints	moderate	marked	minimal	minimal	unknown	—	mitral prolapse <sup>4</sup>
XII*	1. joint hypermobility 2. emphysema 3. seizures	minimal	marked	minimal	moderate	unknown	—	sinus of Valsalva aneurysms <sup>5</sup>

\* Not accepted by all authors.

reported in various types of Ehlers-Danlos syndrome. Unfortunately, many of these reports did not clearly distinguish the various types of Ehlers-Danlos syndrome. Abnormalities that have been reported include atrial septal defect,<sup>32-34</sup> ventricular septal defect,<sup>35</sup> dextrocardia,<sup>33</sup> valvular,<sup>35</sup> subvalvular,<sup>36</sup> and peripheral<sup>37</sup> pulmonic stenosis, pulmonic regurgitation,<sup>35</sup> tetralogy of Fallot,<sup>38</sup> partial atrioventricular canal,<sup>39</sup> aneurysms of the sinuses of Valsalva often associated with aortic insufficiency,<sup>5,35,40,41</sup> right-sided aortic arch,<sup>32</sup> calcific aortic stenosis,<sup>32,42</sup> papillary muscle dysfunction,<sup>33,43</sup> mitral<sup>20,35,44</sup> and combined mitral and tricuspid prolapse,<sup>35</sup> combined mitral and tricuspid regurgitation,<sup>45</sup> and conduction abnormalities (first-degree atrioventricular block,<sup>35,44</sup> third-degree atrioventricular block,<sup>32,46</sup> bundle branch block,<sup>32,33,42</sup> and bifascicular block<sup>47</sup>). Arteriovenous malformations have also been reported.<sup>48</sup> It is likely that many of these associations occur by chance. Those disorders in which the cardiovascular manifestation has been reported often enough to suggest more than a chance association are summarized in the *Table*. One case of successful coronary artery vein grafting has been reported.<sup>49</sup>

This is the first report, to our knowledge, of cardiac amyloidosis occurring in a patient with Ehlers-Danlos syndrome. Whether there is any relation between the two conditions or whether this was a chance occurrence is a matter for speculation. The accumulated material in this patient's heart was not thought to represent an accumulation of abnormal collagen nor a collagen precursor because it was extracellular. Cultured fibroblasts in one patient with Type IV Ehlers-Danlos syndrome have been shown to accumulate a collagen precursor,<sup>10,50</sup> but it was intracellular. Furthermore, the staining characteristics were typical for amyloid. Thus, we do not think that a biochemical defect of collagen synthesis was directly responsible for the amyloid deposition in this patient's heart. It is possible that chronic overproduction of a precursor of collagen or chronic stimulation of cells to produce a substance (type III collagen) that they are unable to produce may be linked to the production or deposition of amyloid. At present, the factors controlling the synthesis of collagen and amyloid are not well enough understood to allow more than speculation on this point.

The prognosis for patients with Ehlers-Danlos syndrome Type IV is not good; life expectancy

is half of normal.<sup>1</sup> The prognosis for cardiac amyloidosis is even worse; most patients die within two years.<sup>26</sup> No therapy is available for either disorder. Thus, the outlook for our patient appears grim.

Douglas S. Moodie, M.D.  
The Cleveland Clinic Foundation  
9500 Euclid Avenue  
Cleveland, OH 44106

## References

1. Pyeritz RE. Cardiovascular manifestations of heritable disorders of connective tissue Ehlers-Danlos syndromes. *Prog Med Genet* 1983; **5**:214-226.
2. Byers PH, Siegel RC, Holbrook KA, Narayanan AS, Bornstein P, Hall JG. X-linked cutis laxa: defective cross-link formation in collagen due to decreased lysyl oxidase activity. *N Engl J Med* 1980; **303**:61-65.
3. Arneson MA, Hammerschmidt DE, Furcht LT, King RA. A new form of Ehlers-Danlos syndrome: fibronectin corrects defective platelet function. *JAMA* 1980; **244**:144-147.
4. Walker BA, Beighton PH, Murdoch JL. The Marfanoid hypermobility syndrome. *Ann Int Med* 1969; **71**: 349-352.
5. Cupo LN, Pyeritz RE, Olson JL, McPhee SJ, Hutchins GM, McKusick VA. Ehlers-Danlos syndrome with abnormal collagen fibrils, sinus of Valsalva aneurysms, myocardial infarction, panacinar emphysema and cerebral heterotopias. *Am J Med* 1981; **71**:1051-1058.
6. Sykes EM. Colon perforation in Ehlers-Danlos syndrome: report of two cases and review of the literature. *Am J Surg* 1984; **147**:410-413.
7. Beighton P, Horan FT. Surgical aspects of the Ehlers-Danlos syndrome: a survey of 100 cases. *Br J Surg* 1969; **56**:255-259.
8. Pope FM, Martin GR, Lichtenstein JR, et al. Patients with Ehlers-Danlos syndrome Type IV lack Type III collagen. *Proc Natl Acad Sci USA* 1975; **72**:1314-1316.
9. Aumailley M, Krieg T, Dessau W, Müller PK, Timpl R, Bricaud H. Biochemical and immunological studies of fibroblasts derived from a patient with Ehlers-Danlos syndrome type IV. *Arch Dermatol Res* 1980; **269**:169-177.
10. Byers PH, Holbrook KA, Barsh GS, Smith LT, Bornstein P. Altered secretion of Type III procollagen in a form of Type IV Ehlers-Danlos syndrome: biochemical studies in cultured fibroblasts. *Lab Invest* 1981; **44**:336-341.
11. Pope FM, Martin GR, McKusick VA. Inheritance of Ehlers-Danlos type IV syndrome. *J Med Genet* 1977; **14**:200-204.
12. Pope FM, Jones PM, Wells RS, Lawrence D, Nicholls AC. EDS IV (acrogeria): new autosomal dominant and recessive types. *J R Soc Med* 1980; **73**:180-186.
13. Bazex A, Dupre A. "Acrogeria" (type Gottron); Place de "l'acrogeria" dans le cadre des atrophies cutanées congénitales. *Ann Dermatol et Syph* 1955; **82**:604-625.
14. Pearl W, Spicer M. Ehlers-Danlos syndrome. *South Med J* 1981; **74**:80-81.
15. Hunter GC, Malone JM, Moore WS, Misiorowski RL, Chvapil M. Vascular manifestations in patients with Ehlers-Danlos syndrome. *Arch Surg* 1982; **117**:495-498.



16. Nanfro JJ. Spontaneous rectus hematoma: occurrence in a patient with Ehlers-Danlos syndrome Type IV. *Arch Dermatol* 1982; **118**:695-696.
17. Imahori S, Bannerman RM, Graf CJ, Brennan JC. Ehlers-Danlos syndrome with multiple arterial lesions. *Am J Med* 1969; **47**:967-977.
18. Clark JG, Kuhn C III, Uitto J. Lung collagen in Type IV Ehlers-Danlos syndrome: ultrastructural and biochemical studies. *Am Rev Respir Dis* 1980; **122**:971-978.
19. Scully RE, Galdabini JJ, McNeely BU. Case records of the Massachusetts General Hospital, Case 3-1979. *N Engl J Med* 1979; **300**:129-135.
20. Jaffe AS, Geltman EM, Rodey GE, Uitto J. Mitral valve prolapse: a consistent manifestation of Type IV Ehlers-Danlos syndrome: the pathogenetic role of the abnormal production of Type III collagen. *Circulation* 1981; **64**:121-125.
21. Hammer D, Leier CV, Baba N, Vasko JS, Wooley CF. Altered collagen composition in a prolapsing mitral valve with ruptured chordae tendineae. *Am J Med* 1979; **67**:863-866.
22. Byers PH, Holbrook KA, McGillivray B, MacLeod PM, Lowry RB. Clinical and ultrastructural heterogeneity of type IV Ehlers-Danlos syndrome. *Hum Genet* 1979; **47**:141-150.
23. Farrokh A, Walsh TJ, Massie E. Amyloid heart disease. *Am J Cardiol* 1964; **13**:750-756.
24. Buja LM, Khoi NB, Roberts WC. Clinically significant amyloidosis: clinicopathologic findings in 15 patients. *Am J Cardiol* 1970; **26**:394-405.
25. Roberts WC, Waller BF. Cardiac amyloidosis causing cardiac dysfunction: analysis of 54 necropsy patients. *Am J Cardiol* 1983; **52**:137-146.
26. Brigden W. Cardiac amyloidosis. *Prog Cardiovasc Dis* 1964; **7**:142-150.
27. Bernreiter M. Cardiac amyloidosis: electrocardiographic findings. *Am J Cardiol* 1958; **1**:644-647.
28. Siqueira-Filho AG, Cunha CLP, Tajik AJ, Seward JB, Schatenberg TT, Giuliani ER. M-mode and two-dimensional echocardiographic features in cardiac amyloidosis. *Circulation* 1981; **63**:188-196.
29. Child JS, Levisman JA, Abbasi AS, MacAlpin RN. Echocardiographic manifestations of infiltrative cardiomyopathy: a report of seven cases due to amyloid. *Chest* 1976; **70**:726-731.
30. Chew C, Ziady GM, Raphael MJ, Oakley CM. The functional defect in amyloid heart disease: the "stiff heart" syndrome. *Am J Cardiol* 1975; **36**:438-444.
31. O'Donnell JK, Go RT, Bott-Silverman C, Feiglin DH, Salcedo E, MacIntyre WJ. Magnetic resonance imaging in cardiac amyloidosis. *J Nucl Med* 1984; **25**:P81-P82.
32. Beighton P. Cardiac abnormalities in the Ehlers-Danlos syndrome. *Br Heart J* 1969; **31**:227-232.
33. Antani J, Srinivas HV. Ehlers-Danlos syndrome and cardiovascular abnormalities. *Chest* 1973; **63**:214-217.
34. Scheinin TM, Dahl M. Repair of atrial septal defect in a patient with the Ehlers-Danlos syndrome. *Scan J Thorac Cardiovasc Surg* 1967; **1**:114-117.
35. Leier CV, Call TD, Fulkerson PK, Wooley CF. The spectrum of cardiac defects in the Ehlers-Danlos syndrome, Types I and III. *Ann Int Med* 1980; **92**:171-178.
36. Marquez J, Juffe A, Rutilanchas JJ, Maitre M, Artaza M. Successful correction of valvular and fibromuscular subpulmonary ring stenosis in a patient with Ehlers-Danlos syndrome. *J Cardiovasc Surg* 1978; **19**:271-275.
37. Lees MH, Menashe VD, Sunderland CO, Morgan CL, Dawson PJ. Ehlers-Danlos syndrome associated with multiple pulmonary artery stenoses and tortuous systemic arteries. *J Pediatr* 1969; **75**:1031-1036.
38. Wallach EA, Burkhart EF. Ehlers-Danlos syndrome associated with tetralogy of Fallot. *Arch Dermat Syph* 1950; **61**:750-752.
39. Fantl P, Morris KN, Sawers RJ. Repair of cardiac defect in a patient with Ehlers-Danlos syndrome and deficiency of Hageman factor. *Br Med J* 1961; **1**:1202-1204.
40. Tucker DH, Miller DE, Jacoby WJ. Ehlers-Danlos syndrome with a sinus of Valsalva aneurysm and aortic insufficiency simulating rheumatic heart disease. *Am J Med* 1963; **35**:715-720.
41. Simon AP, Stein PD. Aortic insufficiency in Ehlers-Danlos syndrome. *Angiology* 1974; **25**:290-296.
42. Edmondson P, Nellen M, Ross DN. Aortic valve replacement in a case of Ehlers-Danlos syndrome. *Br Heart J* 1979; **42**:103-105.
43. Antani JA, Srinivas HV, Shivashankar A. Clinical manifestations of papillary muscle dysfunction in Ehlers-Danlos syndrome. *Jap Heart J* 1975; **16**:235-242.
44. Brandt KD, Sumner RD, Ryan TJ, Cohen AS. Herniation of mitral leaflets in the Ehlers-Danlos syndrome. *Am J Cardiol* 1975; **36**:524-528.
45. Madison WM, Bradley EJ, Castillo AJ. Ehlers-Danlos syndrome with cardiac involvement. *Am J Cardiol* 1963; **11**:689-693.
46. Smithen CS, Brown KG, Sowton E. Congenital complete atrio-ventricular block in Ehlers-Danlos syndrome with the demonstration of the site of block by His bundle electrogram. *Guys Hosp Rep* 1971; **120**:355-364.
47. Cabeen WR, Reza MJ, Kovick RB, Stern MS. Mitral valve prolapse and conduction defects in Ehlers-Danlos syndrome. *Arch Int Med* 1977; **137**:1227-1231.
48. Lynch HT, Larsen AL, Wilson R, Magnuson CL. Ehlers-Danlos syndrome and "congenital" arteriovenous fistulae. *JAMA* 1965; **194**:1011-1014.
49. Redington A, McCue J, Lennox S. Coronary artery vein grafting in a case of Ehlers-Danlos syndrome. *Br Heart J* 1984; **52**:237-239.
50. Holbrook KA, Byers PH. Ultrastructural characteristics of the skin in a form of the Ehlers-Danlos syndrome Type IV: Storage in the rough endoplasmic reticulum. *Lab Invest* 1981; **44**:342-350.