

Radiology Features

William A. Chilcote, M.D.
James K. O'Donnell, M.D.
Section Editors

Radiologic evaluation of the asymptomatic carotid bruit¹

David M. Paushter, M.D.
Antoinette LaValley, M.D.
Scott A. Rosenbloom, M.D.

The authors compare the advantages and disadvantages of duplex sonography to arteriography and intravenous digital subtraction angiography for the evaluation of an asymptomatic carotid bruit. Overall, the use of duplex sonography is favored due to its lack of morbidity and competitive diagnostic accuracy.

Index terms: Angiography • Carotid artery diseases, diagnosis • Carotid artery, radiography • Radiology features • Subtraction technic

Cleve Clin Q 53:367-372, Winter 1986

A 49-year-old white man was admitted to the Cleveland Clinic for the evaluation of renovascular hypertension. The patient underwent a coronary artery bypass graft approximately two and a half years prior to admission. He had been followed on an outpatient basis and treated medically for refractory hypertension. Intravenous digital subtraction angiography (DSA) performed just prior to admission demonstrated bilateral renal artery stenosis.

On admission, the patient described symptoms of mild, bilateral lower extremity claudication, but was otherwise asymptomatic. The patient appeared cachectic, and blood pressure measurements were 170/98 upright and 160/80 supine. Cardiac examination revealed a grade II/VI systolic murmur. Abdominal, left femoral, and left subclavian bruits were noted, as well as a grade III/VI right carotid bruit.

¹ Department of Diagnostic Radiology, The Cleveland Clinic Foundation. Submitted for publication Jan 1986; accepted Apr 1986.

0009-8787/86/04/0367/06/\$2.50/0

Copyright © 1986, The Cleveland Clinic Foundation

Admission laboratory data were essentially within normal limits except for serum sodium (133 mEq/L), serum chloride (91 mEq/L), serum creatinine (2.6 mg/dL), and BUN (47 mg/dL). An aortogram with pelvic view demonstrated thrombus within the infrarenal abdominal aorta and marked stenosis at the origins of both main renal arteries. The celiac, superior mesenteric, and inferior mesenteric arteries were occluded at their origins with collateral circulation supplied by the left hypogastric artery. The patient also had a right common iliac artery occlusion and marked stenosis of the left common iliac artery.

Questions

Does the patient's asymptomatic carotid bruit require further evaluation preoperatively?

If so, which of the three commonly used radiologic imaging methods (duplex carotid sonography [DCS], intravenous DSA, or arteriography) would be most appropriate?

DCS was performed due to the asymptomatic carotid bruit (*Fig. 1*) and demonstrated marked, mixed plaque formation in the right carotid bulb, extending into the right internal carotid artery. Flow parameters suggested a 70%–90% stenosis. The Doppler frequency data also demonstrated a moderate right external carotid artery stenosis. Moderate to marked noncalcific plaque formation was present in the left carotid bulb, extending into the left internal carotid artery. Flow parameters suggested a 60%–80% stenosis. The left external carotid artery was not visualized.

Due to the sonographic findings, an intraarterial DSA was obtained (*Fig. 2*). This examination also demonstrated marked stenosis of the proximal right internal carotid artery with moderate irregularity and an ulcerated segment posteriorly. A mild to moderate right external carotid artery stenosis was present. On the left, moderate to marked

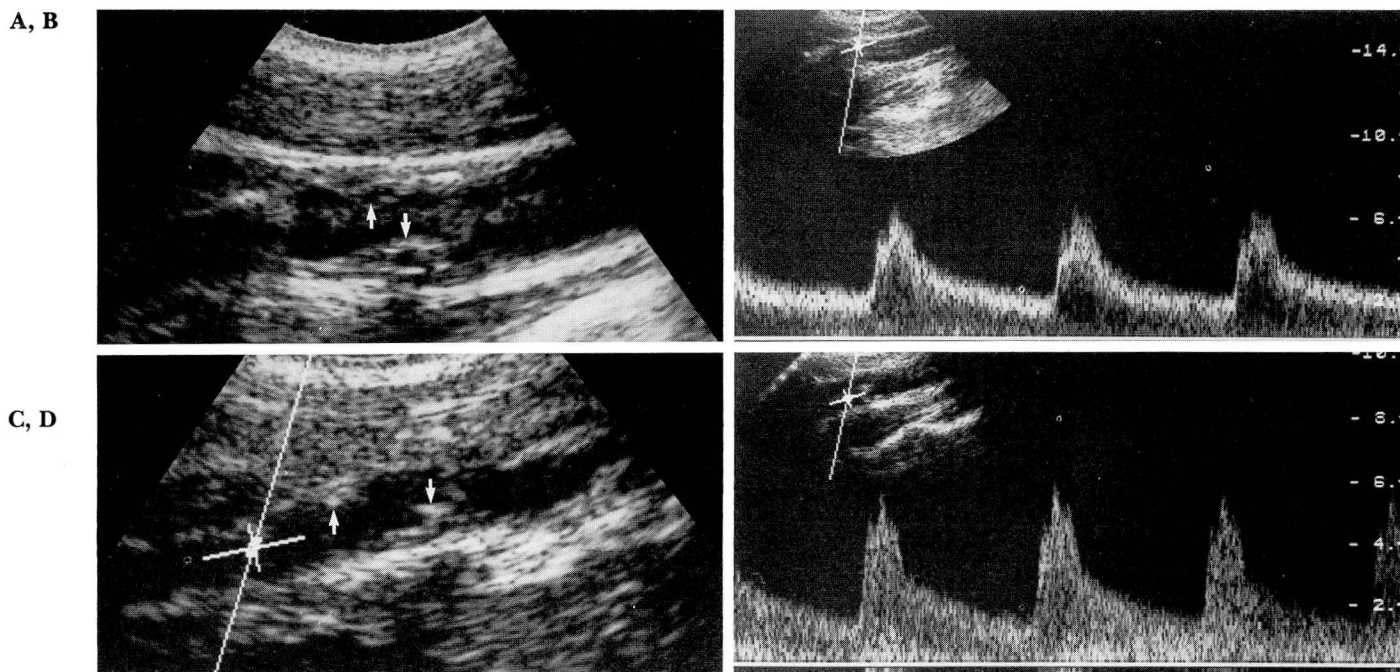


Fig. 1. Bilateral internal carotid artery stenosis shown by DCS.

- A. Real-time sonogram shows marked plaque formation (arrows) in the proximal right internal carotid artery.
 B. Spectral waveform demonstrates a peak frequency shift of 7 kHz in this region with associated turbulence, seen as a "filling in" of the window underneath the waveform.
 C. Real-time sonogram of the left internal carotid artery. Moderate to marked plaque formation is present (arrows).
 D. Left internal carotid artery spectral data demonstrate a peak frequency shift of 6 kHz and turbulence.

stenosis of the proximal left internal carotid artery with moderate irregularity was shown, and the left external carotid artery was occluded at its origin. Bilateral subclavian artery stenoses were also present.

Five days after admission, the patient underwent a left carotid endarterectomy with saphenous vein patch, left aorto-iliac and right aorto-femoral bypass grafts, bilateral renal revascularization, and aorto-superior mesenteric artery bypass graft.

Discussion

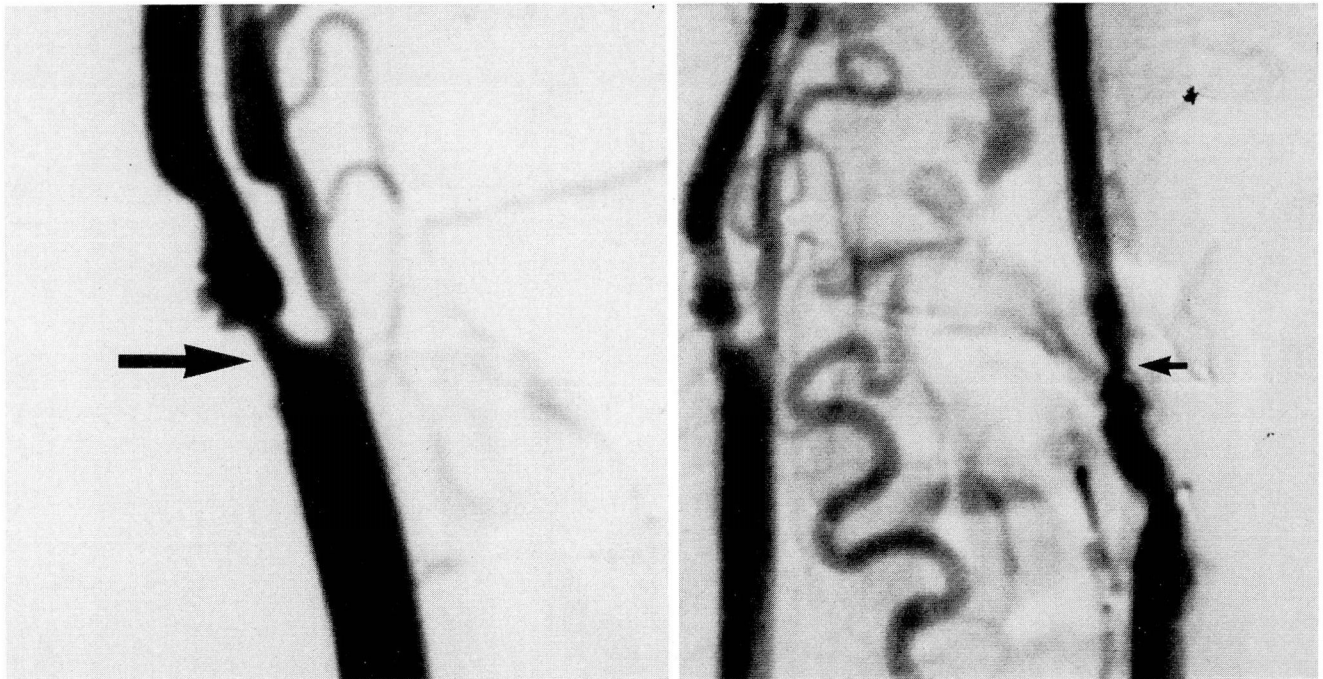
At the present time, there are a number of invasive and noninvasive studies available for the evaluation of carotid occlusive disease. This discussion will focus on the most frequently used imaging techniques: intravenous DSA, carotid arteriography (conventional and digital subtraction), and DCS.

Intravenous DSA allows vascular imaging following an intravenous administration of iodinated contrast material using computer-aided subtraction techniques of digitized information. This results in enhanced contrast resolution with less spatial resolution than conventional techniques. The primary advantage of this modality is its ability to visualize not only the carotid

bifurcation in a relatively high percentage of cases, but also the vertebral arteries, aortic arch, and intracranial vasculature in a lesser percentage. The information is also presented in a visual format similar to that of conventional arteriography.

When intravenous DSA quality is good or excellent, sensitivity and specificity for stenosis are greater than 90% when compared to conventional arteriography.^{1,2} High-quality studies are obtained in 60%–99% of patients^{1–3}; overall, approximately 10% of the studies are uninterpretable. Sensitivity and specificity drop substantially when interpretation of suboptimal images is attempted. This imaging technique also appears to be less sensitive for stenoses less than 50%.

Intravenous DSA is less hazardous and incurs a lower cost than conventional carotid arteriography. Also, the radiation dose to the patient during an examination is less. However, the incidence of adverse contrast-material reactions is approximately 5%.⁴ Severe reactions are uncommon, although renal failure induced by the contrast material has an incidence of approximately 2%,⁵ but is clinically significant in only 5% of



A, B

Fig. 2. Bilateral internal carotid artery stenosis shown by intraarterial DSA.

A. Marked stenosis of the proximal right internal carotid artery (arrow) and moderate stenosis of the right external carotid artery are apparent.

B. Arch injection corroborates the degree of left internal carotid artery narrowing demonstrated by DCS (arrow). The left external carotid artery is occluded at its origin.

these patients. Rare venous and right atrial perforations have also been reported.³

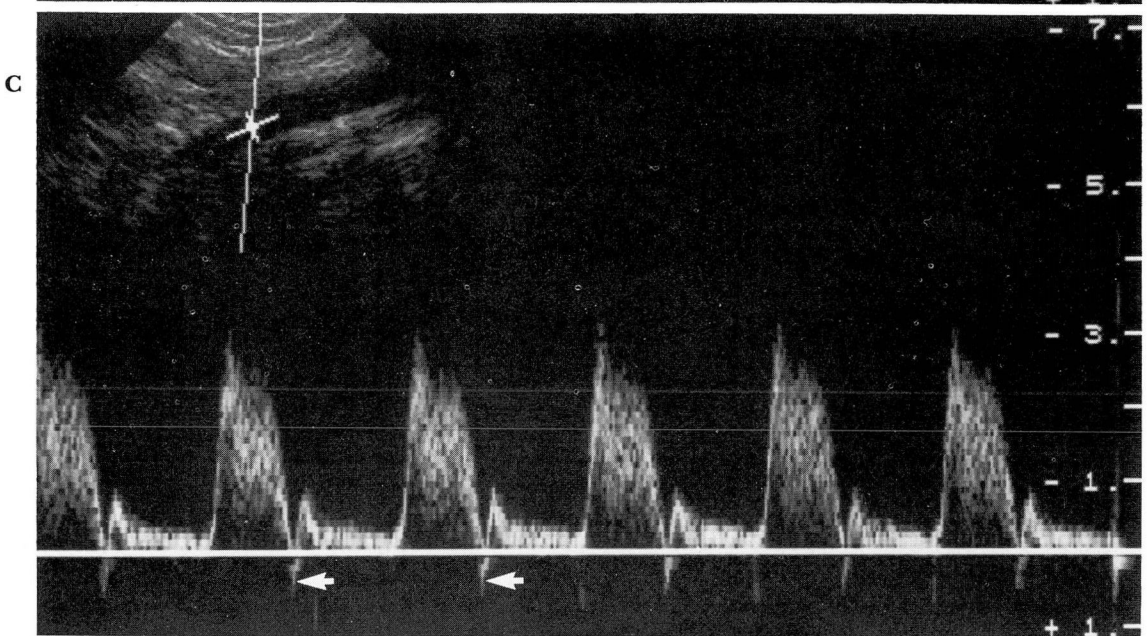
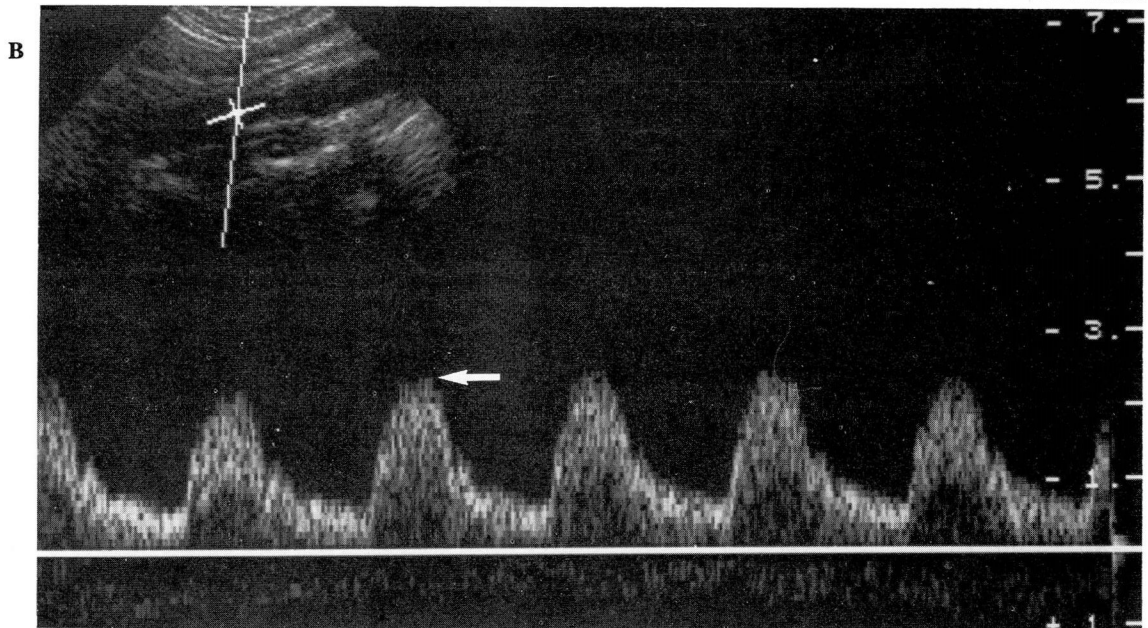
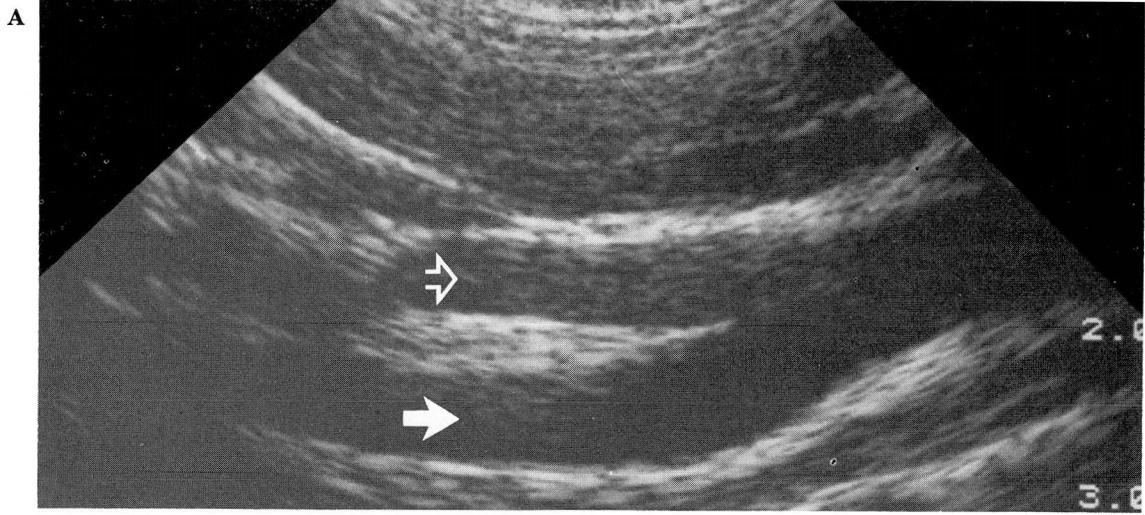
Technically, intravenous DSA has several distinct disadvantages, including poor image quality secondary to motion artifacts, vessel overlap, impaired cardiac output, and jugular venous reflux. Negative studies are often not reliable indicators of the absence of carotid arteriosclerotic disease and web stenoses, and ulcerations and thrombi may be difficult to visualize.⁶

Carotid arteriography remains the "gold standard" in the evaluation of carotid occlusive disease, although there is still significant intraobserver variation in the estimation of the severity of stenoses involving the carotid bifurcation. Although more accurate than intravenous DSA in the detection of ulcerated plaques, arteriography may overlook up to 40% of ulcerations when compared to autopsy data.⁷ Intraarterial DSA allows evaluation of the carotid system with less contrast material than conventional arteriography due to the improved contrast resolution. Although spatial resolution remains less than that obtained with conventional angiography, intraarterial DSA has the advantage of superior subtraction techniques and the ability to manipulate

the gray scale. Also, less iodinated contrast material is needed when compared with both conventional arteriography and intravenous DSA.

Although the complication rate of carotid arteriography far surpasses that of intravenous DSA, a large portion of this is due to local hematomas. In a recent study,⁸ neurologic complications occurred in 2.6% of patients, with an overall 0.33% incidence of permanent neurologic deficit which doubled for patients with symptomatic cerebrovascular disease. The incidence of contrast-material reactions is much lower than with intravenous injections (approximately 2%).

DCS represents a combined high-resolution, real-time ultrasound and pulsed Doppler examination of the carotid arteries. Real-time imaging allows assessment of plaque extent, location, and morphology, as well as accurate selection of the Doppler sample volume for frequency analysis. Doppler ultrasound is used for estimation of red blood cell (RBC) velocity within a vessel. The Doppler transducer produces an ultrasound beam of known frequency which is, in part, reflected back to the transducer by moving RBCs. This detected Doppler signal is frequency shifted



relative to the original beam, and the degree of frequency shift is related to the velocity of RBC flow.

In actuality, due to the pulsatile nature of blood flow, different Doppler-shifted frequencies are obtained during the cardiac cycle, and therefore, a peak frequency shift (PFS) in midsystole is used for measurements. Since flow can be equated to cross-sectional area \times velocity, and flow is held relatively constant until a vessel is markedly stenotic, Doppler-shifted frequencies allow estimation of cross-sectional area (percent stenosis). The PFS continues increasing until at least a 90% vessel diameter reduction is reached. Doppler ultrasound also allows estimation of turbulence associated with carotid occlusive disease by displaying the range of frequencies encountered (spectral broadening). We use a grading system for internal carotid artery stenosis based on the work of Jacobs et al⁹ who correlated PFS with percent vessel stenosis, although we attempt to subdivide their broad category of a 50%–90% stenosis. It has recently been suggested that the rate of maximum internal carotid artery velocity to common carotid artery velocity may be a sensitive indicator of luminal narrowing.¹⁰

DCS is able to differentiate the internal carotid artery from the external carotid artery by anatomic parameters, audible signals, and waveform analysis (Fig. 3). The internal carotid artery is usually larger and is posterior and lateral to the external carotid artery in 95% of cases. Also, the external carotid artery branches may be visualized with DCS, and distortion of the external carotid artery waveform may be obtained by tapping on the superficial temporal artery. The internal and external carotid artery waveforms are substantially different since the internal carotid artery feeds the relatively low-resistance vascular bed of the brain and the external carotid artery supplies a high-resistance muscular bed. Corresponding audible differences between the internal and external carotid artery are usually easily appreciated by the examiner.

DCS has proved to be highly accurate in the diagnosis of atherosclerotic disease with a sensi-

tivity of more than 90% for stenoses greater than 50% (commonly considered to be a hemodynamically significant lesion^{9,11,12}). Like intravenous DSA, DCS appears to be less accurate for stenoses less than 50%. The advantages of DCS when compared to intravenous DSA include a higher percentage of acceptable examinations, lack of morbidity or discomfort, less expense, and lack of radiation exposure. DCS does have disadvantages, primarily related to the highly operator-dependent nature of the examination. At least six months of experience with DCS is required to gain an acceptable level of expertise.⁹ In addition, the format of DCS is less amenable to interpretation by referring physicians. DCS allows examination of only the common carotid artery and the first 3 to 5 cm of the bifurcation vessels in most instances.

There are well-recognized interpretative pitfalls associated with DCS, but most of these difficulties can be avoided by the experienced examiner.^{9,13} The external carotid artery may be identified as the internal carotid artery, particularly with internal carotid artery occlusion, since collateral flow to the internal carotid artery circulation may "internalize" the external carotid artery waveform. DCS may not accurately distinguish between subtotal and total internal carotid artery occlusion, but this may, in part, be secondary to the high sensitivity of Doppler for minimal flow when compared to contrast studies. PFS may decrease due to a severe stenosis, but this is usually associated with marked plaque formation. Also with a severe internal carotid artery stenosis, there may be increased flow in the contralateral carotid system with elevation of waveforms above the baseline. Less frequent but usually obvious causes of inaccurate Doppler data include high flow states such as aortic stenosis, low flow states with severely impaired cardiac output, and arrhythmias resulting in variable PFS. Also, inaccurate Doppler data may be obtained from a tortuous or kinked vessel due to difficulties in positioning the sample volume.

DCS routinely visualizes small carotid plaques not identified by intravenous DSA or intraarte-

←
Fig. 3. Normal duplex carotid sonograms.

- A. Real-time study of the carotid bifurcation demonstrates normal internal (closed arrow) and external (open arrow) carotid arteries.
- B. Normal internal carotid artery spectral analysis shows a midsystolic peak frequency shift of 2.5 kHz (arrow) and characteristic gradual diastolic slope toward baseline with flow throughout diastole.
- C. Normal external carotid artery spectral analysis demonstrates a rapid systolic upstroke with a peak frequency shift of 3 kHz. A characteristic dicotic notch (arrows) at end systole indicates flow reversal, with return to baseline during diastole.

rial techniques. Recently, there has been much interest in the ultrasound evaluation of plaque morphology. Presently, the future role of DCS in this area is uncertain since the technique is relatively insensitive to plaque ulceration.¹⁴

The decision whether or not to evaluate an asymptomatic carotid bruit is a subject of considerable debate. Past studies^{15,16} have documented high stroke rates in patients with asymptomatic bruits, but a substantial percentage of strokes were nonischemic, embolic, or not related to the side of the bruit. Therefore, arteriography and selective endarterectomy with their associated morbidity may not be warranted as has been previously suggested.¹⁷ Recent articles^{18,19} have proposed DCS as an excellent noninvasive method for evaluating an asymptomatic carotid bruit. Despite high rates of disease progression in patients with a carotid bruit continually evaluated by DCS, Roederer et al¹⁹ have suggested that endarterectomy can be delayed until symptoms occur or stenosis progresses to greater than 89%. Therefore, DCS is recommended for initial screening and follow-up of the patient with an asymptomatic carotid bruit. If the study is suboptimal, intravenous DSA can be performed. If significant disease is demonstrated by DCS or the patient becomes symptomatic, carotid arteriography may be warranted.

Similarly, recent data have revealed that the asymptomatic carotid bruit may not be a significant risk factor for perioperative stroke in patients undergoing major cardiovascular procedures. However, the preoperative screening of such patients with noninvasive tests has been advocated to permit follow-up in the late postoperative period.²⁰ This subject remains highly controversial, and further prospective studies are needed.

References

- Chilcote WA, Modic MT, Pavlicek WA, et al. Digital subtraction angiography of the carotid arteries: a comparative study in 100 patients. *Radiology* 1981; **139**:287-295.
- Wood GW, Lukin RR, Tomsick TA, Chamers AA. Digital subtraction angiography with intravenous injection: assessment of 1,000 carotid bifurcations. *AJR* 1983; **140**:855-859.
- Furlan AJ, Weinstein MA, Little JR, Modic MT. Digital subtraction angiography in the evaluation of cerebrovascular disease. *Neurol Clin North Am* 1983; **1**:55-72.
- Shehadi WH, Toniolo G. Adverse reactions to contrast media: a report from the Committee on Safety of Contrast Media of the International Society of Radiology. *Radiology* 1980; **137**:299-302.
- D'Elia JA, Gleason RE, Alday M, et al. Nephrotoxicity from angiographic contrast material: a prospective study. *Am J Med* 1982; **72**:719-725.
- Turski PA, Zwiebel WJ, Strother CM, Crummy AB, Celesia GG, Sackett JF. Limitations of intravenous digital subtraction angiography. *AJNR* 1983; **4**:271-273.
- Edwards JH, Kricheff II, Riles T, Imparato A. Angiographically undetected ulceration of the carotid bifurcation as a cause of embolic stroke. *Radiology* 1979; **132**:369-373.
- Earnest F IV, Forbes G, Sandok BA, et al. Complications of cerebral angiography: prospective assessment of risk. *AJR* 1984; **142**:247-253.
- Jacobs NM, Grant EG, Schellinger D, Byrd MC, Richardson JD, Cohan SL. Duplex carotid sonography: criteria for stenosis, accuracy, and pitfalls. *Radiology* 1985; **154**:385-391.
- Garth KE, Carroll BA, Sommer FG, Oppenheimer DA. Duplex ultrasound scanning of the carotid arteries with velocity spectrum analysis. *Radiology* 1983; **147**:823-827.
- Blasberg DJ. Duplex sonography for carotid artery disease: an accurate technique. *AJNR* 1981; **3**:609-614.
- Wetzner SM, Kiser LC, Bezreh JS. Duplex ultrasound imaging: vascular applications. *Radiology* 1984; **150**:507-514.
- Jackson VP, Kuehn DS, Bendick PJ, Becker GJ, Holden RW, Dilley RS. Duplex carotid sonography: correlation with digital subtraction angiography and conventional angiography. *J Ultrasound Med* 1985; **4**:239-249.
- Zwiebel WJ, Austin CW, Sackett JF, Strother CM. Correlation of high-resolution, B-mode and continuous-wave Doppler sonography with arteriography in the diagnosis of carotid stenosis. *Radiology* 1983; **149**:523-532.
- Wolf PA, Kannel WB, Sorlie P, McNamara P. Asymptomatic carotid bruit and risk of stroke: the Framingham study. *JAMA* 1981; **245**:1442-1445.
- Heyman A, Wilkinson WE, Heyden S, et al. Risk of stroke in asymptomatic persons with cervical arterial bruits: a population study in Evans County, Georgia. *N Engl J Med* 1980; **302**:838-841.
- Thompson JE, Patman RD, Talkington CM. Asymptomatic carotid bruit: long-term outcome of patients having endarterectomy compared with unoperated controls. *Ann Surg* 1978; **188**:308-316.
- Jackson VP, Bendick PJ. Duplex ultrasound screening for carotid arteriosclerotic disease in asymptomatic patients. *J Ultrasound Med* 1985; **4**:411-415.
- Roederer GO, Langlois YE, Jager KA, et al. The natural history of carotid arterial disease in asymptomatic patients with cervical bruits. *Stroke* 1984; **15**:605-613.
- Barnes RW. Asymptomatic carotid disease in preoperative patients: perioperative and late stroke risk. [In] Bernstein EF, ed. *Noninvasive Diagnostic Techniques in Vascular Disease*. St. Louis, CV Mosby, 1985, pp 474-478.

David M. Paushter, M.D.
 Department of Diagnostic Radiology
 The Cleveland Clinic Foundation
 9500 Euclid Ave.
 Cleveland, OH 44106