

Cutaneous blastomycosis

Report of a case presumably acquired by direct inoculation and treated with carbon dioxide laser vaporization¹

Gary R. Kantor, M.D.
Randall K. Roenigk, M.D.
Philip L. Bailin, M.D.
Wilma F. Bergfeld, M.D., F.A.C.P.
Jonathan Bass, M.D.

A patient who worked as a landscaper had a solitary lesion of cutaneous blastomycosis on the foot at a site of abrasion from the bark of a tree shrub. The authors postulate that the patient's disease was caused by direct inoculation. The lesion was vaporized with the carbon dioxide laser after initiating systemic ketoconazole therapy.

Index terms: Blastomycosis • Case reports

Cleve Clin J Med 54:121-124, March/April 1987

Blastomycosis is usually a primary pulmonary infection, but may disseminate to skin, bone, the central nervous system, and prostate.¹⁻⁴ The face and extremities are particularly common sites of disseminated infection since the causative fungus, *Blastomyces dermatitidis*, is dermatropic.⁵ Consequently, the dermatologist is frequently consulted for diagnosis. Characteristically, ulcerated,

inflamed, verrucous papules, plaques, or nodules are seen with focal abscess formation at the periphery. Small "black dots" resulting from thrombosis of dermal capillaries may be found within the lesion.⁶ As the nodules expand, scarring develops centrally.

In contrast, primary inoculation cutaneous blastomycosis is rare; only 12 cases have been reported in the literature.⁷⁻¹¹ Nine cases resulted from accidental inoculation during laboratory or pathology work, and three cases resulted from dog bites. These lesions have been described as chancreiform and associated with variable lymphangitis or lymphadenitis.⁷⁻⁹ We wish to report a patient that presented with a verrucous tumor on the foot that was diagnosed as blastomycosis and is presumed to have been acquired by direct inoculation.

Case report

A 34-year-old white man presented with a 10-month history of a slightly tender verrucous tumor on the right medial foot that had slowly enlarged without healing. The patient worked as a landscaper and reported traumatizing the affected area with a piece of bark while planting a tree shrub. Prior treatment with topical antibiotics was unsuccessful. The physical examination revealed a 2.5 × 3.0-cm indurated, verrucous, crusted plaque with pustules and

¹ Departments of Dermatology (G.R.K., P.L.B.) and Pathology (W.F.B., J.B.), The Cleveland Clinic Foundation, and the Department of Pathology (R.K.R.), Mayo Clinic, Rochester, Minn. Submitted for publication Aug 1986; accepted Oct 1986.

0891-1150/87/02/0121/04/\$2.00/0

Copyright © 1987, The Cleveland Clinic Foundation

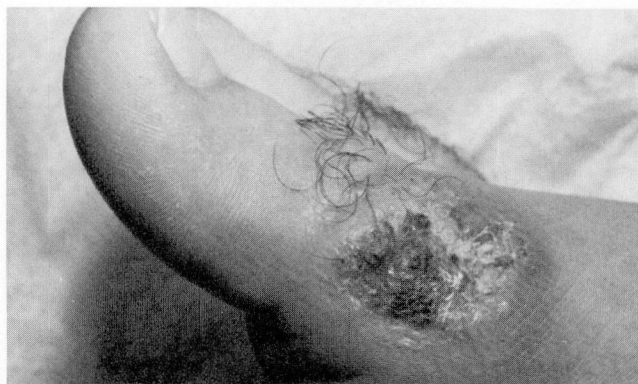

Fig. 1. Large verrucous, fissured nodule with focal vascular thromboses on the right dorsomedial metatarsal head.

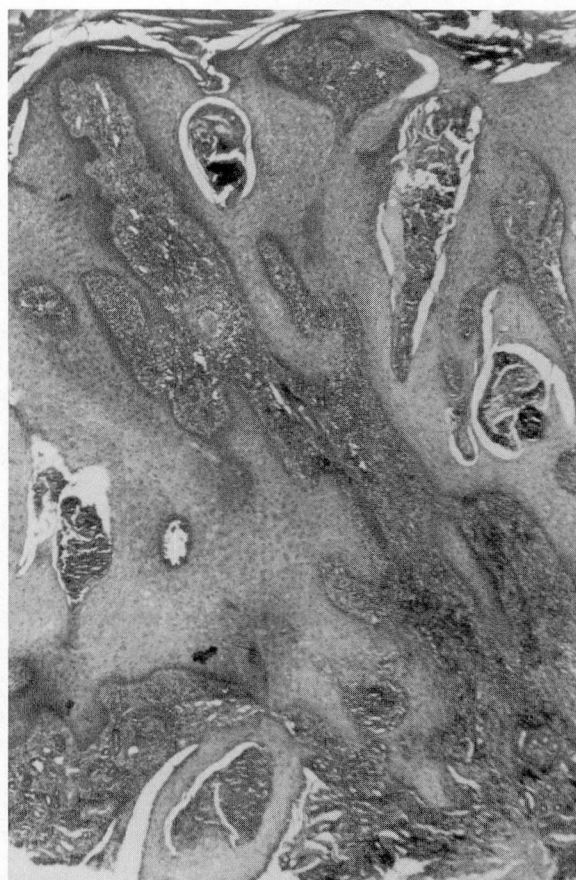

Fig. 2. Marked pseudoepitheliomatous hyperplasia of the epidermis and focal intraepidermal abscess formation. A dense chronic inflammatory infiltrate is present in the dermis (hematoxylin-eosin, original magnification $\times 40$).

black dots on the right dorsomedial aspect of the first metatarsal head (Fig. 1). There was no regional lymphadenitis or lymphadenopathy, and the lung fields were clear

to auscultation and percussion. The remainder of the physical examination was normal.

Results of skin biopsy showed marked pseudoepitheliomatous hyperplasia of the epidermis and intraepidermal neutrophilic abscess formation (Fig. 2). A dense dermal infiltrate consisting of lymphocytes, histiocytes, and few giant cells was present. Several thick-walled, budding spores measuring $10\ \mu$ in diameter and showing retraction of protoplasm from their walls were seen within the intraepidermal abscesses (Fig. 3).

A fungal culture from a biopsy specimen grew *Blastomyces dermatitidis* in 10 days. Complement fixation was negative for blastomycosis, but immunodiffusion detected one positive band to *Blastomyces* antigen. Serologic findings were negative for histoplasmosis, coccidioidomycosis, and aspergillosis. A complete blood count, automated serum chemistry profile, and radiographs of the right foot and chest were normal.

A diagnosis of cutaneous blastomycosis was made. Orally administered ketoconazole (200 mg, twice daily) was begun and, one week later, the tumor was debulked for symptomatic relief with carbon dioxide laser, vaporizing in the defocused mode at 6–10 W with a continuous 2.0-mm spot-sized beam. Clinically normal tissue margins were obtained in five passes. Postoperative wound care consisted of twice daily cleansing with 3% hydrogen peroxide and the application of a thin film of Polysporin ointment. One week postoperatively, there was no evidence of secondary infection and healthy granulation tissue was present at the base (Fig. 4). Ketoconazole therapy was continued for three months. At two months postoperatively, there was complete reepithelialization of the wound and no evidence of persisting infection (Fig. 5). The patient had no clinical or laboratory evidence of ketoconazole toxicity.

Discussion

Gilchrist et al identified the causative agent of blastomycosis in 1894 and Montgomery et al first described the systemic form in 1908.⁴ Evans reported primary inoculation cutaneous blastomycosis from a laboratory accident in 1903.¹¹ In 1955, Scott first reported the development of cutaneous blastomycosis after a dog bite.¹² Subsequently, *Blastomyces dermatitidis* was isolated from the soil.¹³

Primary inoculation cutaneous blastomycosis is rare and an occupational hazard to pathologists and laboratory personnel.⁹ In rare instances, this disease may develop after a dog bite.¹⁰ In all cases, lesions develop on the hands with a chancre at the inoculation site and occasional lymphadenopathy, referred to as the chancriform syndrome.⁸ However, cutaneous lesions typical of systemic blastomycosis may be seen,⁹ as in the patient reported here. Rarely, erythema nodosum may accompany primary inoculation blastomycosis.¹⁰

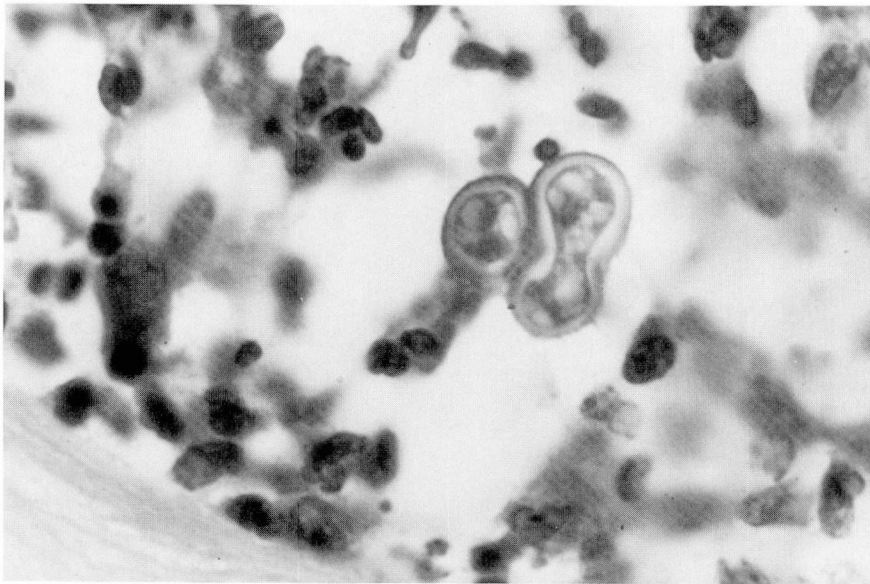


Fig. 3. Thick-walled, budding yeast cells are surrounded by acute and chronic inflammatory cells (hematoxylin-eosin, original magnification $\times 1,000$).

We believe our case to be unique because infection was associated with trauma from the bark of a tree shrub. Since *Blastomyces dermatitidis* has been isolated from the soil and the greatest number of cases of blastomycosis occur in the Mississippi, Missouri, and Ohio River basins,² the latter in which the patient resided and worked, we believe the infection resulted from inoculation. The patient had no evidence of systemic blastomycosis. Excluding inoculation from a dog bite, he would thus represent the first case of nonlaboratory-acquired inoculation blastomycosis. This may be a more common diagnosis than the literature indicates since patients may not seek medical assistance if the lesion heals spontaneously without treatment.⁹

The differential diagnosis includes primary tumors such as keratoacanthoma, squamous cell carcinoma, verrucous carcinoma, and verruca vulgaris. Infectious possibilities include sporotrichosis, leishmaniasis, coccidioidomycosis, chromoblastomycosis, mycobacterial infections, nocardiosis, tularemia, cat-scratch disease, syphilis, and blastomycosis-like pyoderma¹⁴ (Table).

Because of the small number of cases reported, there is no uniform therapy for primary inoculation blastomycosis. Previously reported treatment has included surgical excision or local debridement, soaks, potassium iodide, amphotericin B, or radiation treatment.⁹ The first reported

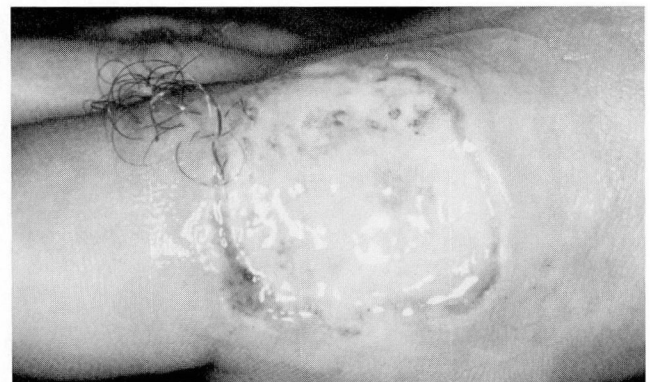

Fig. 4. One week postoperatively, the wound is healing with healthy granulation tissue and no evidence of secondary infection.

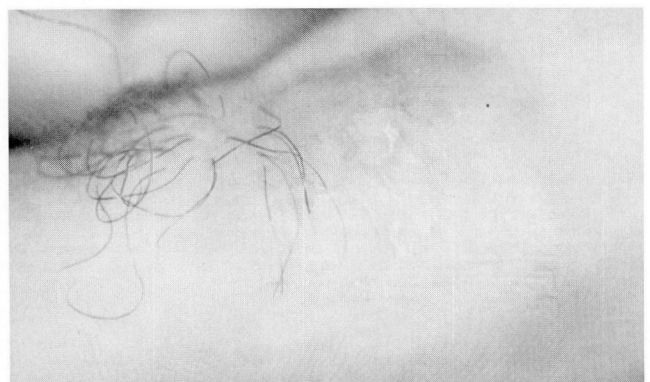


Fig. 5. Two months postoperatively, there is no evidence of persisting infection. A minimally erythematous scar is present.

Table. Differential diagnoses of primary inoculation cutaneous blastomycosis

Tumors
Keratoacanthoma
Squamous-cell carcinoma
Verrucous carcinoma
Verruca vulgaris
Inoculation infections
Sporotrichosis
Leishmaniasis
Coccidioidomycosis
Chromoblastomycosis
Mycobacterial infections
Tuberculosis
Atypical mycobacteria
Leprosy
Nocardiosis
Tularemia
Cat-scratch disease
Syphilis
Blastomycosis-like pyoderma

case was treated by amputation of the affected finger.¹¹ We elected to debride the lesion using carbon dioxide laser. Other surgical procedures were considered; however, the unique properties of carbon dioxide laser for sealing small blood vessels and lymphatics decreased the likelihood of disseminating infection. In addition, perioperative bleeding and postoperative swelling and pain were minimal—the latter effect due to this laser's ability to “weld” small nerve endings.

Ketoconazole is a recent addition to the clinician's armamentarium for treating blastomycosis.^{15,16} It is an orally administered imidazole without the renal and hematologic toxicity of amphotericin B.¹⁵ The main adverse effects of ketoconazole therapy include nausea, vomiting, hepatocellular dysfunction, gynecomastia, endocrine dysfunction, and anaphylactoid reactions.^{15,16} Ketoconazole is effective in non-life-threatening systemic blastomycosis at a dosage of 400 mg/day for six months.¹ We elected to use ketoconazole in our patient because of its proved effectiveness and low incidence of toxicity. Our patient has had no evidence of recurrent disease.

References

- Riegler HF, Goldstein LA, Betts RF. Blastomycosis osteomyelitis. *Clin Orthop* 1974; **100**:225–231.
- Logsdon MT, Jones HE. North American blastomycosis: a review. *Cutis* 1979; **24**:524–535.
- Varkey B, Lohaus G, Rose HD, Sohnle PG. Blastomycosis: clinical and immunologic aspects. *Chest* 1980; **77**:789–795.
- Tenenbaum MJ, Greenspan J, Kerkering TM. Blastomycosis. *CRC Crit Rev Microbiol* 1982; **9**:139–163.
- Duttera MJ Jr, Osterhout S. North American blastomycosis: a survey of 63 cases. *South Med J* 1969; **62**:295–301.
- Bongiorno FJ, Leavell UW, Wirtschafter JD. The black dot sign and North American cutaneous blastomycosis. *Am J Ophthalmol* 1974; **78**:145–147.
- Landay ME, Schwarz J. Primary cutaneous blastomycosis. *Arch Dermatol* 1971; **104**:408–411.
- Larsh HW, Schwarz J. Accidental inoculation blastomycosis. *Cutis* 1977; **19**:334–335, 337.
- Larson DM, Eckman MR, Alber RL, Goldschmidt VG. Primary cutaneous (inoculation) blastomycosis: an occupational hazard to pathologists. *Am J Clin Pathol* 1983; **79**:253–255.
- Gnann JW Jr, Bressler GS, Bodet CA III, Avent CK. Human blastomycosis after a dog bite (brief report). *Ann Intern Med* 1983; **98**:48–49.
- Evans N. A clinical report of a case of blastomycosis of the skin from accidental inoculation. *JAMA* 1903; **40**:1772–1775.
- Scott MJ. Cutaneous blastomycosis. *Northw Med* 1955; **54**:255–257.
- Klein BS, Vergeront JM, Weeks RJ, et al. Isolation of *Blastomyces dermatitidis* in soil associated with a large outbreak of blastomycosis in Wisconsin. *N Engl J Med* 1986; **314**:529–534.
- Su WPD, Duncan SC, Perry HO. Blastomycosis-like pyoderma. *Arch Dermatol* 1979; **115**:170–173.
- Heel RC, Brogden RN, Carmine A, Morley PA, Speight TM, Avery GS. Ketoconazole: a review of its therapeutic efficacy in superficial and systemic fungal infections. *Drugs* 1982; **23**:1–36.
- Stamm AM, Dismukes WE. Current therapy of pulmonary and disseminated fungal diseases. *Chest* 1983; **83**:911–917.
- National Institute of Allergy and Infectious Diseases Mycoses Study Group. Treatment of blastomycosis and histoplasmosis with ketoconazole: results of a prospective randomized clinical trial. *Ann Intern Med* 1985; **103**:861–872.

Philip L. Bailin, M.D.
 Department of Dermatology
 The Cleveland Clinic Foundation
 9500 Euclid Av.
 Cleveland, OH 44106