

Coronary artery spasm following percutaneous transluminal coronary angioplasty¹

G. Stefan Davis, M.D.
Jay Hollman, M.D., F.A.C.C.

This report demonstrates symptomatic coronary artery spasm at a site different from that of the previous percutaneous transluminal coronary angioplasty.

Index terms: Arteries, transluminal angioplasty • Case reports • Spasm

Cleve Clin J Med 54:207-209, May/June 1987

Coronary artery spasm following percutaneous transluminal coronary angioplasty (PTCA) has only been documented at or adjacent to the site of previous PTCA.^{1,2} Spasm is thought to be responsible for symptoms following PTCA when fixed lesions are not found.³ The chronology of a patient's symptoms, however, may suggest that the spasm is not at or next to the initial PTCA site.

Case report

A 56-year-old man with a history of smoking, hypertension, and a mild increase in cholesterol level, awoke with chest tightness radiating to the left arm. A myocardial infarction was ruled out, but the patient had recurrent episodes of angina while hospitalized. A cardiac catheterization revealed a dominant circumflex artery with a 90% obstruction in the high lateral circumflex branch and a 60% obstruction of the middle atrioventricular-groove circumflex vessel (*Fig. 1A*). The patient was referred for PTCA.

¹ Department of Cardiology, The Cleveland Clinic Foundation. Submitted for publication July 1986; accepted Dec 1986.

0891-1150/87/03/0207/03/\$1.75/0

Copyright © 1987, The Cleveland Clinic Foundation

On admission to this hospital, the patient's resting electrocardiogram was normal. The patient was given verapamil (80 mg), aspirin (650 mg), and dipyridamole (50 mg). The patient then underwent PTCA of both lesions of the circumflex system without complication (*Fig. 1B*) and was discharged. He was to continue taking verapamil (80 mg, four times daily), aspirin (650 mg, twice daily), and dipyridamole (50 mg, four times daily).

Six weeks later, the patient returned for a treadmill examination. He had been asymptomatic since the PTCA, but the treadmill test showed a 1-mm downsloping ST-T wave segment in leads II, III, aV_F, V₅, and V₆ after seven minutes using the Bruce protocol. This abnormal test prompted a re-cardiac catheterization at which time a 60% lesion of the middle atrioventricular groove circumflex vessel at the site of the original stenosis was found. During the same catheterization, the patient underwent repeat PTCA of this lesion. Good results were obtained. The patient was discharged and was to take the same medications (verapamil, aspirin, dipyridamole, and nitroglycerin as needed).

For four months following the second PTCA, the patient remained asymptomatic, with no limitations of his activity. Over the next few months, however, the patient noticed a return of his substernal chest discomfort, usually occurring at rest in the mornings soon after he arose from sleep. The chest discomfort lasted between five and 15 minutes, never requiring more than one nitroglycerin tablet for relief. The patient denied any chest pain with exertion.

Because of the recurrent anginal symptoms, the patient underwent his third cardiac catheterization without any premedication. A 30% narrowing at the site of the high circumflex branch and a 10%-20% narrowing of the middle circumflex vessel at the site of the second PTCA were noted (*Fig. 2A*). Ergonovine was administered (0.5, 0.1, and 0.2 mg dosages at three-minute intervals), while limb leads of the electrocardiogram were monitored. The patient's substernal chest pain was reproduced after the third ergonovine dose, which was associated with a 1-mm ST-T depression in lead I. Selective coronary angiography was then repeated and the image showed no change. The patient was given

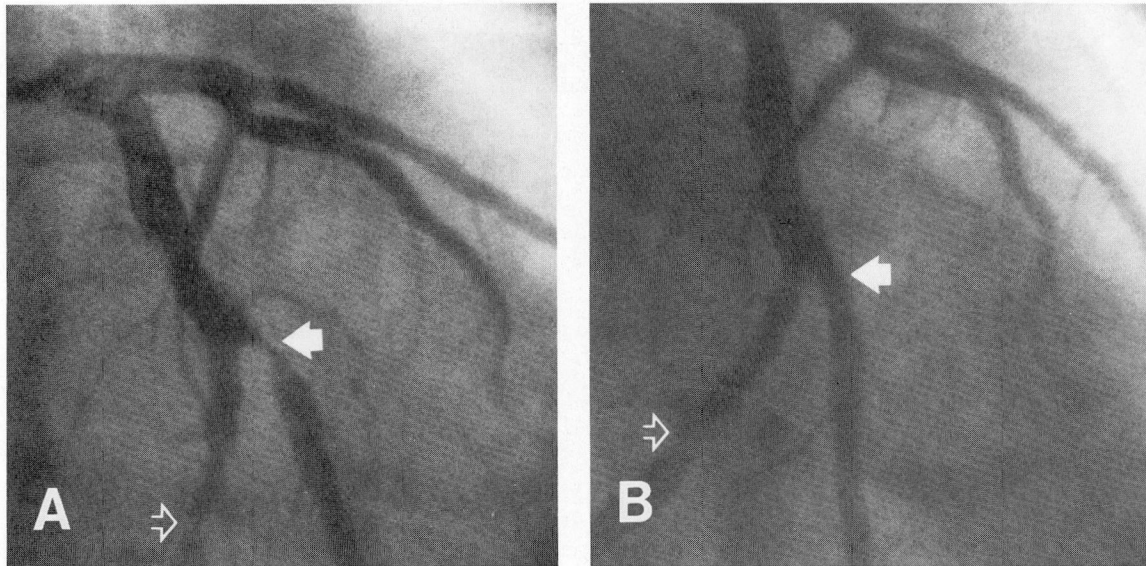


Fig. 1. Left coronary artery (right anterior oblique projection).
A. Before PTCA.
B. After PTCA. Both lateral circumflex branches, as well as the middle atrioventricular-groove circumflex vessel, are shown.
 The solid arrow indicates the origin of the lateral circumflex artery. The hollow arrow points to the middle atrioventricular-groove circumflex vessel.

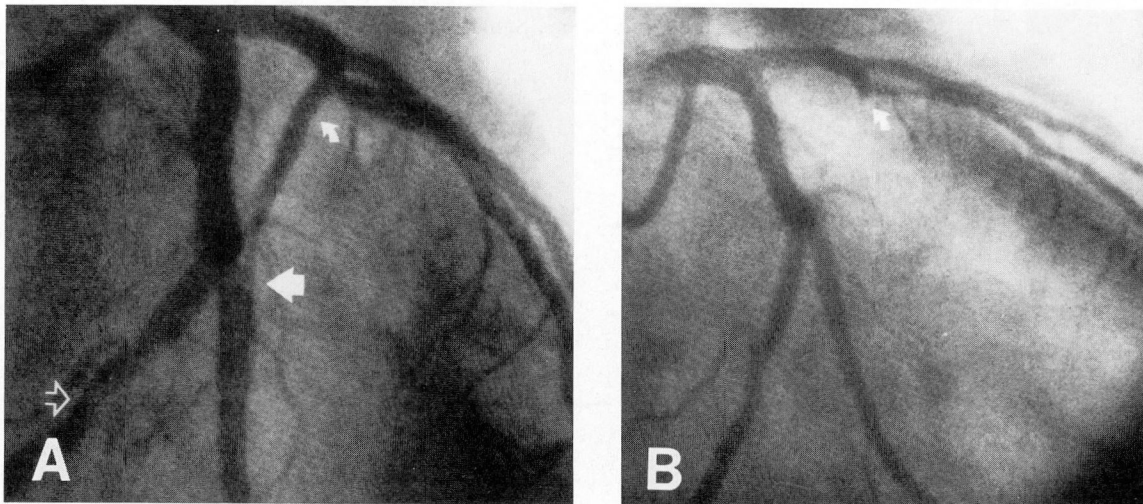
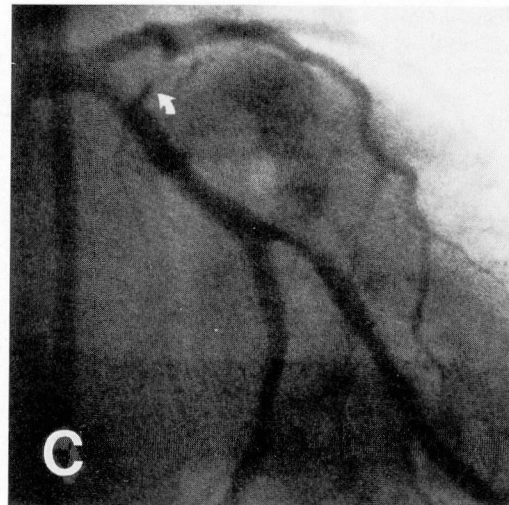


Fig. 2. Left coronary artery (right anterior oblique projection).
A. Baseline. No medication was given. The large solid arrow points to the site of previous PTCA of the lateral circumflex branch. The large hollow arrow points to the site of previous PTCA of the middle atrioventricular-groove circumflex vessel.
B. After administration of ergonovine, occlusion of the large septal perforator is shown.
C. As the angina pain begins to subside, the initial phase of reperfusion of the large septal perforator is visualized. The small solid curved arrow points to the first septal perforator.



nitroglycerin (0.4 mg sublingually) and within 10 minutes the chest pain had completely resolved and the electrocardiogram had reverted to baseline. Upon review of the angiograms after the film had been developed, 100% blockage of a large septal perforator originating from the left anterior descending artery was noted after the ergonovine challenge (*Fig. 2B*). This vessel had begun to reappear on the angiograms obtained when the chest pain had begun to resolve (*Fig. 2C*). The patient was discharged. He continued to take nifedipine (10 mg, four times daily) with a decrease in frequency of his rest angina. By his six-week follow-up examination, the patient had had two previous episodes of rest pain. Nifedipine administration was increased to 20 mg, four times daily.

Discussion

This case report illustrates coronary artery spasm occurring after PTCA at a site other than the site of balloon dilatation. Two reports documenting coronary artery spasm after PTCA show all 11 patients to have had spasm at or adjacent to the site of the previous angioplasty.^{1,2} Coronary artery spasm in uninvolved vessels has not previously been described.

The second contrasting feature of this patient is the time of onset of his angina after PTCA. In the group reported by Hollman et al,¹ all 5 patients had symptomatic coronary artery spasm

within two months of PTCA. The group of patients reported by David et al² had proved coronary artery spasm at or next to the site of previous angioplasty one week to four months after the procedure. The patient reported here can be differentiated from the others based on the amount of time between PTCA and his angina. We suspect that when rest pain occurs less than four months after PTCA, spasm is more likely to occur at the angioplasty site.

Jay Hollman, M.D., F.A.C.C.
Department of Cardiology
The Cleveland Clinic Foundation
9500 Euclid Ave.
Cleveland, OH 44106

References

1. Hollman J, Austin GE, Gruentzig AR, Douglas JS Jr, King SB III. Coronary artery spasm at the site of angioplasty in the first 2 months after successful percutaneous transluminal coronary angioplasty. *J Am Coll Cardiol* 1983; **2**:1039-1045.
2. David PR, Waters DD, Scholl J-M, et al. Percutaneous transluminal coronary angioplasty in patients with variant angina. *Circulation* 1982; **66**:695-701.
3. Levine S, Ewels CJ, Rosing DR, Kent KM. Restenosis (R) following transluminal coronary angioplasty (TCA) (abst). *Circulation* 1983; **68**(suppl):III-96.