

# Enflurane-induced hepatitis with prominent cholestasis<sup>1</sup>

P. Gregory Foutch, D.O., F.A.C.P.<sup>2</sup>  
D. Roy Ferguson, M.D.  
Ralph J. Tuthill, M.D.

Previously reported cases of enflurane-induced hepatitis share similar clinical, biochemical, and histological features. Systemic symptoms follow a brief latent period after exposure to the anesthetic. Aminotransferase abnormalities predominate and coincide with the histological finding of centrilobular necrosis. The authors describe a case of enflurane-induced hepatitis with typical clinical manifestations associated with mixed hepatocellular and cholestatic liver-function-test abnormalities. Biochemical cholestasis eventually predominated and spuriously simulated an extrahepatic bile duct obstruction. Results of a percutaneous liver biopsy showed a mixed hepatocanalicular drug reaction.

**Index terms:** Case reports • Cholestasis • Enflurane, adverse effects • Hepatitis

Cleve Clin J Med 54:210-213, May/June 1987

Since its introduction into routine clinical practice, enflurane, a halogenated inhalation anesthetic, has been generally regarded as safe, effective, and relatively free of major side effects.<sup>1</sup> However, despite this, sufficient data have been garnered to implicate enflurane as a potentially

hepatotoxic agent.<sup>2-4</sup> According to Lewis et al,<sup>1</sup> 24 well-documented reports of enflurane-induced hepatitis have appeared in the literature. In all previously reported cases, the clinical, biochemical, and morphological derangements have been similar. Systemic symptoms follow a brief latent period after exposure to the anesthetic, and aminotransferase abnormalities predominate and coincide with the histologic finding of centrilobular necrosis.<sup>1</sup> We are reporting a case of enflurane-induced hepatitis which included typical clinical manifestations associated with marked cholestatic biochemical abnormalities and histologic features indicative of a mixed-hepatocanalicular injury.

## Case report

A 60-year-old man complained of dyspnea, productive cough, and hemoptysis. A chest radiograph showed a right perihilar mass with an infiltrate confined to the anterior segment of the right upper lobe. Examination of bronchoscopic biopsy specimens confirmed the presence of poorly differentiated squamous cell carcinoma arising from the right upper lobe bronchus. Evaluation for the presence of metastatic disease via cranial computed tomography, a radionuclide bone scan, bone marrow aspirate and biopsy, and liver-spleen scan was negative. Values of the following were within normal limits: complete blood count, aspartate aminotransferase (AST), serum cholesterol, prothrombin time, and total bilirubin. The alkaline phosphatase value was 131 IU/L (normal, 20-110 IU/L).

A right pneumonectomy was performed on October 7, 1983. Enflurane, nitrous oxide, and pancuronium bromide were the anesthetic agents used. Cefamandole was given on the day of surgery and continued through the first and second postoperative days only. Modest doses of meperidine hydrochloride and Percocet were the only additional medi-

<sup>1</sup> Departments of Gastroenterology (D.R.F.) and Pathology (R.J.T.), The Cleveland Clinic Foundation. Submitted for publication July 1985; accepted Mar 1986.

<sup>2</sup> Assistant Chief, Gastroenterology Section, V.A. Medical Center, Phoenix, Arizona, and Assistant Clinical Professor of Medicine, University of Arizona College of Medicine, Tucson, Arizona.

0891-1150/87/03/0210/04/\$2.00/0

Copyright © 1987, The Cleveland Clinic Foundation

**Table.** Serial changes in liver function tests following enflurane exposure\*

Postoperative day	AST†	ALT‡	AP§	GGTP**	T Bili††	Chol‡‡
24	455	—	341	—	3.9	210
25	594	574	748	—	4.6	229
27	415	534	865	1,280	5.2	299
29	390	—	780	—	6.0	399
31	238	—	850	1,330	7.5	500
45	55	77	550	—	2.2	411
61	34	28	223	243	0.8	318
74	33	—	130	—	0.8	280

\* Results of the liver function tests listed in this table were normal preoperatively, with the exception of the alkaline phosphatase level which was 131 IU/L.

† Aspartate aminotransferase (normal, 7–40 IU/L).

‡ Alanine aminotransferase (normal, 3–36 IU/L).

§ Alkaline phosphatase (normal, 20–110 IU/L).

\*\* Gamma glutamyl transpeptidase (normal, 0–50 IU/L).

†† Total serum bilirubin (normal, ≤1 mg/dL).

‡‡ Serum cholesterol (normal, 150–240 mg/dL).

cations used in the postoperative period. The patient was known to have received these medications in the past at similar doses without incident. Operating time was 270 minutes. There was no perioperative hypotension or hypoxemia.

Pathological examination of the surgical specimen revealed invasive, poorly differentiated squamous cell carcinoma involving the main stem bronchus and right middle lobe. None of the 28 resected lymph nodes contained neoplasm.

The patient's postoperative course was uneventful. He did not require transfusion, and pyrexia was never observed. He was discharged on the sixth postoperative day. Liver function tests were not re-evaluated prior to discharge.

On the eighth postoperative day, profound nausea developed. Intermittent rigors with associated fever to 38.9° C began on day 10. Over the ensuing 12 days, the patient experienced progressive weakness, fatigue, anorexia, and malaise in association with mild right upper quadrant discomfort. Choloria, pruritus, and overt jaundice became apparent on day 22. He was hospitalized on day 24. He denied contact with jaundiced persons and had not consumed alcohol since its discharge. His only medication was Percocet which he had used for postoperative incisional pain. Seventy-six tablets, confirmed by pill counting, had been consumed on a four-times-a-day (q.i.d.) basis over 18 days. Review of his medical record indicated that he had received isoflurane as a primary general anesthetic for an uncomplicated complete dental extraction and a vestibuloplasty with skin graft in January 1982 and April 1982, respectively. He had no atopic history.

Scleral icterus was the only abnormal physical finding.

Hepatitis B surface antigen, antibody to hepatitis B surface antigen, antibody to hepatitis B core antigen, and IgM antibody to hepatitis A were negative. The acute and convalescent antibody titer to cytomegalovirus was 1:32. The monospot was negative, and the heterophile antibody titer was nondiagnostic. The white blood cell count was normal, but the total eosinophil count was 786 cells/mm<sup>3</sup> and re-

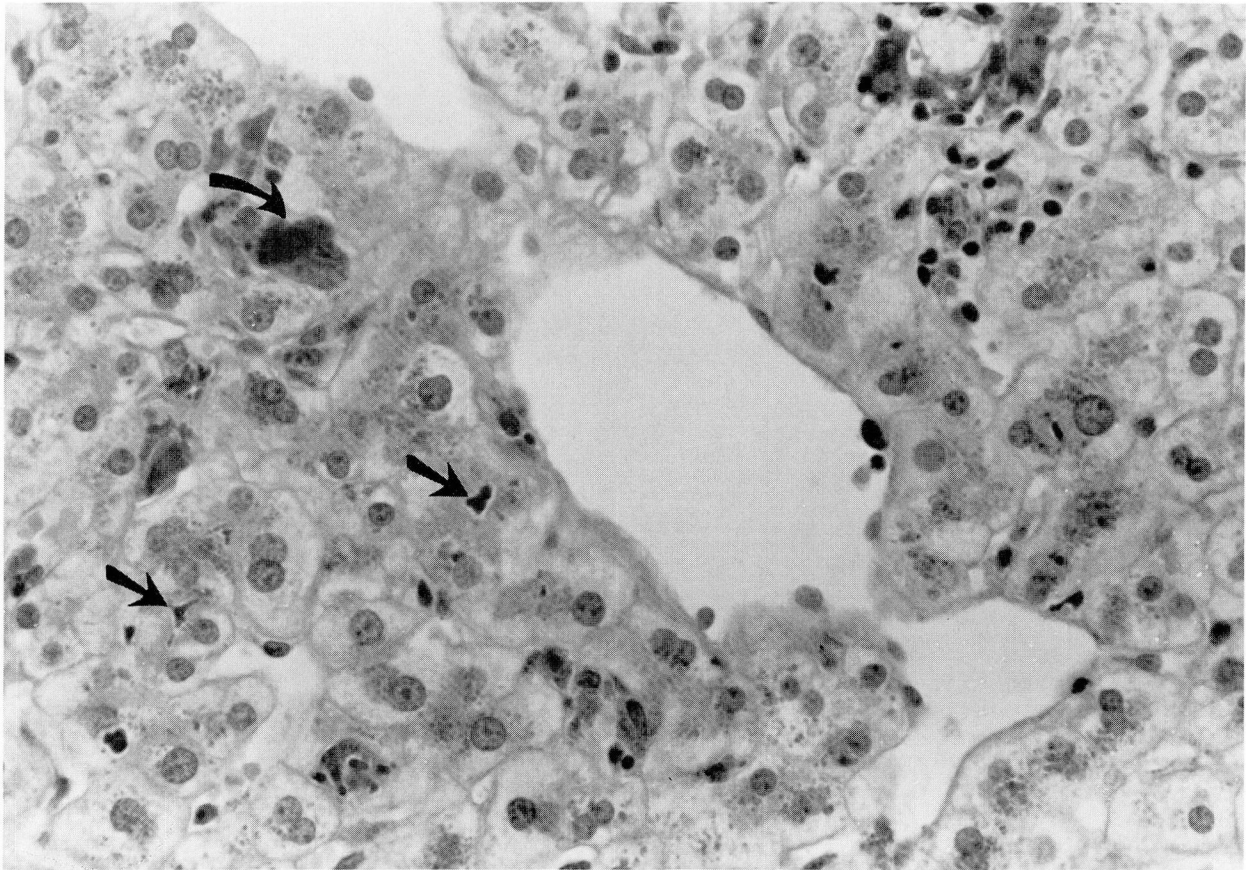
mained elevated throughout the patient's hospitalization. Antimitochondrial antibodies were absent. Prothrombin time was normal. Serial trends in liver function tests are summarized (Table). A lymphocyte transformation test performed against enflurane and Percocet was negative. Both abdominal ultrasound and computed tomography performed on day 29 and 31, respectively, failed to demonstrate dilated extrahepatic or intrahepatic bile ducts. The gallbladder was visualized by both modalities and did not contain stones. The patient's condition stabilized, and he was discharged on the 31st postoperative day. The follow-up laboratory evaluation is given (Table). A percutaneous liver biopsy, performed on day 45, revealed centrilobular canalicular cholestasis in all liver lobules. Bile pigment was seen in hepatocytes and Kupffer cells as well as in the canaliculi (Fig. 1). There was mild lobular disarray characterized by ballooning of hepatocytes. No acidophilic bodies were seen. Ceroid pigment including PAS-positive material was present in centrilobular macrophages. Nine portal tracts were unremarkable; however, three portal tracts revealed mild acute inflammation with polymorphonuclear leukocytes, slight edema of the portal connective tissue, and mild bile duct proliferation (Fig. 2). Polymorphonuclear leukocytes were seen close to and within bile duct epithelium and were within a bile duct lumen in one focus. One small noncaseating granuloma was present. Special stains for acid-fast and fungal organisms were negative. Immunoperoxidase stains for hepatitis B surface antigen and hepatitis B core antigen were negative.

In the ensuing four weeks, all liver-function-test results returned to normal. The alkaline phosphatase value returned to its preanesthetic level of 130 IU/L. The patient currently remains asymptomatic, has gained weight, and has resumed normal daily activities.

## Discussion

Following a latent period of eight days after exposure to enflurane and after two past exposures to isoflurane, a preicteric fever developed in our patient followed by other constitutional symptoms and then jaundice. Initially, eosinophilia in conjunction with a mixed hepatocellular-cholestatic liver injury was observed. However, biochemical cholestasis predominated by the 31st postoperative day and ultimately simulated extrahepatic bile duct obstruction. A percutaneous liver biopsy was consistent with a mixed hepatocannalicular drug reaction. The centrilobular ceroid pigment deposition in macrophages and mild lobular disarray with ballooned hepatocytes suggested prior hepatocellular damage, and the focal portal tract changes implied a hepatocannalicular drug hypersensitivity reaction.<sup>5</sup> A solitary granuloma may have been an incidental finding or an intrinsic response to drug hypersensitivity. Within approximately 10 weeks, all clinical and biochemical parameters returned to normal.

We suspect enflurane as the etiologic hepato-

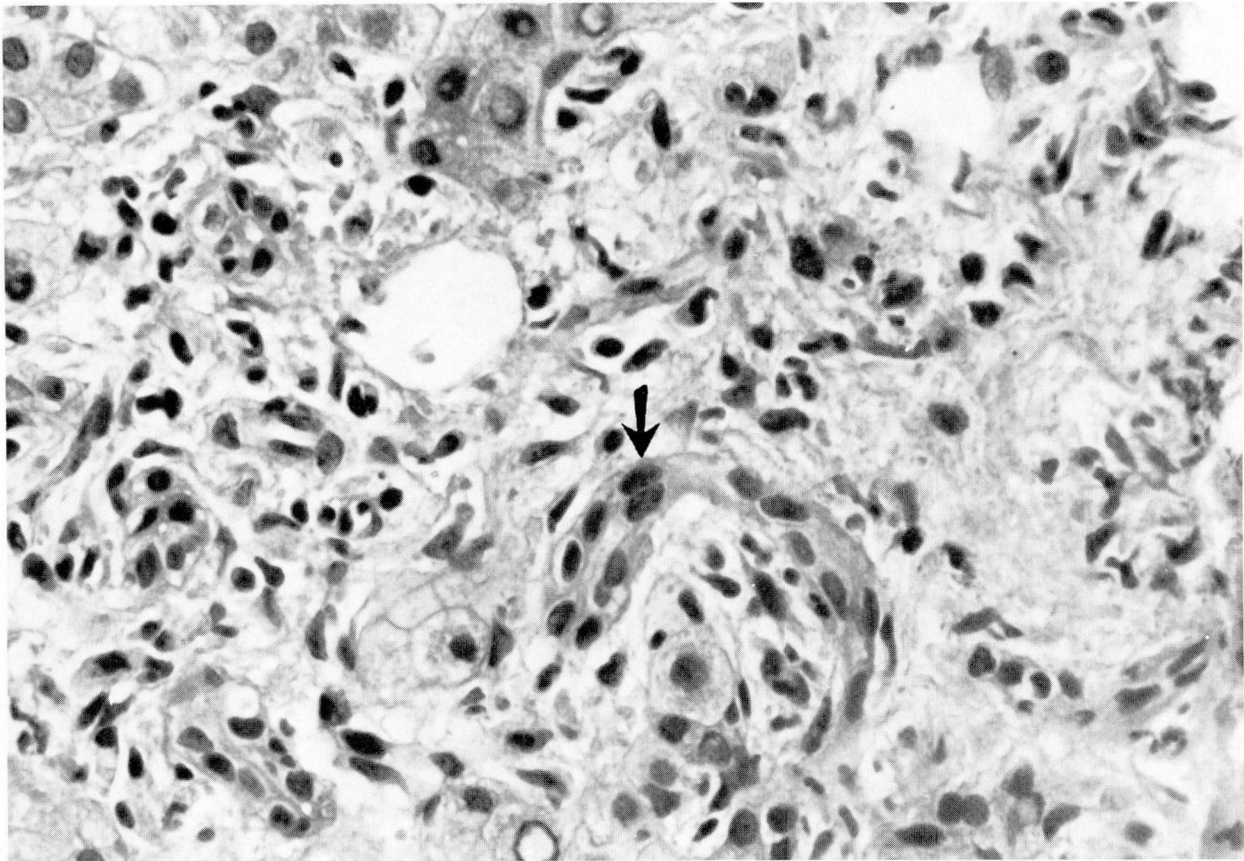


**Fig. 1.** Bile plugs in canaliculi (straight arrows) and macrophages filled with PAS-positive material (curved arrow) are seen near a central vein (periodic acid Schiff,  $\times 400$ ).

toxic agent. To our knowledge, the associated cholestatic features which predominated late in the clinical course have not been previously described in conjunction with enflurane-induced hepatitis. More usual causes of postoperative hepatic dysfunction, including shock, sepsis, hypoxemia, and cardiac failure, were not present. Ultrasound and computed tomography performed during peak elevations in serum bilirubin values demonstrated patent extrahepatic bile ducts. Viral etiologies, including hepatitis A, hepatitis B, cytomegalovirus, and Epstein-Barr virus, were appropriately excluded. Without identifiable serologic markers, it is impossible to unequivocally rule out an intercurrent non-A non-B infection as the responsible agent. However, the temporal relationship to surgery, the relatively short latent period between surgery and the onset of the patient's symptoms, and the presence of eosinophilia as a clinical indicator of hypersensitivity militate against non-A non-B hepatitis as a likely cause.

We are unable to indict benign postoperative intrahepatic cholestasis. This syndrome becomes manifest in severely debilitated patients requiring multiple transfusions after prolonged operations complicated by sepsis, hemorrhage, or cardiac or renal failure.<sup>6</sup> Minimal transaminase elevations (AST  $< 200$ ), hyperbilirubinemia, and a profound increase in alkaline phosphatase levels observed between the second and 10th postoperative days are characteristic biochemical features.<sup>6</sup> Our patient underwent an uncomplicated transfusion-free surgery. He became overtly jaundiced on the 22nd postoperative day and the initial biochemical profile suggested a combined cholestatic-hepatocellular liver injury with a peak AST elevation of 594 IU/L. Eosinophilia, as seen in our patient, is not part of the syndrome of benign postoperative intrahepatic cholestasis.<sup>6</sup>

When multiple medications are prescribed, it becomes difficult to incriminate a single specific drug as a cause of an isolated episode of hepatitis. Besides enflurane, our patient perioperatively re-



**Fig. 2.** A portal tract is expanded with edema, marginal pseudobile duct proliferation (arrow), and inflammatory cells (hematoxylin and eosin,  $\times 400$ ).

ceived nitrous oxide, pancuronium bromide, meperidine hydrochloride, Percocet, and cefamandole. Of these, only the acetaminophen component of Percocet is directly hepatotoxic. Our patient received a mean daily equivalent dose of 1,372 mg of acetaminophen over an 18-day interval in the immediate postoperative period, a dosage far removed from that considered to be hepatotoxic.<sup>5</sup>

An idiosyncratic hypersensitivity reaction to any of the remaining medications is remotely possible and cannot be unequivocally excluded. However, the chronological sequence of clinical events observed in our patient correlates best with previous reports of enflurane-induced hepatitis.<sup>1</sup> Therefore, if our observation is correct, under appropriate clinical circumstances, enflurane must be considered in the differential diagnosis of cholestatic as well as hepatocellular causes of postoperative jaundice.

#### Acknowledgment

We are grateful to William D. Carey, M.D., for his critical review of the manuscript.

#### References

1. Lewis JH, Zimmerman HJ, Ishak KG, Mullick FG. Enflurane hepatotoxicity: a clinicopathologic study of 24 cases. *Ann Intern Med* 1983; **98**:984-992.
2. Denlinger JK, Lecky JH, Nahrwold ML. Hepatocellular dysfunction without jaundice after enflurane anesthesia. *Anesthesiology* 1974; **41**:86-87.
3. Kline MM. Enflurane-associated hepatitis. *Gastroenterology* 1980; **79**:126-127.
4. White LB, DeTarnowsky GO, Mir JA, Layden TJ. Hepatotoxicity following enflurane anesthesia. *Dig Dis Sci* 1981; **26**:466-469.
5. Zimmerman HJ. *Hepatotoxicity: The Adverse Effects of Drugs and Other Chemicals on the Liver*. New York, Appleton-Century-Crofts, 1978.
6. LaMont JT, Isselbacher KJ. Current concepts: postoperative jaundice. *N Engl J Med* 1973; **288**:305-307.

D. Roy Ferguson, M.D.  
Department of Gastroenterology  
The Cleveland Clinic Foundation  
9500 Euclid Ave.  
Cleveland, OH 44106