

# Progress, reason, and fallacy in today's world of neurosurgery<sup>1</sup>

Charles A. Fager, M.D.

I first met Doctor Gardner in 1949. I was here at the Cleveland Clinic in the customary process of searching out a residency. He took me to the operating room to observe his two cases that afternoon—the first an occipital neurectomy (popular in those days) and the second a brain tumor. It was the first time I had seen surgery done with the patient sitting. It was the first (and last) time I had seen a circular craniotome. When I expressed some sadness that the brain tumor was a glioblastoma, he appeared irritated at what seemed an immature reaction and glowered at me, “If you are going into neurosurgery, this is one of the things that you have to live with!” I found him a fascinating person and enjoyed picking his brain the many times we met over the years. He was often to be found at the scientific exhibit area of a meeting explaining some physical principle or another, the well-known twinkle in his eye as he elaborated on his position.

Doctor Gardner was remarkably inventive but more than just a “gadgeteer” since many of his innovations have endured. I would like to tell him that I still use the sitting position and have not been swayed by any of the arguments against it. From such a simple notion as the spring-loaded tongs to the more complex theories on the de-

velopment of syringomyelia, trigeminal neuralgia, and hemifacial spasm, his ingenuity and originality are obvious. His theories on the embryology of the fourth ventricle and central canal, controversial as they may have been, will probably survive the test of time and stand as a measure of his genius and tenacity.

Doctor Gardner received his medical degree in the same year that I was born; we are a generation apart. Neurosurgery was alive, holding the promise of useful survival. Flushed with some success and implements inherited from the British, French, and developing American schools, Doctor Gardner and his peers were exploring new frontiers. The momentum of brain and spinal surgery propelled them into other endeavors—the field was theirs for the taking and the psychology of the times called for action. Talking pictures, the radio, and aviation, as well as general medicine and surgery, were racing ahead, hardly affected by the Depression, though the infant specialty held a tentative and uncertain position in the medical community.

## Progress and reason

The Second World War brought progress in surgical technique and supportive therapy as well as improved stature and more confidence in the young specialty. I learned so much from my own mentors, especially James Poppen, though some of their explorations in those days into psychosurgery, sympathectomy, and all forms of deafferentation eventually yielded to prudence and discrimination.

Reflecting on what I might say to you today, it

<sup>1</sup> Dr. Fager is chairman emeritus of the Department of Neurosurgery at the Lahey Clinic. He was past president of the Neurosurgical Society of America (1975–1976) and was a member of the American Board of Neurological Surgery (1977–1983). He is particularly noted for his expertise in spinal surgery.

Presented at The Cleveland Clinic Foundation, June 20, 1986.

0891-1150/87/04/0261/10/\$3.50/0

Copyright © 1987, The Cleveland Clinic Foundation

occurred to me that the third generation of neurosurgeons has lived through an even more exhilarating period. Forty years ago, I received my own medical degree, and my first rotation as a rookie intern in April 1946 was on a communicable disease service. During one of the worst measles epidemics our country has known, my first sleepless month as a physician was spent sustaining many cases of encephalitis, hoping for recovery rather than death or permanent damage. I never dreamed that this terrible disease or the more dreaded poliomyelitis would be controlled in my lifetime. We were still using sulfadiazine for meningitis since the newly discovered penicillin was in short supply. Tuberculosis was treated by bed rest, pneumothorax, and thoracoplasty. There was, of course, no hope for severe sepsis or renal failure. In this single area of infectious disease, as in every sphere of scientific endeavor, progress in 40 years has surpassed that of all prior civilizations. In fact, we have gone beyond the control of bacteria in our environment and even put them to work for us. Who could have dreamed that we would involve *E. coli* in the manufacture of insulin?

Progress must be balanced by reason, scientific achievement by common sense. The excesses of such achievement will haunt us—not only the preposterous transplant of a baboon heart, but also the widespread use of coronary bypass surgery and carotid endarterectomy which has led some to wonder how much has been justifiable.

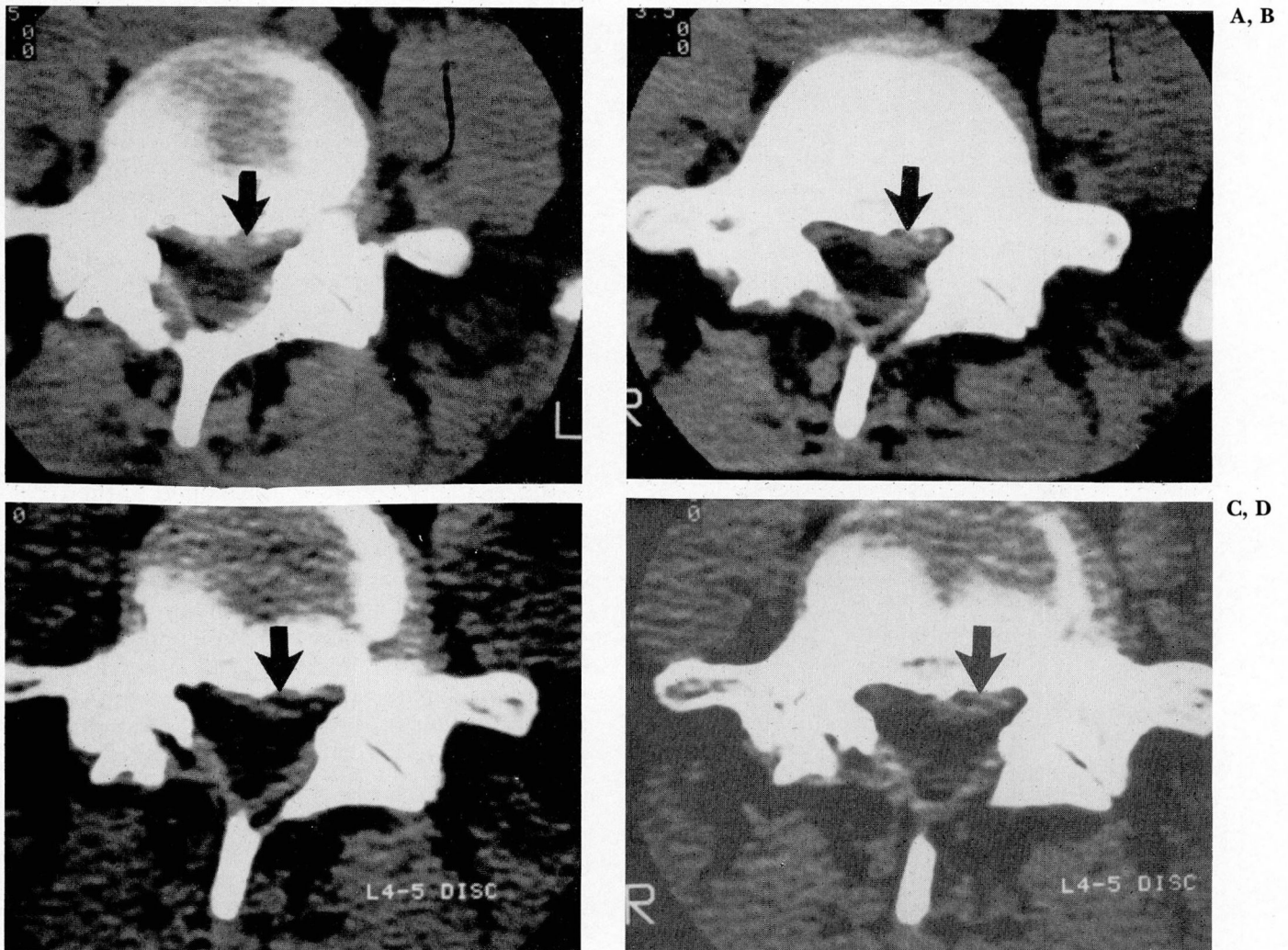
What of neurosurgery? Twenty-seven years ago in an essay entitled “The Changing Pattern of Neurosurgery,” I wrote, “We can look back with wonder and marvel at the pioneer neurosurgeons who successfully removed many a brain tumor without such aids as the electrocautery, ventriculogram, or arteriogram. Yet we wonder also whether such procedures such as these will be considered clumsy or unnecessary at some future time.” I did not however believe that air studies would be discarded so soon. Neurosurgeons in the ensuing years became occupied with ablative procedures—stereotactic methods for movement disorders and pain, pituitary ablation for breast cancer and diabetic retinopathy, and more selective psychosurgical procedures for emotional modification.

Some success in these areas led to the first of several fragmentations within our specialty as the concept of functional and stereotactic surgery emerged. Since any ablation must be attended by functional loss, whether subtle or adverse, efforts

in recent years have been directed at preservation of function. Though electrical stimulation of thalamus, cerebellum, and spinal cord has met with little enthusiasm, microvascular dissection of blood vessels at the root entry and exit of the trigeminal and facial nerves could prove to be an acceptable approach to trigeminal neuralgia and hemifacial spasm, provided the morbidity and mortality of these procedures declines—as reason comes closer to progress. (Doctor Gardner described redundant vessels compressing the facial nerve at least 25 years ago.<sup>1</sup>)

The introduction of the operating microscope to neurosurgery must be considered unsurpassed by any other technological achievement thus far. Magnification has clearly extended our frontiers, allowing appreciably better dissection of basal tumors, lesions around the brain stem, intramedullary tumors, many aneurysms, and arteriovenous malformations. Acoustic surgeons now discuss preservation of hearing. The thrill of this experience in my view has been somewhat diminished by reports of operations lasting 14 hours or more for cerebellopontine angle tumors, resulting in cerebellar edema or brain stem damage. Equally disheartening have been similar complications from transsphenoidal pituitary surgery.

I do not pretend that there were no problems in premicrosurgical times, but among fewer neurosurgeons, greater experience was gained with each procedure. Furthermore, many pituitary adenomas were successfully treated by radiation and others, some of the microadenomas of today, proved to be self-limited. Transposing that sophistication of dealing with these lesions probably with more centralization to the microsurgical techniques of today certainly combines the best of both worlds. The use of ultrasonic and laser devices in tumor extirpation provides some additional help with broadly fixed basal meningiomas. A more intriguing laser technology deals with the anastomosis and sealing of blood vessels which assumes more importance if controversy over bypass procedures is resolved and, in any event, for the anastomosis and repair of cerebral vessels. Improvements in electrocorticography, ultrasonography, and evoked potential monitoring during surgery have added immeasurably to the development of safer and more effective surgery. Yet neither laser nor chemotherapy nor radiation of many types has significantly changed the plight of the glioblastoma patient in recent years. Some of these treatments which appear to

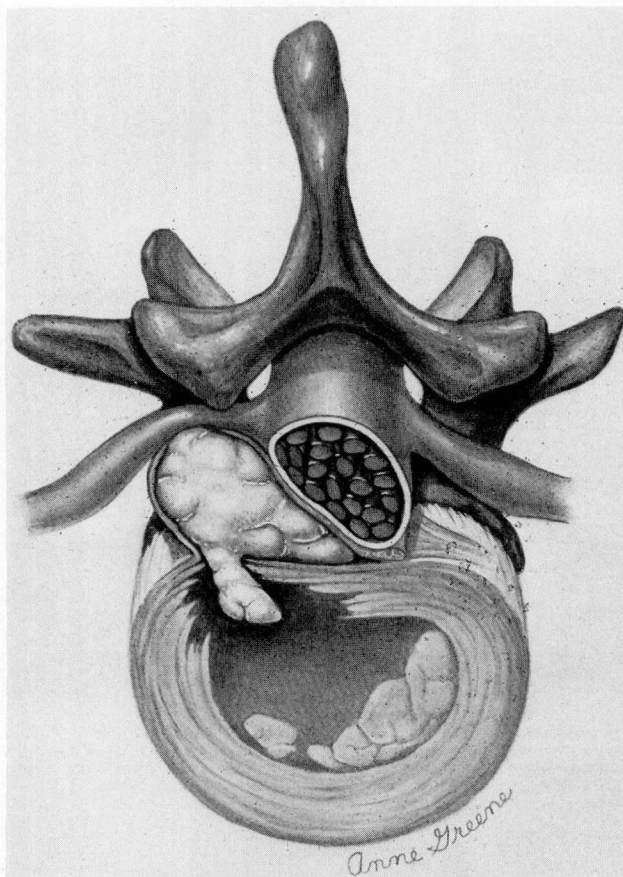


**Fig. 1.** Lumbar CT scan of patient with ruptured disk, left L-5 root compression, and spontaneous recovery (A and B). Six months later, the patient remained asymptomatic. CT scans show partial resolution of the disk fragment (C and D).

represent progress have at times exceeded the bounds of reason with little thought to the quality of extended life.

Finally the triumph of imaging represents progress we only dreamed of during our travails with air studies and arteriograms. Diagnostic procedures were at times such an ordeal for patient and surgeon that they were often withheld when an earlier diagnosis would have served the patient better. The unique portrait of a posterior fossa tumor today has not lost its novelty as I reflect that its presence at one time was only reckoned by the obvious hydrocephalus detected by ventriculography or during pneumoencephalography by the absence of ventricular filling, little air in the cisterna magna, and a small amount of supracallosal air outlining the lateral ventricles.

Yet here also progress must be tempered by reason. Paradoxically, the more that is seen by CT and MRI scans, especially those of the spine, the greater the potential for inappropriate surgery. I consult almost daily with patients seeking an opinion bearing their spinal CT scans—few people with backache escape scanning these days. These are often purported to show disk rupture when, in fact, there is nothing more than the normal disk configuration at the lower lumbar levels, or they are said to indicate neural foramen encroachment, a finding which has always been and still is illusory. The reasonable surgeon must be a critical interpreter of these images in terms of his patient's complaints and physical findings. One added advantage, however, of current imaging is that it seems to have laid to rest the



**Fig. 2.** Typical disk rupture which requires surgery. A large fragment extrudes through a small opening of the annulus, distending the posterior longitudinal ligament, which is attenuated or torn at the apex of the fragment.

foolishness of epidural venography. But why in the world does anyone need thermography?

### Fad and fallacy

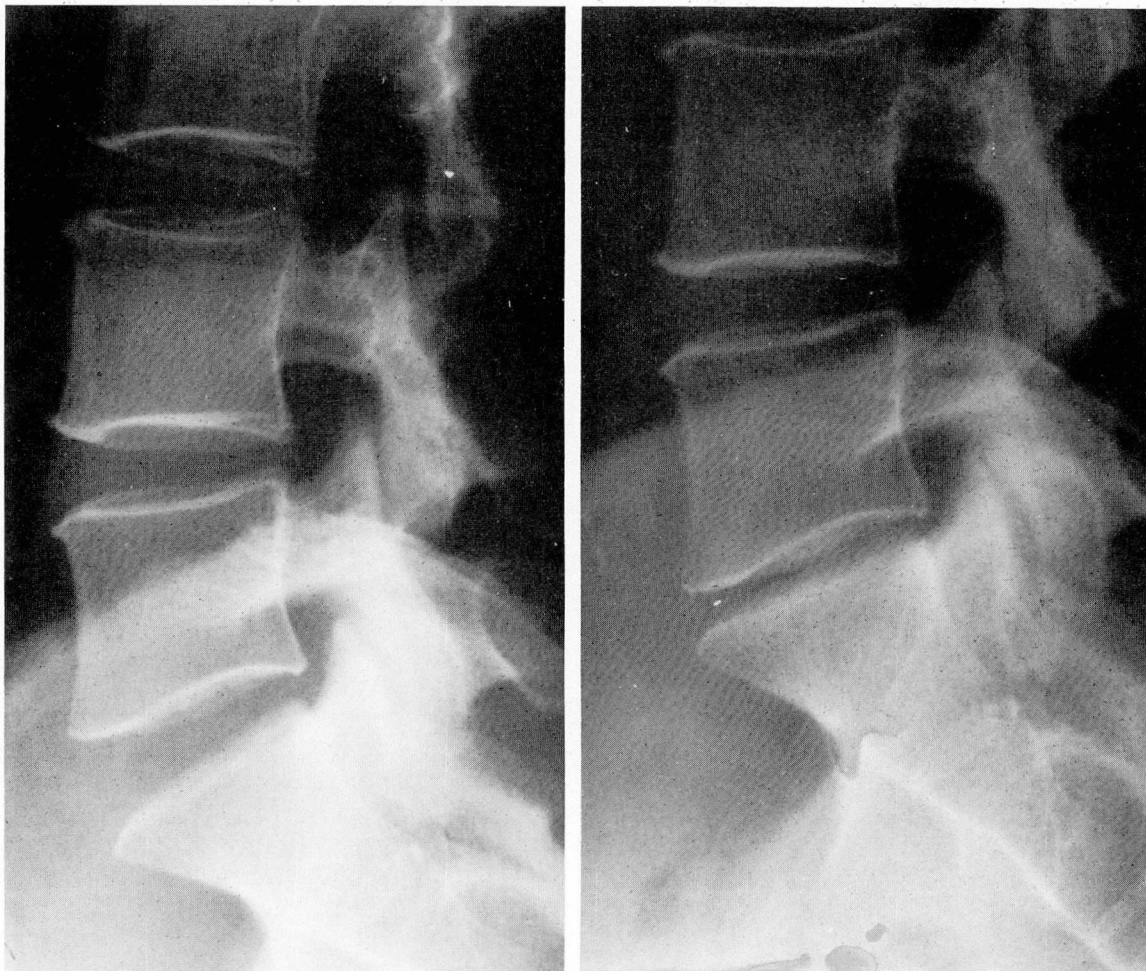Doctor Gardner, commenting over 20 years ago on specialization in intraspinal surgery, was concerned that surgery within the spinal lumen was being done by surgeons not qualified through training for such operations.<sup>2</sup> He expressed the belief that while the ability of the individual surgeon varies widely within each specialty, in intraspinal disease, the advantage is with the patient whose surgeon has graduated from an approved program in neurological surgery. Since then there have been many orthopedic programs that have provided special training in spinal surgery. My own observations, having

seen many patients operated on by graduates of approved programs in both specialties, suggest that neither has been successful in reducing the inordinate number of spinal operations or eliminating inappropriate surgery. In the midwestern United States, it was estimated several years ago that there are over 45 lumbar disk operations per 100,000 people each year, while in the United Kingdom only 12, and in Sweden 10. The figures must be much higher on the east and west coasts in view of the estimated 200,000 operations each year referred to more recently. It seems unlikely that Americans have a particular predisposition to lumbar disk disease, requiring so much more surgery, or that many Britons and Swedes are suffering from a lack of surgery.

Just as many fads have developed in the treatment of neck and back problems, the area of spinal surgery has spawned many fallacies. We may be critical of chiropractic, acupuncture, rolfing, and other forms of manipulation. Backache has responded to many types of charlatanism, all kinds of traction, braces, and devices. Those of us with back pain can now go to the back store—a supermarket of delights from special chairs to gravity boots. Yet one must also ask if steroid injections, facet blocks, so-called rhizolysis, and electronic stimulators have anything more to offer. Actually, these pale in significance to the explosion of surgical procedures which have gained prominence in recent years. From anterior cervical fusion to posterior lumbar interbody fusion, anterior lumbar fusion, many internal fixation devices, each in its own mode, having some merit but all inordinately overdone.

One fallacy of our times is the notion that trauma plays an important primary role in rupture of a spinal disk. Disk rupture as a direct result of injury is uncommon in my experience, accounting for no more than 10% of patients who require surgery. Yet many persons who suffer nothing more than back or neck sprain at work or in vehicular collisions are still subjected to major spinal operations. These have been done even in the face of normal myelography, especially cervical, on the flimsy justification that there has been some internal derangement of the disk.

Other operations have been undertaken on patients with back pain because of radiological evidence of disk degeneration or other spondyloitic changes which have often been asymptomatic. Failure to improve after successive opera-



A, B

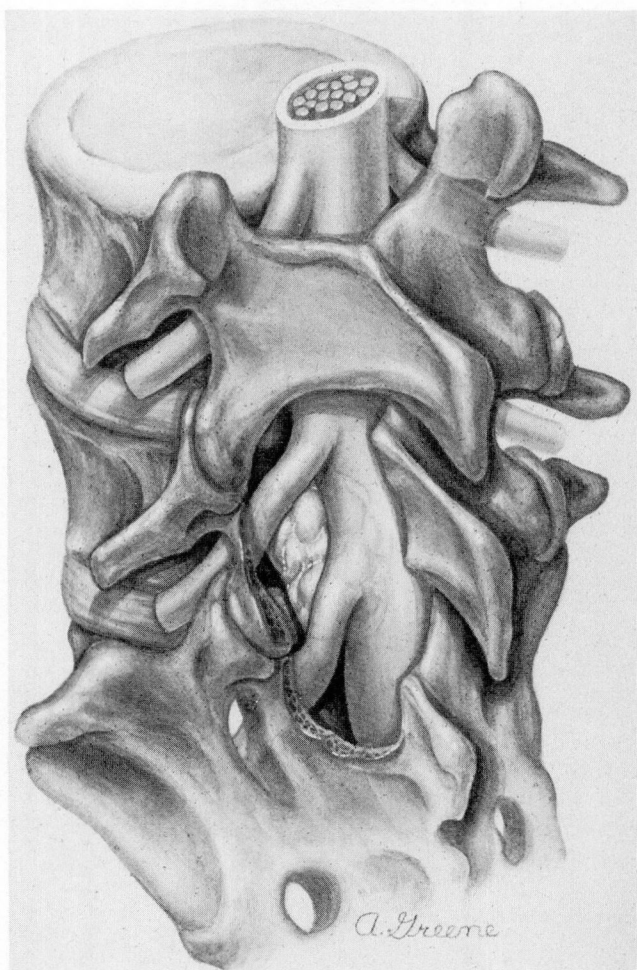**Fig. 3.** Lateral radiographs of lumbar spine showing normal L5-S1 disk space before injection of chymopapain (A) and marked narrowing of disk space three months after injection (B).

tions is not considered the surgeon's fault, rather the "failed back" or the "litigation case." Nothing of course justifies disability for a minor injury better than major surgery. Among many patients who have had 10 or more spinal operations, it is evident that there was no indication for the first one and with each successive procedure the patient becomes more and more incapacitated. One tragic byproduct is that the patient with an extruded disk who can expect a successful outcome is at times unwilling to consider surgery. Another is that surgeons have given up what should be a gratifying operation in search of other treatments for the wrong reasons.

We could be spared the national embarrassment many of us feel if we were to accept a few basic doctrines—most backaches get better in

time, there is no cure for a bad back, and none of the many treatments or devices surpass a good exercise routine in helping people to live with their back problems. As effective as it may be in the relief of neural compression or instability, there is little surgery which improves spinal structure.

Spontaneous recovery from a ruptured disk is so common that results of any treatment may be delusive. It appears likely that what actually happens is a resorption of disk tissue adequate to provide more room for a nerve root and thus relief of radicular pain. This is evident in patients with a ruptured lumbar disk who recover fully without treatment (*Fig. 1*). Recovery of this type has been attributed to steroids, colchicine, manipulations, and many other treatments. It has



**Fig. 4.** Large disk fragment extrudes cephalad to L5-S1 disk space. Adequate hemilaminectomy would be required for decompression of both nerve roots and atraumatic liberation of the fragment.

certainly accounted for the relief of pain among patients receiving placebos in double-blind studies and probably for the improvement of many patients who have received enzyme injections.

It was entirely predictable that chemonucleolysis as a treatment alternative for disk rupture could be more regressive than beneficial.<sup>3</sup> Apparently, some surgeons unwilling to accept the rigid criteria for proper patient selection and appropriate surgical technique perceived intradiskal therapy as a benign substitute. Proclaimed as a method which could eliminate much lumbar disk surgery, it is clear that many patients who previously had surgery which should not have been done now undergo chemonucleolysis which

should not be done, until recently at multiple levels.

The use of proteolytic agents and the other intradiskal gimmick, so-called percutaneous discectomy, are faulted by the well-established observation that most disk fragments which eventually require surgical intervention of any kind are either extruded or incarcerated outside the disk space. These loosened fragments have often burst mushroom-like through a small opening in the annulus, sometimes contiguous with the disk space but *not* with intradiskal cartilage (*Fig. 2*). While chymopapain may affect cartilage within the disk space, its influence on such ruptured fragments must be considered dubious, the procedure therefore worthless. Of the numerous studies reported thus far, there remains little evidence to conclude that the effect of chymopapain is better than that of a placebo.<sup>4</sup>

Furthermore, statements in the literature concerning the dangers of chymopapain have been misleading. Agre et al<sup>5</sup> compared the mortality rate of chemonucleolysis with that of laminectomy and claimed 11 deaths in 60,000 patients (0.02%), but the study which reported 11 deaths and 11 cases of paraplegia had data on only 29,075 patients. More recently, there are reports of 21 deaths in an "estimated" 98,000 chemonucleolysis patients.<sup>6</sup> There are, of course, no published data whatsoever on 98,000 patients and we have no way of knowing if the latest figures on mortality and adverse reaction are still in the 50% range.

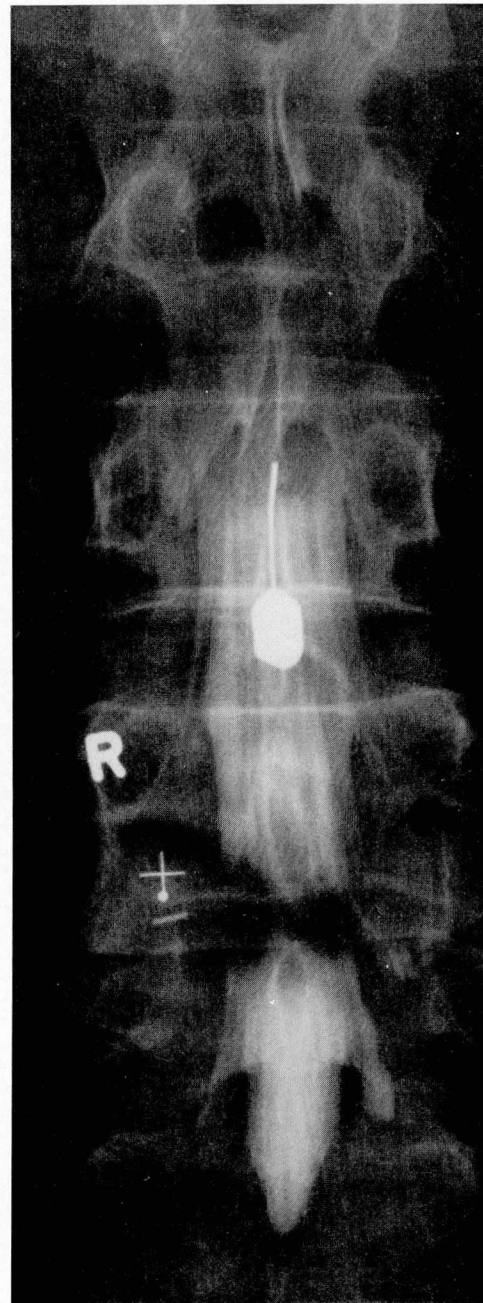
What has been referred to as "postmarketing surveillance" demonstrates some of the abuse of chymopapain, disclosing that approximately 24% of patients had been injected at more than one level.<sup>6</sup> I have yet to see the first patient with simultaneous symptomatic rupture of more than one disk. Inappropriate applications of the procedure are common with many injections made into normal ("bulging") disks, degenerative disks, and a number of patients with spondylosis, facet arthropathy, and spinal stenosis.

The conspicuous finding in many of the patients I have seen who were worse after enzyme injection has been a rapid narrowing of the disk space (*Fig. 3*), but I have also observed patients with radiculopathy involving single or multiple nerve roots similar to that which has occurred following surgery. It is difficult to escape the

conclusion, having studied about 50 of these unhappy patients, that the degree of destruction of cartilage and thus narrowing of the disk space may be proportional to the concentration of enzyme within the intervertebral disk space. Some leakage of the agent into surrounding tissue or rapid absorption into venous circulation may well occur in those patients in whom no postinjection narrowing develops. A number of patients of course have been forced to undergo surgery after failed chemonucleolysis, adding to their discomfort and expense.

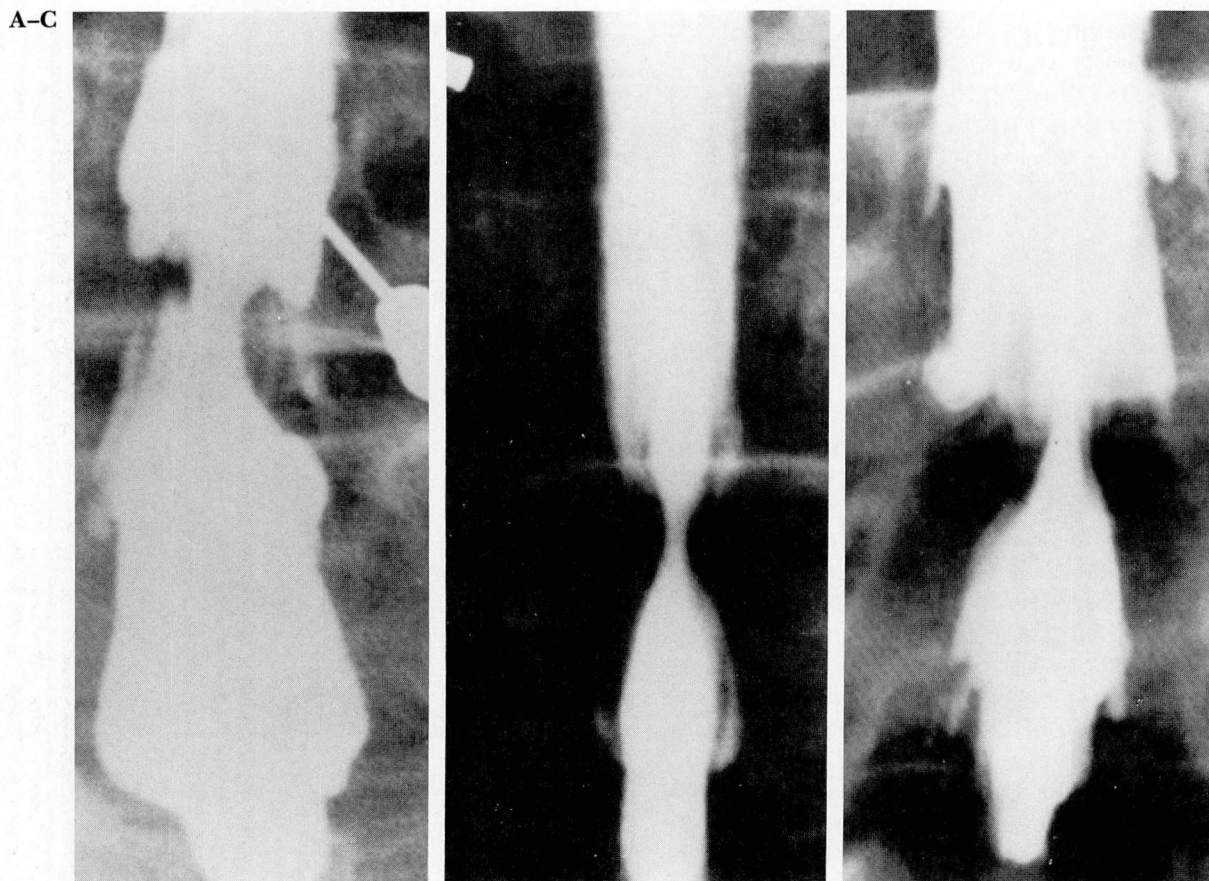
While failure of chemonucleolysis appears to have been treated lightly, it is evident that the procedure is not innocuous, that the reported adverse effects represent serious complications, and that other harmful effects lead to prolonged pain and disability. Considering all the undesirable side effects, the question must be asked whether the placebo effect of this procedure, which may account for "success" in many patients, justifies its continued use. I have asked this question of the Food and Drug Administration which has no intention of changing its position.

Advocates of lumbar microdiscectomy, proclaiming a more conservative approach than conventional surgery, seem to ignore all the other improvements in surgical technique. The patient of 35 years ago frequently endured great pain after disk surgery, had to be turned by "log-rolling," often required catheterization and prolonged confinement in bed, and was in the hospital 10 days or more. Today, patients are ambulatory within hours of the operation, are discharged from the hospital in two or three days, and return to work in two to three weeks. These changes preceded the needless introduction of 1-inch incisions, limited exposure, and superfluous magnification. Paradoxically, in my experience, they have come about with longer incisions, longer and less traumatic retraction of muscle, and more bone removal<sup>7,8</sup> largely to gain access to the many disk fragments which require surgery (*Fig. 4*). Utilizing the operating microscope under circumstances of adequate bone removal and epidural exposure may be useful for the surgeon who feels this is helpful, but the operation of lumbar microdiscectomy as it has been described is associated with several disadvantages and actually additional risks for the patient with a ruptured lumbar disk who may require surgery. I have reoperated on a number of patients with



**Fig. 5.** Myelogram of a patient with ruptured disk at L4-5 on right. A lumbar microdiscectomy three months before failed to locate a major disk fragment and relieve root compression.

retained disk fragments, some having neurological deficits after microdiscectomy (*Fig. 5*). In several reports, there have been excessive numbers of dural tears.<sup>9-11</sup>



**Fig. 6.** A-C. Myelograms of 3 patients with constrictive spondylotic lesions misinterpreted as disk rupture. Surgery in each case was through small bilateral openings without adequate decompression.

Proponents of microdiscectomy have reported surgical series with compensation cases numbering as high as 46%.<sup>12</sup> This only suggests to me a lesser operative procedure for a number of patients after work-related accidents in whom satisfactory recovery might be expected without any operation at all.

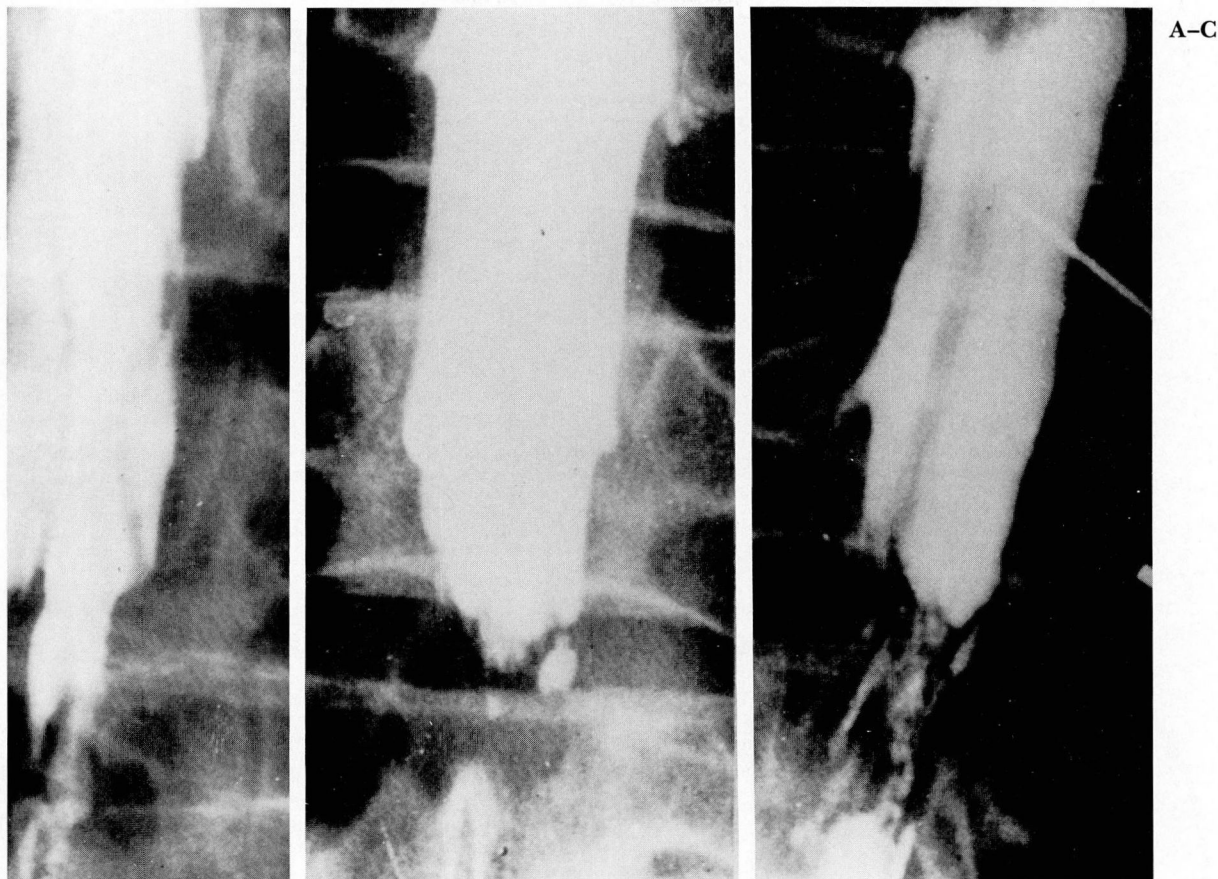
Before the introduction of microsurgery, it was clear that poor exposure and inadequate decompression were the major causes of failure in those patients who required surgery. Spondylotic constriction or so-called waist-like myelographic deformities have often been misinterpreted as midline disk protrusions or annular bulge, which has led to disk removal through small frequently bilateral surgical exposures (*Fig. 6*). The same type of operation has also been advised for median-paramedian disk ruptures. This type of surgery, rather than relieving compression of the nerve root or cauda equina, has intensified con-

striction because of contusion, early root edema in a confined canal, later epidural fibrosis, and cohesion of nerve roots, often termed adhesive arachnoiditis (*Fig. 7*). The practice of using fat pads pushed into small openings actually seems to intensify rather than alleviate this problem.

The quintessence of spinal surgery relies on two basic principles—satisfactory neural decompression and adequate exposure. These fundamentals increase in importance, ascending through the thoracic and into the cervical spine (*Fig. 8*). Anterior approaches may not satisfy both requirements any more than improper posterior approaches in dealing with disk rupture, spondylosis, or tumor. It is fallacious to believe that paraplegia or quadriplegia may be prevented simply by one approach or another.

I suppose what I am trying to say is that every change does not represent progress; there is a delicate balance between reason and fallacy.





**Fig. 7. A-C.** Postoperative myelograms after inadequate decompression show appearance considered typical of arachnoiditis.

Some dogma do endure, though each generation eventually gives way to its successor.

I was recently complaining as I do frequently about being delayed by placement of the central line and the arterial line and the Doppler and all the paraphernalia I no longer have the drive or the ability to fight. I was wondering out loud as usual about how we could have operated on so many brain tumors and cervical disks without these devices. The young anesthesiologist paying little heed to my raving countered with the expression "May this house be safe from tigers" and promised the reference. It comes from a book by Alexander King who relates the habit of his friend, Norman Prelick, a Zen Buddhist:

Every time this character comes to visit me and finally gets ready to leave, he stops in the doorway, folds his hands Hindu fashion, lowers his fourth-dimensional eyelids and says:  
"May this house be safe from tigers."

He does this every time.

The other day, when his senseless little orison had fallen on me again, I said to him, "What is the meaning of this idiot prayer you're always uttering over me every time you leave here? What the hell does it mean, anyway?"

(It should be noted that King was a resident of Manhattan.)

Norman looked surprised and even a little hurt, and finally he gave off the familiar long-suffering sigh of the frequently misunderstood.

"What's wrong with my prayer?" he said.

"How long have I been saying it to you?"

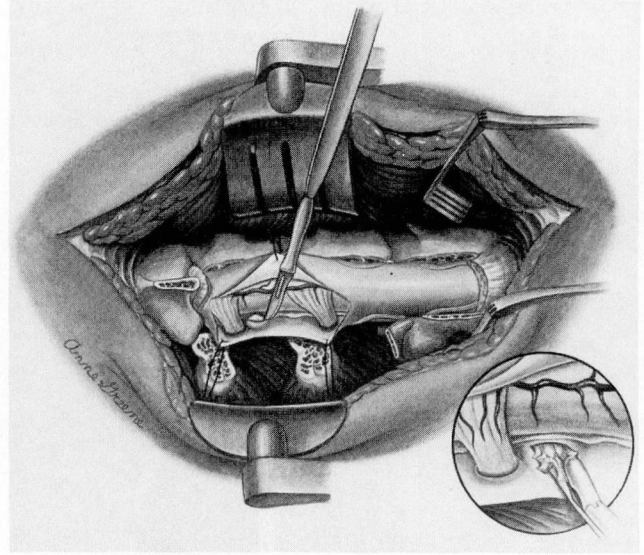
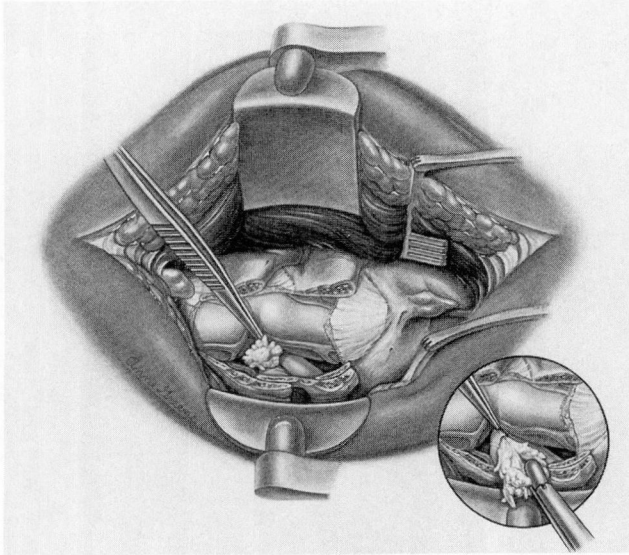
"Oh, about three years, on and off."

"Three years," he said. "Well—been bothered by any tigers lately?"

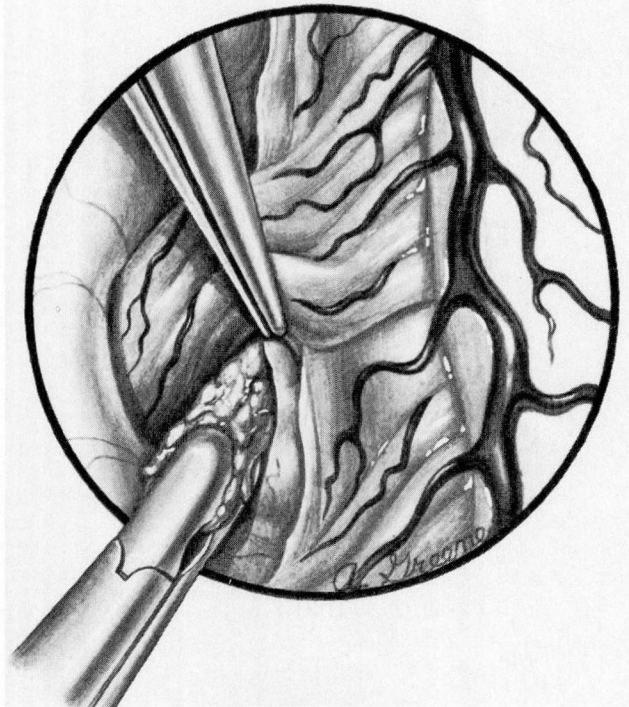
I may have to surrender to Zen Buddhism and obviously already have to the next generation.

Lahey Clinic  
41 Burlington Mall Rd.  
Burlington, MA 01803

A, B



C



**Fig. 8. A.** Lumbar laminectomy at L4-5 for rupture median disk. Note the bone removal beyond the lateral margin of dura on the left side decompressing the cauda equina and providing for a posterolateral approach to the lesion.

**B.** Posterolateral approach to ruptured thoracic disk. Transdural exposure minimizes the risk of retraction.

**C.** Posterolateral transdural approach to ruptured median (paramedian) cervical disk. The spinal cord is decompressed by adequate laminectomy and lateral bone removal on one side.

## References

- Gardner WJ, Sava GA. Hemifacial spasm—a reversible pathophysiologic state. *J Neurosurg* 1962; **19**:240–247.
- Gardner WJ. Specialization in intraspinal surgery (editorial). *Surg Gynecol Obstet* 1965; **121**:838–839.
- Fager CA. Chymopapain for chemonucleolysis for lumbar disk disease in U.S. *Orthop Rev* 1979; **8**:189–190.
- Deyo RA. Chymopapain for herniated intervertebral disc: a methodologic analysis and an agenda for future research. *Spine* 1984; **9**:474–478.
- Agre K, Wilson RR, Brim M, McDermott DJ. Chymodiactin postmarketing surveillance: demographic and adverse experience data in 29,075 patients. *Spine* 1984; **9**:479–485.
- Javid MJ. Efficacy and safety of chymopapain versus laminectomy (response to letter). *J Neurosurg* 1985; **63**:992–994.
- Fager CA. Ruptured median and paramedian lumbar disk: a review of 243 cases. *Surg Neurol* 1985; **23**:309–323.
- Fager CA. Lumbar microdiscectomy: a contrary opinion. *Clin Neurosurg* 1986; **33**:419–456.
- Merli GA, Angiari P, Tonelli L. Three years experience with microsurgical technique in treatment of protruded lumbar disc. *J Neurosurg Sci* 1984; **28**:25–31.
- Wilson DH, Kenning J. Microsurgical lumbar discectomy: preliminary report of 83 consecutive cases. *Neurosurgery* 1979; **4**:137–140.
- Wilson DH, Harbaugh R. Microsurgical and standard removal of the protruded lumbar disk: a comparative study. *Neurosurgery* 1981; **8**:422–427.
- Williams RW. Microlumbar discectomy: a conservative surgical approach to the virgin herniated lumbar disk. *Spine* 1978; **3**:175–182.