

Benign essential blepharospasm treated with botulinum toxin¹

A. Jan Berlin, M.D.
Joyce H. Cassen, M.D.
Garland DeNelsky, Ph.D.
Maurice R. Hanson, M.D.
Patrick J. Sweeney, M.D.

Blepharospasm in 12 patients was graded according to its severity. Six patients also underwent neurological and psychological examinations. All were treated with periocular botulinum toxin injections, and all noted a reduction in spasm severity one week later. The effect lasted 60 to 90 days. The average improvement range was 2 gradations of spasm severity. Complications included a transient ptosis (two patients) and superficial punctate keratopathy (one patient). A psychological component—apparent secondary gain from the blepharospasm—was noted in three patients.

Index term: Eyelid diseases, drug therapy

Cleve Clin J Med 54:421-426, Sep/Oct 1987

Blepharospasm and its related spasmodic condition, when severe enough, cause blindness. One of the most recent attempts to reduce this debilitating eyelid closure has been the injection of botulinum toxin (Oculinum) into the eyelids to weaken the musculature.¹ This paper will present our early experience using this drug-related therapy.

Materials and methods

All patients presenting at the Cleveland Clinic from December 1, 1984, to May 1, 1985, and found to have benign essential blepharospasm (BEB) or hemifacial spasm (HFS) were considered eligible for the study. The investigational nature of the proposed treatment was explained in detail to the patients and informed consent was obtained in writing.

¹ Departments of Ophthalmology (A.J.B., J.H.C.), Psychiatry (G.D.), and Neurology (M.R.H., P.J.S.), The Cleveland Clinic Foundation. Submitted for publication Aug 1985; accepted May 1987.

0891-1150/87/05/0421/06/\$2.50/0

Copyright © 1987, The Cleveland Clinic Foundation

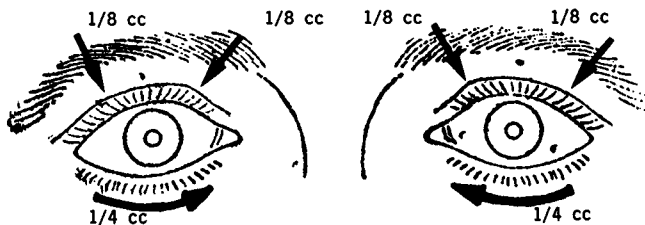


Fig. 1. Procedural notations in patient chart.

All patients had undergone medical therapy previously. Biofeedback had been tried by half of the patients without success. One patient had received five previous botulinum toxin injections at another institution. No patients had undergone surgery.

Twelve patients (21 eyes) were admitted to the study. Each participant underwent a complete eye examination. Nine patients had BEB, two had HFS, and one had Meige's syndrome. The female-to-male ratio was 2:1, and the age range was 61 to 77 years (average, 68 years). The patients lived in the western Pennsylvania and northern Ohio regions. The average duration of BEB was four years; the longest durations were 20 and 28 years. The degree of BEB was graded on a 0-to-4 system, noting both severity and frequency of spasm (*Table*).

Slides (35 mm) were obtained of all patients before and one week after the injection. Selected patients underwent video taping as well. Grading and administration of toxin were performed by two ophthalmologists.

During the ophthalmic examination, 6 patients were judged to require further workup. Six underwent neurologic examinations (four with BEB, one with HFS, and one with Meige's syndrome); the other six patients chose not to be tested neurologically. Five patients (four with BEB and one with Meige's syndrome) underwent a psychological workup that included an evalua-

tion and MMPI-CPI testing. Psychological testing was not done on one of the HFS patients since the neurologic work-up revealed the cause. The other patients were not tested psychologically because they wanted to proceed directly to injection treatment.

The initial dose of botulinum toxin was injected into each lid according to the method described by Frueh et al.² All injections were administered with a 1-mL tuberculin syringe 3 mm from the lid margin in order to reach the orbicularis muscle. Upper lids were injected using a short 30-gauge needle. Half of the dose was placed in the medial third of the lid, and the remainder into the lateral third of the upper lid. Care was taken to spare the central third to avoid the levator and thus avoid the complication of ptosis, as shown by the procedural notations (*Fig. 1*). The lower lid was injected with a 25-gauge, 3.8-cm needle. All injections were given subcutaneously. The dose varied from 0.0025 μ g (6.25 units) per lid to 0.01 g (25 units) per lid (total, 0.01–0.04 μ g [25–100 units]) per patient. The dose per lid was selected using 0.0025 μ g for the first injection, 0.005 μ g for the second injection, and 0.01 μ g for the third and all subsequent injections.

All patients were checked one to two weeks after the injection and thereafter at one- to two-month intervals. The blepharospasm was graded at each follow-up visit. Vision and slit-lamp findings were noted as well.

Results

The neurological examination of the six patients revealed no other abnormalities. The cause of the blepharospasm was deemed to be essential in four instances. HFS was diagnosed in one other case and Meige's syndrome in the other.

The psychological evaluation of five patients revealed several common characteristics. Nearly all could be described as nonassertive, dependent, emotionally over-controlled people who were prone to internalize and/or repress their feelings to an above-average degree. Most possessed high personal standards and also showed evidence of above-average somatic concern. Nearly all described themselves as having to render unusually large amounts of care to others (e.g., taking care of an ailing mother). Further evaluation revealed that they believed they had received inadequate appreciation for their ef-

Table. Severity of blepharospasm

0	None
1	Increased blinking caused by external stimuli
2	Mild but spontaneous eyelid fluttering
3	Moderate spasm of lids; mildly incapacitating
4	Spasm of eyelids and possibly other facial muscles; severely incapacitating

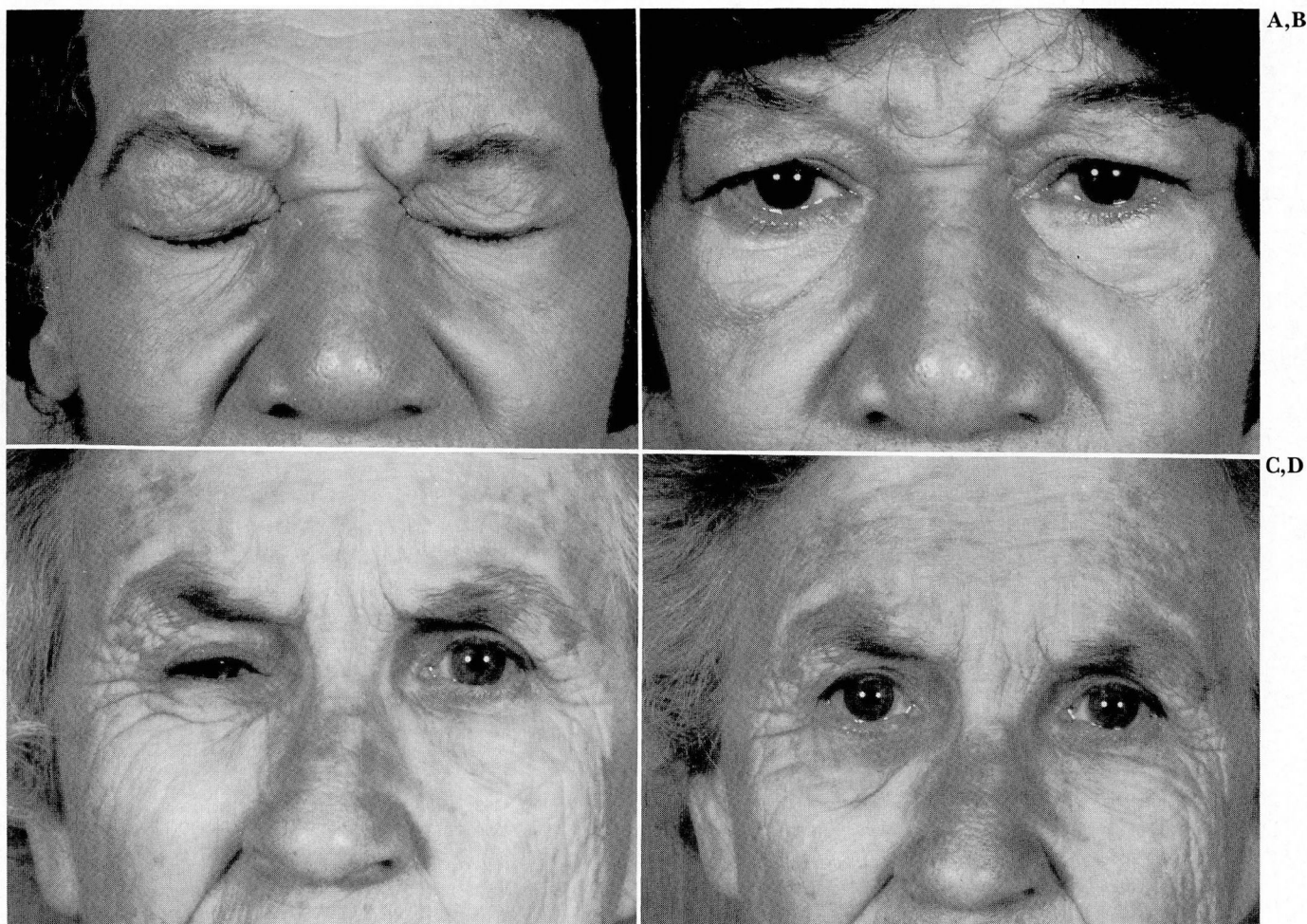

Fig. 2. Patient with benign essential blepharospasm before (A) and one week after injection (B), as well as a patient with hemifacial spasm before (C) and one week after injection (D).

forts, although they had not voiced their complaint directly to the one for whom they were caring. All five patients were thought to have significant personality disorders described as dependent profiles, resulting in secondary gain.

After injection with botulinum toxin, all 12 patients responded to some degree. The maximal therapeutic effect occurred after three days (*Fig. 2*). The nine patients with BEB and the one with Meige's syndrome achieved an average decrease in severity by 2 gradations (range, 2–4 gradations). The changes involving the two patients with HFS were 2 and 3 gradations, respectively. One of the patients with HFS was so pleased with her result that she requested injection in the orbicularis oris as well. Three to four days after

that injection, she noted decreased facial spasm and clearer speech.

Three of the 5 patients with significant personality disorders continued to display episodes of spasm, although diminished to gradation 1, while at the Cleveland Clinic. In one case, family members remarked that the patient's blepharospasm increased at home when the patient desired attention.

Patients noted a decrease in spasm for approximately 60 to 90 days, after which further injections were administered upon patient request. Nine patients chose to have repeat injections.

Complications included transient blepharoptosis (*Fig. 3*) in two patients and mild exposure keratopathy in one. The one patient who had six

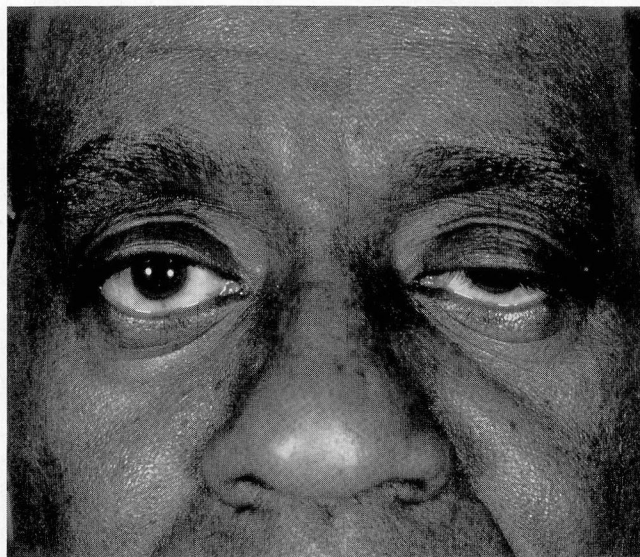


Fig. 3. A complication. Ptosis developed one week after injection.

injections at another institution described a hypertropia after the final injection, presumably by diffusion of toxin into the superior rectus muscle. The tropia resolved with no residual effect prior to his evaluation at the Cleveland Clinic. Patients with dry-eye symptoms were treated with natural tear substitutes.

Discussion

BEB is a forceful, involuntary bilateral contraction of the orbicularis oculi and surrounding periorbital musculature. This results in spasmodic bilateral blinking which occurs intermittently.

The pathogenesis is not known. Jankovic and Ford³ suspect a central dopaminic activity in the middle brain and basal ganglia. Others believe the cause is functional.^{4,5}

Jankovic and Orman⁶ found that on the average patients were in their 40s or 50s when BEB developed. Females were affected more frequently than males (3:1).

When BEB is accompanied by a myodystonia of the orbicularis oris and adjacent facial musculature, the entity is termed Meige's syndrome. Also, blepharospasm must be differentiated from tardive dyskinesia which consists of difficulty in performing voluntary movements, habit mannerisms (repetitive characteristic movements), and

facial tics (sometimes unilateral involuntary twitching of the facial musculature). Any condition producing photophobia (e.g., uveitis) may cause reflex blepharospasm,⁷ which is not considered BEB because there is a clear-cut cause for the rapid blinking pattern.

HFS is a different entity that involves the entire unilateral facial nerve distribution, including orbicularis oculi and oris. HFS results from vascular compression of the facial nerve near the brainstem that, in turn, stimulates the motor branch of the cranial nerve, causing a paroxysmal hyperkinesia, or constant twitch, of the facial nerve.

The blepharospasmodic condition generally progresses until the patient's simple daily activities, such as reading, writing, driving, and walking, are severely compromised. When eyelid closure becomes prolonged, the patient usually seeks medical attention. To date, treatment of blepharospasm has been tried by various medical, psychological, and surgical means. Drugs that block catecholamine synthesis or dopamine receptors, deplete central nervous system monoamines, or increase central cholinergic tone have been used with variable success. Clonazepam and amantadine have been used at the Cleveland Clinic with improvement noted in only a few cases. Electromyographic biofeedback has been employed to bring about the voluntary control of specific muscles and has been used with some positive results, as reported by Surwitt and Rotberg.⁸ Surgical methods have included selective dissection and avulsion of the facial nerve⁹ and a technique of eyelid protractor extirpation introduced by Gillum and Anderson.¹⁰ Surgical complications of selective neurectomy include lower lid ectropion, epiphora, dermatochalasis, and exposure keratopathy. The eyelid protractor extirpation procedure may result in lateral canthal deformity, corneal erosion, and partial necrosis of upper eyelid skin.

Since 1976, Scott¹ has been using injections of botulinum A toxin to weaken extraocular muscles. He began by injecting minute amounts of toxin into the horizontal recti of monkeys, achieving a paralysis lasting from weeks to months. The organism *Clostridium botulinum* produces the neurotoxin from which eight immunologic strains have been isolated (A, B, C1, C2, D, E, F, G).¹¹ Botulinum A is a single-chain polypeptide with a molecular weight of 900,000 daltons. The toxin inhibits conduction in the

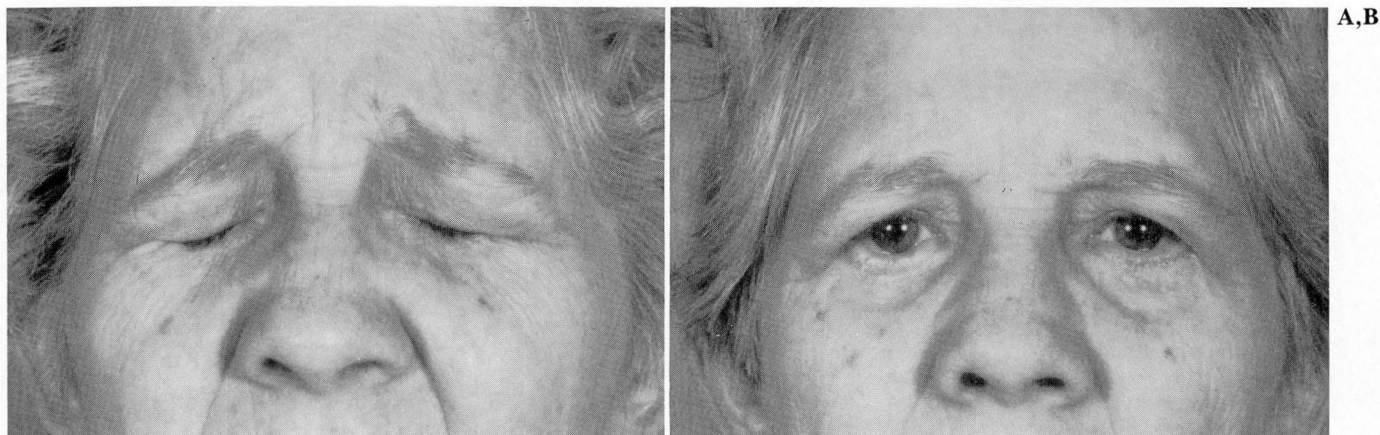

Fig. 4. Patient with blepharospasm, thought to be deriving secondary gain from her condition, before (A) and one week after injection (B).

peripheral nerves by presynaptic blockade. Calcium ion metabolism is disrupted in the nerve terminal, preventing acetylcholine release. The action of the toxin involves three steps in the nerve terminal. First, it binds to a specific cell surface receptor on the terminal. Second, a possible absorptive pinocytosis or channel formation develops. Third, transmission is blocked. When ingested, botulinum A causes systemic neurologic symptoms that include lethargy, nausea, vomiting, generalized muscular weakness, and respiratory paralysis. Visual disturbances include paralysis of accommodation, diplopia, ptosis, and ophthalmoplegia. Based on his studies, Scott¹ estimated that the lethal dose in humans was 2 μ g.

Recent Federal Drug Administration guidelines have made possible the study of botulinum toxin injections for the treatment of BEB at a number of centers around the country. In 1985, we investigated botulinum toxin therapy for both BEB and HFS, expanding the parameters previously studied to include selected neurological and psychological examinations.

We noted improvement in the severity of BEB lasting between two and three months. Other authors have reported similar data.^{2,12-16} Most of their patients improved by 2 gradations of spasm severity. The treatment took effect two to three days after the injection and lasted an average of three months. These other studies, however, grouped BEB and HFS together in the results and neither neurological nor psychological screening of the patients was mentioned.

Psychological evaluation of five of our patients

showed that BEB symptoms appeared either during or soon after periods of considerable stress. Although most patients admitted that nervousness and stress tended to aggravate their symptoms, all but one showed remarkably little insight regarding the probable role of psychological factors. Additionally, development of BEB typically resulted in a significant secondary gain. For example, one patient (Fig. 4), because of her restricted vision, could no longer perform her excessive caregiving role and her dependency needs tended to be met more fully. These findings are in general agreement with others who have reported a significant functional dimension to BEB.^{3,4}

By identifying psychological and ruling out neurological factors, the most appropriate form of treatment might be selected, whether it be psychotherapy or botulinum toxin injection, or a combination of both.

Acknowledgments

We would like to thank the Ophthalmology Photography Department, Mary Kay Ciechanski, R.N., Alice Good, and Louise A. Berlin for their assistance in this project and in the preparation of this manuscript.

A. Jan Berlin, M.D.
Department of Ophthalmology
The Cleveland Clinic Foundation
9500 Euclid Avenue
Cleveland, OH 44106

References

1. Scott AB. Botulinum toxin injection of eye muscles to correct strabismus. *Trans Am Ophthalmol Soc* 1981; **LXXIX**: 734-770.
2. Frueh BR, Felt DP, Wojno TH, Musch DC. Treatment of blepharospasm with botulinum toxin. *Am J Ophthalmol* 1985; **99**:176-179.
3. Jankovic J, Ford J. Blepharospasm and orofacial-cervical dystonia: clinic and pharmacological findings in 100 patients. *Ann Neurol* 1983; **13**:402-411.
4. Cavenar JO, Brantley IJ, Braasch E. Blepharospasm: organic or functional? *Psychosomatics* 1978; **19**:623-628.
5. Diamond EL, Trobe JD, Belar CD. Psychological aspects of essential blepharospasm. *J Nerv Ment Dis* 1984; **172**:749-756.
6. Jankovic J, Orman J. Blepharospasm: demographic and clinical survey of 250 patients. *Ann Ophthalmol* 1984; **16**:371-376.
7. Jankovic J, Havins WE, Wilkins RB. Blinking and blepharospasm: mechanism, diagnosis, and management. *JAMA* 1982; **248**:3160-3164.
8. Surwit RS, Rotberg M. Biofeedback therapy of essential blepharospasm. *Am J Ophthalmol* 1984; **98**:28-31.
9. Frueh BR, Callahan A, Dortzbach RK, et al. The effects of differential section of the viith nerve on patients with intractable blepharospasm. *Trans Am Acad Ophthalmol Otolaryngol* 1976; **81**:OP-595-OP-602.
10. Gillum WN, Anderson RL. Blepharospasm surgery: an anatomical approach. *Arch Ophthalmol* 1981; **99**:1056-1062.
11. Rowell DP. Botulism. Delivered at a seminar held at the University of Iowa, 1983.
12. Tsoy EA, Buckley EG, Dutton JJ. Treatment of blepharospasm with botulinum toxin. *Am. J Ophthalmol* 1985; **99**:176-179.
13. Scott AB, Kennedy RA, Stubbs HA. Botulinum A toxin injection as a treatment for blepharospasm. *Arch Ophthalmol* 1985; **103**:347-350.
14. Shorr N, Seiff SR, Kopelman J. The use of botulinum toxin in blepharospasm. *Am J Ophthalmol* 1985; **99**:542-546.
15. Lingua RW. Sequelae of botulinum toxin injection. *Am J Ophthalmol* 1985; **100**:305-307.
16. Magoon EH. Botulinum injection for treatment of blepharospasm, corneal exposure, and entropion. *J Ocul Ther Surg* 1985; **4**:133-135.