

Adult linear IgA disease associated with an erythema multiforme-like drug reaction¹

Zsolt B. Argenyi, M.D.
Wilma F. Bergfeld, M.D.
Rafael Valenzuela, M.D.
James T. McMahon, Ph.D.
James S. Taylor, M.D.

The authors describe a 58-year-old woman who experienced an erythema multiforme-like reaction following therapy with cefamandole naftate. Histologically, findings were consistent with erythema multiforme, but diffuse linear deposition of IgA was demonstrated at the dermo-epidermal junction by direct immunofluorescence. Ultrastructurally, deposits were located beneath the basal lamina, around the anchoring fibrils. These observations illustrate that adult linear IgA bullous dermatosis can mimic the clinical and histological features of erythema multiforme and suggest the possibility of drug-induced pathogenesis.

Index term: Skin diseases, chemically induced

Cleve Clin J Med 54:445-450, Sep/Oct 1987

Linear IgA bullous dermatosis (LABD)¹ clinically and histologically resembles bullous pemphigoid or dermatitis herpetiformis.²⁻⁹ The diagnostic finding, based on a direct immunofluorescence examination, is the linear homogenous deposition of IgA at the dermo-epidermal junction.² Ultrastructurally, the IgA deposits may be

located in the lamina lucida, below the lamina densa around the anchoring fibrils, or simultaneously at both sites.¹⁰⁻¹² Additional features of LABD are the rare occurrence of IgA ant basement membrane antibodies,^{13,14} the absence or low incidence of gluten-sensitive enteropathy,^{2,15-18} and the relatively low incidence of HLA-B8 antigen.^{2,15,17,18} Although LABD has been associated with several diseases,¹⁹⁻²² we found only two cases in the literature where a drug-induced etiology had been mentioned.^{23,24} We report an unusual clinical and histological presentation of linear IgA disease in a patient and its possible relationship to cefamandole naftate therapy.

Case report

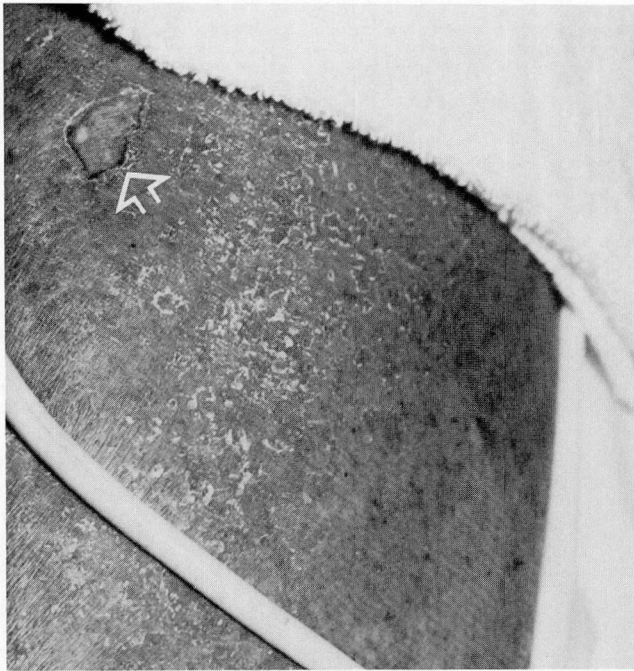A 58-year-old black woman had a five-year history of eczematous dermatitis treated by topical and oral corticosteroids (methyl prednisolone, 8 mg/day) and a known allergy to penicillin and sulfonamides. She was admitted to a local hospital for treatment of a bleeding duodenal ulcer and a fever of unknown origin. Treatment using cefamandole naftate (500 mg, four times a day) was started. Three days later, red and tender plaques appeared; some had evolved into large flaccid bullae. The patient was subsequently transferred to the Cleveland Clinic for surgical treatment of the bleeding ulcers. By this time, generalized erythema, with slightly scaling plaques and islands of sparing on the limbs, had developed. No iris-like lesions were seen, but there were scattered recent blisters. Large bullae in the popliteal fossae and on the thigh near the inguinal area were evident (*Fig. 1*). No mucosal lesions were seen. During the first few days of her hospitalization, new vesicles appeared in the popliteal fossa and on the inner thigh. Our initial impression was that the patient had an erythema multiforme-like drug reaction developing on pre-existing chronic eczematous dermatitis.

¹ Departments of Pathology and Dermatology, University of Iowa Hospitals and Clinics (Z.B.A.), Departments of Dermatology (W.F.B., J.S.T.) and Pathology (R.V., J.T.M.), The Cleveland Clinic Foundation. Submitted for publication Feb 1987; accepted May 1987.

Presented in part at the Forty-third Annual Meeting of the American Academy of Dermatology in Washington, D.C., December 1984.

0891-1150/87/05/0445/06/\$2.50/0

Copyright © 1987, The Cleveland Clinic Foundation



← **Fig. 1.** Extensive exfoliative erythroderma, involving the extremities. The base of the bulla is present on the upper medial aspect of the left thigh (arrow).

Administration of parenteral steroids (methyl prednisolone sodium succinate, 100 mg twice a day) was begun.

Materials and methods

Four-millimeter punch biopsy specimens were obtained from lesional and perilesional sites. The lesional skin specimen was processed for light and electron microscopy, and the perilesional specimen for routine light microscopy, direct immunofluorescence, and immunoelectron microscopy. Tissue submitted for light microscopy was fixed in 10% buffered formalin and subsequently stained with hematoxylin and eosin. For direct immunofluorescent examination, 4- μ m unfixed frozen cryostat sections were stained with FITC-labeled goat antihuman IgG, IgA, IgM, C₃, and fibrinogen according to our standard laboratory procedures. Electron microscopic studies were

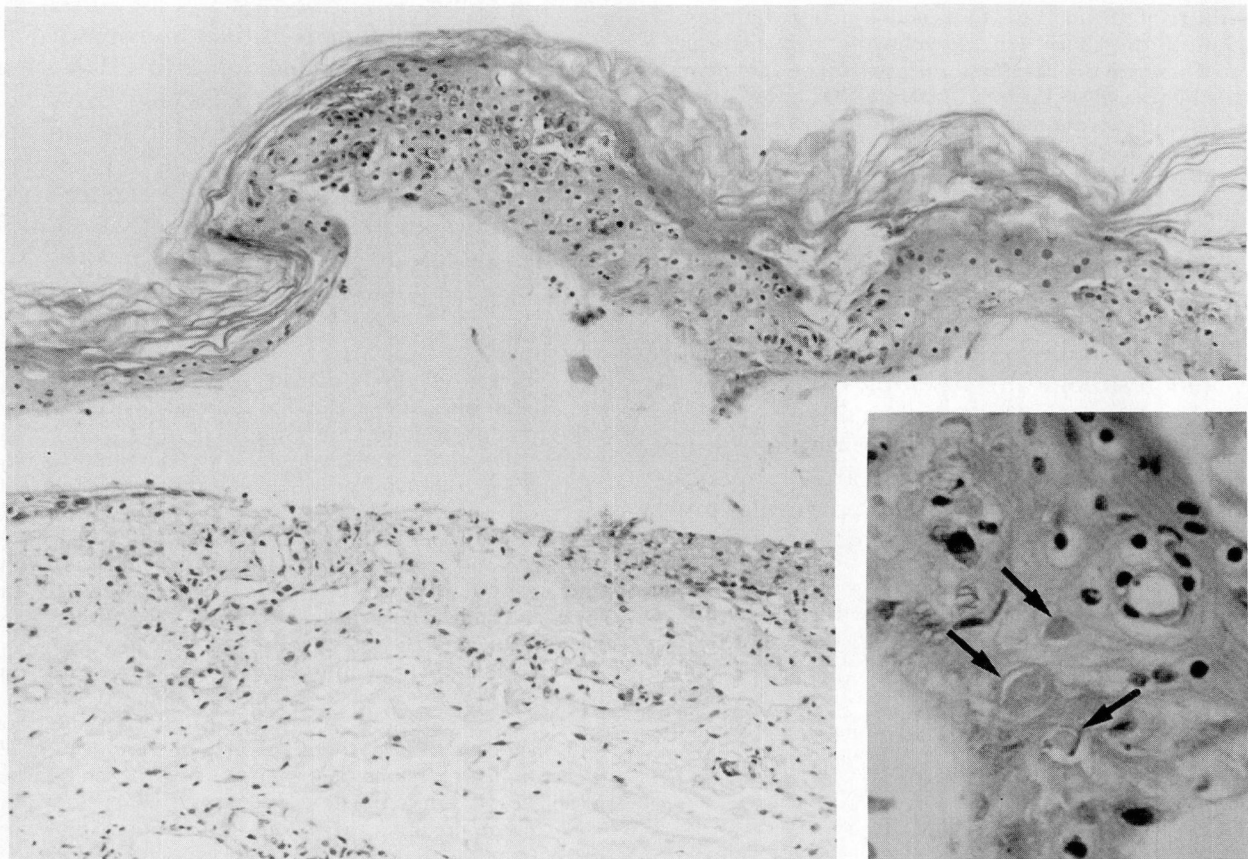


Fig. 2. Micrograph of a lesional biopsy specimen, showing subepidermal bulla and scant upper dermal lymphohistiocytic infiltrate (hematoxylin-eosin, $\times 100$). Inset: Occasional necrotic keratinocytes in the epidermis (arrows) (hematoxylin-eosin, $\times 500$).

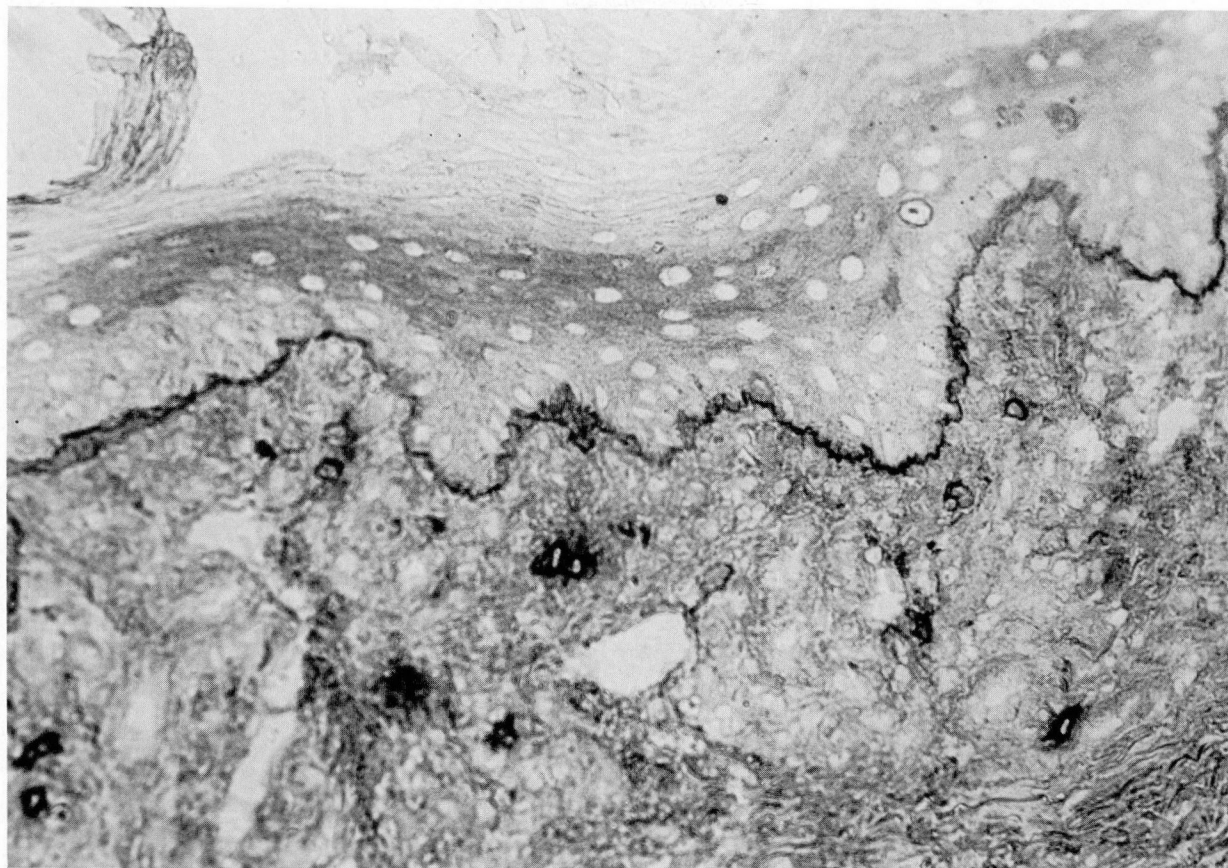


Fig. 3. Immunoperoxidase reaction of perilesional skin, demonstrating in vivo-bound IgA, linearly deposited along the dermo-epidermal junction ($\times 350$).

performed on formalin-fixed material with postfixation in osmium tetroxide and embedment in epoxy resin. Thin sections were stained with uranyl acetate and lead citrate and examined with a Philips 400 electron microscope.

For immunoelectron microscopy, 5- μm sections of snap-frozen biopsy material from a perilesional site were incubated with horseradish peroxidase-labeled antihuman IgA for 30 minutes, followed by rinses in phosphate-buffered solution. The color reaction was developed with a diaminobenzidine chromogen/hydrogen peroxide medium. Subsequently, the tissue was osmicated and dehydrated according to the standard protocol, followed by embedment in epoxy resin for electron microscopic processing. Ultrathin sections were examined with and without staining.

Histopathologic studies

A biopsy specimen of a lesion demonstrated the presence of an extensive subepidermal bulla with several apoptotic cells in the epidermis (*Fig.*

2), and focal areas of full-thickness eosinophilic necrosis of the epidermis. The bulla contained only a few degenerated and mononuclear cells, with minimal fibrin at the base. A mild perivascular lymphohistiocytic infiltrate was present in the dermis, and the papillary dermis was markedly edematous. A biopsy specimen of perilesional skin showed occasional necrotic keratinocytes in the epidermis, and vacuolar alteration of the dermo-epidermal junction with few lymphocytes. The dermis contained a sparse superficial perivascular lymphohistiocytic infiltrate. These features are diagnostic of the mixed type of erythema multiforme.

Direct immunofluorescent examination of the perilesional biopsy specimens demonstrated diffuse linear deposition of IgA (3+) and fibrin (2+) along the dermo-epidermal junction. Focal globular deposits of IgM (1+) and fibrin (1+) were also present in the papillary dermis. This pattern was confirmed by immunoperoxidase technique (*Fig. 3*). No indirect immunofluorescent studies were performed.

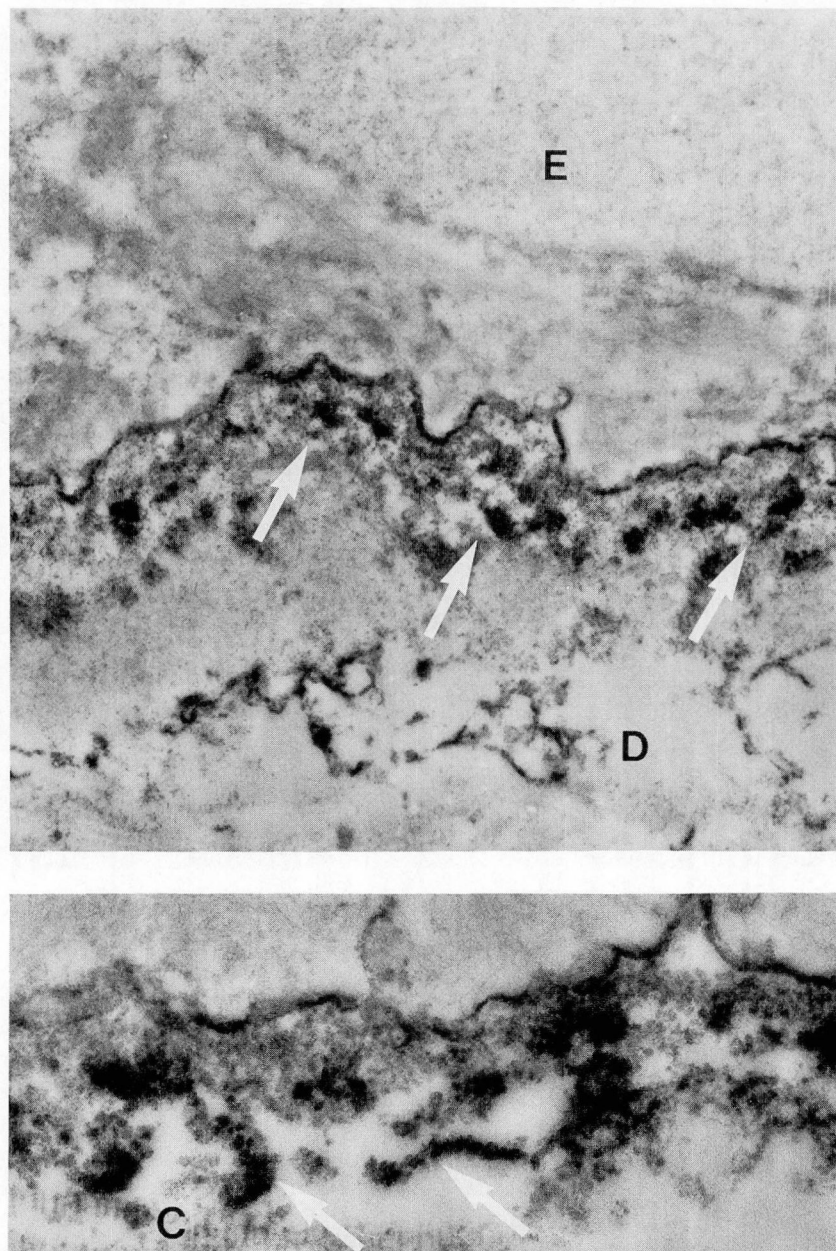


Fig. 4. Immunoelectron microscopic image of perilesional specimen. Coarse clumps of immunoreactants (white arrows) are located along and beneath the basal lamina. *E* = epidermis and *D* = dermis (unstained, $\times 15,000$). Inset: High magnification demonstrates the intimate relationship of the immunoreactants around the anchoring fibrils (arrows). *C* = collagen (unstained, $\times 36,000$).

Transmission electron microscopic examination of the lesional biopsy specimen reclaimed from paraffin-embedded tissue revealed separation beneath the basal lamina. The overlying basal keratinocytes had intact intercellular attachments and hemidesmosomes. The intracytoplasmic preservation was suboptimal.

By immunoelectron microscopic examination,

the IgA deposits were localized just beneath the basement membrane. They appeared to be aggregated around the anchoring fibrils (*Fig. 4*). Based on the immunofluorescence and immunoelectron microscopic findings, the diagnosis of adult LABD was made.

Over the next few days, the severity of the patient's eruption lessened, with the absence of

vesicle formation and decreased exudation. However, the patient died of postoperative complications.

Discussion

Our case meets the criteria of LABD as defined by Chorzelski et al,¹ but also has two additional interesting features: (1) erythema multiforme-like clinical and histological manifestation, and (2) a possible relationship with drug (cefamandole naftate) therapy.

Since at the time of her admission the drug therapy had been stopped and our patient had been taking systemic steroids, the skin showed a later stage in the development of erythema multiforme combined with the features of the pre-existing chronic eczema. Although no iris-like lesions were present, the overall clinical picture was quite compatible with an erythema multiforme-like drug reaction. The literature contains only one previous report of an erythema multiforme-like presentation of LABD.²⁵

Histologically, the picture of a subepidermal bulla with several apoptotic cells and relatively scant upper dermal lymphohistiocytic infiltrate, as found in this case, is classical of bullous erythema multiforme. There was no evidence of papillary microabscesses, neutrophils at the rete tips, or eosinophils in the bulla fluid.

LABD has an obscure pathogenesis. There have been several case reports in which LABD was associated with various diseases, including atopic eczema,¹⁹ Hodgkin's disease,²⁰ lupus erythematosus,²¹ and chronic active hepatitis.²² We found only two cases in the literature where a drug-induced pathomechanism was considered.^{23,24}

In our case, the manifestation of an erythema multiforme-like drug reaction appeared directly related to cefamandole naftate therapy. Cefamandole naftate, a semisynthetic broad-spectrum cephalosporin antibiotic, can result in cutaneous side effects such as hypersensitivity, urticaria, anaphylaxis, and maculopapular rash. At the time of admission, there was no other reasonable alternative explanation for the patient's skin eruption. The timing of the eruption correlated well with the drug exposure, and there was a response to the removal of the suspect agent. A rechallenge test was not possible because the patient had died. Dapsone, the drug of choice in LABD, could not be introduced for the same reason. (Although it is a sulfone drug, no cross-reaction with the sulfonamides has been reported.)

While the timing and course suggest a drug etiology, the possibility exists that the relationship between drug exposure and development of LABD may have been merely coincidental. The patient may have had preexisting LABD that was either coexistent with chronic eczema or had been modified and suppressed by the continuous steroid therapy.

In summary, this is a case of LABD with a possible drug-induced pathogenesis and erythema multiforme-like clinical and histological features. The variable clinical and histological presentation of LABD in this and other patients requires consideration of such a diagnosis in atypical presentations of bullous diseases and emphasizes the importance of direct immunofluorescence studies.

Zsolt Argenyi, M.D.
Department of Pathology
University of Iowa Hospitals and Clinics
5244D Roy Carver Pavilion
Iowa City, IA 52242

References

1. Chorzelski TP, Jablonska S, Beutner EH. Linear IgA bullous dermatosis. [In] Beutner EH, Chorzelski TP, Bean SF, eds, *Immunopathology of the Skin*. New York, Wiley & Sons, 1979, pp 315-323.
2. Leonard JN, Haffenden GP, Ring NP, et al. Linear IgA disease in adults. *Br J Dermatol* 1982; **107**:301-316.
3. Jones RR, Goolamali SK. IgA bullous pemphigoid: a distinct blistering disorder: case report and review of the literature. *Br J Dermatol* 1980; **102**:719-725.
4. Davies MG, Eady RA. Bullous pemphigoid with linear basement membrane zone IgA. *Clin Exp Dermatol* 1980; **5**:79-83.
5. Provost TT, Maize JC, Ahmed AR, Straus JS, Dobson RL. Unusual sub-epidermal bullous diseases with immunological features of bullous pemphigoid. *Arch Dermatol* 1979; **115**:156-160.
6. van Joost T, Faber WR, Westerhof W, de Mari F. Linear dermo-epidermal IgA deposition in bullous pemphigoid. *Acta Derm Venereol (Stockh)* 1979; **59**:463-465.
7. Jablonska S, Chorzelski TP, Beutner EH, Maciejowska E, Rzaea G. Dermatitis herpetiformis and bullous pemphigoid. *Arch Dermatol* 1976; **112**:45-48.
8. Honeyman JF, Honeyman AR, De la Parra MA, Pinto A, Eguiguren GJ. Polymorphic pemphigoid. *Arch Dermatol* 1979; **115**:423-427.
9. Blenkinsopp WK, Haffenden GP, Fry L, Leonard JN. Histology of linear IgA disease, dermatitis herpetiformis and bullous pemphigoid. *Am J Dermatopathol* 1983; **5**:547-554.
10. Yaoita H, Hertz KC, Katz SI. Dermatitis herpetiformis: immunoelectronmicroscopic and ultrastructural studies of a patient with linear deposition of IgA. *J Invest Dermatol* 1976; **67**:691-695.
11. Yaoita H, Katz SI. Immunoelectron microscopic localization

- of IgA in the skin of patients with dermatitis herpetiformis. *J Invest Dermatol* 1976;**67**:502–506.
12. Dabrowski J, Chorzelski TP, Jablonska S, Krainska T, Jarzabek-Chorzelska M. The ultrastructural localization of IgA in skin of a patient with mixed form of dermatitis herpetiformis and bullous pemphigoid. *J Invest Dermatol* 1978;**70**:76–79.
 13. Pehamberger H, Konrad K, Holubar K. Circulating IgA anti-basement membrane antibodies in linear dermatitis herpetiformis (Dühring): immunofluorescence and immunoelectronmicroscopic studies. *J Invest Dermatol* 1977;**69**:490–493.
 14. Pehamberger H, Gschnait F, Konrad K, Holubar K. Bullous pemphigoid, herpes gestationis and linear dermatitis herpetiformis: circulating anti-basement membrane zone antibodies; *in vivo* studies. *J Invest Dermatol* 1980;**74**:105–108.
 15. Leonard JN, Haffenden GP, Ring N, Fry L. Ultrastructural localization of IgA deposits in adult linear IgA disease. *J R Soc Med* 1982;**75**:237–241.
 16. deFranchis R, Primignani M, Cipolla M, et al. Small-bowel involvement in dermatitis herpetiformis and in linear-IgA bullous dermatosis. *J Clin Gastroenterol* 1983;**5**:429–436.
 17. Mobacken H, Kastrup W, Ljunghall K, et al. Linear IgA dermatosis: a study of ten adult patients. *Acta Derm Venereol (Stockh)* 1983;**63**:123–128.
 18. Lawley TJ, Strober W, Yaoita H, Katz SI. Small intestinal biopsies and HLA types in dermatitis herpetiformis patients with granular and linear IgA skin deposits. *J Invest Dermatol* 1980;**74**:9–12.
 19. Leroy D, Michel M, Leport Y, Deschanmps P. Association d'un eczéma atopique, d'une dermatose bulleuse à IgA linéaire et d'une gale croûteuse. *Ann Dermatol Venereol* 1980;**107**:933–936.
 20. Kienzler JL, Blanc D, Laurent R, Agache P. Dermatose bulleuse à IgA linéaire et maladie de Hodgkin. *Ann Dermatol Venereol* 1983;**110**:727–728.
 21. Thaipisuttikul Y, Piamphongsant T, Suwanwela N. Coexistence of linear IgA dermatitis herpetiformis and systemic lupus erythematosus. *J Dermatol (Tokyo)* 1983;**10**:161–166.
 22. Oranje AP, Vuzevski VD, Bouquet J, Sinaasappel M, van Joost T, Stolz E. Linear IgA disease and chronic active hepatitis—a coincidence or not? *Acta Derm Venereol (Stockh)* 1985;**65**:440–442.
 23. Gabrielsen TØ, Stærfløt F, Thune PO. Drug-induced bullous dermatosis with linear IgA deposits along the basement membrane. *Acta Derm Venereol (Stockh)* 1981;**61**:439–441.
 24. Sekula SA, Tschén JA, Bean SF, Wolf JE Jr. Linear IgA bullous disease in a patient with transitional cell carcinoma of the bladder. *Cutis* 1986;**38**:354–356.
 25. Argenyi Z, Bergfeld WF, Valenzuela R, et al. Linear bullous dermatosis mimicking erythema multiforme in adult. *Int J Dermat (in press)*.