

# Scimitar syndrome

## Its diagnosis by digital subtraction angiography and an anatomical review

David E. Gossman, MD  
Douglas S. Moodie, MD  
Carl C. Gill, MD  
Richard Sterba, MD

A case of scimitar syndrome is used to demonstrate the application of digital subtraction angiography in the diagnosis of anomalous pulmonary venous drainage. The authors also review the literature on scimitar syndrome.

**Index terms:** Angiography • Radiographic image enhancement • Scimitar syndrome

**Cleve Clin J Med** 1987; 54:510-512

The use of intravenous digital subtraction angiography (DSA) to evaluate pulmonary venous abnormalities has been described.<sup>1,2</sup> However, the usefulness of DSA in evaluating patients with the scimitar syndrome has not, to our knowledge, been reported. We present the first report of scimitar syndrome diagnosed in such a manner. A review of the literature on scimitar syndrome follows.

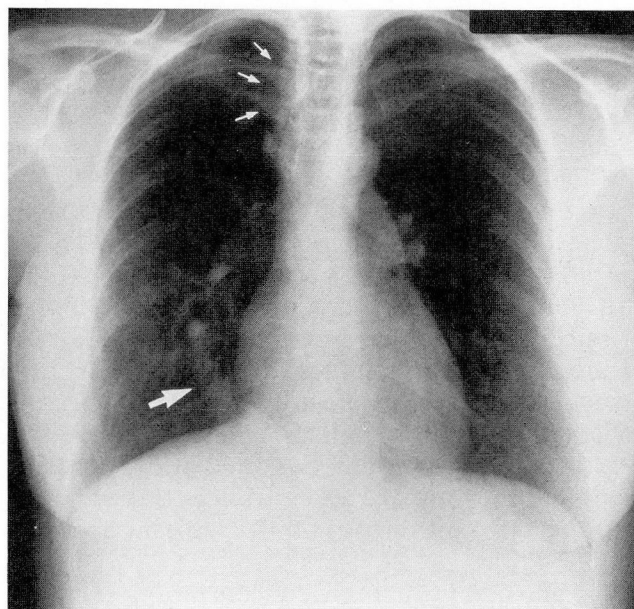
### Case Report

A 36-year-old woman was evaluated for hemoptysis and dyspnea. Her physical examination disclosed a widely fixed splitting of S2, with a normal P2 component, and a grade

Departments of Cardiology (D.E.G., D.S.M., R.S.) and Thoracic and Cardiovascular Surgery (C.C.G.), The Cleveland Clinic Foundation. Submitted for publication Dec 1986; accepted March 1987.

0891-1150/87/06/0510/03/\$1.75/0

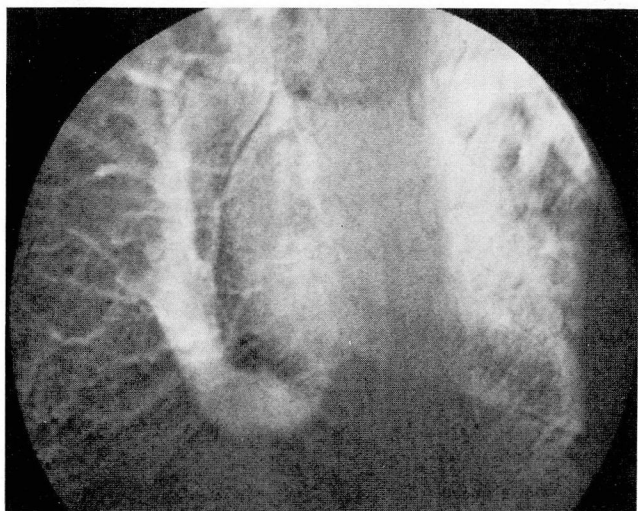
Copyright © 1987, The Cleveland Clinic Foundation



**Fig. 1.** Preoperative chest radiograph demonstrating the scimitar sign (large arrow). Associated azygous lobe is also present (small arrows).

II systolic ejection murmur at the left lower sternal edge radiating to the left upper sternal edge. The remainder of the physical examination was normal. The chest radiograph showed a crescent-shaped shadow in the right lower lung field running parallel to the right heart border; an azygous lobe was present (*Fig. 1*). The ECG was normal and without evidence of right ventricular hypertrophy. The right side of the heart was catheterized, demonstrating an oxygenation step-up of 72-84% from the low inferior vena cava to the junction of the inferior cava and right atrium. There was





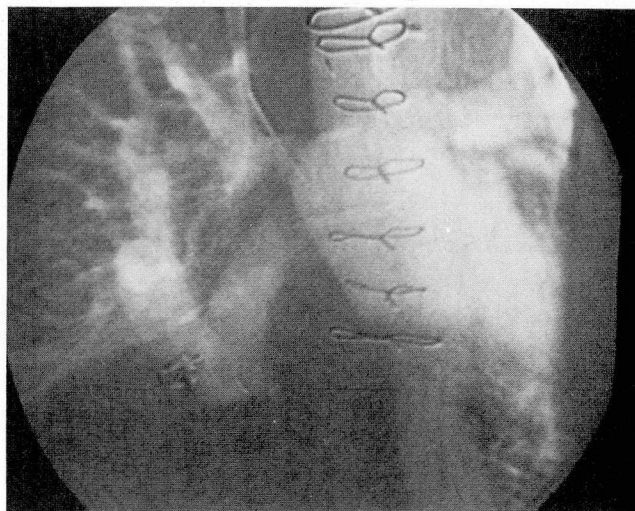
**Fig. 2.** Preoperative intravenous DSA demonstrating partial anomalous venous return to the inferior vena cava.

no further step-up within the right atrial or ventricular chambers. The following hemodynamic pressures were recorded: right atrium, 6 mm Hg; right ventricle (systolic), 24 mm Hg; pulmonary artery, 24/11 mm Hg; pulmonary capillary wedge, 10 mm Hg; left ventricle 135/10 mm Hg; aorta, 135/98 mm Hg; cardiac index, 4.4 l/min/m<sup>2</sup>; pulmonary vascular resistance, 45 dynes·secs·cm<sup>-5</sup>. Systemic vascular resistance was 1120 dynes·secs·cm<sup>-5</sup> and the QP:QS ratio was 1.5:1. The left ventriculogram did not reveal a ventricular septal defect, and left ventricular function was normal. Bronchoscopy revealed no cause of hemoptysis. The echocardiogram was normal, showing no evidence of right ventricular overload and normal chamber sizes.

## Methods

Intravenous DSA was performed using the percutaneous technique from the right basilic vein. Forty milliliters of meglumine diatrizoate were injected into the superior vena cava through an NIH catheter at 15 mL/sec. Angiographic images were obtained in the anteroposterior projection, using a commercial digital subtraction angiographic unit. As is standard in our laboratory, a single mask was used at 80 kV with an 8-mA/frame at 6 frames/sec. The image matrix size was 256 × 256 pixels and 256 shades of gray. The data were stored on digital disc for immediate viewing of subtracted images and postprocessing, then later transferred to digital tape and conventional radiographic film for viewing and filing.

Anomalous pulmonary venous drainage was demonstrated from the right middle and right lower lobes to the inferior vena cava below the level of the diaphragm (Fig. 2). The right upper lobe appeared to drain normally into the left atrium. No hypoplastic changes of the pulmonary



**Fig. 3.** Postoperative DSA demonstrating surgical correction of the anomalous pulmonary veins.

arteries were noted. The right ventricular cavity was slightly elongated and hypertrophic. The left ventricle was normal. Septal integrity of the atria and ventricles was demonstrated.

At surgery, a large common vein draining the lower portions of the right lung was found which passed through the diaphragm, where it received venous branches from the liver before entering the inferior vena cava. A small pulmonary vein drained the right upper lobe into the left atrium. The right atrium and ventricle were found to be moderately enlarged. The remainder of the heart appeared normal. The aberrant pulmonary vein was dissected free and ligated distally. An 18-mm Gore-Tex (W. L. Gore Associates, Newark, DE) conduit was sewn between the anomalous vein and left atrium. A second DSA study was performed on the first postoperative day, demonstrating a patent conduit draining to the left atrium (Fig. 3).

## Discussion

### Digital subtraction imaging

The application of digital imaging is rapidly expanding. We have already described its use in other forms of pulmonary venous anomalies.<sup>1</sup> This case report demonstrates its application in diagnosing and defining the scimitar syndrome. This diagnostic modality offers several advantages over conventional angiography. Subtraction of unnecessary background images permits improved anatomic definition. Less total radiation is used, 2–3 cGy versus 20 cGy for conventional angiography. Although 40 mL of contrast

material was used for our patient, a smaller volume may be used with reasonable results. This material may be injected into a peripheral vein, keeping the catheter position extracardiac, thus allowing the procedure to be done on an outpatient basis.<sup>6</sup>

### *Scimitar syndrome*

Scimitar syndrome is a rare pathological subset of anomalous pulmonary drainage, wherein oxygenated blood from the right lung drains into the inferior vena cava. Anatomical variants and associated congenital heart defects can be expected, which would alter the surgical repair; therefore, a preoperative study is essential.

Farnsworth and Ankeney and Kiely et al discuss these anatomical variations in detail.<sup>3,4</sup> These variants can be divided into five categories: 1) abnormal pulmonary venous drainage patterns, 2) abnormal pulmonary arterial supply, 3) bronchopulmonary segmentation abnormalities, 4) diaphragmatic anomalies, and 5) associated congenital heart defects.

A single anomalous venous channel most commonly drains the entire right lung as it runs parallel to the right heart border, eventually inserting below the diaphragm near the junction of the hepatic veins. It may, however, insert above the diaphragm. Portions of the right lung, especially the upper lobe, may drain normally into the left atrium; this occurred in eight of the 24 cases that Kiely et al reported.<sup>4</sup> This group also reported two parallel anomalous veins occurring in one of their 24 cases.

The pulmonary arterial supply may arise from the pulmonary artery, bronchial arteries, vessels originating on the thoracic aorta, and diaphragmatic or subdiaphragmatic sources (16 of 24 cases reported on by Kiely et al<sup>4</sup>). The pulmonary artery itself is hypoplastic in 60% of the cases; pulmonary artery ectasia has been described.<sup>5</sup>

The right lung is often hypoplastic, which accounts for the rightward displacement of the heart. This has been reported in 58% of the cases reviewed and reported on by Kiely et al.<sup>4</sup> Pulmonary segmentation abnormalities are commonly reported,<sup>3,4</sup> hyposegmentation being most frequent. Diverticular or cystic changes of the bronchi are often reported (21% in Kiely et al<sup>4</sup>).

Kiely et al<sup>4</sup> reported a 21% incidence of diaphragmatic abnormalities. The right hemidiaphragm may be elevated as a result of volume loss in the right lung. Herniation of the right lower lobe through the foramen of Bochdalek,

abnormal attachment of the right hemidiaphragm, and an accessory diaphragmatic leaf have all been described.<sup>4</sup>

Coexisting congenital heart defects have also been frequently described.<sup>4</sup> Of 67 cases, atrial septal defect was identified or suspected six times, patent ductus four, tetralogy of Fallot three, ventricular septal defect two, and coarctation of the aorta one.

Our patient demonstrated several features illustrative of scimitar syndrome: partial anomalous pulmonary venous drainage, an azygous lobe, and hemoptysis probably due to bronchiectatic changes. We were able to successfully define the anomalous venous drainage with digital imaging. We believe that this is the first time scimitar syndrome has been diagnosed with DSA.

Since anatomical variants and associated defects can be expected, and since these are very difficult to define intraoperatively, a precise preoperative study is essential. Prior success with DSA to define the anatomy of more common forms of anomalous venous drainage has been demonstrated.<sup>1,2</sup> We have now expanded its application to delineate the scimitar syndrome. DSA provides a diagnostic tool that can be used on an outpatient basis or in the early postoperative period to demonstrate patency of the repair. Images obtained provide useful anatomic information comparable to that obtained with conventional angiography.

Douglas S. Moodie, MD  
Department of Pediatric and Adolescent Medicine  
The Cleveland Clinic Foundation  
9500 Euclid Avenue  
Cleveland, Ohio 44106

### References

1. Haggman DL, Moodie DS, Sterba R, Gill CC. Intravenous digital subtraction angiography in the evaluation of systemic and pulmonary venous anomalies. *Cleve Clin Q* 1985; **52**:55–60.
2. Sider L, Fisher MR, Mintzer RA. The evaluation of partial anomalous pulmonary venous return with the use of digital subtraction angiography. *Chest* 1984; **86**:97–99.
3. Farnsworth AE, Ankeney JL. The spectrum of the scimitar syndrome. *J Thorac Cardiovasc Surg* 1974; **68**:37–42.
4. Kiely B, Fuller J, Stone S, Doyle EF. Syndrome of anomalous venous drainage of the right lung to the inferior vena cava: a review of 67 reported cases and three new cases in children. *Am J Cardiol* 1967; **20**:102–116.
5. Mathey J, Galey JJ, Logeais Y, et al. Anomalous pulmonary venous return into inferior vena cava and associated bronchovascular anomalies (the scimitar syndrome): report of three cases and review of the literature. *Thorax* 1968; **23**:398–407.
6. Moodie DS, Buonocore E, Yiannikas J, Gill CC, Pavlicek WA. Digital subtraction angiography in congenital heart disease in pediatric patients. *Cleve Clin Q* 1982; **49**:159–171.