

Intracranial meningioma metastatic to the lung

James K. Stoller, MD
Mani Kavuru, MD
Atul C. Mehta, MD
Cheryl E. Weinstein, MD
Melinda L. Estes, MD
Gordon N. Gephardt, MD

Although meningiomas only rarely metastasize, extracranial metastasis does occur and the lung is the most common site. To clarify the clinical spectrum of metastatic meningioma and to highlight its importance for the pulmonary physician, the authors describe one case and review 112 others. Metastatic meningioma should be considered in the differential diagnosis of the solitary pulmonary nodule, especially in patients with an associated intracranial mass.

Index terms: Case reports • Lung neoplasms, metastases • Meningioma

Cleve Clin J Med 1987; 54:521-527

Although meningiomas usually are benign intracranial tumors, unusual clinical presentations may occur, such as extracranial primary meningiomas^{1,2} (including primary lung tumors³), or extracranial metastases from intracranial primary tumors.⁴⁻⁶ Metastatic meningiomas are rare,^{4,7-9} as only 112 cases have been described since the first report by Power in 1886.¹⁰ We recently encountered a patient whose intracranial meningioma metastasized to the lung.

From the Departments of Pulmonary Disease (J.K.S., A.C.M.), Internal Medicine (M.K., C.E.W.), and Pathology (M.L.E., G.N.G.), The Cleveland Clinic Foundation. Submitted for publication Apr 1987; accepted July 1987.

0891-1150/87/06/0521/07/\$2.75/0

Copyright © 1987, The Cleveland Clinic Foundation

Case report

A 63-year-old woman with a history of locally recurrent meningioma presented to the Cleveland Clinic in September 1986 for evaluation of lower abdominal discomfort. During an evaluation for syncope in 1968, she had a left frontal intracranial mass, which was completely resected and identified as a meningioma (fibroblastic type). Histologic examination showed dural invasion. In 1976, a recurrent left frontal meningioma was detected after a focal right-sided seizure, and the patient underwent a second craniotomy and resection. The recurrent meningioma (transitional type) (*Fig. 1*) was adjacent to the sagittal sinus and again invaded the dura. As with the original tumor, there was no histologic evidence of necrosis, mitosis, or invasion of the cerebral cortex. Neither tumor exhibited features of a papillary or hemangiopericytoma pattern.^{11,12} The patient had since been free of seizures. She continued to smoke two packs of cigarettes daily as she had for 20 years.

In 1986, however, the patient complained of abdominal pain. Physical examination revealed mild, diffuse, lower abdominal tenderness, but was otherwise unremarkable. A computed tomogram of the abdomen showed a left lower-lobe lung nodule that was not apparent on the plain chest radiograph (*Fig. 2*). Further evaluation with chest CT and densitometry studies revealed a single 13-mm noncalcified nodule. The patient underwent a mediastinoscopy and subsequent thoracotomy with left lower-lobe wedge resection. Bronchial and mediastinal lymph nodes showed no evidence of tumor. Histologic examination of the nodule (*Fig. 3*) revealed a meningioma with features similar to the patient's recurrent intracranial lesion. After an uneventful postoperative recovery, additional workup with CT of the head revealed a 2.5-cm left frontal lesion, interpreted as a third local recurrence.

Discussion

Lung metastasis from intracranial meningioma

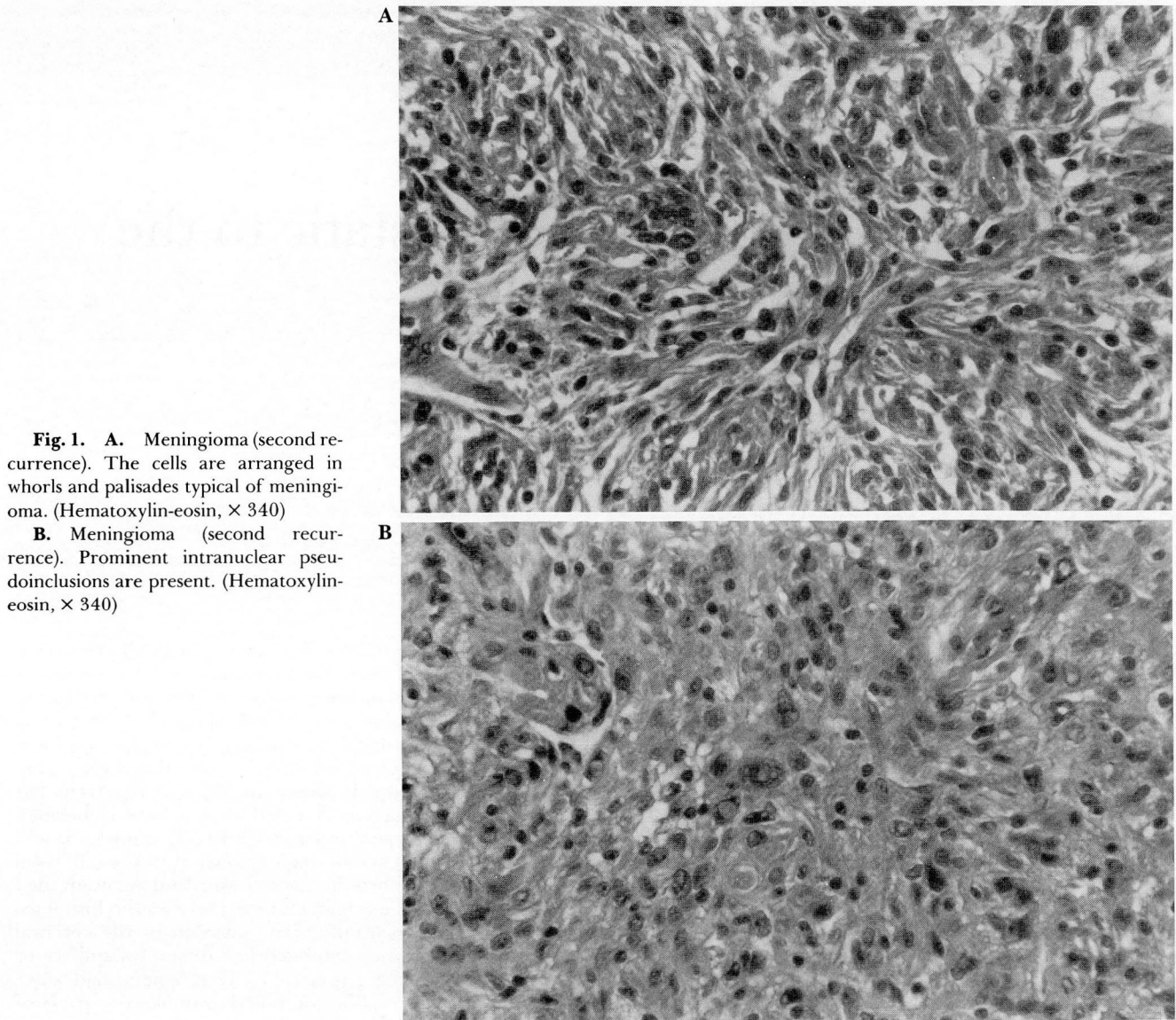
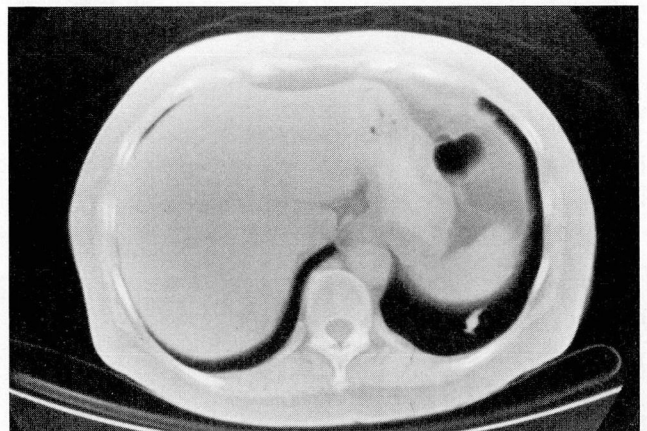


Fig. 2. CT scan of the abdomen, showing left lower lobe nodule.



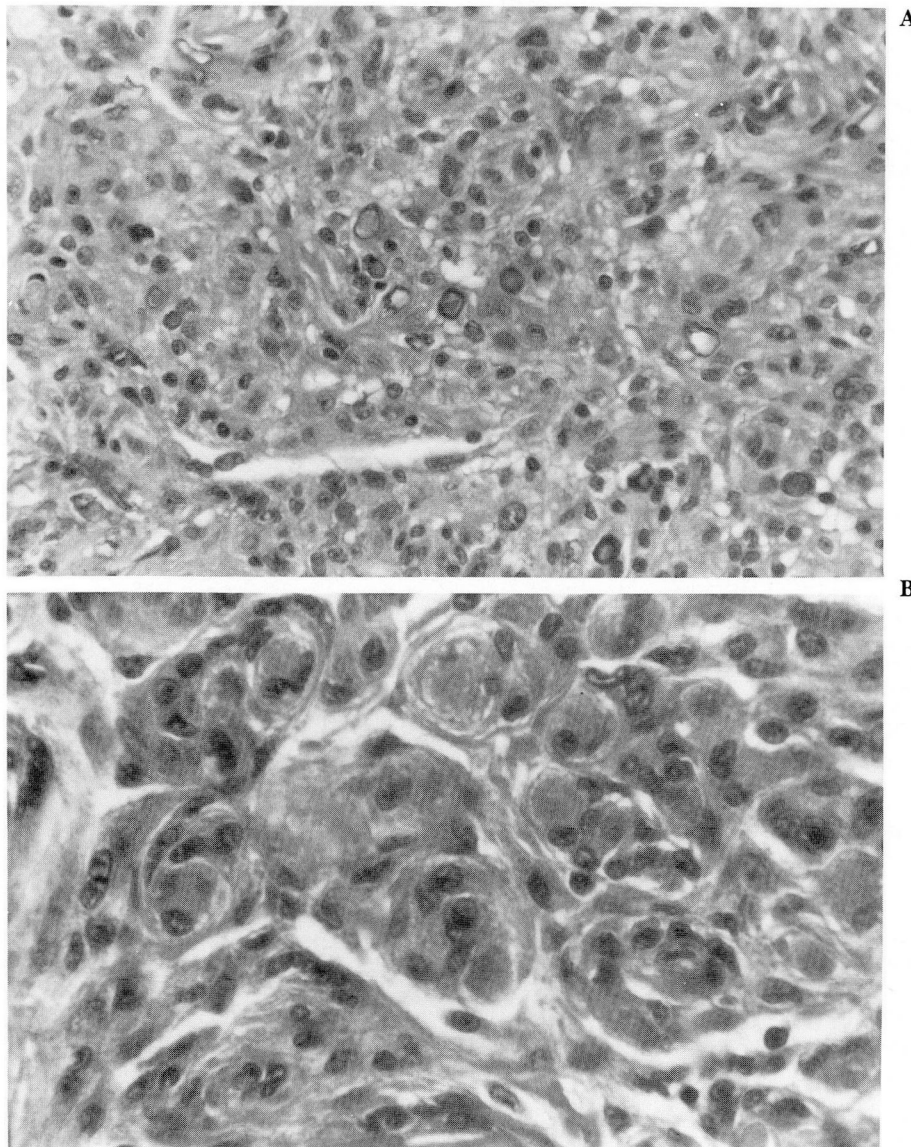


Fig. 3. A. Meningioma metastatic to the lung. The histologic pattern and intranuclear pseudoinclusions are similar to the recurrent intracranial meningioma resected 10 years earlier. (Compare with Fig. 2.) (Hematoxylin-eosin, $\times 340$)

B. Meningioma metastatic to the lung. High-power magnification demonstrates whorls and nests typical of meningioma. (Hematoxylin-eosin, $\times 540$).

is rare and has received little attention in the pulmonary literature. The case report described here establishes metastatic meningioma among the causes of solitary pulmonary nodules, especially in patients with associated intracranial masses. To further clarify the clinical spectrum of metastasizing meningioma, we reviewed the 113 available case descriptions of meningiomas that have metastasized to extracranial sites. A total of 88 cases have already been reviewed,^{5,13} but eight more have been reported since and 17 others were not included in the earlier series. *Table 1* presents the clinical features of these 25 additional patients.

Table 2 lists the metastatic sites in all 113 patients (mean, 1.9 metastases per patient). Although most patients (52%) had single metastases, multiple metastases were common (*Fig. 4*), with two metastases in 26%, three in 8%, and more than three in 13%. (The greatest number of metastases reported in a single patient is 11.³¹) Altogether, 61% of the 113 patients had lung metastasis (with or without others) and, as in our newly reported patient, the lung was the only site of extracranial metastasis in 32%. However, it was nearly as common (31%) for metastases to spare the lung but involve other extracranial organs. Only rarely were the pulmonary metas-

Table 1. Clinical features of 25 patients with metastatic meningioma

Reference	Patient age/sex	Site of primary meningioma	No. of metastases detected	Site of metastases	Method of lung metastases detection	Interval from primary detection to first metastasis	Previous craniotomy
Fikula (1968) ¹⁴	52/F	Parasagittal	1	Lung		—Not specified—	
Akagi et al (1974) ¹⁵	33/F	Bifrontal parasagittal	4	Lungs, liver, pancreas, vertebrae	Chest radiograph	7 years	Yes
Scott et al (1974) ¹⁶	38/M	Right cerebellar	2	T12-L2, right temporal bone	(No pulmonary metastases)	16 years	Yes
Ludwin et al—Case 1 (1975) ¹¹	41/M	Left occipital	2	Lungs, liver	Autopsy	Not specified	Yes
Palacios and Azar-Kia—Case 3 (1975) ¹⁷	40/M	Posterior fossa	3	Lungs, pancreas, kidney	Chest radiograph	8 years	Yes
Peck et al (1976) ¹⁸	27/M	Right frontal parasagittal	1	Lung	Chest radiograph, needle aspiration	9 years	Yes
Jędrzejewska-Iwanowska and Dowgiallo (1976) ¹⁹	65/F	Left frontal	4	Heart, lungs, kidneys, thyroid	Autopsy	1 month	No
Allen et al (1977) ²⁰	14/F	C4-5, extradural	3	Lungs, pleura, bronchial nodes	Autopsy	2 months	Yes
Wasserkrug et al—Case 1 (1979) ²¹	29/M	Left frontal temporal	2	L4, femur	(No pulmonary metastases)	6 years	Yes
Wasserkrug et al—Case 2 (1979) ²¹	50/F	Right frontal parasagittal	3	Left humerus, right orbit, left pelvis	(No pulmonary metastases)	10 years	Yes
Fukui et al—Case 1 (1980) ²²	39/M	Left frontal parasagittal	1	Skull	(No pulmonary metastases)	16 years	Not specified
Fukui et al—Case 2 (1980) ²²		—Not specified—	2	Lungs, liver	Not specified	9 years	Not specified
Thomas et al—Case 1 (1981) ²³	69/M	Right parietal	1	Jaw	Autopsy	8 years	Yes
Thomas et al—Case 2 (1981) ²³	33/M	Left parietal	2	Heart, other not specified	Autopsy	1 year	Yes
Thomas et al—Case 3 (1981) ²³	42/M	Left parietal	1	Lungs	Chest radiograph	6 years	Yes
Barz et al (1982) ²⁴	59/F	Not specified	1	Adrenal gland	(No pulmonary metastases)	Not specified	Yes
New et al (1982) ⁷		—Not specified—	2	Lungs, vertebrae		—Not specified—	
Jennings and Cook (1983) ⁹	37/M	Right petrous ridge	2	Right shoulder, right 9th rib	(No pulmonary metastases)	4 years	Yes

Table 1. — continued

Reference	Patient age/sex	Site of primary meningioma	No. of metastases detected	Site of metastases	Method of lung metastases detection	Interval from primary detection to first metastasis	Previous craniotomy
Wende et al (1983) ²⁵	35/M	Frontal parasagittal	1	Left lung	Chest radiograph, needle aspiration	2 years	Yes
Inoue et al (1983) ²⁶	56/F	Right parasagittal	5	Lungs, liver, kidney, pancreas, spleen	Chest radiograph	7 years	Yes
Ishibashi et al (1983) ²⁷	21/F	Left occipital	2	Lungs, liver	Chest radiograph	2 years	Yes
Dastur et al (1984) ²⁸	67/M	T12-L1, intradural	1	Left lung	Chest radiograph	0	No
Miller et al (1985) ²⁹	61/M	Left parasagittal	1	Right lung	Chest radiograph, thoracotomy	0	No
Pasquier et al (1986) ³⁰	29/M	Left parietal parasagittal	1	Left lung	Autopsy	6 years	Yes
Stoller et al (1987)	63/F	Left frontal	1	Left lung	Abdominal CT, thoracotomy	18 years	Yes

Table 2. Sites of metastases in 113 patients with metastatic meningioma

Site of metastasis	Number of metastases	Total metastases (%)
Lungs/pleura	78	35
Musculoskeletal system	38	17
Liver	29	13
Reticuloendothelial system (e.g., lymph nodes, spleen)	25	11
Kidney	18	8
Other site	37	16
TOTAL	225	100

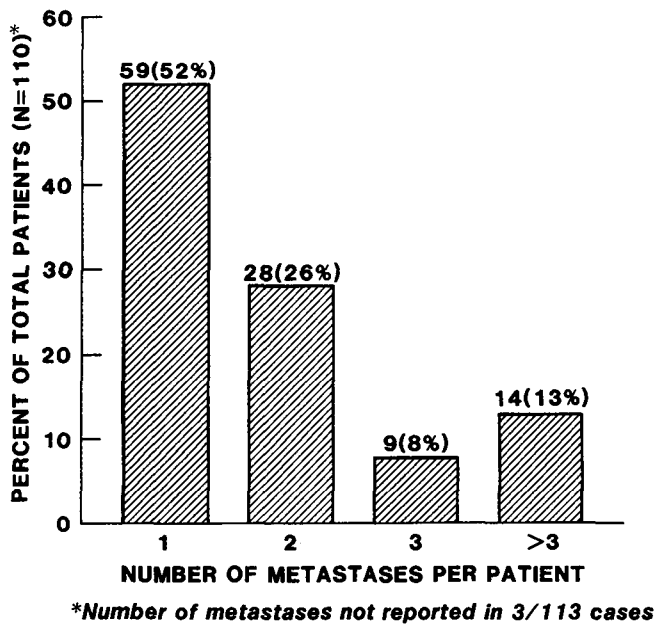


Fig. 4. Number of metastases in patients with metastatic meningioma.

tases associated with local symptoms (e.g., dyspnea, pleuritic pain, and in two extraordinary cases, respiratory failure^{19,32}). Most lung metastases were incidentally detected by chest radiography or by CT (53%). In the case we just described, the metastasis occupied a costophrenic sulcus and therefore escaped detection by plain chest radiography. Lung metastases were sometimes first detected at necropsy (37% of patients).

Although varying clinical surveillance makes it difficult to assess the interval between the primary and detection of the first metastasis, the literature collectively suggests that metastatic meningioma is usually an indolent disease. In 22 of 25 recently described patients for whom such information is available, the mean (\pm SD) interval from detection of the primary tumor to detection of the first metastasis was 77 months (6.4 years) \pm 66 months, and the longest interval was 20 years. Among all 113 cases, the longest reported interval to first detection of metastases is 24 years.⁵ Mean survival time from first diagnosis to death in recently reported patients was 88 months (range, one month to 19 years). Death may result from sequelae of distant metastases or, more frequently, from local intracranial recurrence, which has been estimated to occur in 10%–21% of patients with metastatic meningioma.^{7,8}

Because metastasis is especially surprising when the primary meningioma is histologically benign, investigators have suggested two risk factors for extracranial spread: previous craniotomy and venous sinus invasion. Yet neither factor explains all observed metastases. Specifically, Simpson⁸ observed histologic infiltration of venous sinuses in 34 of 246 (14%) patients with intracranial meningioma, though only one of the patients had detectable extracranial metastases. Kepes¹³ observed that more patients with extracranial metastases had previously undergone craniotomy (59 patients *v.* 13 patients), but Shaungshoti et al⁶ reported that 25% of patients with extracranial metastases had *not* previously undergone resection, including those whose tumors did not grossly infiltrate venous sinuses. Thus, although hematogenous dissemination is a likely mechanism, the exact cause of extracranial metastasis remains equivocal.

James K. Stoller, M.D.
Department of Pulmonary Disease
The Cleveland Clinic Foundation
9500 Euclid Avenue
Cleveland, Ohio 44106

References

1. Hoyer SJ, Hoar CS, Murray JE. Extracranial meningioma presenting as a tumor of the neck. *Am J Surg* 1960; **100**:486–489.
2. So SC, Ngan H, Ong GB. Ectopic meningiomas: report of two cases and review of the literature. *Surg Neurol* 1978; **9**:231–237.
3. Kemnitz P, Spormann H, Heinrich P. Meningioma of the lung: first report with light and electron microscopic findings. *Ultrastruct Pathol* 1982; **3**:359–365.
4. Kruse F Jr. Hemangiopericytoma of the meninges (angioblastic meningioma of Cushing and Eisenhardt): clinicopathologic aspects and follow-up studies in 8 cases. *Neurology (Minneapolis)* 1961; **11**:771–777.
5. Karasick JL, Mullan SF. A survey of metastatic meningiomas. *J Neurosurg* 1974; **39**:206–212.
6. Shuangshoti S, Hongsaprabhas C, Netsky MG. Metastasizing meningioma. *Cancer* 1970; **26**:832–841.
7. New PFJ, Hesselink JR, O'Carroll CP, Kleinman GM. Malignant meningiomas: CT and histologic criteria, including a new CT sign. *AJNR* 1982; **3**:267–76.

8. Simpson D. The recurrence of intracranial meningiomas after surgical treatment. *J Neurol Neurosurg Psychiatry* 1957; **20**:22–39.
9. Jennings PG, Cook PL. Bony metastases from intracranial meningioma. *Br J Radiol* 1983; **56**:421–422.
10. Power D. Fibrosarcoma of the dura mater. *Trans Pathol Soc Lond* 1886; **37**:12–14.
11. Ludwin SK, Rubinstein LJ, Russell DS. Papillary meningioma: a malignant variant of meningioma. *Cancer* 1975; **36**:1363–1373.
12. Jellinger K, Slowik F. Histological subtypes and prognostic problems in meningioma. *J Neurol* 1975; **208**:279–298.
13. Kepes JJ. Meningiomas: biology, pathology, and differential diagnosis. [In] Kepes J, ed., *Masson Monographs in Diagnostic Pathology*. New York, Masson, 1982, pp 190–199.
14. Fillkula J. Meningotheliomatous meningioma metastasizing to the lungs. *Cs Patologie (Prague)* 1968; **4**:189–191.
15. Akagi T, Iwata K, Utsunomiya T, Yoshimura H. An autopsy case of meningioma with extracranial remote metastases. *Acta Pathol Jpn* 1974; **24**:667–671.
16. Scott M, Kellett G, Peal A. Angioblastic meningioma (hemangiopericytoma) of the cerebellar fossa with metastases to the temporal bone and the lumbar spine. *Surg Neurol* 1974; **2**:35–38.
17. Palacios E, Azar-Kia B. Malignant metastasizing angioblastic meningiomas. *J Neurosurg* 1975; **42**:185–188.
18. Peck AG, Dedrick CG, Taft PD. Pulmonary metastases from intracerebral meningioma: diagnosis by percutaneous needle aspiration biopsy. *AJR* 1976; **126**:419–422.
19. Jędrzejewska-Iwanowska A, Dowgiallo M. Case of malignant meningioma with multiple metastases to the heart and other organs. *Pol Tyg Lek* 1976; **31**:2141–2142.
20. Allen IV, McClure J, McCormick D, Gleadhill CA. LDH isoenzyme pattern in a meningioma with pulmonary metastases. *J Pathol* 1977; **123**:187–191.
21. Wasserkrug R, Peyser E, Lichtig C. Extracranial bone metastases from intracranial meningiomas. *Surg Neurol* 1979; **12**:480–484.
22. Fukui M, Shima F, Abe M, et al. Recurrent intracranial meningioma with metastasis in the skull. A case report. *Neurol Med Chir (Tokyo)* 1980; **20**:107–111.
23. Thomas HG, Dolman CL, Berry K. Malignant meningioma: clinical and pathological features. *J Neurosurg* 1981; **55**:929–934.
24. Barz H, Voss K, Kunze K-D. Karyometrische Untersuchungen an einem rezidivierenden und metastasierenden Meningiom. *Zentralbl Allg Pathol* 1982; **126**:261–267.
25. Wende S, Bohl J, Schubert R, Schulz V. Lung metastasis of a meningioma. *Neuroradiology* 1983; **24**:287–291.
26. Inoue A, Hirano A, Kawakami S, Nakai O. [Metastasizing malignant meningioma: a case report—histopathological observation.] *No Shinkei Geka* 1983; **11**:187–192. (Jpn)
27. Ishibashi Y, Okada H, Mori T, Suzuki J. [Meningioma with extracranial multiple metastases—a case report.] *No Shinkei Geka* 1983; **11**:203–208. (Jpn)
28. Dastur KJ, Raji MR, Smith WI Jr. Pulmonary metastasis from intraspinal meningioma. *AJNR* 1984; **5**:483–484.
29. Miller DC, Ojemann RG, Proppe KH, McGinnis BD, Grillo HC. Benign metastasizing meningioma: case report. *J Neurosurg* 1985; **62**:763–766.
30. Pasquier B, Gasnier F, Pasquier D, Keddari E, Morens A, Couderc P. Papillary meningioma. Clinicopathologic study of seven cases and review of the literature. *Cancer* 1986; **58**:299–305.
31. Meredith JM, Belter LF. Malignant meningioma: case report of a parasagittal meningioma of the right cerebral hemisphere with multiple extracranial metastases to the vertebrae, sacrum, ribs, clavicle, lungs, liver, left kidney, mediastinum and pancreas. *South Med J* 1959; **52**:1037–1040.
32. Kepes JJ, MacGee E, Vergara G, Ranajit S. A case report. Malignant meningioma with extensive pulmonary metastases. *J Kans Med Soc* 1971; **72**:312–316.