

Mitral valvuloplasty at The Cleveland Clinic Foundation

Delos M. Cosgrove, MD
Altagracia M. Chavez, MD
Carl C. Gill, MD
Leonard A. R. Golding, MB,BS
Bruce W. Lytle, MD
Robert W. Stewart, MD
Paul C. Taylor, MD
Floyd D. Loop, MD

In 1986, 273 patients at The Cleveland Clinic Foundation had surgery on their native mitral valves. Mitral insufficiency occurred in 153 (56.0%) of these patients, mitral stenosis in 70 (25.6%), and mixed lesions in 50 (18.3%). Valvular lesions were due to rheumatic valvulitis in 134 (49.1%) patients, degenerative mitral valve disease in 97 (35.5%), ischemia in 23 (8.4%), and varied causes, including bacterial endocarditis and congenital lesions, in the rest. There were 10 deaths in the entire series, a 3.7% operative mortality rate. Operative mortality was similar for mitral stenosis, mitral insufficiency, and mixed lesions. The low operative mortality rate and wide applicability of mitral valvuloplasty, which avoids the complications associated with a mitral valve prosthesis, should encourage surgical intervention before ventricular function deteriorates or atrial fibrillation becomes irreversible.

Index term: Mitral valve, surgery

Cleve Clin J Med 1988; 55:37-42

The number of mitral valve operations performed in the United States continues to increase; in 1984, 18,000 patients underwent mitral valve surgery. There has been a recognized decrease in the incidence of rheumatic heart disease,¹ and a concomitant increase in the incidence of degenerative mitral valve disease.^{2,3} Mitral valvuloplasty is reported to have a lower operative mortality rate and better long-term results than mitral valve replacement,⁴ and it has been demonstrated to be applicable in a high percentage of patients undergoing mitral valve surgery. This study was undertaken to examine the etiology and pathology of heart disease in patients undergoing mitral

Department of Thoracic and Cardiovascular Surgery, The Cleveland Clinic Foundation. Submitted for publication May 1987; accepted Sep 1987.

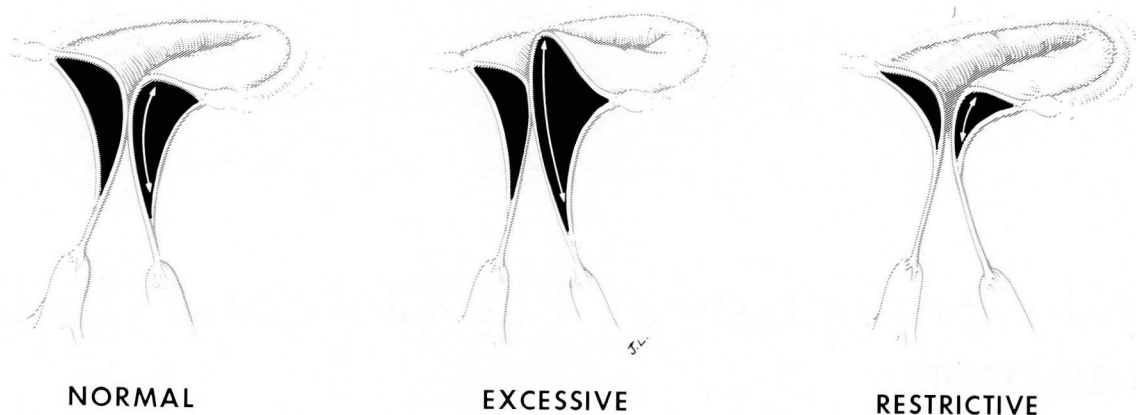


Fig. 1. Types of motion of the mitral valve leaflet.

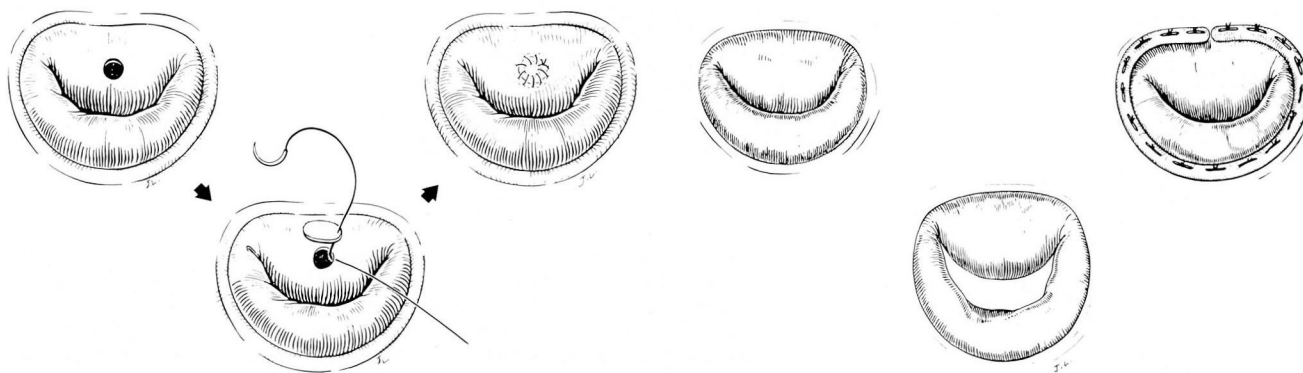


Fig. 2. Perforation of the leaflet may be treated by patching with pericardium.

Fig. 3. Correction of dilatation of mitral valve annulus with an annuloplasty ring.

valve surgery and to examine the applicability and surgical risk of mitral valvuloplasty in the patient population in the United States.

Patients and methods

In 1986, 296 patients underwent mitral valve operations at The Cleveland Clinic Foundation. Twenty-three patients had previously received a mitral valve prosthesis. The remaining 273 patients had surgical procedures performed on their native mitral valve and they form the basis of this report. There were 100 males and 173 females. The mean age was 60.7 ± 13.2 years, and the range was from 7 to 85 years.

Mitral valve disease etiology was determined from the surgical findings and histologic examination of excised valvular tissue. Operative mortality rate included all deaths occurring within 30 days of the surgical procedure.

Recent developments have encouraged the cardiac surgeon to undertake repair of the mitral valve. Carpentier increased understanding by

physiologically classifying the lesions of the mitral valve,⁵ pragmatically dividing lesions of the mitral valve according to the motion of the mitral valve leaflet: normal, excessive, or restricted (Fig. 1).

Specific surgical techniques vary with the pathologic entity. Perforation of the leaflet may be treated by patching with pericardium (Fig. 2).

Dilatation of the annulus is corrected by an annuloplasty ring. A Carpentier-Edwards annuloplasty ring reduces the diameter of the mitral annulus by a systematic plication of the posterior leaflet while maintaining the area of the anterior leaflet. In addition, it reshapes the mitral annulus, decreasing the anterior-posterior dimension and increasing coaptation between the anterior and posterior leaflet, and prevents further dilatation (Fig. 3).

Excessive leaflet motion or prolapse is most frequently secondary to ruptured posterior chordae. When this is true, it is treated by quadrilateral resection of the posterior leaflet and plica-

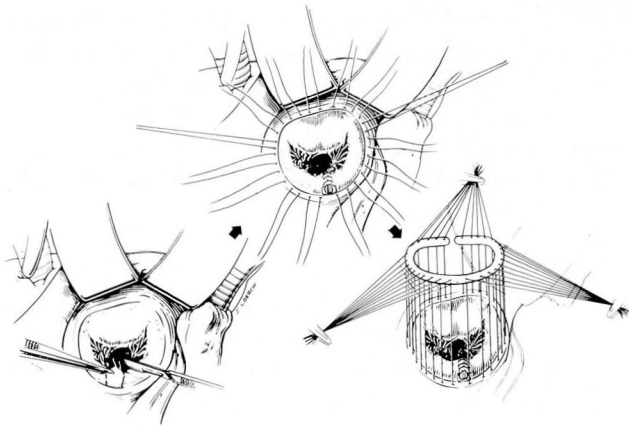


Fig. 4. Excessive leaflet motion or prolapse secondary to ruptured posterior chordae is treated by quadrilateral resection of the posterior leaflet and plication of the annulus with suture of leaflet material. The repair is reinforced with an annuloplasty ring.

tion of the annulus with suture of the leaflet tissue (*Fig. 4*). The repair is then reinforced with an annuloplasty ring. This technique is not applicable to the anterior leaflet because it compromises the area of the anterior leaflet enclosure.

Ruptured chordae of the anterior leaflet are managed by transfer of chordae from the posterior leaflet to the anterior leaflet and suturing them to the free edge of the anterior leaflet. The unsupported portion of the posterior leaflet is then resected (*Fig. 5*).

Elongated chordae to the anterior and posterior leaflet are treated by chordal shortening. A trench is made in the papillary muscle and the chordae drawn into the trench, thus shortening the chordae by twice the depth of the trench (*Fig. 6*).

Excessive leaflet motion secondary to ruptured or elongated papillary muscles is increasingly recognized to be associated with ischemic disease of the mitral valve. Elongated papillary muscle may be shortened by plication or by creating a trench in the wall of the left ventricle and reimplanting it (*Fig. 7*). A similar approach may be used for treatment of ruptured papillary muscle tips.

Occasionally, repair may be achieved by suturing the ruptured papillary muscle tips to an adjacent papillary muscle or by reimplantation to the free wall of the left ventricle (*Fig. 8*).

An aggressive approach to mitral stenosis is debridement of calcium by curettage of the anterior leaflet and division of the commissure of the chordae tendineae and papillary muscle; this approach may salvage many mitral valves (*Fig. 9*).

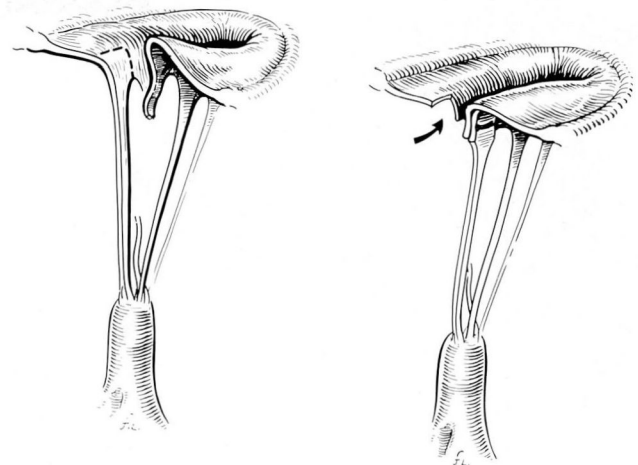


Fig. 5. Repair of ruptured chordae of the anterior leaflet by transfer of chordae from the posterior to anterior leaflet.

We used the Student t-test to test for statistical significance of our results.

Results

In the 273 patients undergoing mitral valve procedures, mitral insufficiency occurred in 153 (56%) and mitral stenosis in 70 (25.6%); mixed lesions accounted for 50 (18.3%).

When valvular disease was examined according to its etiology, rheumatic valvulitis accounted for 134 cases (49.1%). Degenerative mitral valve disease was the second most common cause, accounting for 97 cases (35.5%). Ischemia was the cause in 23 cases (8.4%). Bacterial endocarditis, congenital lesions, and other varied causes accounted for the remaining cases.

In 153 patients with pure mitral insufficiency, degenerative diseases accounted for 97 cases (63.4%). Ischemia was the second most common etiologic factor, accounting for 23 cases (15.0%).

To identify the anatomic abnormalities found in patients with mitral insufficiency secondary to degenerative disease, 97 patients in this category were analyzed. Forty-one patients (42.3%) had ruptured chordae. Twenty-eight of these had ruptured posterior chordae, eight anterior chordae, and five chordae to both the anterior and posterior leaflets. Elongated chordae were present in 39 cases (40.2%) and dilated annulus in 17 cases.

Operative procedure

In the 153 patients with mitral insufficiency, 88 (57.5%) underwent mitral valvuloplasty. In 70 patients with pure mitral stenosis, 33 (47.1%)

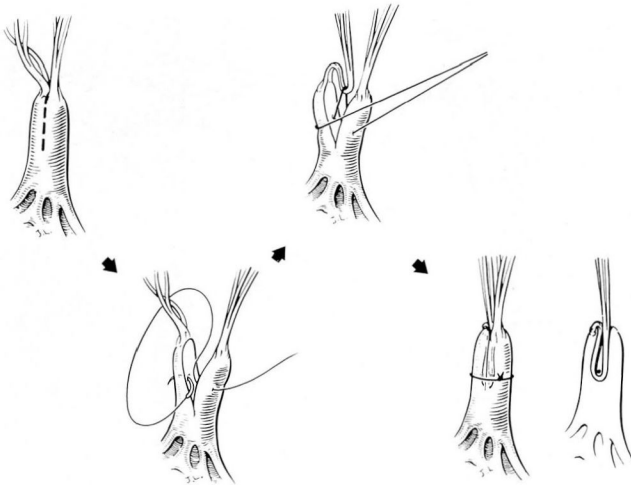


Fig. 6. Shortening of elongated chordae.

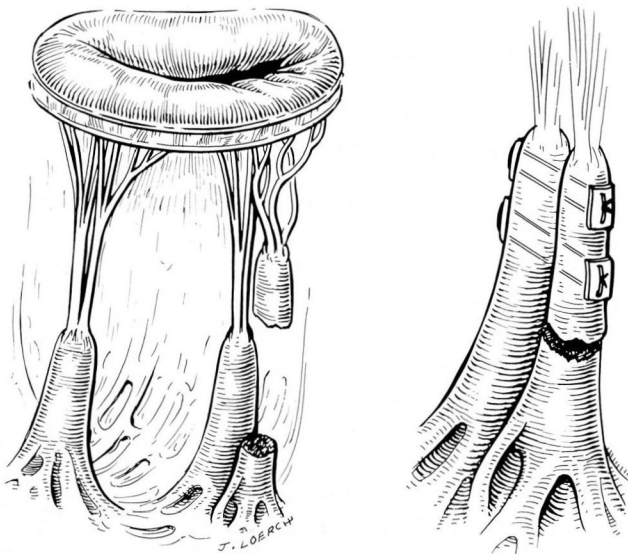


Fig. 7. Shortening of elongated papillary muscle.

underwent mitral valvuloplasty. The lowest percentage of patients undergoing mitral valvuloplasty had mixed lesions (21 of 50 patients, 42%).

Degenerative disease of the mitral valve lent itself well to valvuloplasty (66 of 97 cases, 68%). Fourteen of 23 patients (60.9%) with mitral insufficiency secondary to ischemic heart disease underwent valvuloplasty; however, only 60 of 134 patients (44.8%) with rheumatic disease underwent valvuloplasty. Patients with mitral insufficiency secondary to degenerative disease responded particularly well to valvuloplasty. A total of 70.7% of the patients with ruptured chordae,

75% with posterior ruptures, and 75% with anterior chordal ruptures underwent repair, but only 40% of the patients with ruptured chordae to both leaflets did. Elongated chordae were repaired in 29 out of 39 cases (74.4%). When dilatation of an annulus was the sole cause, eight of 17 (47.1%) were repaired.

Operative mortality rate

There were 10 deaths in the entire series, a 3.7% operative mortality rate. Operative mortality rates were similar for mitral stenosis, mitral insufficiency, and mixed lesions (4.3%, 3.9%, and 2%, respectively).

There were seven deaths in 131 patients undergoing mitral valve replacements, a 5.3% operative mortality rate, as opposed to three deaths in 142 patients undergoing mitral valve repairs, a 2.1% operative mortality rate. The difference was not statistically significant. In patients undergoing primary isolated mitral valve procedures, there were two deaths from 45 mitral valve replacements, a 4.4% operative mortality rate, and one death from 80 mitral valve repairs, a 1.3% operative mortality rate. The difference was not statistically significant.

Discussion

It is well documented that the incidence of rheumatic valvular heart disease is decreasing in the United States.¹ The extent of mitral valve prolapse is being increasingly appreciated; mitral valve prolapse is estimated to affect 5% of the U.S. population.⁶ Approximately 5% of these will require mitral valve surgery after the diagnosis of mitral valve prolapse.⁷

As the U.S. population continues to age, an increasing number of patients with degenerative mitral valve disease is expected. The most common lesion associated with degenerative mitral valve disease is ruptured chordae. Seventy-five percent of these patients develop mitral insufficiency because of degenerative mitral valve disease and will be excellent candidates for mitral valve repair.

Because mitral valvuloplasty is a technically more demanding and more time-consuming procedure than mitral valve replacement, it might be expected that the operative mortality rate associated with repair would be higher. The results of mitral valvuloplasty reported in the literature suggest a low mortality rate. The combined results of series comparing mitral valve

replacement and mitral valve repair in similar groups of patients demonstrated an operative mortality rate of 2% for mitral valve repair compared with 10% for mitral valve replacement.⁸⁻¹² This superior mortality rate for mitral valvuloplasty is partly attributable to the preservation of left ventricular function by maintaining the subvalvular mechanism and its continuity with the valve. David et al¹³ and Hansen et al¹⁴ have confirmed this work both clinically and experimentally by demonstrating that left ventricular function deteriorates when the subvalvular mechanism is interrupted, but function is preserved when the subvalvular apparatus is maintained. In a more recent experimental study, Hansen et al¹⁵ demonstrated that disruption of either anterior or posterior chordae interfered significantly with left ventricular systolic function. Disruption of either set of chordae was important, and disruption of both sets was additive, causing about a 42% reduction in left ventricular systolic function. When the mitral subvalvular apparatus is severed, left ventricular dyskinesia is prominent in the area of insertion of the papillary muscles. The geometry of the left ventricle during the period of isovolumetric contraction is thereby altered and overall left ventricular systolic function depressed.¹⁶ Studies like these provide an impetus for expanding the use of techniques that preserve intact the subvalvular mechanism of the mitral valve.

The majority of previous reports on mitral valvuloplasty come from Europe and other areas where the incidence of rheumatic fever is higher than in the United States. This led to concern that mitral valvuloplasty might not be applicable in the majority of patients seen in the United States and would not be carried out as extensively in patients with degenerative mitral valve disease. Our findings demonstrate that mitral valvuloplasty is applicable to the majority of patients undergoing mitral valve surgery in the United States and to a particularly high percentage of patients with degenerative mitral valve disease. The incidence of valvuloplasty and commissurotomy is rapidly increasing. In 1986, 49% of the entire patient population with mitral valve disease underwent valvuloplasty or commissurotomy (Fig. 10). As experience accumulates and surgical techniques improve, an increasing percentage of patients with mitral insufficiency secondary to ischemic heart disease will also be good candidates for mitral valve repair.

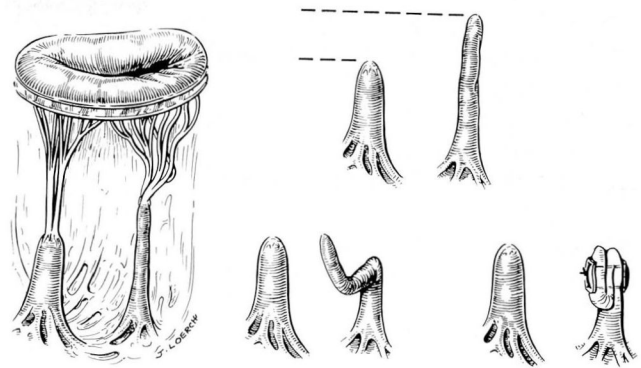


Fig. 8. Repair of ruptured papillary muscle tips.

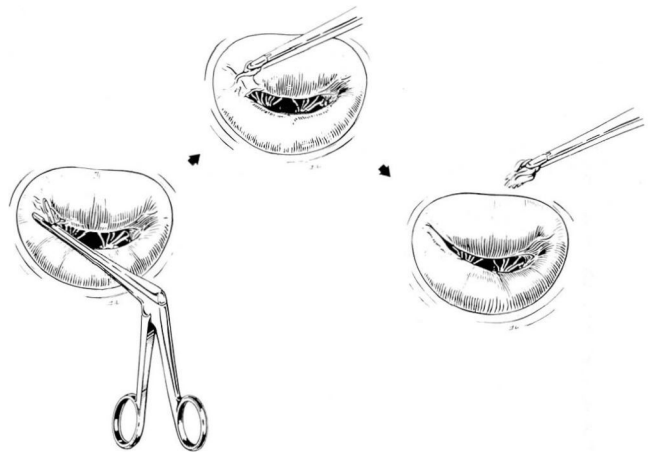


Fig. 9. Debridement of calcium by curettage of the anterior leaflet and division of the commissure of the chordae tendineae and papillary muscle.

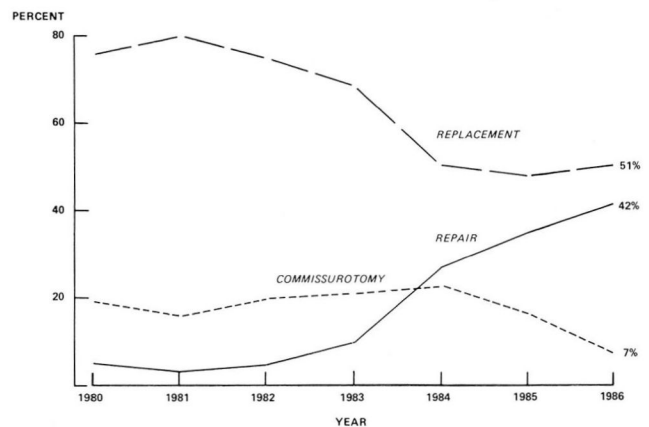


Fig. 10. In 1986, 49% of the entire mitral valve patient population underwent valvuloplasty or commissurotomy.

The low operative mortality rate and wide applicability of mitral valvuloplasty, which avoids the complications associated with a mitral valve prosthesis, should encourage surgical intervention before ventricular function deteriorates or atrial fibrillation becomes irreversible.

Delos M. Cosgrove, MD
The Cleveland Clinic Foundation
9500 Euclid Avenue
Cleveland, Ohio 44106

References

1. Gordis L. The virtual disappearance of rheumatic fever in the United States: lessons in the rise and fall of disease. T. Duckett Jones Memorial Lecture. Current Views from Circulation Preludes and Progress Editorials and Perspectives July 1983–July 1986, pp 183–197. [published originally as a Perspective in *Circulation* 1985; **72**:1155–1262]
2. Cooley DA, Gerami S, Hallman GL, Wukasch DC, Hall RJ. Mitral insufficiency due to myxomatous transformation: “Floppy valve syndrome”. *J Cardiovasc Surg* 1972; **13**:346–349.
3. Salomon NW, Stinson EB, Griep RB, Shumway NE. Surgical treatment of degenerative mitral regurgitation. *Am J Cardiol* 1976; **38**:463–468.
4. Perier P, Deloche A, Chauvaud S, et al. Comparative evaluation of mitral valve repair and replacement with Starr, Bjork, and porcine valve prostheses. *Circulation* 1984; **70**(suppl I) I-187–I-192.
5. Carpentier A. Cardiac valve surgery—the “French correction”. *J Thorac Cardiovasc Surg* 1983; **86**:323–337.
6. Devereux RB. Mitral valve prolapse. *Primary Care* 1985; **12**:39–54.
7. Nishimura RA, McGoon MD, Shub C, Miller FA, Ilstrup DM, Tajik AJ. Echocardiographically documented mitral-valve prolapse. *N Engl J Med* 1985; **313**:1305–1309.
8. Duran CG, Pomar JL, Revuelta JM, et al. Conservative operation for mitral insufficiency. Critical analysis supported by postoperative hemodynamic studies of 72 patients. *J Thorac Cardiovasc Surg* 1980; **79**:326–337.
9. Oury JH, Peterson KL, Folkerth TL, Daily PO. Mitral valve replacement versus reconstruction. An analysis of indications and results of mitral valve procedures in a consecutive series of 80 patients. *J Thorac Cardiovasc Surg* 1977; **73**:825–835.
10. Yacoub M, Halim M, Radley-Smith R, McKay R, Nijveld A, Towers M. Surgical treatment of mitral regurgitation caused by floppy valves: repair versus replacement. *Circulation* 1981; **64**(suppl II) II-210–II-216.
11. Oliveira DBG, Dawkins KD, Kay PH, Paneth M. Chordal rupture: II: comparison between repair and replacement. *Br Heart J* 1983; **50**:318–324.
12. Adebo OA, Ross JK. Surgical treatment of ruptured mitral valve chordae. A comparison between valve replacement and valve repair. *Thorac Cardiovasc Surg* 1984; **32**:139–142.
13. David TE, Strauss HD, Mesher E, Anderson MJ, Macdonald IL, Buda AJ. Is it important to preserve the chordae tendineae and papillary muscles during mitral valve replacement? *Can J Surg* 1981; **24**:236–239.
14. David TE, Uden DE, Strauss HD. The importance of the mitral apparatus in left ventricular function after correction of mitral regurgitation. *Circulation* 1983; **68**(suppl II):II-76–II-82.
15. Hansen DE, Cahill PD, Derby GC, Miller DC. Relative contributions of the anterior and posterior mitral chordae tendineae to canine global left ventricular systolic function. *J Thorac Cardiovasc Surg* 1987; **93**:45–55.
16. Hansen DE, Cahill PD, DeCampi WM, Harrison DC, Derby GC, Mitchell RS, Miller DC. Valvular-ventricular interaction: importance of the mitral apparatus in canine left ventricular systolic performance. *Circulation* 1986; **73**:1310–1320.