

# Results of mechanical ventricular assist in bridging to cardiac transplantation

Leonard A. R. Golding, MD  
Dennis J. Tishko, MD  
Robert W. Stewart, MD

Five patients who were cardiac transplantation candidates were supported with a simple mechanical assist system when unresponsive low cardiac output developed and an appropriate donor heart was not available. The periods of support ranged from 2½ to 15 days with a simple left ventricular assist device in four patients and a biventricular assist device in one. Three patients died prior to transplantation and two were discharged following cardiac transplantation and remain in good health. Two patients were supported for five and 15 days, respectively, by continuous flow with pulsatility and have shown recovery and maintenance of systemic organ functions.

**Index term:** Heart, mechanical

**Cleve Clin J Med** 1988; 55:59-62

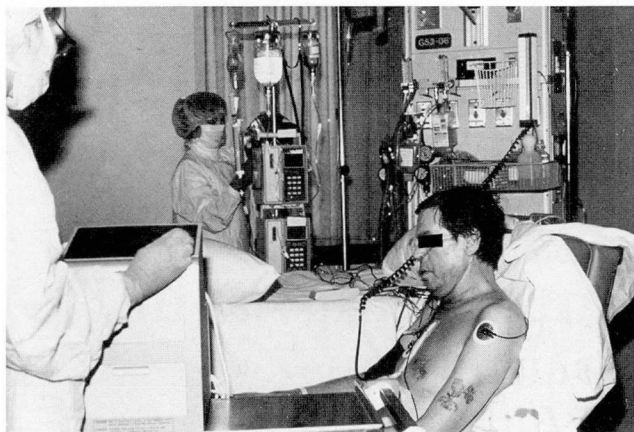
Cardiac transplantation is the final therapeutic option for certain patients with end-stage cardiac dysfunction, but the scarcity of an appropriate donor organ can result in their death while waiting for transplantation. We report our experience with the Biomedicus Bio-pump, a simple mechanical assist device, as a bridge to cardiac transplantation in five patients.

## Case reports

**CASE 1.** A 34-year-old white man was transferred to the Cleveland Clinic in cardiogenic shock three days following an acute massive myocardial infarction. Catheterization confirmed the diagnosis and showed inoperable disease. Over the ensuing four days, his condition deteriorated and he became unresponsive to cardiotoxic agents, vasodilators, and finally intra-aortic balloon pumping (IABP). After accelerated transplant evaluation and acceptance, left ventricular mechanical assist was

---

Department of Thoracic and Cardiovascular Surgery, The Cleveland Clinic Foundation. Submitted for publication March 1987; accepted May 1987.



**Figure.** Patient supported by left ventricular mechanical assistance for 10 days is sitting out of bed.

instituted with flows maintained at 2.4 L/min/m<sup>2</sup>. Sepsis then developed, eliminating the possibility of transplant. Ventricular support was discontinued after 124 hours and the patient died.

**CASE 2.** A 56-year-old white woman underwent mitral valve surgery, but was unable to be weaned from bypass despite IABP and appropriate pharmacological support. Supported by the left ventricular assist device, she was returned to the intensive care unit with flows maintained at 2.6 L/min/m<sup>2</sup>. No return of left ventricular function was noted after 48 hours, and after rapid evaluation, she was accepted as a transplant candidate. After 81 hours of support, a donor heart was procured and transplantation was performed. She was discharged from the hospital in good health. The excised heart showed necrosis of 70% of the left ventricle.

**CASE 3.** A 50-year-old white man, who underwent coronary revascularization surgery, had a stormy postoperative course requiring cardiotoxic agents and IABP. He was transferred to the Cleveland Clinic in cardiogenic shock with low urine output. He transiently improved and was accepted as a transplant candidate, but a left ventricular assist device was inserted when his condition further deteriorated. Flows were maintained at 2.6 L/min/m<sup>2</sup>, renal function returned, and after 60 hours of support, a donor heart was found. Transplantation was performed, and he was discharged from the hospital in good health. The excised heart showed massive injury to the left ventricle.

**CASE 4.** A 30-year-old white man was evaluated and accepted into the transplant program with the diagnosis of terminal cardiomyopathy. Despite intermittent cardiotoxic infusions and IABP, his condition progressively deteriorated. Biventricular support was subsequently necessary for profound biventricular failure. He was managed for three days with flows maintained at 4.3 L/min/m<sup>2</sup> (L/R). Support was discontinued because of progressive difficulty in main-

taining adequate perfusion and persistent hypotension, probably secondary to sepsis.

**CASE 5.** A 43-year-old white man with class IV cardiomyopathy was accepted into the transplant program. Over the next eight weeks, he required intermittent cardiotoxic infusions and eventually IABP support. He became unresponsive and oliguric, and left ventricular assist device support was instituted. Positive blood cultures were obtained 36 hours later, consistent with line sepsis existing prior to implant of the device. Consequently, he was removed from the transplant list and managed with an intensive 10-day course of antibiotics. During this time, he underwent extubation, blood cultures were negative, renal function recovered, and he was again placed on the waiting list for transplantation (*Figure*). However, 14 days after initiating ventricular support, there was a marked and rapid progressive deterioration of cerebral function. A scan showed multiple cerebral emboli. Support was discontinued on the 15th day and he died. The autopsy showed multiple cerebral emboli, both old (prior to left ventricular mechanical assistance) and recent. The source of emboli appeared to be the left ventricular cavity, not the assist system devices, which showed minimal deposition.

### Ventricular assist apparatus

The basis of the simple ventricular assist system is the Biomedicus pump. The acrylic pump head consists of a single moving part that rotates. Incoming blood is accelerated over a set of parallel cones producing a constrained vortex. The blood flow generated is in proportion to the number of revolutions per minute. Readily available Tygon tubing connects the inflow and outflow ports to standard wire-reinforced cannulas. Arterial return to the patient is through the standard 24-F armored endhole cannula with drainage through a 32- or 36-F armored venous cannula. The cannulas are held in position by Teflon-pledgeted purse-string sutures. In four instances, the drainage cannula was placed through the left atrial appendage as part of a sternotomy approach, while in the fifth case, a left thoracotomy was performed due to previous sternotomy and the cannula was positioned through the left ventricular apex. The cannulas were tunneled to exit at a site distant from the operative incision and held by heavy suture. Pump heads were changed if pump performance was questionable or unusual vibration noises developed. In such circumstances, replacement of the pump head could be performed in less than 60 seconds. In all cases, after postoperative bleeding had been controlled, heparin was instituted to maintain the activated clotting time at approximately 1½ times normal.

## Results

Mechanical ventricular assistance as a bridge to cardiac transplantation was attempted in five patients between August 1985 and December 1986. The patients (four men and one woman) ranged in age from 30 to 54 years. In one patient, support was instituted as an aid to weaning from cardiopulmonary bypass following mitral valve surgery and she was accepted into the transplant program when there was no evidence of recovery of ventricular function. The other four patients had already been accepted into the cardiac transplant program and experienced deterioration of ventricular function while awaiting an appropriate donor. In these patients, the device was deployed only after adequate cardiac outputs could not be maintained despite the use of full pharmacological support with cardiotoxic agents, vasodilators, and IABP.

The insertion of the device was done without the aid of cardiopulmonary bypass in four cases due to the relatively simple technique. In the fifth case, the device was inserted as an aid to weaning from cardiopulmonary bypass following mitral valve surgery. In all cases, good flows were easily achieved and maintained at 2.4 L/min/m<sup>2</sup> or higher. The duration of mechanical assistance ranged from 2½ to 15 days. In two cases, an appropriate donor heart was found soon after their acceptance as transplant candidates and transplantation was performed successfully. These two patients were discharged and are doing well. No donor organ was ever found for the other three patients.

In the immediate postoperative period, bleeding necessitated reoperation in three of five cases and was related to cannulation sites. When Teflon strips were used around the cannulas in the latter two cases, bleeding was not a problem. Hemolysis associated with the use of the Biomedicus pump has not proved to be a clinically significant problem; free serum hemoglobin levels have usually been 10 mg/100 mL or less after the first 24 hours. Platelet numbers tended to decrease with continued use of the Biomedicus pump; in two patients, platelet replacement therapy was necessary.

Renal function was impaired in all patients at the time of left ventricular mechanical assistance with the exception of case 2. The oliguria or anuria resolved spontaneously with institution of mechanical support and the biochemical abnor-

malities regressed. This was true also for the two patients in whom balloon pumping was discontinued and nonpulsatile flow was the means of support. In the patient supported for 15 days, although the serum blood, urea, nitrogen, and creatinine levels normalized, 24-hour creatinine clearance on the 11th day of support was mildly abnormal at 64 mg per 24 hours (normal, 0–40 mg per 24 hours). Liver function showed early mild dysfunction and then rapid recovery to normal for all patients.

For two patients, supported for five and 15 days, respectively, the IABP was removed in an attempt to minimize the risk of sepsis. Although neither patient survived, they represent, to our knowledge, the longest clinical survivors with pulseless perfusion in a conscious state, extubated, and able to communicate. As a result, we have learned that blood pressure can be monitored noninvasively by using a sphygmomanometer arm cuff and a Doppler flow probe positioned over either the radial or the brachial artery and that this correlated extremely well with values obtained by an indwelling arterial catheter. The longest survivor was able to sit out of bed briefly, but was never ambulated. These two experiences encouraged us to consider early removal of IABP in conjunction with prolonged use of a nonpulsatile support system.

## Discussion

Nonpulsatile ventricular assist devices (either a roller pump or a centrifugal pump) are the most frequently used blood pumps for the management of patients with persistent low cardiac output state unresponsive to standard techniques such as IABP.<sup>1–5</sup> The Biomedicus pump is the most frequently used and has also been employed as a bridge to cardiac transplantation by some groups.<sup>6,7</sup> Such mechanical devices are becoming increasingly needed for this latter purpose due to the relative lack of donors. For patients accepted into a cardiac transplant program, most groups have shown a 20%–30% mortality prior to transplantation due to the inadequate supply of donor hearts. From August 1984, when we initiated a transplant program, through December 1986, 10 transplant candidates died due to lack of a donor organ.

Mechanical ventricular assist as a bridge to transplant was first attempted by Cooley et



al.<sup>8</sup> Since then, both pulsatile and nonpulsatile pumps have been used.<sup>9–12</sup> Certainly the excision of the failing heart and its temporary replacement by an artificial total heart have been surprisingly successful.<sup>10</sup> Most patients, however, die of left ventricular failure and would benefit from a left ventricular mechanical assist while awaiting an appropriate donor organ. Hill et al<sup>12</sup> had the first success with this concept, and now many devices, both intracorporeal and extracorporeal, have been successfully used.

Since August 1985, the simple Biomedicus mechanical ventricular assist system has been used in five cases in an attempt to prolong the period available for finding an appropriate donor organ. Each of these cases has different features, but each has been a learning experience for us. In one case, after sepsis developed, support was discontinued five days later and the patient died. In contrast, in the 15-day case, a decision was made not to discontinue support despite the presence of sepsis. Subsequently, an appropriate course of antibiotics was successful. The autopsy results in this patient, however, showed emboli in the brain and right coronary artery from the native ventricle. A cannula had been inserted through the left atrial appendage and although the patient was maintained in a nonpulsatile state, intermittent ejection was occasionally noted in the arterial trace. While it is traditional to avoid cannulating the apex for temporary ventricular assist in a pre-transplant patient, further myocardial injury is not a relevant problem. Furthermore, left atrial drainage most probably results in relative stasis in the ventricle and potentially promotes the formation of thrombus. We believe that the optimal site for drainage in a pre-transplantation patient should be via the left ventricular apex, which will minimize the potential for stasis and thrombus formation.

### Conclusion

When we initiated the program of using assist devices prior to transplantation, the average waiting time for a donor was significantly shorter. Accordingly, it seemed appropriate to make use of this simple temporary ventricular assist system for periods of up to two weeks. Now, the waiting time for a donor has increased markedly and the need for more prolonged support with implantable devices has to be considered. Thus the Bio-

medicus device may be used prior to an implant pump, providing a waiting period during which the patient's potential for recovery and ability to survive a prolonged support course can be assessed.

Leonard A. R. Golding, MD  
Department of Thoracic and Cardiovascular Surgery  
The Cleveland Clinic Foundation  
9500 Euclid Avenue  
Cleveland, Ohio 44106

### References

1. Pennington DG, Swartz MT, McBride R. Clinical experience with temporary non-pulsatile ventricular assist systems: the centrifugal pump for ventricular assist. Presented at the First International Symposium on Current Problems for Further Development of Artificial Heart and Assist Devices, August 5, 1984, in Tokyo.
2. Park SB, Liebler GA, Burkholder JA, et al. Mechanical support of the failing heart. *Ann Thorac Surg* 1986; **42**:627–631.
3. Golding L, Hill JD, Joyce J, et al. Temporary mechanical support for cardiogenic shock. *Trans Am Soc Artif Intern Organs* 1986;**32**.
4. Golding L, Loop FD, Nosé Y. Clinical and Experimental Use of the Centrifugal Pump: New Developments in Cardiac Assist Devices. Philadelphia, Praeger, 1986, pp 92–102.
5. Rose DM, Laschinger J, Grossi E, Krieger KH, Cunningham JN Jr, Spencer FC. Experimental and clinical results with a simplified left heart assist device for treatment of profound ventricular dysfunction. *World J Surg* 1985;**9**:11–17.
6. Phillips SJ, Kongtahworn C, Zeff RH, et al. Heart transplantation and left ventricular support: experience with 12 patients (abst). *J Heart Transplantation* 1986; **5**:366.
7. Bolman RM, Spray TL, Cance C, Saffitz J, Genton RE, Eisen H. Heart transplantation in patients requiring preoperative mechanical support (abst). *J Heart Transplantation* 1986; **5**:374.
8. Cooley DA, Liotta D, Hallman GL, Bloodwell RD, Leachman RD, Milam JD. Orthotopic cardiac prosthesis for two-staged cardiac replacement. *Am J Cardiol* 1969; **24**:723–730.
9. Magovern JA, Pennock JL, Campbell DB, Pae WE, Pierce WS, Waldhausen JA. Bridge to heart transplantation: the Penn State experience. *J Heart Transplantation* 1986; **5**:196–202.
10. Joyce LD, Johnson KE, Pierce WS, et al. Summary of the world experience with clinical use of total artificial hearts as heart support devices. *J Heart Transplantation* 1986; **5**:229–235.
11. Zumbro GL, Kitchens WR, Galloway RF. Mechanical assistance for bridging to heart transplantation and support of the failing transplanted heart (abst). *J Heart Transplantation* 1986; **5**:382.
12. Hill JD, Farrar DJ, Hershon JJ, et al. Use of a prosthetic ventricle as a bridge to cardiac transplantation for postinfarction cardiogenic shock. *New Engl J Med* 1986; **314**:626–628.