

# A 29-year-old woman with back pain and a lumbar mass

Melinda L. Estes, MD  
Richard J. Lederman, MD  
Srinivasan Vijayakumar, MD, DMRT  
Russell W. Hardy, MD  
H. Faleck, MD  
Scott A. Rosenbloom, MD

### Presentation of case

When first seen at the Cleveland Clinic, this 29-year-old woman had a one and one-half-year history of progressive, severe low-back pain radiating into her left lower extremity. Her general health had been good, except for the onset of generalized headaches in January 1986. A computed tomographic (CT) scan at that time showed a probable pituitary adenoma. A pituitary screening test showed increased levels of prolactin. She took a butalbital, aspirin, and caffeine combination medication (Fiorinol) as needed for symptomatic relief. She was taking no other medication, had no known allergies, and neither smoked nor drank.

She dated the onset of her back pain to January 1985. The pain, initially noted while she was driving, was located in her low back and radiated posteriorly down her left lower extremity. The pain had increased markedly since September 1985, and was exacerbated by coughing and sneezing. Since March 1986, two months before hospitalization, she had had anterior thigh pain as well as increasing pain in her low back

but without urinary or bowel problems. Her general medical examination revealed no abnormalities. A neurologic examination revealed normal mentation, cranial nerves, and cerebellar function. A motor examination revealed normal strength, no atrophy, and a positive, straight-leg raising on the left at approximately 60°. Sensory examination was normal, and reflexes were symmetric in the upper extremities. In the lower extremities she had a 2+ knee jerk on the right (0–4+), an absent knee jerk on the left, and absent ankle jerks. Her toes were flexor-to-plantar stimulated. Magnetic resonance (MR) imaging of the spine was performed. The patient underwent lumbar surgery.

### Discussion and differential diagnosis

*Dr. Richard Lederman:* Although we have the history of progressively worsening pain in the lower back and left leg, we have no information about the effects of position or activity on her pain, except that it is increased by coughing or sneezing.

An interesting finding is the evidence from blood studies and CT scan of a “probable” prolactin-producing pituitary adenoma. I assume that this is a correct interpretation and also assume that the pituitary adenoma is unrelated to this young woman’s back and leg problem.

Departments of Neuropathology (M.L.E.), Neurology (R.J.L., H.F.), Radiation Therapy and Radiology (S.V., S.A.R.), and Neurosurgery (R.W.H.), The Cleveland Clinic Foundation. Submitted for publication April 1987; accepted Aug. 1987.

Cleve Clin J Med 1988;55:152–157

What can we determine from the relatively meager data provided? We have the symptom of pain in the lower back with radiation posteriorly down the left leg, the clinical picture of sciatica. Subsequent anterior thigh pain could well indicate spread beyond the distribution of the sciatic nerve as the process progressed. Low back pain, of course, is not a very specific symptom and may originate not only from the spine and contiguous structures but also from intrapelvic and intra-abdominal sources, retroperitoneal tissues, and the musculoskeletal apparatus. Pain in the lower extremity, especially radiating from the back, suggests an intra- or paraspinal source. The indication that coughing or sneezing aggravates the pain, presumably associated with the increased intraspinal pressure accompanying this maneuver, strongly suggests that nerve roots themselves are the origin of the pain.

Since pain is described as radiating posteriorly down the left lower extremity, the most likely level of root involvement would be L-5 through S-2. We must recognize at the onset that these nerve roots arise at the level of the conus medullaris, the caudal portion of the spinal cord, which generally extends to the lower edge of the L-1 vertebra, meaning that an intraspinal lesion could conceivably be as high as the L-1 vertebra and still cause symptoms in the L-5 through sacral distribution. Later pain in the left anterior thigh would suggest rostral spread to the level of L-3 or even L-2 nerve roots.

The physical examination helps in localization as well. The straight-leg-raise maneuver (so-called Lasègue's sign) stretches the sciatic nerve and its contributing roots and is generally positive in lesions affecting L-5, S-1, and S-2. The absence of the ankle jerk in a patient this age is very likely to be abnormal and, again, suggests involvement primarily of S-1 or S-2 fibers; the L-5 root contributes to the reflex, but, in most cases of L-5 radiculopathy alone, the Achilles reflex is spared. Absence of the left patellar reflex indicates involvement of the L2-4 roots or the femoral nerve. Taken together, the history and examination strongly suggest a lesion at the spinal level, affecting mid to lower lumbar and upper sacral nerve roots on the left and the upper sacral roots on the right. The bilateral nerve root involvement clearly favors an intraspinal process but certainly does not exclude bilateral paraspinal lesions. We are not told anything about localized tenderness or cutaneous lesions overlying the spine and must assume that they were not present.

Next we should deal with the nature of the process, and here the clinical picture can take us only so far. We know the age and sex of the patient, we know that the pain has been progressive over one and one half years, and we know the process very likely affects the nerve roots, as discussed above. Clearly, the most common cause of this particular configuration of pain, which we can call *sciatica*, is lumbar disc herniation. Actually, there is nothing in this protocol that would allow me to exclude that diagnosis, although progressive pain, especially with the hint of rostral spread over time, is more suggestive of an expanding lesion. A central disc protrusion, especially at L-3 or even L-4, could certainly cause pain in this configuration as well as the observed neurologic signs.

My suspicions, however, lie elsewhere in this case. There are many other possible causes of back and leg pain of this type, with evidence of lumbosacral radiculopathy. Congenital lesions, including diastematomyelia and other dysraphic states, could be considered, but the age at onset, the progression, and the lack of cutaneous and other skeletal anomalies make it unlikely. Extradural infection, either from the disc space or the epidural space itself, can produce this very picture, including the progression. Most often, however, the course is shorter, and the lack of predisposing causes or underlying disease, as well as the lack of local tenderness or evidence of systemic infection, renders this an unlikely diagnosis.

Vascular malformations can and often do occur at this location, and the clinical picture could be similar. Again, without a cutaneous clue or a localized bruit, I cannot make this diagnosis and will discard it. Had the diagnosis of arteriovenous malformation been suspected, an angiogram most likely would have been performed.

The most likely process is a neoplasm. Here we must consider a number of primary as well as secondary or metastatic tumors, although we can, I think, summarily dismiss the majority of these on clinical or statistical grounds. In the final analysis, we have to rely on the radiographic findings to help us narrow the differential diagnosis more definitively.

Tumors arising from the skeleton itself must be considered. These may be benign, such as chondromas, osteoblastomas, angiomas, giant-cell tumors, or aneurysmal bone cysts, or they may be malignant, including osteosarcomas and chondrosarcomas. The only skeletal tumor worthy of more than brief mention in this setting



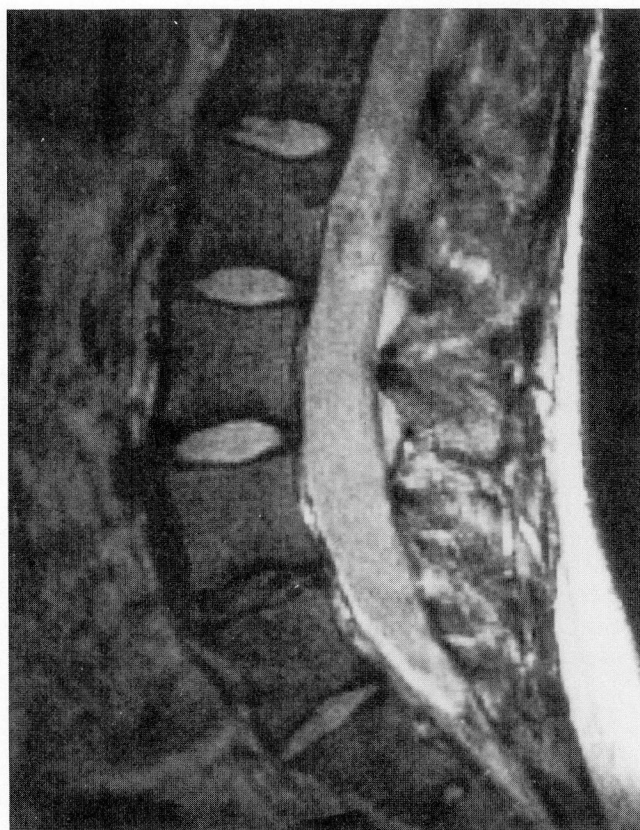
would be the chordoma. Although more often rostral along the neuraxis, these can arise from notochordal remnants in the sacrococcygeal region and can produce a painful cauda equina syndrome.<sup>1</sup> The relatively rapid evolution, the lack of lower sacral involvement, and the male predominance of chordoma lead me to reject this as an unlikely diagnosis.

Another primary tumor that should be considered is the lipoma.<sup>2</sup> This can be intradural or extradural. The latter are uncommon and mostly thoracic. Intradural lipomas are also rare in the lumbar region, are generally seen in younger patients, and the clinical course is usually longer, with root pain appearing only late. A number of metastatic tumors should also be mentioned, particularly lymphoma. All of the features seen in this patient could be manifestations of such a lesion, although, typically, the course is somewhat shorter. Because we have no evidence of systemic malignancy or other sites of involvement, I will discard this idea as well. We have reported a primary lymphoma of the lumbar spinal cord, but this is exceedingly rare and I won't consider it further.<sup>3</sup>

Meningiomas are common spinal tumors and can certainly occur at this age, although the large majority appear in the fourth to sixth decades. They are more common in women and usually present with pain and neurologic symptoms and signs, either of myelopathy or radiculopathy. They most frequently occur, however, in the thoracic region, less commonly in cervical, and only occasionally at the lumbosacral level.<sup>4</sup> I believe this is an unlikely diagnosis in the present case.

This leads me to what I believe are the most likely possibilities: Schwannoma (or conceivably neurofibroma) and ependymoma. Either one of these, in my view, could easily give rise to this picture, and nothing in the protocol excludes either diagnosis. Schwannomas (or neurinomas) are common spinal tumors, and the peak incidence is between the ages of 25 and 40 years. While about half are at the thoracic level, up to 25% are lumbar in origin.<sup>4</sup> Since Schwannomas arise from the nerve root, radicular pain followed by neurologic signs would be expected. The intraspinal expansion of the tumor could easily account for the contralateral root compression noted in this case. Overall, this diagnosis is appealing.

Finally, we must consider the ependymoma, which would statistically be the most common and, hence, most likely diagnosis. Indeed, the



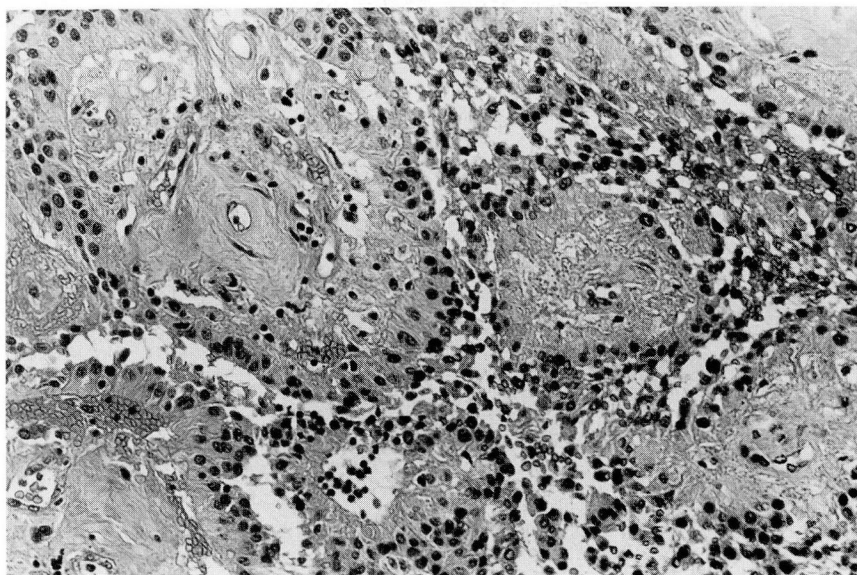
**Fig. 1.** Sagittal, T2-weighted magnetic resonance image of lumbar spine. An ovoid mass occupying the entire anteroposterior diameter of the lumbar canal at L-2 is seen.

level of the cauda equina is the favorite spinal site for this glial-derived tumor,<sup>5</sup> which usually arises from the filum terminale, where it most commonly takes the myxopapillary form histologically.<sup>6</sup> Although males are more frequently affected, representing about 60% in several series, the age of our patient is typical, since peak incidence is in the third and fourth decades of life.<sup>5</sup> Clinically, as well, our case would be characteristic; in the 77 patients reported on by the Mayo Clinic group,<sup>6</sup> 96% presented with low back pain with or without sciatica, and sensorimotor disturbances developed in 53%.

Before making a final choice, I would like to review the radiologic studies to see if they would help us choose among the various possibilities discussed and, particularly, between the last two tumor types.

*Dr. Scott Rosenbloom:* A sagittal, T2-weighted MR image of the lumbar spine shows a relatively well-defined, ovoid mass occupying the entire anteroposterior diameter of the lumbar canal at the level of L-2 (*Fig. 1*). The mass is higher in signal intensity than the surrounding cerebrospi-





**Fig. 2.** Hematoxylin-eosin-stained section of the tumor demonstrating a pseudopapillary neoplasm with vessels at the core of many of the papillae. Magnification  $\times 300$ .

nal fluid, although there are some areas of decreased spinal signal within it. Note the degeneration of the L4-5 intervertebral disc, evidenced by its lack of intense signal on this pulse sequence, as well as mild bulging of the disc.

*Dr. Richard Lederman:* The MR image appears to confirm the presence of a tumor at the suspected level. Its configuration, location, and signal intensity on the T2-weighted image would be consistent with either ependymoma or Schwannoma. The apparent intradural location would exclude chordoma, and I believe the appearance would not be compatible with lipoma. On the basis of the reasoning advanced above, I believe that this patient will prove to have had an ependymoma of the cauda equina. I assume that the surgical procedure was an attempt at gross total removal.

### Clinical diagnosis

Ependymoma of the cauda equina

### Pathological discussion

*Dr. Russell Hardy:* An intradural exploration was carried out, disclosing an encapsulated, pink tumor that arose from the filum terminale. The nerve roots of the cauda equina were splayed over and around the tumor but were separate from it. A biopsy of the lesion was performed, and an attempt was made to remove the tumor, but this was unsuccessful due to its extreme friability. The tumor was debulked and dissected

free from the surrounding nerve roots. The filum itself was divided proximally and distally, and the remaining tumor was separated rather easily from the nerve roots, except where it adhered to the floor of the canal and one or two small rootlets. At the end of the procedure, the surgeons were confident that the tumor had been completely removed.

*Dr. Melinda Estes:* Histologically, a delicate fibrous capsule surrounded portions of the tumor, which was composed of pseudopapillae lined by flattened cuboidal to columnar cells (*Fig. 2*). The cells were mildly pleomorphic and had oval to elongate nuclei with a delicate chromatin pattern. Staining for glial fibrillary acidic protein was positive. Rare mitoses were present. No hemorrhage or hemosiderin deposition was found. The tumor was highly vascular and associated with a mucoid matrix surrounding many of the vessels. A moderate amount of mucin, staining positive with Alcian blue, was present intra- as well as intercellularly.

The histologic pattern and location were characteristic of a myxopapillary ependymoma. This variant of ependymoma is, with rare exception, limited to the filum terminale.<sup>6</sup> The tumor is more common in adults and has a better prognosis than cellular, intraspinal ependymomas.<sup>7</sup> In a review of 77 cases of myxopapillary ependymoma, Sonneland et al found the prognosis to be independent of mitotic activity, extensive mucinous change, or cytologic atypia.<sup>6</sup> The recur-

rence rate in patients with myxopapillary ependymoma appears to be related to the extent of surgical resection.<sup>6</sup> This patient underwent piecemeal gross total removal of the tumor, which, in one series, was associated with a recurrence rate of 19%, a rate similar to that for patients who underwent gross total removal of tumors.<sup>6</sup> Local recurrence is the most common pattern, and spread via the cerebrospinal fluid with intracranial tumor is rare.<sup>8</sup>

*Dr. Srinivasan Vijayakumar:* This woman's clinical problem typifies the dilemma one often faces in the management of the ependymoma of the spinal cord and cauda (cauda equina, conus medullaris, and filum terminale). What is the role of surgery? How aggressive should the surgery be? What are the indications for radiotherapy?

Because ependymoma of the spinal cord is uncommon, the majority of reports in the literature have only a small number of patients. In general, these patients are added to study groups over many years and have been treated with different surgical and radiotherapy techniques. In addition, there is almost universal intentional or unintentional patient selection. For these reasons, making treatment recommendations is a challenging task.

However, from a critical review of the literature, the following observations can be made:<sup>9</sup> 1) ependymoma of the cauda equina has a long, relatively benign natural history; 2) complete resection is possible, and recurrences are rare after total excision; 3) when the tumor has not been totally excised, radiotherapy can prevent recurrences and improve results; 4) myxopapillary ependymoma is more common in the region of the cauda equina and is biologically more benign than its cellular counterpart.<sup>7,10,11</sup>

There are authors who recommend total surgical excision in all patients; there are others whose approach is biopsy followed by radiotherapy. In our opinion, the treatment must be individualized, with one important dictum in mind, "Do no harm." The patient and the family, the neurologist, the neurosurgeon, and the radiation oncologist should all be part of the decision-making process.<sup>12</sup>

Combining the results from 17 series in the literature,<sup>9</sup> complete surgical excision appears to be possible in about 50% of the patients, although these figures can be as high as 85–100% with modern advances in microsurgical technique.<sup>13,14</sup> Recent surgical improvements include: 1) use of intraoperative ultrasound during laminectomy;

2) intraoperative physiological monitoring such as somatosensory evoked potential (SSEP) monitoring; 3) use of ultrasonic aspirators; and 4) CO<sub>2</sub> and Nd-YAG laser.<sup>13,15–17</sup> The majority of the patients with cauda ependymomas are long-term survivors after total surgical resection. If only biopsy or subtotal resection can be achieved, postoperative radiotherapy achieves excellent local control and long-term survival.

Based on a review of the literature,<sup>9</sup> the following recommendations can be made: If possible, the tumor should be totally resected. However, caution should be taken not to produce neurological damage. Removal at any cost,<sup>5</sup> is not acceptable.<sup>18</sup> In specific circumstances with infiltration of the spinal cord, conus medullaris, or nerve roots, as much safe debulking as possible should be performed, and further control should be left to radiotherapy. With advances in surgical techniques, decompressive laminectomy alone or biopsy alone are unacceptable.<sup>13</sup> If total removal is not possible, postoperative radiotherapy should be administered. For ependymoma of the spinal cord, a dose of 45–50 Gy with the conventional 1.8–2.0 Gy per fraction is recommended. For the cauda group, 50–55 Gy can be delivered without significant risk of neurological sequelae, since the tolerance of nerve roots is higher than that of the spinal cord. A margin of two vertebral bodies above and below the gross tumor should suffice. Since the incidence of spread through cerebrospinal fluid (CSF) is low (about 7%), craniospinal axis irradiation is not indicated, except if the CSF cytologic studies are abnormal. Using external megavoltage radiotherapy, the risk of radiation myelopathy is low with the doses recommended.<sup>11,19–22</sup> Although Marsa et al<sup>23</sup> speculate that spinal cord with tumor may be more sensitive than normal spinal cord, Kopelson<sup>22</sup> did not find a case of radiation myelopathy among 19 patients who lived for at least one year with intramedullary spinal cord glioma treated with radiation therapy. The long-term sequelae of craniospinal axis irradiation among children tested for medulloblastoma has been reviewed recently.<sup>24</sup> Since the majority of these sequelae are due to the treatment of spinal axis with megavoltage x-rays or gamma rays, therapy with electrons, whose physical properties include rapid fall-off, may be an attractive alternative to avoid irradiating normal structures such as vertebral bodies, ovaries, thyroid, etc., in the radiotherapy of ependymoma of spinal cord.<sup>24–26</sup>

*Dr. Melinda Estes:* The patient did not receive



radiation therapy and has remained asymptomatic.

### Final pathological diagnosis

Myxopapillary ependymoma of the filum terminale.

Melinda L. Estes, MD  
Department of Pathology  
The Cleveland Clinic Foundation  
9500 Euclid Avenue  
Cleveland, Ohio 44106

### References

- Dahlin DC, MacCarty CS. Chordoma: a study of fifty-nine cases. *Cancer* 1952; **5**:1170-1178.
- Giuffrè R. Intradural spinal lipomas. Review of the literature (99 cases) and report of an additional case. *Acta Neurochir* 1966; **14**:69-95.
- Mitumoto H, Breuer AC, Lederman RJ. Malignant lymphoma of the central nervous system: a case of primary spinal intramedullary involvement. *Cancer* 1980; **46**:1258-1262.
- Nittner K. Spinal meningiomas, neurinomas and neurofibromas and hourglass tumours. [In] Vinken PJ, Bruyn GW, eds. *Handbook of Clinical Neurology*, Vol 20. Amsterdam, North Holland Publishing Co., 1976, pp 177-322.
- Fischer G, Tommasi M. Spinal ependymomas. [In] Vinken PJ, Bruyn GW, eds. *Handbook of Clinical Neurology*, Vol 20, Amsterdam, North-Holland Publishing Co, 1976, pp 353-387.
- Sonneland PRL, Scheithauer BW, Onofrio BM. Myxopapillary ependymoma: a clinicopathologic and immunocytochemical study of 77 cases. *Cancer* 1985; **56**:883-893.
- Mørk SJ, Løken AC. Ependymoma: a follow-up study of 101 cases. *Cancer* 1977; **40**:907-915.
- Rubinstein LJ, Logan WJ. Extraneural metastases in ependymoma of the cauda equina. *J Neurol Neurosurg Psychiatry* 1970; **33**:763-770.
- Vijayakumar S, Estes ML, Lederman R, Hardy RW, Rosenbloom S, Thomas F. Roles of surgery and radiotherapy in the optimal management of ependymoma of the spinal cord and "cauda." *Cleve Clin J Med* **55**:163-170.
- Kopelson G, Linggood RM, Kellinman GM, Doucette J, Wang CC. Management of intramedullary spinal cord tumors. *Radiology* 1980; **135**:473-479.
- Marks JE, Adler SJ. A comparative study of ependymomas by site of origin. *Int J Radiat Oncol Biol Phys* 1982; **8**:37-43.
- Radiation Oncology in Integrated Cancer Management: Report of the Inter-Society Council for Radiation Oncology, November 1986.
- Cooper PR, Epstein F. Radical resection of intramedullary spinal cord tumors in adults: recent experience in 29 patients. *J Neurosurg* 1985; **63**:492-499.
- Fischer G, Mansuy L. Total removal of intramedullary ependymomas: follow-up study of 16 cases. *Surg Neurol* 1980; **14**:243-249.
- Perria C, Francaviglia N, Borzone M, Chinnici A, Piano E, Pacini P. The value and limitations of the CO<sub>2</sub> laser in neurosurgery. *Neurochirurgia* 1983; **26**:6-11.
- Beck OJ. The use of Nd-YAG and CO<sub>2</sub> laser in neurosurgery. *Neurosurg Rev* 1980; **3**:261-266.
- Kornblith PL, Walker MD, Cassady JR. Neoplasms of the central nervous system. [In] DeVita VT Jr, Hellman S, Rosenberg SA, eds. *Cancer: Principles and Practice of Oncology*, 2nd Ed. Philadelphia, JB Lippincott, pp 1437-1510.
- Scott M. Infiltrating ependymomas of the cauda equina: treatment by conservative surgery plus radiotherapy. *J Neurosurg* 1974; **41**:446-448.
- Peschel RE, Kapp DS, Cardinale F, Manuelidis EE. Ependymomas of the spinal cord. *Int J Radiat Oncol Biol Phys* 1983; **9**:1093-1096.
- Shaw EG, Evans RG, Scheithauer BW, Ilstrup DM, Earle JD. Radiotherapeutic management of adult intraspinal ependymomas. *Int J Radiat Oncol Biol Phys* 1986; **12**:323-327.
- Wara WM, Phillips TL, Sheline GE, Schwade JG. Radiation tolerance of the spinal cord. *Cancer* 1975; **35**:1558-1562.
- Kopelson G. Radiation tolerance of the spinal cord previously-damaged by tumor and operation: long term neurological improvement and time-dose-volume relationships after irradiation of intraspinal gliomas. *Int J Radiat Oncol Biol Phys* 1982; **8**: 925-929.
- Marsa GW, Goffinet DR, Rubinstein LJ, Bagshaw MA. Megavoltage irradiation in the treatment of gliomas of the brain and spinal cord. *Cancer* 1975; **36**:1681-1689.
- Vijayakumar S, Muller-Runkel R. Medulloblastoma: Are we over-treating? *J Natl Med Assoc* 1985; **77**:89-95.
- Muller-Runkel R, Vijayakumar S. Spinal axis irradiation with electrons: measurements of attenuation by the spinal processes. *Med Phys* 1986; **13**:539-543.
- Vijayakumar S, Muller-Runkel R. Medulloblastoma therapy using electron beams. *Radiology* 1985; **157**:541-542.