

Prosthetic ball free in the left ventricle in a patient with an aortic Starr-Edwards prosthesis

Daniel D. Schrader, MD
Miguel A. Sellanes, MD
Norberto Kelijman Laschover, MD
Roberto J. Macchi, MD, FACC
Marcos Eserequis, MD
Jorge I. Mizraji, MD
Carlos A. Nojek, MD

Ball-valve intermittent poppet dislodgment into the left ventricle is a rare complication, having been reported previously only in patients with the Braunwald-Cutter prosthesis. This type of variance is reported in a patient with an aortic Starr-Edwards prosthesis and minimal symptoms.

Index term: Heart valve prosthesis
Cleve Clin J Med 1988; 55:175-177

Several cases have been reported with prosthetic valve dysfunction including dislodgment of the ball from the cage and sudden death. We here describe a patient with intermittent dislodgment of the ball of the Starr-Edwards valve into the ventricle with no hemodynamic jeopardy and minimal symptoms.

Case report

This 51-year-old patient was transferred to our hospital (Hospital Español de Buenos Aires) on March 26, 1984, for surgical treatment of prosthetic valve dysfunction. In 1972, he had bacterial endocarditis, and, in 1973, he underwent aortic valve replacement for severe aortic regurgitation.

A Starr-Edwards prosthesis was implanted. The patient had an uncomplicated postoperative course and was very

active until two months before this admission, when he noticed a change in the prosthetic sounds, as well as palpitations. He had no other associated symptoms.

Physical findings

Physical examination revealed a well-built man in no acute distress. The blood pressure was 150/90 mm Hg, the pulse was regular at 70 beats per min. Examination of the neck showed no jugular venous distension. The lungs were clear. Cardiovascular examination revealed a point of maximal impulse at the fifth intercostal space and an intermittent pounding that could be felt 2 cm lateral from the midclavicular line. The first heart sound was normal, and the opening click of the aortic prosthesis also sounded normal, except for intermittent beats in which it could not be heard; after these pauses its intensity increased. The second heart sound had a normal pulmonary component and a normal-sounding closing click, which disappeared intermittently, as did the opening click. There was a 2/6 systolic ejection murmur in aortic area, as well as an intermittent 3/6 diastolic blowing murmur, which coincided with the pulse and point of maximal impulse findings (*Fig. 1*).

Laboratory findings

The electrocardiogram revealed a sinus rhythm and non-diagnostic STT changes. The chest radiograph showed mild cardiomegaly and clear lung fields. Blood studies were within normal limits except for prolonged prothrombin time, due to anticoagulants. The echocardiogram revealed mildly dilated left atrium. The left ventricle was moderately dilated, but with an increased percentage shortening. At the mitral level, we detected an intermittent fine tremor of the anterior mitral leaflet as well as an early closure. Also notice the ball artifact (*Fig. 2*). On the bidimensional echocardiogram, the prosthetic ball could be seen at the apex of the

Cardiology Institute, Hospital Español de Buenos Aires (D.D. S., M.A.S., N.K.L., R.J.M., M.E., J.I.M.) and Cardiology Department, Policlínico Ferroviario Central (C.A.N.), Buenos Aires, Argentina. Submitted Dec. 1986; accepted Oct. 1987.

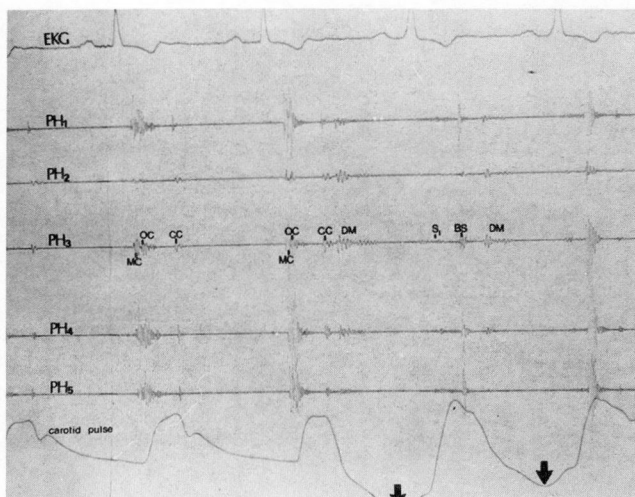


Fig. 1. Phonocardiogram in aortic area and carotid pulse tracing. The first beat shows a normal opening click with no diastolic murmurs; the carotid pulse is normal. In the second beat, the opening click is unchanged and the closing click is slightly wider, followed by a diastolic murmur coincident with a drop (arrows) in the pulse during diastole. The third beat has a very diminished first heart sound, a midsystolic ball sound, and diastolic murmur. *BS* = ball sound; *CC* = closing click; *DM* = diastolic murmur; *MC* = mitral closure; *OC* = opening click; *PH1-5* = phonocardiogram; *SI* = first heart sound.

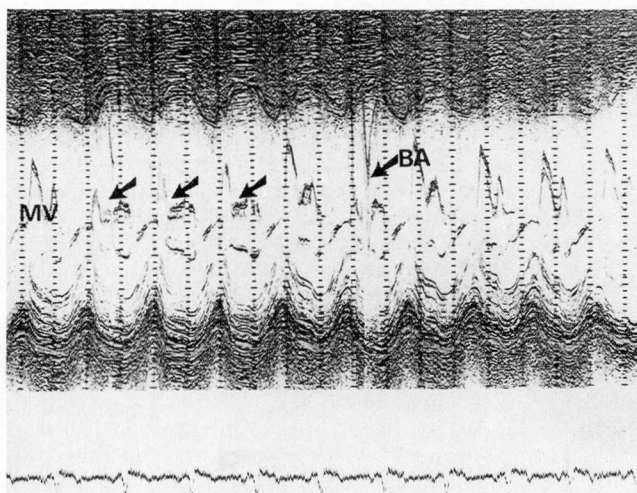


Fig. 2. Mitral valve echocardiogram. The first beat shows a normal mitral valve, followed by three beats (printed with arrows) with early closure and diastolic tremor of the anterior leaflet. The sixth beat shows a ball artifact in mid-diastole. *BA* = ball artifact; *MV* = mitral valve.

left ventricle (Fig. 3). It was difficult to visualize the motion of the ball during real time, but this motion was clearly seen at low speed on the tape. Cardiac catheterization revealed normal coronary arteries with an abnormal pressure curve (Fig. 4) coincident with the intermittent dislodgment of the ball into the left ventricle (Fig. 5).

Surgical findings

During open heart surgery to remove the prosthesis, the ball was found in the left ventricular cavity. The ball was found to have a fissure that allowed it to slide through the ring of the cage as well as through the struts (Fig. 6). The

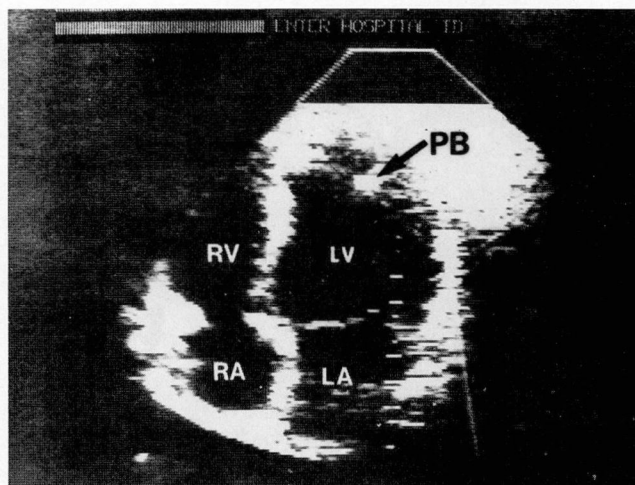


Fig. 3. Four-chamber view. The prosthetic ball can be seen at the apex of the left ventricle. *LA* = left atrium; *PB* = prosthetic ball; *RA* = right atrium; *RV* = right ventricle.

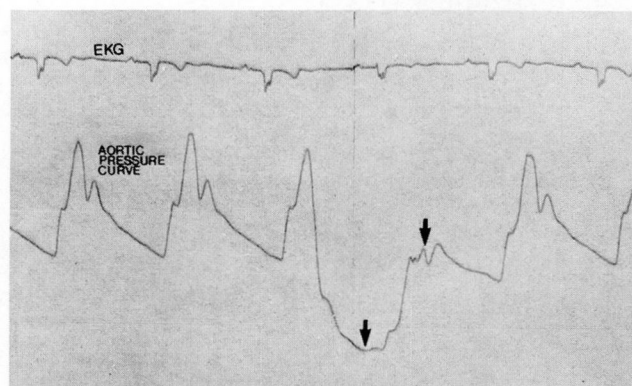


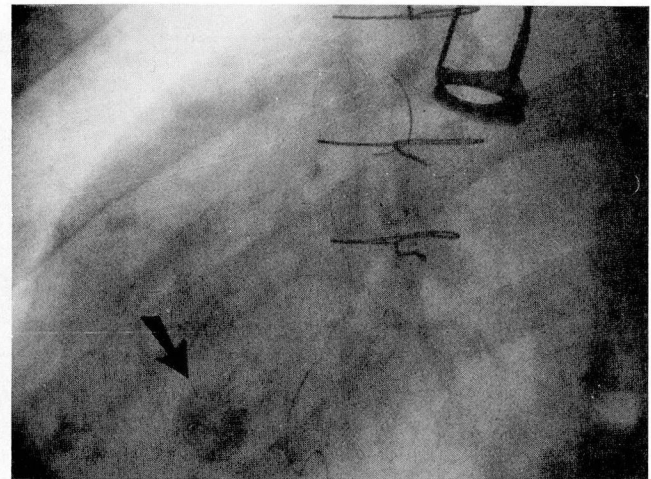
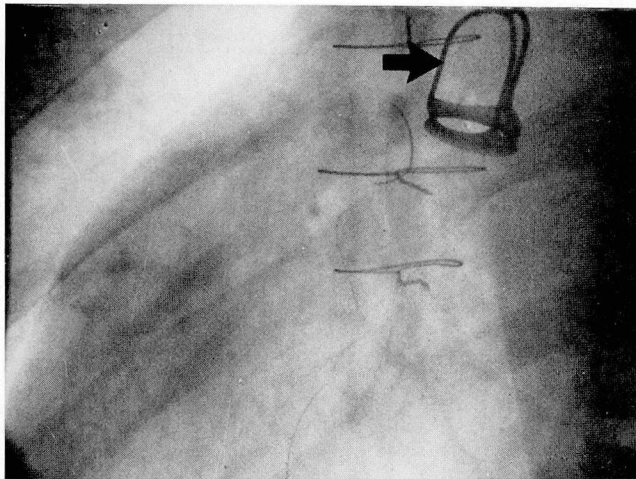
Fig. 4. Aortic pressure curve. The first two beats are normal, the third and fourth show a similar diastolic dip as that of the carotid pulse (Fig. 1).

valve was replaced by a Medtronic-Hall No. 23 and the postoperative course was uncomplicated.

Discussion

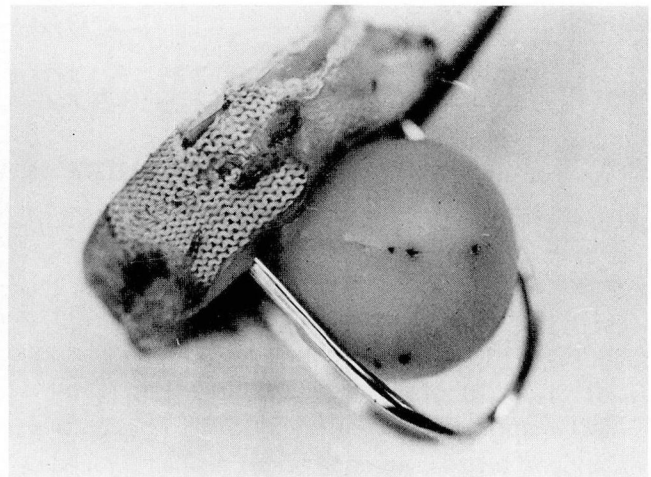
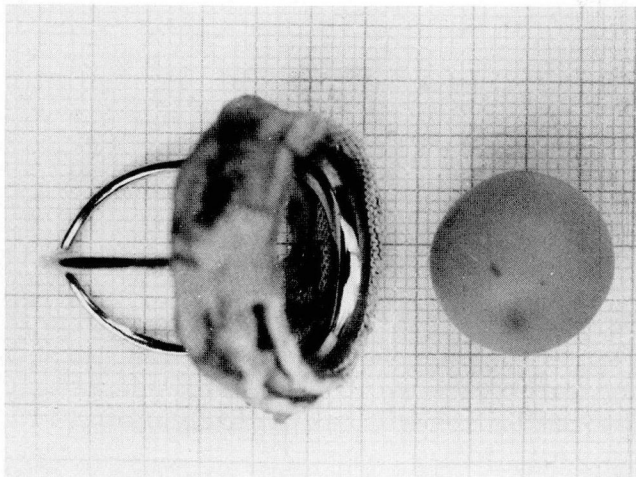
There have been several reports in the literature of Starr-Edwards prosthetic dysfunction, some of them with fatal outcome.¹⁻⁴ Nonfatal prosthetic poppet dislodgment into the left ventricle was reported by Kunstadt et al⁵ in 1976 in a patient with a Braunwald-Cutter aortic valve prosthesis as well as by Yakirevich et al⁶ in 1984 in a patient with mitral and aortic Braunwald-Cutter prostheses; the physical findings in both these cases were similar to those in our patient. Intermittent poppet dislodgment into the left ventricle from a Starr-Edwards prosthesis in a nearly asymptomatic patient has not been reported before. Variance in this case was due to cracking and diameter reduction of the poppet because of abrasion.

As suggested by Hysten et al,⁷ aortic ball variance most frequently includes increase in size and



A, B

Fig. 5. A. Fluoroscopic view in the left anterior oblique projection. Ball in the cage.
B. Same projection as above, ball free in the left ventricle.



A, B

Fig. 6. A. Prosthesis with ball out of the cage through the ring.
B. Prosthesis with ball between struts.

weight of the poppet due to lipid infiltration, and it is uncommon to find abrasion damage and loss of weight of the poppet, as in this case. It is difficult to explain why the poppet persisted in the cage intermittently and did not move freely back and forth through the ring with a fatal outcome. Because the ball was asymmetrical, the ring may have stopped it when it was positioned in the large diameter, and it may have fallen into the left ventricular chamber when the small diameter was presented to the ring.

Acknowledgment

We thank Jacqueline Schrader for her assistance in the preparation of this manuscript.

Daniel D. Schrader, MD
Mariano Pelliza 1858
(1636) Olivos
Pcia. Buenos Aires
Republica Argentina

References

1. Ablaza SG, Blanco G, Maranhao V, Goldberg H. Fatal extrusion of the ball from a Starr-Edwards aortic valve prosthesis: report of a case. *J Thorac Cardiovasc Surg* 1965; **50**:401-409.
2. Mackenzie JW, Almond CH. Expulsion of ball from aortic valve prosthesis. *Ann Thorac Surg* 1966; **2**:435-437.
3. Newman MM, Hoffman MS, Gesink MH. Mechanical failure of Starr Edwards aortic prosthesis due to ball fracture. *J Thorac Cardiovasc Surg* 1967; **53**:398-400.
4. Hairston P, Summerall CP, Muller WH. Embolization of silastic ball from Starr Edwards prosthesis. *Ann Surg* 1967; **166**:817-819.
5. Kunstadt D, Adeyemo A, Clauss RH. Aortic insufficiency: a result of intermittent migration of aortic valve prosthetic poppet. *JAMA* 1976; **235**:2847-2848.
6. Yakirevich V, Miller HI, Shapira I, et al. Intermittent poppet dislodgment in a Braunwald-Cutter prosthesis: noninvasive diagnosis and successful surgical treatment. *J Am Coll Cardiol* 1984; **3**:442-446.
7. Hylén JC, Kloster FE, Starr A, Griswold HE. Aortic ball variance: diagnosis and treatment. *Ann Intern Med* 1970; **72**:1-8.