



Carcinoid tumors of the terminal ileum simulating Crohn's disease

SEID HOSSEIN MIR-MADJLESSI, MD, FACP; EUGENE I. WINKELMAN, MD, FACP; GARY A. DAVIS, DO

■ Four patients had carcinoid tumors of the terminal ileum but were diagnosed as having Crohn's disease and treated for one to four years. The true diagnosis was made only at laparotomy when intestinal obstruction necessitated surgery. Metastasis was present in three cases, and two patients died of metastatic disease. Several diseases other than Crohn's disease may involve the terminal ileum and produce both clinically and radiologically similar features. Differential diagnostic criteria are discussed. Close follow-up, including carefully performed small bowel series with particular attention to the technical and interpretative details, will help avoid misdiagnosis. If the diagnosis is in doubt, there should be no hesitation to recommend a laparotomy.

□ INDEX TERMS: CARCINOID TUMOR; CROHN DISEASE; ILEAL NEOPLASMS □ CLEVE CLIN J MED 1988; 55:257-262

ALTHOUGH Crohn's disease is the most common illness affecting the distal ileum, numerous other diseases involve this segment of the small intestine. These include infections, various inflammatory lesions, endometriosis, metastatic carcinomas, and primary small intestinal tumors (polyps, adenocarcinoma, lymphoma, and carcinoid).¹⁻⁸

The clinical and radiological manifestations produced by these diseases may be indistinguishable from those of Crohn's disease. Generally, the diagnosis of Crohn's disease is a simple one when the classic radiological findings are present, but, on occasion, differentiating this from the other diseases that involve the terminal ileum may be difficult. The medical treatment of Crohn's disease is not altogether satisfactory, and at least 40% to 50% of the patients will require surgery at some time during the

course of their disease.⁹ Because of the high recurrence rate and the potential for subsequent intestinal resections, physicians are reluctant to recommend surgery in Crohn's disease, whereas surgery is the treatment of choice in some of the diseases that simulate Crohn's disease, and a delay may be detrimental. Although a few years ago Crohn's disease was considered to be an underdiagnosed illness,¹⁰ there is evidence that it is now overdiagnosed.¹

Recently, during an investigation concerning malignancy in Crohn's disease, we encountered four patients (out of 3,500) who had been diagnosed as having Crohn's disease and treated for it for one to four years, but were later found to have carcinoid tumor of the terminal ileum. A survey of the literature showed that cases simulating Crohn's disease are not rare.^{1,7,8,11} Unfortunately, the true magnitude of the problem is unknown and may be higher than it seems. To draw attention to this problem, we report these four cases and review problems of diagnosis and management in this type of patient.

Departments of Gastroenterology and Radiology, The Cleveland Clinic Foundation. Submitted for publication May 1987; accepted Nov 1987.

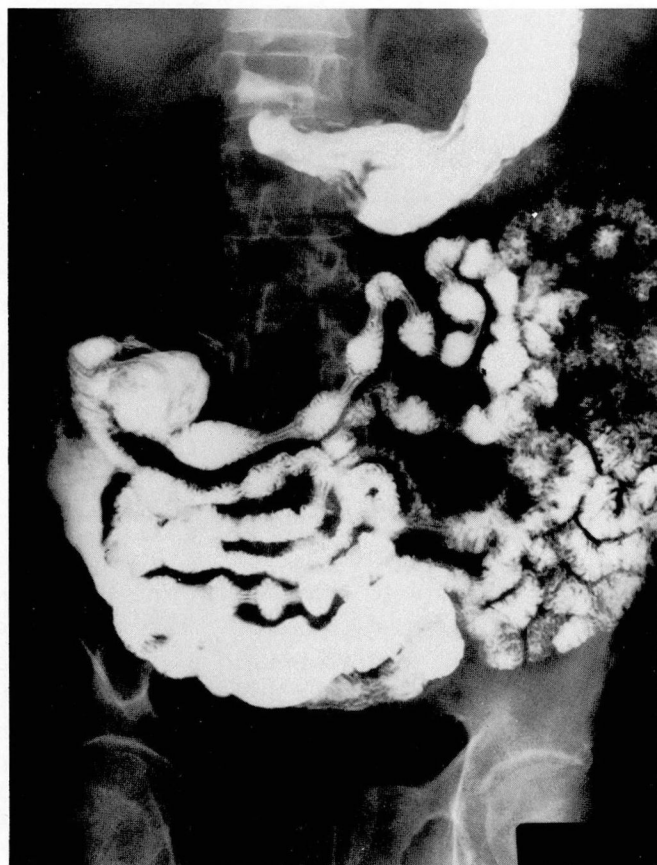

FIG. 1. Case 2. Radiograph from small bowel series showing multiple areas of narrowing and irregularities of the distal ileum, with mild prestenotic dilatation.

CASE REPORTS

Case 1

A 52-year-old white man was referred to The Cleveland Clinic Foundation in January 1964 with a four-year history of recurrent episodes of diarrhea, crampy abdominal pain, and abdominal distention. Investigations elsewhere, at the beginning of his illness and in October 1963, had been unrevealing. Physical examination was unremarkable. The barium enema examination was normal except for an irregular appearance of the cecum. The appendix and terminal ileum were not visualized. Small bowel radiographs showed normal jejunum, dilated ileal loops, and an abnormal mucosal pattern of the terminal ileum. Loops of the small intestine were described as appearing to surround a mass in the ileocecal area that was considered to be inflammatory. These changes were interpreted as being consistent with Crohn's disease.

Treatment with prednisone produced marked symptomatic improvement and weight gain. One year later, diarrhea and abdominal pain recurred. No new findings were noted in the small bowel series. Medical treatment was continued for six months, when complete small bowel obstruction supervened. At laparotomy, a mass involving the ileocecal area was found, and a right hemicolectomy and ileocolic anastomosis were performed. The gross pathological examination revealed a 5 x 5-cm dumbbell-shaped tumor extending through the full thickness of the intestinal wall into the serosal fat, obstructing the terminal ileum. The mesentery was firm and thick. Microscopically, the mass was an invasive carcinoid tumor. Postoperatively, the 24-hour urinary 5-hydroxy-indoleacetic acid (5-HIAA) level was normal when tested on several occasions. When last seen, six years later, the patient was well and asymptomatic.

Case 2

A 65-year-old white man was examined at The Cleveland Clinic Foundation in August 1974 and had a one-year history of nonbloody diarrhea, abdominal pain, and abdominal distention. Investigations elsewhere had included a normal upper gastrointestinal series and barium enema examination. A small bowel series was reported to show "distorted terminal ileum and nodular defects in the cecum consistent with Crohn's disease." The patient had been treated with corticosteroids for approximately one year, with some improvement. The previous radiographs, reviewed by our hospital radiologist, were consistent with a diagnosis of regional enteritis (Fig. 1).

The patient was treated with ACTH and salicylazosulfapyridine (SAS), with marked clinical improvement. He did well until December 1975, when diarrhea and abdominal pain recurred and he began losing weight. A repeat barium enema examination appeared normal, but the terminal ileum was not filled and loops of the small intestine appeared dilated. A small bowel series showed only ileal dilatation, because the terminal ileum could not be visualized. The patient had intermittent relapses of symptoms until July 1977, when complete small bowel obstruction occurred. At this time, the patient appeared chronically ill, with hepatomegaly, abdominal distention, and edema of the lower extremities. At laparotomy, a mass involving the terminal ileum was noted. Metastasis involved the retroperitoneal and pancreatic lymph nodes as well as the liver. A right hemicolectomy and ileocolic anastomosis were performed. The resected specimen contained a 4 x 2.5 x 2-cm firm tumor that extended through the intestinal wall, causing a marked

narrowing of the lumen. Microscopically, the tumor was a malignant carcinoid that involved the terminal ileum, its serosa, the appendix, and the periappendicular fat. Lymph nodes and the liver also contained carcinoid tumor. The patient died of metastatic carcinoid in September 1983. During the intervening 74 months, the 24-hour urinary 5-HIAA level ranged between 36 and 163 mg (normal less than 10 mg). Evidence of the carcinoid syndrome was never observed.

Case 3

A 62-year-old white woman was examined at the Cleveland Clinic Foundation in September 1975, and had a one-year history of "attacks of Crohn's disease" consisting of recurrent episodes of abdominal pain, diarrhea, and vomiting. Investigations elsewhere had included a barium enema examination that showed "a nodular mucosal pattern in the colonic flexures, contractions of the colon and loss of haustration in the left colon." The small bowel loops were dilated, and no reflux into the terminal ileum was obtained. A small bowel radiographic series using meglumine diatrizoate (Gastrografin) had shown "delayed transit and dilatation of intestinal loops." A diagnosis of Crohn's disease had been made, and the patient had been treated with ACTH and prednisone, with no improvement.

On physical examination, the abdomen appeared distended and tender. The proctosigmoidoscopic examination to a distance of 18 cm was normal. Complete small bowel obstruction led to a laparotomy, which revealed dilatation of the distal 60 cm of the ileum. There were adhesions from the ileum to the pelvic organs and to the leaves of its own mesentery. The colon was also adherent to the inflammatory mass in the ileocecal area. Tiny nodules were seen on the peritoneal surface, and a 1.5-cm mass was felt in the distal pancreas. A segmental resection of the ileum with end-to-end anastomosis was performed.

Macroscopically, the resected specimen consisted of loops of the ileum matted together by fibrosis and multiple adhesions. The bowel wall and the mucosa were grossly edematous and thick and there were multiple narrowings of the intestinal lumen. No ulceration or fistulas were present. The mesenteric fat appeared inflamed. The microscopic examination showed a malignant carcinoid involving the ileum and extending to the appendix and the mesentery. The lymph nodes were tumor-free. The pancreatic mass consisted of a hyalinoma and the peritoneal nodules of chronic inflammatory aggregates containing foreign-body reaction granulomas.

Postoperatively, the patient received four courses of streptozotocin and 5-fluorouracil and died in January 1976 of metastatic carcinoid. The 24-hour urinary excretion of 5-HIAA was not increased during the postoperative period.

Case 4

A 49-year-old white man had been well until June 1980 when abdominal pain and distention developed. A barium meal study, barium enema examination, and oral cholecystography were normal. During hospitalization elsewhere, colonoscopy to the cecum had shown a normal colonic mucosa and some inflammation of the ileocecal area. A biopsy of that area had revealed focal infiltration of mononuclear cells consistent with a chronic nonspecific inflammation. The small bowel series had been reported to show "a segment of the terminal ileum exhibiting irregular mucosal pattern" (Fig. 2), strongly suggestive of Crohn's disease. SAS was given, without benefit, but the addition of prednisone resulted in marked clinical improvement. Prednisone was continued for several months, tapered off, and eventually discontinued. The remission continued until early 1983 when abdominal pain and diarrhea reappeared. At this time, treatment with prednisone did not benefit the patient. A small bowel series in March 1984 showed dilated ileal loops and spiculated distal ileum (Fig. 3).

The patient was referred to The Cleveland Clinic Foundation in April 1984 for further investigation. On physical examination, the right lower abdominal quadrant was tender and bowel sounds were active. A double-contrast barium enema examination appeared normal; the terminal ileum was not visualized. The clinical impression was of obstructing Crohn's disease of the ileocecal area. At laparotomy, a submucosal tumor was observed that involved the distal ileum and narrowed the lumen. Adjacent lymph nodes were involved, but the liver was intact. A segment of the terminal ileum was resected, and ileoileal anastomosis was performed. The specimen contained a 3 x 3-cm mass that narrowed the intestinal lumen and involved the full thickness of the ileum. No mucosal ulcerations were seen. The microscopic examination showed a malignant carcinoid invading the lymphatics and extending through the wall into the mesentery. Four of the seven lymph nodes contained carcinoid tumor. The postoperative course was uneventful. When last examined in May 1985, the patient was well. The 24-hr urinary excretion of 5-HIAA remained normal.

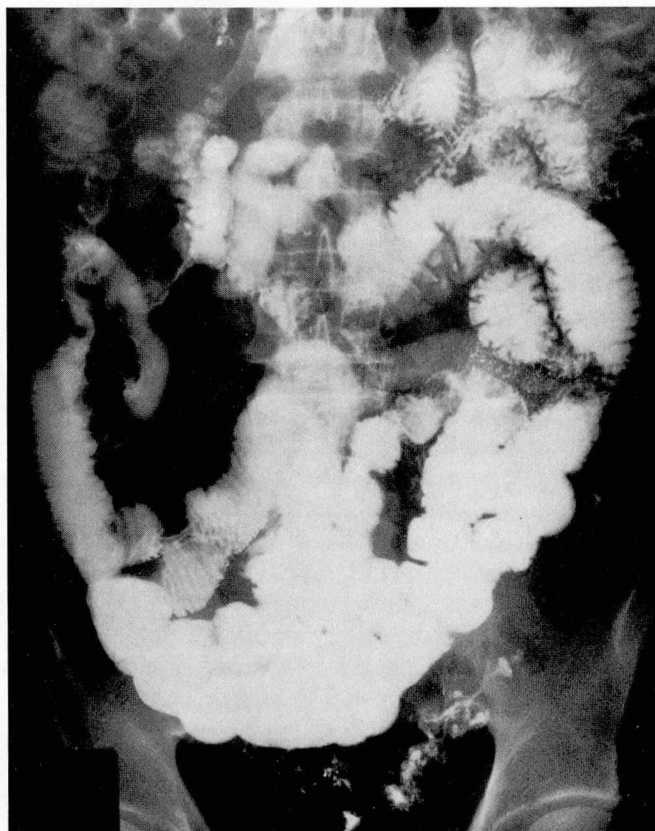


FIG. 2 Case 4. Radiograph from small bowel series showing multiple narrowed, irregular areas of the terminal ileum and mild prestenotic dilatation.

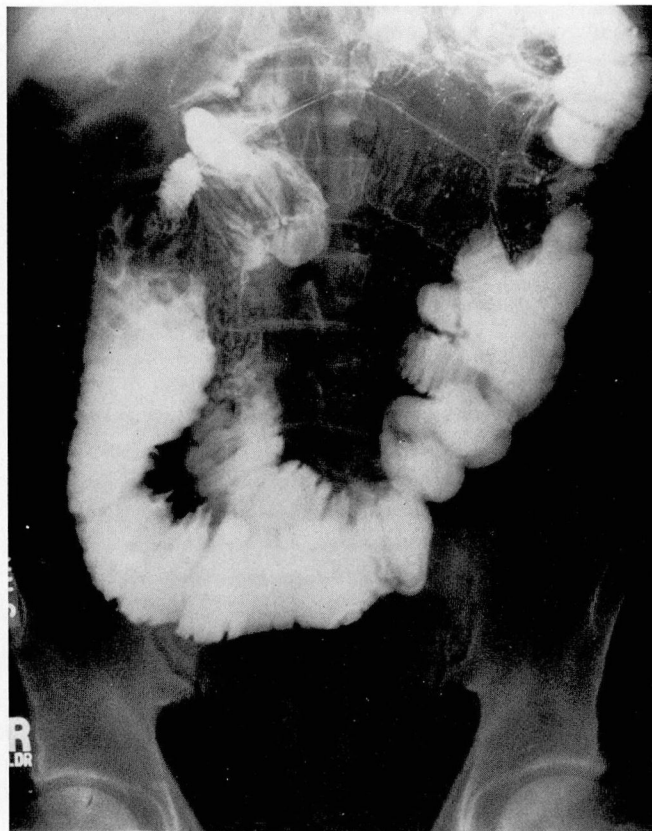


FIG. 3. Case 4. Radiograph from repeat small bowel series showing marked dilatation of loops of the ileum and spiculated appearance of the mucosa.

DISCUSSION

We have described four cases of carcinoid tumors of the terminal ileum that both clinically and radiologically simulated Crohn's disease. They were treated for one to four years with ACTH, prednisone, and SAS and showed marked clinical improvement, lasting as long as three years in three patients. Only when complete small bowel obstruction necessitated laparotomy was the true nature of the disease discovered. No patient showed evidence of carcinoid syndrome.

Although a frequent site of involvement with Crohn's disease, the terminal ileum is involved with other pathological entities that may simulate Crohn's disease both clinically and radiographically. These include: infections (tuberculosis, yersiniosis, actinomycosis, and salmonellosis), inflammatory processes (adhesions, ischemia, and radiation), endometriosis, polyps, and both metastatic carcinomas and primary small bowel malignancies.¹⁻¹¹ Even though carcinoid tumors,¹²⁻¹⁶ adenocarcinomas,^{17,18}

and lymphomas¹⁸⁻²⁰ may rarely complicate Crohn's disease of the ileum the possibility of diseases other than Crohn's disease should be considered in occasional patients. Crohn's disease is a transmural inflammatory disease characterized by mononuclear and polymorphonuclear infiltration, granuloma formation, edema of the intestinal wall, and thickening and fibrosis of the submucosa.⁹ Fissuring and fistulization are common.⁹ The clinical manifestations are nonspecific and include diarrhea, crampy abdominal pain, weight loss, and abdominal masses.^{1,9,21} Typical radiological findings include thickening of the mucosa, nodular mucosal patterns, strictures, cobblestone appearance, skin areas, and asymmetrical involvement of the intestinal wall.²² A mass effect produced both by abscess formation and thickening and retraction of the mesentery may be present, and ulcerations, fissures, and fistulas are frequently observed.²²

Carcinoid tumors are the most common neoplasm of the ileum.⁷ They originate deep in the mucosa from the

Kulshitzki cells and spread outward to infiltrate the intestinal wall and to invade the mesentery and adjacent lymph nodes. The mesentery involved by a marked desmoplastic reaction becomes shortened, thickened, and fixed, causing kinking and angulation of the intestinal loops.^{7,8,22-24} Ulceration of the mucosa is rare, but mesenteric venous occlusion by the neoplasm causes edema of the mucosal folds.²³ Clinically, patients with carcinoid tumors present with diarrhea, abdominal pain, and weight loss.^{23,25} Intermittent small bowel obstruction occurs frequently.²⁵ This is usually related to the desmoplastic mesenteric reaction and less often to the tumor growth and intussusception.²² Typical radiographic features of carcinoid tumors include solitary or multiple discrete submucosal filling defects, either alone or accompanied by the manifestations of extensive mesenteric desmoplasia.^{7,23,24} In general, in the absence of carcinoid syndrome, the diagnosis of carcinoid tumor is seldom made preoperatively.^{22,25} An elevated level of 24-hour urinary 5-HIAA, if present, confirms the diagnosis.

Differentiating Crohn's disease from carcinoid tumor of the terminal ileum simulating Crohn's disease may be extremely difficult. The onset of symptoms in patients older than 45 years should alert the physician to the possibility of a diagnosis other than Crohn's disease. Indeed, all patients in our series, as well as some other series,^{1,4,11} were older than 45 years. The peak age at the onset of Crohn's disease is under 35 years,²⁶ and symptoms began after the age of 50 in only about 10% of these patients.²⁷ On the other hand although reported at any age, carcinoid tumors of the ileum generally appear after 50-60 years of age.²⁵ Clinically, the appearance of intestinal obstruction occurring at the onset or early in the disease is of some diagnostic help.⁴ Furthermore, an atypical clinical course and lack of response to an adequate medical treatment for Crohn's disease should raise the suspicion of another disease. Unfortunately, in both Crohn's disease and carcinoid tumor, the clinical course may be variable. Although recurrent early small bowel obstruction, especially in the absence of sepsis and fistulization, should suggest a diagnosis of carcinoid tumor, intestinal obstruction is common in Crohn's disease, being present in 35% of the patients with ileitis and in 44% of those with ileocolitis.²⁶ However, only one of our patients (case 3) had an atypical clinical course and continued to be symptomatic despite an "adequate medical treatment" for Crohn's disease. The remaining three apparently responded to the treatment and had "remission" lasting from one to as long as three years. The improvement may have been related to the anti-inflammatory effects of corticosteroids on the involved intes-

tine. Thus, a therapeutic response does not necessarily exclude the possibility of carcinoid tumor.

Stark et al,⁸ who reported the first case of metastatic carcinoid tumor of the ileum mimicking Crohn's disease, concluded that marked changes in the radiological appearance of the small bowel, showing transient ileitis-like features within a short time, were pathognomonic of carcinoid tumors. Andreson and Banks⁴ stressed that tethering and pleating of the ileal folds, sharp angulation of the involved ileum, amputation of the mucosal folds on the medial aspect of the cecum, and an abrupt demarcation between the stenotic tumor-involved ileum and the normal ileum are features specific to malignancies of the ileocecal area. Such a pattern was present in only one of our patients (Fig. 3). Endoscopic examination of the colon has been recommended by some authors as a means to differentiate Crohn's disease from other diseases involving the terminal ileum. Hyams et al⁶ obtained multiple colonoscopic biopsy specimens of the rectal and colonic mucosa in five patients where the differential diagnosis was between Crohn's disease and lymphoma of the small intestine. The colon had appeared normal both radiographically and endoscopically in these patients. Granulomas and focal colitis suggestive of Crohn's disease were found in three patients, thus obviating the need for a laparotomy. It should be noted that in Crohn's disease, granulomas are found in fewer than 15% of the biopsy specimens when the endoscopic appearance of the colon is normal.⁴ Furthermore, the finding of non-specific inflammation is not helpful in the differential diagnosis and may even be misleading, as was the case in one of our patients (case 4). Meyers et al³ recommended the use of deeper biopsies when considering a differential diagnosis between metastatic carcinoma and Crohn's disease of the colon. Close follow-up of the patients and radiological re-evaluation of the small intestine, either by single-contrast radiography or enteral clysis²⁸ with particular attention to those signs suggesting diseases other than Crohn's disease, are of utmost importance.

Other methods of investigation, such as abdominal angiography^{7,22,23} and computed tomography,⁷ may be of value in certain patients. However, if the diagnosis is in doubt, even when the response to medical treatment seems satisfactory, there should be no hesitation to recommend laparotomy.

EUGENE I. WINKELMAN, MD, FACP
Department of Gastroenterology
The Cleveland Clinic Foundation
One Clinic Center
9500 Euclid Avenue
Cleveland, Ohio 44195

REFERENCES

1. Chang SF, Burrell ML, Belleza MA, Spiro HM. Borderlands in the diagnosis of regional enteritis: trends in overdiagnosis and value of therapeutic trial. *Gastrointest Radiol* 1978; 3:67-72.
2. Tandon R, Buhac I, Rodgers JB Jr. Obstruction of the ileocecal valve by an adenomatous polyp mimicking regional enteritis. *Am J Dig Dis* 1972; 17:929-933.
3. Meyers MA, Ophilant M, Teixidor H, Weiser P. Metastatic carcinoma simulating inflammatory colitis. *AJR* 1975; 123:74-83.
4. Andreson JL, Banks PA. Tumors of the ileocecal region: differentiation from Crohn's disease. *Am J Gastroenterol* 1982; 77:910-912.
5. Adler SN, Lyon DT, Sullivan PD. Adenocarcinoma of the small bowel: clinical features, similarity to regional enteritis, and analysis of 338 documented cases. *Am J Gastroenterol* 1982; 77:326-330.
6. Hyams JS, Goldman H, Katz AJ. Differentiating small bowel Crohn's disease from lymphoma: role of rectal biopsy. *Gastroenterology* 1980; 79:340-343.
7. Clements JL Jr, Hixson GL Jr, Berk RN, Dodds WJ, Goldstein H. Gastrointestinal carcinoid tumors: an analysis of 104 cases. *Mt Sinai J Med* 1984; 51:351-359.
8. Stark S, Bluth I, Rubenstein S. Carcinoid tumor of the ileum resembling regional ileitis clinically and roentgenologically. *Gastroenterology* 1961; 40:813-817.
9. Kirsner JB, Shorter RG. Recent developments in "nonspecific" inflammatory bowel disease (first of two parts). *N Engl J Med* 1982; 306:775-785.
10. Dyer NH, Dawson AM. Diagnosis of Crohn's disease, a continuing source of error. *Br Med J* 1970; 1:735-737.
11. Verma VK. Multiple carcinoid tumour mimicking Crohn's disease: a case report. *J Ir Med Assoc* 1972; 65:412-413.
12. Wood WJ, Archer R, Schaeffer JW, et al. Coexistence of regional enteritis and carcinoid tumor. *Gastroenterology* 1970; 59:265-269.
13. Villote J, Mouchet A, Martin E, et al. Crohn's disease revealed by a vesico-intestinal fistula and associated with a carcinoid tumor of the small intestine. *Sem Hop Paris* 1969; 45:1620-1625.
14. Janin Y, Schwartz D, Beeker JM, et al. Crohn's disease and carcinoid tumor of the appendix in a child. *Z Kinderchir* 1981; 4:376-379.
15. Tehrani MA, Carfrae DC. Carcinoid tumor and Crohn's disease. *Br J Clin Prac* 1975; 29:123-124.
16. Van Landingham SB, Kluppel S, Symmonds R Jr, Snyder SK. Co-existing carcinoid tumor and Crohn's disease. *J Surg Oncol* 1983; 24:310-314.
17. Hawker PC, Gyde SN, Thompson H, Allan RN. Adenocarcinoma of the small intestine complicating Crohn's disease. *Gut* 1982; 23:188-193.
18. Radi MF, Gray GF Jr, Scott HW Jr. Carcinosarcoma of ileum in regional enteritis. *Hum Pathol* 1984; 15:385-387.
19. Glick SN, Teplick SK, Goodman LR, Clearfield HR, Shaner JD. Development of lymphoma in patients with Crohn disease. *Radiology* 1984; 153:337-339.
20. Morrison PD, Whittaker M. Tumores rari et inusitati: a case of Hodgkin's disease complicating Crohn's disease. *Clin Oncol* 1982; 8:271-272.
21. Meyer S, Janowitz HD. Crohn's disease: clinical features. [In] Berk JE, Haubrich WS, Kalser MH, Roth JLA, Schaffner F, eds. *Bockus Gastroenterology*. 4th ed. Vol 3. Philadelphia, WB Saunders, 1985, pp 2240-2259.
22. Pringot J, Bodart P. Inflammatory diseases, small bowel. [In] Margulis AR, Burhenne HJ, eds. *Alimentary Tract Radiology*. 3rd ed. St. Louis, CV Mosby, 1983, pp 917-961.
23. Boijesen E, Kaude J, Tylen U. Radiologic diagnosis of ileal carcinoid tumors. *Acta Radiol [Diag]* 1975; 15:63-82.
24. Bancks NH, Goldstein HM, Dodd GD Jr. The roentgenologic spectrum of small intestinal carcinoid tumors. *AJR* 1975; 123:274-280.
25. Warner RRP. Carcinoid tumor. [In] Berk JE, Haubrich WS, Kalser MH, Roth JLA, Schaffner F, eds. *Bockus Gastroenterology*. 4th ed. Vol 3. Philadelphia, WB Saunders, 1985, pp 1874-1886.
26. Farmer RG, Hawk WA, Turnbull RB Jr. Clinical patterns in Crohn's disease: a statistical study of 615 cases. *Gastroenterology* 1975; 68:627-635.
27. Roger BWG, Clark LM, Kirsner JB. The epidemiologic and demographic characteristics of inflammatory bowel disease: an analysis of a computerized file of 1400 patients. *J Chron Dis* 1971; 24:743-773.
28. Sellink JL, Miller RE. Radiology of the Small Bowel, Modern Enteroclysis Technique & Atlas. Hingham, MA, Martinus Nijhoff, 1982, pp 81-116.