

# Intravenous digital subtraction angiography for preoperative evaluation of patients with extensive renal calculus disease

AUGUST ZABBO, MD; STEVAN B. STREEM, MD; ANDREW C. NOVICK, MD; BARBARA RISIUS, MD

■ This study was done to determine whether intravenous digital subtraction angiography could reliably image the main renal arterial supply in patients with extensive renal calculus disease and compromised renal function. Thirteen patients undergoing complex intrarenal surgery for calculus disease, who otherwise would have been evaluated preoperatively with standard catheter arteriography, instead underwent intravenous digital subtraction angiography. The images obtained were found to have been accurately interpreted in all cases, as determined definitively at the time of renal exploration. The authors conclude that intravenous digital subtraction angiography is a reliable alternative arterial imaging procedure in patients with complex renal calculus disease and compromised renal function.

□ INDEX TERMS: ANGIOGRAPHY; KIDNEY CALCULI; SUBTRACTION TECHNIC □ CLEVE CLIN J MED 1988; 55:263-266

**T**HE MANAGEMENT of patients requiring surgery for renal calculus disease has changed dramatically. In fact, most of these patients are now managed nonoperatively with either shockwave lithotripsy, percutaneous lithotomy, or a combination of these modalities. However, there remains a select group of patients, such as those with extensive staghorn calculus disease, who may still be managed surgically.

In those cases, temporary occlusion of the renal artery is generally used to facilitate the required intrarenal surgery. As such, renal arteriography has been a standard part of the preoperative evaluation. Formerly, standard catheter arteriography (SCA) was the only reliable means available to obtain such images. Recently, however, intravenous digital subtraction angiography (IV-

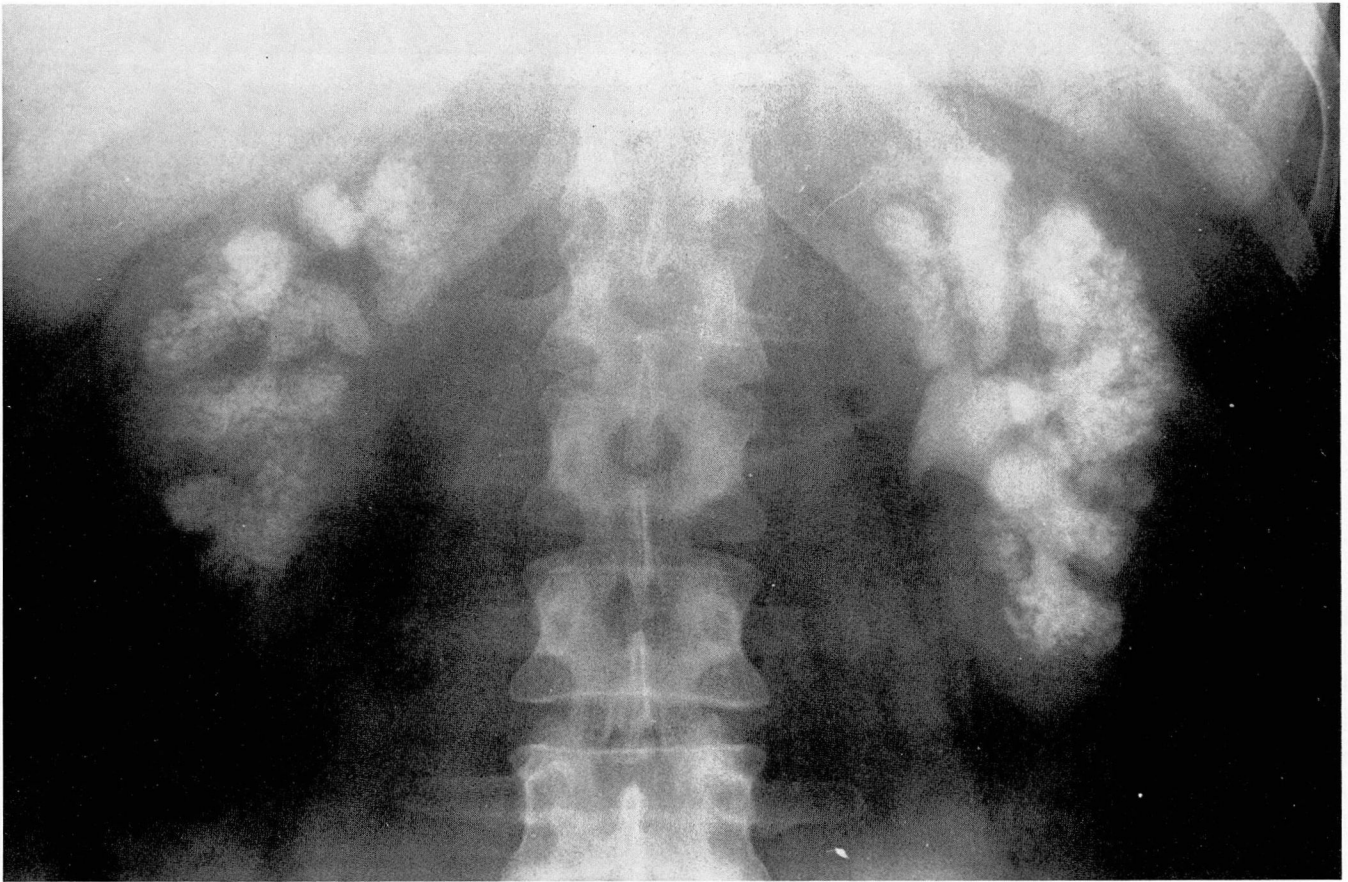
DSA), which is less invasive, safer, and less expensive, has been suggested to replace SCA in some settings requiring imaging of the main renal artery.<sup>1-6</sup>

Herein we report our initial experience using IV-DSA in the preoperative evaluation of 13 patients undergoing complex intrarenal surgery for stone disease. The results suggest that the main renal arterial supply may be accurately imaged with IV-DSA in these patients, even when extensive calculus disease and compromised renal function are present.

## MATERIALS AND METHODS

The technique of IV-DSA of the renal arteries used at our institution has been described in detail elsewhere.<sup>7</sup> Briefly, IV-DSA is a computerized radiologic technique that uses abdominal x-ray images obtained before and after the intravenous injection of a bolus of contrast material. An image obtained prior to the arrival of

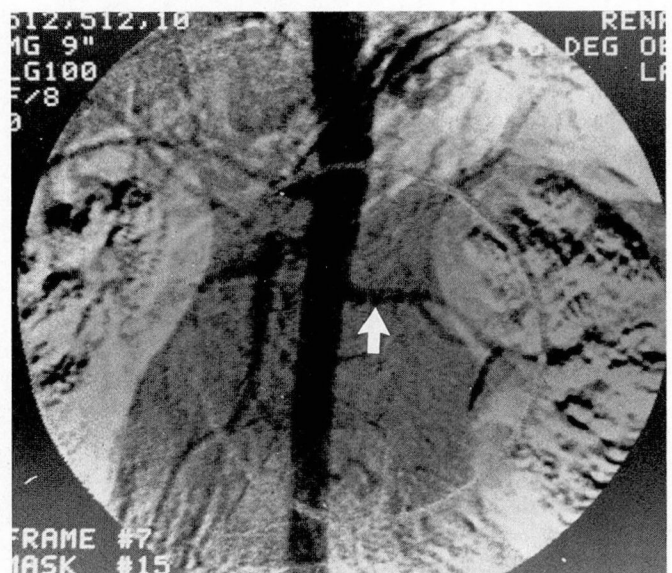
Departments of Urology and Radiology, The Cleveland Clinic Foundation, Cleveland, Ohio. Submitted for publication Sep 1987; accepted Sep 1987.



A

contrast agent (mask frame) is collected in digital mode and stored in the computer. Subsequent image frames are obtained after injection of contrast material. The mask image is digitally subtracted from the contrast-enhanced images and the resultant images are displayed on a television screen. The subtracted images, which are comparable to a standard abdominal aortogram, are then recorded on radiographic film. Oblique views may be obtained on repeat injections.

Thirteen outpatients being evaluated for complex intrarenal stone surgery were studied with IV-DSA of the renal arteries. There were 10 women and three men, ranging in age from 27 to 62 years. The serum creatinine levels ranged from 0.9 to 3.1 mg/dL (mean 1.6 mg/dL) at the time of the IV-DSA. The indications for surgery included a fully branched, mature staghorn calculus in 11 patients, one of whom was affected bilaterally, and calculi in large, upper-pole calyceal diverticula in the other two patients. Because the contrast agent used for IV-DSA is a standard radiographic agent, other studies requiring contrast material injection may be obtained following the DSA. In this study, 11 patients underwent post-IV-DSA urography and one patient post-IV-DSA



B

FIG. 1A. Scout radiograph in this patient with type 1 renal tubular acidosis reveals bilateral nephrocalcinosis and a left staghorn calculus. FIG. 1B. Selected projection from IV-DSA demonstrates single left renal artery (arrow). Serum creatinine level was 1.9 mg/dL at time of this study.

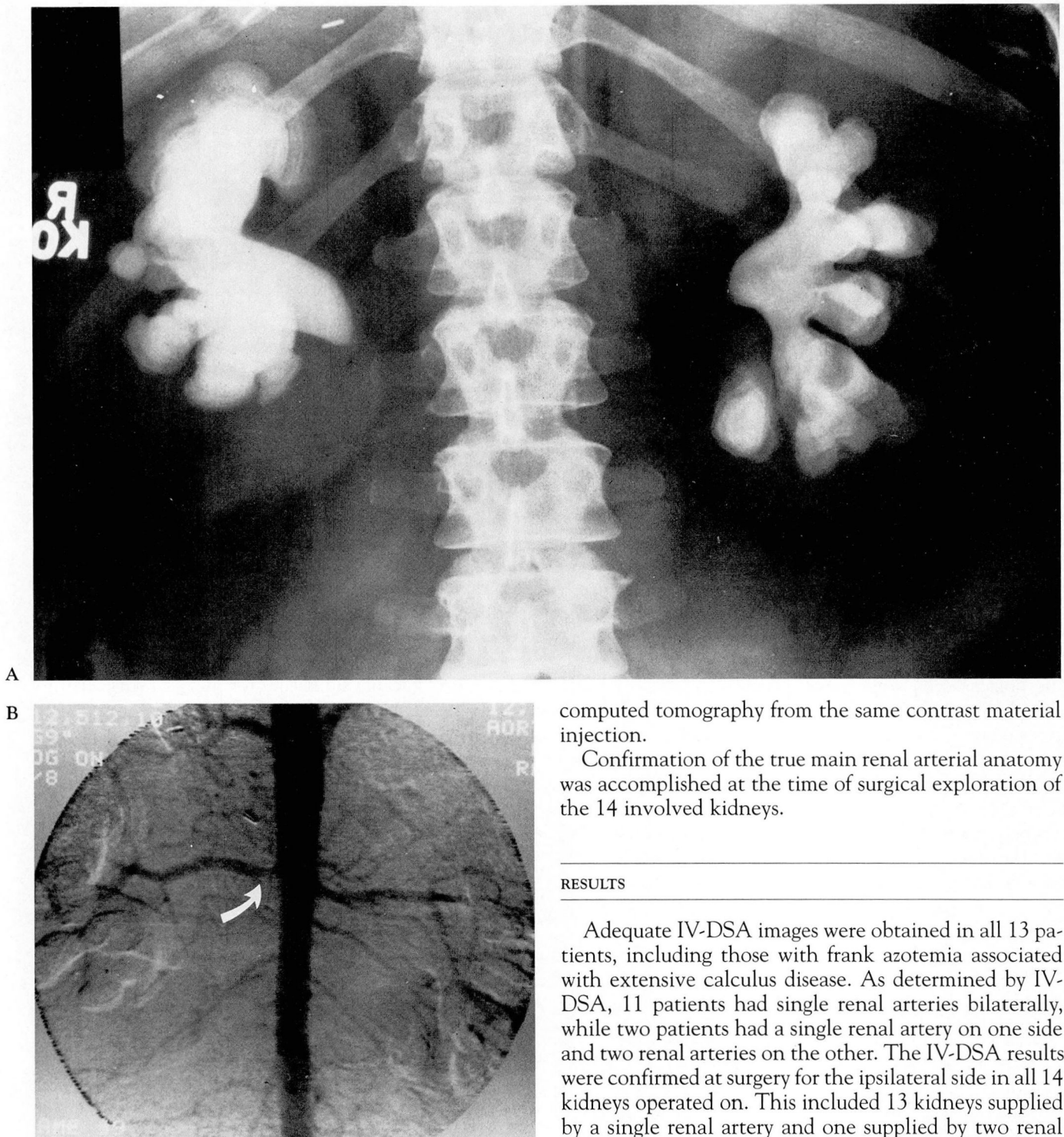


FIG. 2A. Scout radiograph demonstrates extensive bilateral staghorn calculus disease. FIG. 2B. IV-DSA demonstrates single renal arteries bilaterally (also noted is a 50% stenosis of the proximal right renal artery, arrow). Serum creatinine level was 3.1 mg/dL at time of this study.

computed tomography from the same contrast material injection.

Confirmation of the true main renal arterial anatomy was accomplished at the time of surgical exploration of the 14 involved kidneys.

#### RESULTS

Adequate IV-DSA images were obtained in all 13 patients, including those with frank azotemia associated with extensive calculus disease. As determined by IV-DSA, 11 patients had single renal arteries bilaterally, while two patients had a single renal artery on one side and two renal arteries on the other. The IV-DSA results were confirmed at surgery for the ipsilateral side in all 14 kidneys operated on. This included 13 kidneys supplied by a single renal artery and one supplied by two renal arteries.

The only complication in this series related to the IV-DSA study was a transient rise in the serum creatinine level seen in one patient, a diabetic woman who had a baseline serum creatinine level of 3.0 mg/dL, which rose

to 6.1 mg/dL following the IV-DSA. This level returned to baseline over the next three days.

Representative examples of the IV-DSA images obtained in these patients are illustrated here.

**Case 1.** A 29-year-old obese woman had type 1 renal tubular acidosis complicated by chronic *Proteus* urinary tract infection and a left staghorn calculus (Fig. 1A).

The serum creatinine level was 1.9 mg/dL. IV-DSA performed before a left anatomic nephrolithotomy demonstrated a single left renal artery (Fig. 1B). The vascular anatomy was confirmed at the time of surgery.

**Case 2.** A 41-year-old obese woman had chronic renal insufficiency (serum creatinine 3.1 mg/dL) resulting from extensive bilateral staghorn calculus disease and *Proteus* urinary tract infections (Fig. 2A). IV-DSA performed before staged bilateral anatomic nephrolithotomies revealed single renal arteries bilaterally (Fig. 2B). The angiographic findings were confirmed at the time of surgery.

#### DISCUSSION

Renal IV-DSA has been used in several large series for a variety of indications, including screening for renal vascular disease,<sup>1,2</sup> preoperative evaluation of potential renal donors and patients with renal tumors,<sup>3,4</sup> and postoperatively following renal transplantation or revascularization.<sup>5,6</sup> Although IV-DSA has not proven completely reliable for all the aforementioned indications, it has consistently been found to define adequately the number and position of the main renal arteries, which was the objective of this study. The main limitation of renal IV-DSA is that vessels 2 mm or less in diameter are

not reliably imaged. Thus, caution is required when using IV-DSA for some proposed indications, such as screening for renal vascular disease where a partially stenotic lesion of the renal artery might not be appreciated, or when evaluating potential renal donors where failure to recognize a polar vessel might lead to the need for "bench" repair or result in areas of ischemia with the potential for fistula formation.

The relative advantages of IV-DSA compared with SCA are its lower risk because it is less invasive and requires less contrast material, and its decreased expense because it can safely be performed on an outpatient basis. The complications of DSA are essentially those of the contrast material injection. Thus, the usual precautions such as hydration before exposure should be taken for those patients at risk for contrast-material-induced nephrotoxicity, such as those with diabetes mellitus or renal insufficiency.

#### CONCLUSIONS

This study demonstrates that IV-DSA can provide accurate imaging of the main renal arterial supply, even in patients with extensive calculus disease and compromised renal function. As well documented in previous reports, IV-DSA is safer, less expensive, and less invasive than standard catheter arteriography. We conclude that IV-DSA is a suitable substitute for SCA in this setting and we now consider it the preoperative imaging procedure of choice for these patients.

STEVAN B. STREEM, MD  
Department of Urology  
The Cleveland Clinic Foundation  
One Clinic Center  
9500 Euclid Avenue  
Cleveland, Ohio 44195

#### REFERENCES

- Osborne RW, Jr., Goldstone J, Hillman BJ, Ovitt TW, Malone JM, Nudelman S. Digital video subtraction angiography: screening technique for renovascular hypertension. *Surgery* 1981; 90:932-938.
- Zabbo A, Novick AC. Digital subtraction angiography for noninvasive imaging of the renal artery. *Urol Clin North Am* 1984; 11:409-416.
- Flechner SM, Sandler CM, Ben-Menachem Y, Van Buren CT, Kahan BD. Evaluation of living related kidney donors using digital subtraction angiography. *Cleve Clin Q* 1984; 51: 339-343.
- Prager P, Hoevens J, Georgi M. Digital subtraction angiography in the preoperative evaluation of patients with a renal tumor. *Acta Radiol Diag* 1984; 25(Fasc 2):101-105.
- Flechner SM, Novick AC, Meaney TF, Gallagher JH, Braun WE, Steinmuller D. Simultaneous structural and functional imaging of the transplant kidney using digital subtraction angiography. *J Urol* 1983; 129:248-251.
- Novick AC, Buonocore E, Meaney TF. Digital subtraction angiography for postoperative evaluation of renal arterial reconstruction. *J Urol* 1983; 129:14.
- Buonocore E, Meaney TF, Borkowski GP, Pavlicek W, Gallagher J. Digital subtraction angiography of the abdominal aorta and renal arteries. *Radiology* 1981; 139:281-286.