

# Captopril renography for the detection of renovascular hypertension

A preliminary report

JOSEPH V. NALLY, JR., MD; BHARAT K. GUPTA, MD; HARRY S. CLARKE, JR., MD, PHD; JAMES T. HIGGINS, JR., MD; WILLIAM J. POTVIN, PHD; MICHAEL L. GROSS, MD

■ The effect of a provocative challenge with an angiotensin-converting enzyme inhibitor (captopril) upon technetium-99m-labeled diethylene triaminepentaacetic acid (Tc-99m-labeled DTPA) and iodohippurate sodium I-131 (I-131 Hippuran) renograms was studied in a group of 16 selected hypertensive patients. The patients were categorized as having either renal artery stenosis (RAS,  $n=11$ ) or essential hypertension (EHT,  $n=5$ ) based upon renal angiographic findings. In patients with RAS, captopril altered the time-activity curves of the stenotic kidney(s) of both radionuclide studies and improved the diagnostic sensitivity. In patients with EHT, captopril did not alter the radionuclide studies. Converting-enzyme inhibition coupled with noninvasive radionuclide studies of the renovascular bed offers promise in improving the sensitivity and specificity for detecting hemodynamically significant RAS in the hypertensive population.

□ INDEX TERMS: CAPTOPRIL; HYPERTENSION, RENAL; RADIOISOTOPE RENOGRAPHY □ CLEVE CLIN J MED 1988; 55:311-318

**B**ECAUSE of recent advances in percutaneous transluminal renal angioplasty and surgical techniques, interest has been renewed in developing a better screening test to identify renovascular hypertension (RVHT). Conventional rapid-sequence intravenous pyelography (IVP) has been the major tool for screening hypertensive patients for renal artery stenosis, yet this test suffers from somewhat limited sensitivity and specificity as well as potential nephrotoxicity from the iodinated contrast material.<sup>1</sup>

Technological advances have resulted in the development of digital subtraction angiography (DSA) of the

renovascular bed, but a recent comprehensive review of IVP and DSA examinations in hypertensive patients suggests that DSA may be more invasive and cumbersome, less cost-efficient, and yet offer no advantages as a predictive index of RVHT when screening the hypertensive population.<sup>1</sup> Early radionuclide studies of the kidneys employing iodohippurate sodium I-131 (I-131 Hippuran) were unable to improve upon the sensitivity and specificity of the IVP examination. The development of improved radionuclides (such as technetium-99m-labeled diethylene triaminepentaacetic acid [Tc-99m-labeled DTPA]) and computerized technology has resulted in increased sensitivity and specificity for identifying renal artery stenosis in a selected hypertensive population.<sup>2,3</sup>

More recent reports have suggested that combining these computer-assisted radionuclide techniques with the pharmacological challenge of angiotensin convert-

Department of Hypertension and Nephrology, The Cleveland Clinic Foundation, Cleveland, Ohio (J.V.N.), and Department of Medicine and Radiology, Medical College of Ohio, Toledo, Ohio (B.K.G., H.S.C., J.T.H., W.J.P., M.L.G.). Submitted for publication July 1987; accepted September 1987.

ing enzyme (ACE) inhibition may offer improved sensitivity in detecting RVHT.<sup>4-8</sup> Provocative challenge with captopril, which pharmacologically blocks the renin-angiotensin system, was studied for two reasons. First, captopril stimulation of plasma renin activity has been reported to enhance the diagnostic accuracy of these procedures.<sup>9-10</sup> Second, ACE inhibiting agents have been reported to result in acute, reversible impairment of renal function in selected patients with RVHT.<sup>11,12</sup> We present our initial experience using this combined technique of captopril-stimulated renography with a series of 16 selected hypertensive patients, and an illustrative case report.

#### METHODS AND CASE REPORT

Sixteen hypertensive patients who had undergone renal angiography were evaluated using noninvasive radionuclide studies with and without ACE inhibition with captopril. A complete history was obtained, and patients underwent physical examination and routine laboratory studies, including urinalysis and measurement of serum BUN and creatinine. After informed consent was given, a Tc-99m-labeled DTPA study and conventional iodohippurate sodium I-131 renogram were obtained during baseline conditions and then repeated on another day following captopril administration (see Radionuclide studies, below). The patients were categorized as having renal artery stenosis (RAS, group 1,  $n=11$ ) or essential hypertension (EHT, group 2,  $n=5$ ) based upon the results of their renal angiography.

#### Baseline studies

Patients continued to take their usual antihypertensive medications through the morning of the study. If a patient's usual medication included an ACE inhibitor, the drug was withheld for four days prior to the study. Hydration was accomplished by having each patient drink 10 mL water/kg to insure adequate diuresis. Blood pressure was determined at the start of the studies. The patients underwent the Tc-99m-labeled-DTPA renal flow study followed by iodohippurate sodium I-131 renography (see below).

#### Captopril-stimulated studies

The patient's usual antihypertensive medications were withheld starting the prior evening and diuretics were withheld for at least 24 to 48 hours before the captopril-stimulated studies. Blood pressure was measured and 25 mg captopril was administered orally one

hour prior to the radionuclide studies. A similar water load was ingested and blood pressure was monitored. The Tc-99m-labeled-DTPA and iodohippurate sodium I-131 studies were repeated the same as the baseline studies.

#### Radionuclide studies

For the Tc-99m-labeled-DTPA studies, a 10-mCi (370-MBq) bolus of Tc-99m-labeled DTPA was injected rapidly through the antecubital vein with the patient lying supine above the horizontally oriented gamma camera. Anatomy was viewed posteriorly by a large-field gamma camera (General Electric Maxicamera II, Milwaukee, WI, USA). Data were acquired by a PDP 11/34 computer using a predefined study routine operating under Gamma 11 and RT 11 software (Digital Equipment Corporation, Maynard, MA, USA). Data were formulated into a 64 x 64-pixel matrix. The dynamics of the Tc-99m-labeled-DTPA study were specified at a rate of 1 second per frame for 90 seconds, followed by 10 seconds per frame for 28.5 minutes. For the conventional iodohippurate sodium I-131 studies, a 150- $\mu$ Ci (0.370-MBq) bolus was injected rapidly in a similar fashion using the same gamma camera and medium-energy collimator. A framing rate of 30 seconds per frame for 30 minutes was used. Time-activity curves were computer-generated for each kidney region of interest (with background subtraction), and were analyzed visually for configuration, slope, and symmetry and judged to be either normal or abnormal. The curves were deemed to be normal if the uptake and excretion were symmetrical over the left and right kidney. The curves were judged to be diagnostic of RAS if there was a decrease in maximum activity of the radionuclide, delayed uptake, widening of the peak activity, and slow excretory phase compared with the contralateral kidney.<sup>13</sup> The time-activity curves derived from the baseline and postcaptopril studies in each patient were compared. Special emphasis was given to noting the changes induced in the configuration, peak activity, and slopes of the time-activity curves following captopril administration.

Results are expressed as the mean  $\pm$  SEM. Statistical analysis was accomplished by use of the paired and unpaired Student's *t* tests.<sup>14</sup>

The following case report illustrates the effect of ACE inhibition upon the radionuclide studies in a patient with unilateral RAS.

#### Case report

A 65-year-old white man was evaluated for poorly controlled hypertension and hypokalemia despite therapy with prazosin and a potassium-sparing diuretic.

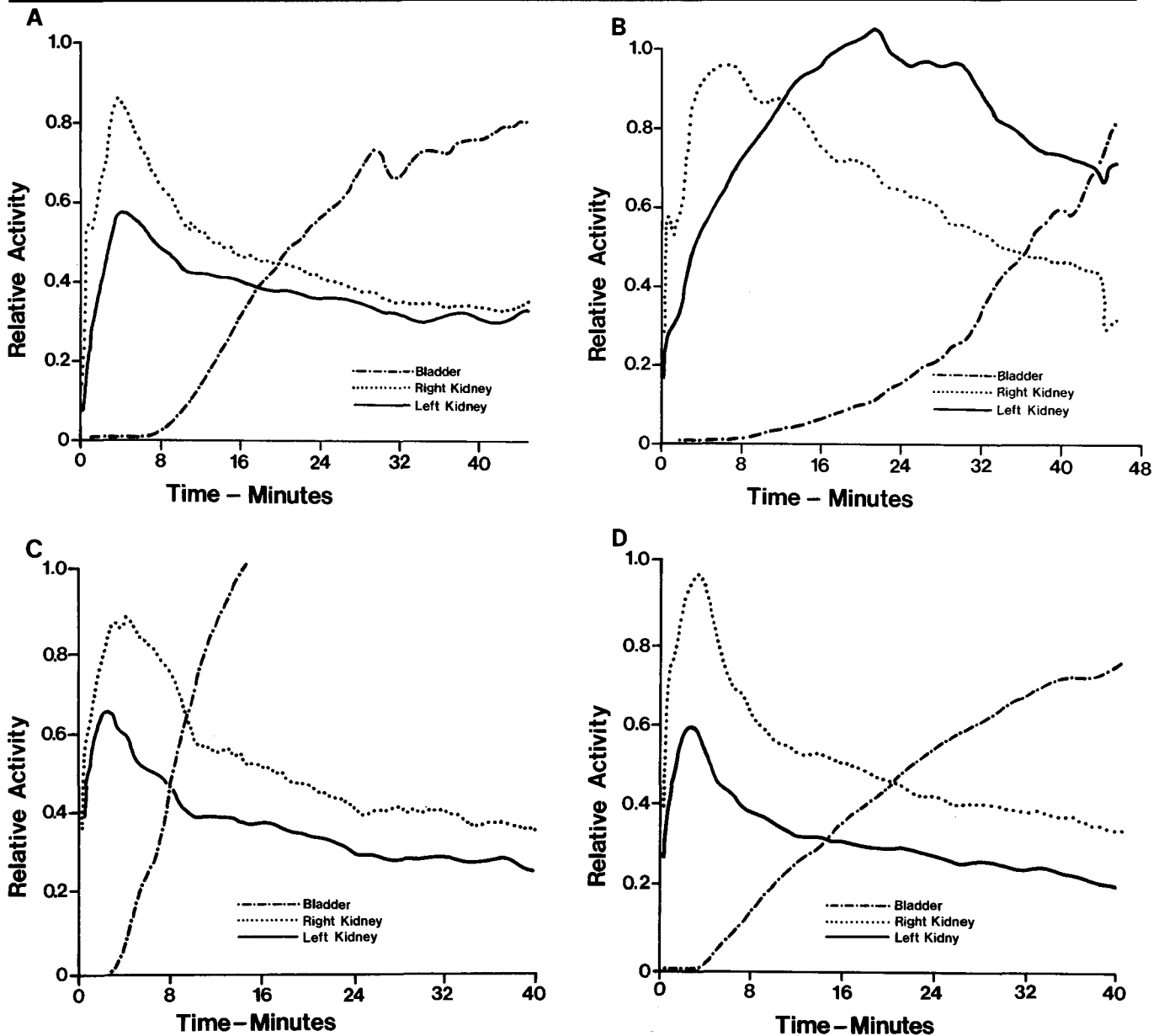


FIGURE 1. Unilateral renal artery stenosis. Top panel: Tc-99m DTPA time-activity curves during baseline (A) and following captopril stimulation (B) prior to surgery. Bottom panel: Tc-99m DTPA time-activity curves without captopril (C) and during captopril (D) two weeks following left renal angioplasty. See text for details.

Blood pressure was 200/100 mmHg and the serum creatinine level was 1.3 mg/100 mL. The baseline Tc-99m-labeled-DTPA study (Figure 1A) demonstrated physiological uptake and excretion of the radionuclide although the peak activity of the left kidney was approximately two-thirds that of the right. Captopril admini-

stration resulted in marked changes in the Tc-99m-labeled-DTPA study (Figure 1B); prolonged uptake, accumulation, and delayed excretion on the left were consistent with a diagnosis of left RAS. Subsequent angiography demonstrated a 70% stenosis on the left with two normal right renal arteries. The patient underwent

**TABLE 1**  
CLINICAL CHARACTERISTICS OF HYPERTENSIVE PATIENTS

Patient Number	Age/Sex	Mean Arterial Pressure (mmHg)		Serum Creatinine (mg/100 mL)
		Baseline	Captopril	
Group 1 (renal artery stenosis)				
1	63F	106	95	1.0
2	60M	98	106	2.7
3	37M	103	88	2.4
4	49M	107	103	1.0
5	69M	103	100	2.2
6	77M	111	111	3.0
7	62F	103	103	0.9
8	72M	102	118	2.0
9	65M	117	117	1.3
10	47F	105	105	2.0
11	19M	102	95	1.0
Mean ±SEM	56.3 ±5	105 ±2	104 ±3	1.79 ±.22
Group 2 (essential hypertension)				
12	26M	107	91	1.4
13	25M	107	91	1.0
14	62F	107	107	2.3
15	34F	110	110	1.1
16	25F	107	106	1.0
Mean ±SEM	34.4 ±7*	107 ±1	101 ±4	1.36 ±.24†

\*  $p < .05$  vs group 1

†  $p = \text{NS}$  vs group 1

successful percutaneous transluminal renal angioplasty, which normalized blood pressure without medications. Postangioplasty Tc-99m-labeled-DTPA studies did not show evidence of alterations in the uptake and/or excretion of the left kidney following captopril stimulation (Figure 1C and D).

## RESULTS

Table 1 lists the clinical characteristics of the hypertensive patients studied. The RAS patients were generally older and had slightly elevated serum creatinine levels. For the baseline radionuclide studies, there were no differences in mean arterial pressure between the two groups while they were receiving their usual antihypertensive medications. The hypotensive response following captopril administration did not differ between the RAS and the EHT groups. In fact, the EHT group tended to have a slightly lower (but nonsignificant) mean arterial pressure than the RAS group during the time of the captopril-stimulated radionuclide

studies. This observation suggests that the changes seen in the captopril-stimulated radionuclide studies in the RAS patients appear to be secondary to intrarenal hemodynamic and/or functional events of the stenotic kidney rather than simply a function of the reduction of mean arterial pressure. Also, we are unable to separate the RAS and EHT groups based upon their individual hypotensive response to captopril. There were no episodes of severe hypotension, renal insufficiency, nor any other untoward side effects related to the captopril studies. (In an earlier pilot study, asymptomatic hypotension developed following 50 mg of captopril by mouth in a patient with severe left RAS.)

Table 2 depicts the findings on the renal angiograms as well as the interpretation

of the Tc-99m-labeled-DTPA (90 seconds and 30 minutes) and iodohippurate sodium I-131 studies before and during captopril treatment of the individual patients studied in groups 1 and 2. Of the RAS patients in group 1, seven had unilateral RAS, four had bilateral RAS, and one had coarctation of the aorta above the level of the renal arteries. All the patients in group 2 had normal renal angiograms.

For the baseline Tc-99m-labeled-DTPA studies in the RAS patients, seven of 11 studies demonstrated unequivocal findings consistent with the diagnosis of RAS; findings were considered equivocal in three and normal in one. Following captopril administration, all of the 30-minute Tc-99m-labeled-DTPA time-activity curves of patients with RAS changed to exhibit either delayed uptake/excretion (Figure 1) or tracer-disappearance curves. The changes were best evidenced in the 30-minute curves and were not well appreciated in the 90-second time-activity curves. All four 30-minute Tc-99m-labeled-DTPA studies considered to be equivocal or nondiagnostic during baseline conditions became diagnostic following the administration of captopril. In es-

sence, the longer phase of the Tc-99m-labeled-DTPA renogram was more helpful in assessing the kidney's functional response to captopril than the 90-second Tc-99m-labeled-DTPA renal flow (perfusion) index. Although helpful in detecting RAS, the changes in the 90-second studies could not be quantitatively correlated with the degree of anatomical RAS. Four of five EHT patients in group 2 had normal time-activity curves during the baseline studies, and one curve was equivocal. Following captopril, four of five curves remained normal and the remaining equivocal curve did not change. The absence of change in the Tc-99m-labeled-DTPA time-activity curves following captopril correlated with the absence of significant RAS upon angiography.

Three patients with RAS did not undergo the iodohippurate sodium I-131 studies pre- and postcaptopril, so there were eight pairs of radionuclide studies available for examination of the effect of ACE inhibition on the renogram using this radionuclide. Six of the eight iodohippurate sodium I-131 time-activity curves were considered to be diagnostic of RAS, one was equivocal, and the other study was considered to be normal. Following captopril, all eight of the studies converted to patterns considered diagnostic of RAS using the predefined criteria. All five patients with EHT (group 2) underwent iodohippurate sodium I-131 renography. In the baseline condition, four of five were considered normal and one equivocal. Following captopril stimulation, the four originally normal studies and the fifth study, deemed equivocal, did not change.

## DISCUSSION

ACE inhibition with captopril induced alterations in both the Tc-99m-labeled-DTPA studies and iodohippu-

**TABLE 2**  
INTERPRETATIONS OF RENAL SCANS AND ANGIOGRAPHY

Patient Number	TC-99m DTPA Renal Flow Studies		I-131 Hippuran Renogram		Angiography
	Before captopril	After captopril	Before captopril	After captopril	
Group 1 (renal artery stenosis)					
1	Eqv.	Abn.	N	Abn.	R-RAS (40%)
2	Abn.	Abn.	Abn.	Abn.	R-100%
3	Abn.	Abn.	Abn.	Abn.	L-RAS (60%)
4	Abn.	Abn.	—	—	L-RAS (99%)
5	Abn.	Abn.	Abn.	—	L-95%, R-60%
6	Eqv.	Abn.	Abn.	Abn.	L-100%, R-95%
7	Abn.	Abn.	Abn.	Abn.	L-50%, R-30%
8	Abn.	Abn.	Abn.	Abn.	L-RAS
9	N	Abn.	—	—	L-RAS
10	Abn.	Abn.	Abn.	Abn.	L-RAS (95%)
11	Eqv.	Abn.	Eqv.	Abn.	Coarct aorta
Group 2 (essential hypertension)					
12	N	N	N	N	N
13	M	N	N	N	N
14	Eqv.	Eqv.	Eqv.	Eqv.	N
15	N	N	N	N	N
16	N	N	N	N	N

Eqv. = equivocal; Abn. = abnormal; N = normal; RAS = renal artery stenosis

rate sodium I-131 renograms of patients with RAS such that the ability to detect RAS was enhanced following captopril administration. No changes in the radionuclide studies of patients with EHT and normal renal angiography were seen following captopril administration. These observations in selected patients suggest that this combined technique, radionuclide studies coupled with ACE inhibition, may offer increased sensitivity and specificity in a noninvasive method for detecting potentially curable RVHT.

The mechanism by which ACE inhibition alters the radionuclide studies in patients with RAS remains to be elucidated. Since ACE inhibiting agents lower systemic blood pressure and may alter intrarenal hemodynamics and function, two possibilities appear to exist. Lowering of systemic pressure per se seems unlikely as the mechanism since both the EHT and RAS patients had similar reductions in blood pressure, yet the radionuclide studies exhibited significant alterations in the RAS patients but not in the EHT patients. Overall, our experience with both patients and experimental animals<sup>15</sup> suggests that



the hypotensive response alone is not responsible for the changes seen in the radionuclide studies with captopril.

Recent evidence suggests that the reduced Tc-99m-labeled-DTPA renal uptake within the stenotic kidney(s) results from changes in renal function and/or hemodynamics induced by ACE inhibition.<sup>15-17</sup> Tc-99m-labeled-DTPA is excreted by the kidney solely via glomerular filtration. In our canine model of two-kidney, one-clip Goldblatt hypertension, the changes with ACE inhibition were best appreciated in the studies using Tc-99m-labeled-DTPA, and were correlated with a 31% reduction of GFR in the stenotic kidney.<sup>15</sup> Blythe<sup>18</sup> has postulated that the existing data support the theory that intrarenal resistance and GFR are maintained by mediation of angiotensin II-dependent, efferent arteriolar constriction when perfusion pressure is diminished, as seen with RAS. However, the renographic changes have not been quite so clear-cut with iodohippurate sodium I-131, which is a marker of effective renal plasma flow (ERPF). In patients with RAS, captopril does not reduce the early uptake of iodohippurate sodium I-131 by the stenotic kidney but may result in prolonged cortical retention; this may be more a function of diminished urine flow within the cortical nephrons in response to ACE inhibition than a reduction in ipsilateral ERPF.<sup>8</sup> With ACE inhibition, the functional impairment of the affected kidney(s) is reflected by a decrease of the Tc-99m-labeled-DTPA uptake and a delay of the iodohippurate sodium I-131 excretion, whereas the iodohippurate sodium I-131 uptake and the 90-second Tc-99m-labeled-DTPA renal flow study seem to be less affected.<sup>6</sup>

Recent experience evaluating patients with RVHT using a combined technique of noninvasive radionuclide studies of the kidney plus ACE inhibition continues to be promising. Majd et al<sup>4</sup> originally reported that captopril enhanced the scintigraphic detection of RAS using Tc-99m-labeled-DTPA renal scans in hypertensive children. Bender et al<sup>19</sup> had shown that ACE inhibition with enalapril transiently reduced GFR and effective renal plasma flow as measured by nonimaging radionuclide techniques, but offered little comment upon the diagnostic utility of the combined technique. Subsequently, several groups of investigators have issued preliminary reports that ACE inhibition with either captopril or enalapril is capable of altering renal perfusion and function, as assessed by radionuclide studies, potentially enhancing the diagnostic accuracy of these studies in evaluating patients for RAS.<sup>4-8,20-23</sup> The tracer of choice to detect the reductions in GFR observed during ACE inhibition appears to be Tc-99m-labeled DTPA in patients with preserved renal function. In patients with impaired renal

function, iodohippurate sodium I-131 may offer a distinct advantage over Tc-99m-labeled DTPA.<sup>6-8</sup>

The crucial issue in evaluating captopril renography is to be able to correlate the changes in the radionuclide studies with evidence that the hypertension and renal function in patients with RVHT are dependent upon an enhanced renin-angiotensin system. By strict definition, the term "renovascular hypertension" implies that both the anatomic lesion of RAS and the functional A-II dependency of the elevated arterial pressure be demonstrated. To date, three of our seven patients with unilateral RAS and abnormal captopril-stimulated renography have undergone angioplasty or surgery and all three have demonstrated improved blood pressure control, suggesting that the changes with captopril indicated hemodynamically significant stenosis. More specifically, however, the changes in the Tc-99m-labeled-DTPA renograms with captopril appear to correlate with the removal of A-II-dependent, postglomerular arteriolar resistance that attempts to preserve glomerular filtration when renal perfusion is compromised. Experimental evidence has demonstrated that the changes in the renograms following ACE inhibition appear to correlate with a decrease in renal function (GFR) of the stenotic kidney.

More recent evidence suggests that these "functional" changes with ACE inhibition also indicate hemodynamically significant changes in the renovascular bed in patients with unilateral RAS. Geyskes et al<sup>24</sup> evaluated the diagnostic and predictive value of captopril-stimulated Tc-99m-labeled-DTPA renography in 34 patients with unilateral RAS (uRAS) and EHT. Twelve of the 15 uRAS patients who had a depressed ipsilateral uptake of Tc-99m-labeled-DTPA after captopril had improved blood pressure after angioplasty. In contrast, none of the six uRAS patients with no changes in the ipsilateral Tc-99m-labeled-DTPA uptake after captopril had an improvement in blood pressure control after a technically successful angioplasty. None of the 13 EHT patients with normal renal angiography had a decrease in Tc-99m-labeled-DTPA uptake after captopril. Hence, a positive captopril test appeared to be predictive of an improvement in blood pressure control following angioplasty. Perhaps as important, a negative captopril study was predictive of little improvement in blood pressure control after intervention in patients with angiographically proved unilateral RAS. These observations may clearly affect clinical decision-making, as determining the A-II dependency of the hypertension appears to be more important than simply documenting an anatomic lesion.

Further studies are clearly needed to evaluate this non-

invasive combined technique for detecting RAS and following individual kidney perfusion and function. From early reports, captopril stimulation appears to enhance the sensitivity of the radionuclide studies in patients with unilateral RAS and preserved renal function. Larger studies are needed to verify whether captopril-enhanced renography will improve our ability to predict the success of revascularization or angioplasty of a kidney better than existing studies such as renal vein renin determinations. It is not known whether this approach will be equally helpful in patients with bilateral RAS or RAS of a solitary kidney.<sup>25</sup> In hypertensive renal transplant patients, Dubovsky et al<sup>21</sup> have reported that three days of captopril administration prior to iodohippurate sodium I-131 renography reduces ERPF of the transplant kidney and distinguishes RAS from other potential causes of post-transplant hypertension. More studies are also needed to determine whether captopril-enhanced renography can achieve greater specificity along with fewer false-positive results in hypertensive patients.

Caution must be exercised in applying these preliminary observations in our selected series of hypertensive patients to the general hypertensive population.<sup>26</sup> The

combination of ACE inhibition and radionuclide studies may be able to reduce the need for invasive angiography, with its attendant risks of allergic reactions and potential nephrotoxicity, and afford a most cost-effective method of both screening a selected group of hypertensive patients and serially assessing individual kidney function in patients with RVHT.

#### ACKNOWLEDGMENTS

We thank Howard Uderman, MD, of the University of Massachusetts for data on Case Report 1, and Donald G. Vidt, MD, for his review of this manuscript. This work was supported by NIH Grant AM/HL 35467 and a Biomedical Research Support Grant from the Medical College of Ohio. The authors thank Ray Borazanian for his secretarial assistance.

JOSEPH V. NALLY, JR, MD  
Department of Hypertension and Nephrology  
The Cleveland Clinic Foundation  
One Clinic Center  
9500 Euclid Avenue  
Cleveland, Ohio 44195

#### REFERENCES

- Havey RJ, Krumlovsky F, delGreco F, Gartner Martin H. Screening for renovascular hypertension. *JAMA* 1985; 254:388-393.
- Chiarini C, Esposti ED, Losinno F, et al. Renal scintigraphy versus renal vein renin activity for identifying and treating renovascular hypertension. *Nephron* 1982; 32:8-13.
- Gross ML, Nally JV, Windham JP, Clarke HS, Riccobono XJ, Potvin WJ. Improved computer-assisted nuclear imaging in renovascular hypertension. *J Clin Hyperten* 1985; 4:326-335.
- Majd M, Potter BM, Guzzetta PC, Ruley EJ. Effect of captopril on efficacy of renal scintigraphy in detection of renal artery stenosis. *J Nucl Med (Abs)* 1983; 24:P23.
- Geyskes GG, Oei KY, Puylaert BAJ, Dorhout Mees EJ. Renography with captopril, changes in a patient with hypertension and unilateral renal artery stenosis. *Arch Intern Med* 1986; 146:1705-1708.
- Oei KY, Geyskes GG, Dorhout Mees EJ, Puylaert BAJ. The significance of captopril renography in renovascular hypertension. [In] Bischof-Delaloye A, Blaufox MD, eds. *Contributions to Nephrology: Radionuclides in Nephrology*. Vol 56. Basel, Karger, 1987, pp 95-103.
- Nally JV, Gupta B, Clarke HS, Gross ML, Potvin WJ, Higgins JT. Captopril-enhanced renal flow studies in detecting renovascular hypertension. *Kidney Int (abs)* 1986; 29:254.
- Sfakianakis G, Bourgoignie J, Jaffe D, et al. Single visit captopril renography for the diagnosis of renovascular hypertension. *J Nucl Med* 1987; 28:1383-1392.
- Re R, Novelline R, Escourron M, Athanasoulis C, Burton J, Haber E. Inhibition of angiotensin-converting enzyme for diagnosis of renal-artery stenosis. *N Engl J Med* 1978; 298:582-586.
- Muller FB, Sealey JE, Case DB, et al. The captopril test for identifying renovascular disease in hypertensive patients. *Am J Med* 1986; 80:633-644.
- Hricik DE, Browning PJ, Kopelman R, Goorno WE, Madias NE, Dzau VJ. Captopril-induced functional renal insufficiency in patients with bilateral renal-artery stenosis or renal-artery stenosis in a solitary kidney. *N Engl J Med* 1983; 308:373-376.
- Curtis JJ, Luke RG, Whelchel JD, Diethelm AG, Jones P, Dustan HP. Inhibition of angiotensin-converting enzyme in renal-transplant recipients with hypertension. *N Engl J Med* 1983; 308:377-381.
- Nally JV, Clarke HS, Windham JP, Grecos GP, Gross ML, Potvin WJ. Technetium-99m DTPA renal flow studies in Goldblatt hypertension. *J Nucl Med* 1985; 26:917-924.
- Sokal R, Rohlf F. *Biometry*. San Francisco, Freeman and Co., 1969, pp 220-223.
- Nally JV, Clarke HS, Grecos GP, et al. Effect of captopril on 99mTc-diethylenetriaminepentaacetic acid renograms in two-kidney, one clip hypertension. *Hypertension* 1986; 8:685-693.
- Lee HB, Blaufox MD. Differential effect of captopril on GFR in rats with renovascular hypertension. *J Nucl Med (abs)* 1985; 26:72.
- Thomas FD, Kopecky RT, McAfee JG, Hellwig B, Tillapaugh-Fay G. Evaluation of captopril challenge in a rat model of renovascular hypertension. *J Nucl Med (abs)* 1986; 27:962.
- Blythe WB. Captopril and renal autoregulation. *N Engl J Med* 1983; 308:390-391.
- Bender W, La France N, Walker WG. Mechanism of deterioration in renal function in patients with renovascular hypertension treated by enalapril. *Hypertension* 1984; 6(suppl 1):1-193-1-197.
- Wenting GJ, Tan-Tjong HL, Derkx FHM, de Bruyn JHB, Man in't Veld AJ, Schalekamp MADH. Split renal function after captopril in unilateral renal artery stenosis. *Br Med J* 1984; 288:886-890.
- Dubovsky EV, Curtis JJ, Luke RG, et al. Captopril as a predictor of curable hypertension in renal transplant recipients. [In] Bischof-Delaloye A, Blaufox MD, eds. *Contributions to Nephrology: Radionuclides in Nephrology*. Vol 56. Basel, Karger, 1986, pp 117-123.

22. Fommei E, Ghione S, Palla L, et al. Captopril suppresses glomerular filtration rate but not blood flow in the affected kidney in renovascular hypertension: report and comments on one case. *J Nucl Med Allied Sci* 1985; **29**:175-177.
23. Hovinga TK, Beukhof JR, van Luyk WH, Piers DA, Donker AJ. Reversible diminished renal <sup>99m</sup>Tc-DMSA uptake during converting-enzyme inhibition in a patient with renal artery stenosis. *Eur J Nucl Med* 1984; **9**:144-146.
24. Geyskes GG, Oei HY, Puylaert CBAJ, Mees, EJD. Renovascular hypertension identified by captopril-induced changes in the renogram. *Hypertension* 1987; **9**:451-458.
25. Nally JV, Clarke HS, Gupta BK, et al. Captopril renography in two-kidney and one-kidney Goldblatt hypertension. *J Nucl Med* 1987; **28**:1171-1179.
26. Nally JV. Renal scintigraphy in the evaluation of renovascular hypertension—A note of optimism yet caution (Editorial Review). *J Nucl Med* 1987; **28**:1501-1505.

