

# Results of transsphenoidal surgery for Cushing's disease

Cleveland Clinic experience

JANET W. BAY, MD AND LESLIE R. SHEELER, MD

■ Thirty-six patients with Cushing's disease underwent transsphenoidal surgery at the Cleveland Clinic between January 1976 and August 1986. Adenomas were identified, removed, and verified pathologically in 28 patients (78%); in all cases, hypercortisolism was corrected. Overall, 31 of the 36 patients (86%) were cured initially (biochemically and clinically). No operative mortality or permanent neurological sequelae were sustained. Follow-up ranged from four to 120 months. There have been three recurrences after an initial apparent cure.

□ INDEX TERM: CUSHING'S SYNDROME □ CLEVE CLIN J MED 1988; 55:357-364

**T**RANSPHENOIDAL microsurgery is the current treatment of choice for Cushing's disease. Since Cushing's report in 1932,<sup>1</sup> the pituitary origin of this serious endocrinopathy has often been questioned because radiographs of affected patients showed a normal sella turcica. Cushing postulated that the pathology originated in the pituitary gland and "the tumor need not necessarily be bulky but, quite to the contrary, striking clinical effects might be produced by minute, symptomatically predictable adenomas." This observation has proved to be true. Histologically verified adenomas of the pituitary gland have been found in 70%–90% of patients with Cushing's disease.<sup>2–8</sup> Most of these tumors (66%–82%) have been microadenomas measuring less than 10 mm.<sup>4–6</sup>

Technical advances in neurosurgery, such as the operating microscope, fluoroscopic imaging capability, and development of specific transsphenoidal instrumenta-

tion, made possible the general use of selective transsphenoidal adenomectomy for treatment of Cushing's disease. Cure rates have ranged from 74%–91% in large centers, with associated low morbidity and mortality.<sup>2–8</sup> Recurrence rates have been low, although follow-up data are not extensive. However, a point of caution has been raised that surgical results may be institution-specific and not as predictable or favorable when clinical experience is limited.<sup>9</sup> Cure rates as low as 10% with recurrence rates of 100% have been reported.<sup>9</sup> This discrepancy highlights the importance of surgical experience for the identification and removal of these minute tumors.

## MATERIALS AND METHODS

Between January 1976 and August 1986, 36 patients (31 female, five male) with the clinical and endocrine diagnosis of Cushing's disease underwent transsphenoidal pituitary microsurgery at the Cleveland Clinic. Ages ranged from 17 to 65 years (mean, 41 years). The most commonly noted clinical features in this group are summarized in *Table 1*.

Departments of Neurological Surgery (J.W.B.) and Endocrinology (L.R.S.), The Cleveland Clinic Foundation. Submitted for publication Aug 1987; accepted Oct 1987.

**TABLE 1**  
COMMON CLINICAL FEATURES OF 36 PATIENTS WITH  
CUSHING'S DISEASE

Round face
Proximal weakness
Truncal weight gain
Hirsutism
Menstrual disturbance
Plethora
Thin skin
Mental disturbance
Acne
Striae
Edema
Bone pain

During this same time, L.R.S. evaluated a total of 60 patients with Cushing's syndrome. Eight of these patients had benign adrenal adenomas, four had adrenal carcinomas, two had macronodular adrenal hyperplasia, one had micronodular adrenal hyperplasia, and five had obvious ectopic ACTH syndrome. The remaining seven underwent either bilateral adrenalectomy or radiation therapy to the pituitary gland.

All patients suspected clinically to have Cushing's disease underwent laboratory testing to document hypercortisolism. Our detailed endocrine testing methods have been previously described.<sup>10</sup> Some patients required more than one round of testing to confirm the diagnosis, which was established by:

1. Elevated plasma cortisol levels (or loss of diurnal variation),
2. Elevated 24-hour urinary free cortisol levels,
3. Lack of suppression of plasma/urine steroid levels by the administration of low-dose dexamethasone (0.5 mg every six hours for 48 hours, administered orally),
4. Suppression (at least by 50%) of plasma/urine steroid levels by the administration of high-dose dexamethasone (2 mg every six hours for 48 hours, administered orally),\* or
5. Normal or slightly elevated levels of plasma ACTH.

Contrast-enhanced computed-tomographic (CT) scans of the head were obtained in all cases; most included high-resolution sections through the sella turcica. Eighteen of 39 scans (46%) showed focal abnormalities such as hypodense lesions within the gland, tilting of the stalk, a sloping sellar floor, and upward bulge of the diaphragm. Unfortunately, many of these radiologic

abnormalities (25%) did not correspond with the tumor location at surgery. Radiographs of the sella turcica, including polytomograms in some early cases, were abnormal in seven of 22 instances (32%). Initially, 15 patients underwent adrenal imaging via either abdominal CT or collimated CT of the adrenal glands. In eight patients, the adrenal glands appeared normal. Symmetrical enlargement, often slight, could be visualized in three instances. In the remaining four cases, one adrenal gland was considerably larger.

All patients then underwent standard microsurgery. In most, a transnasal-transeptal approach to the sphenoid sinus was used, which obviates the need for a sublabial incision. Advantages of this approach include quicker access to the sella turcica, excellent nasal hemostasis, direct visualization of the sellar contents, and fewer nasal or dental complications postoperatively.<sup>11</sup>

If the tumor was not visible or palpable on the surface of the gland, the gland was sharply dissected into quadrants and carefully explored with a micro-curette.

## RESULTS

Adenomas were identified, removed in toto, and histologically verified in 28 of the 36 patients (78%). The tumors were universally described as softer than the normal gland and at times were partially necrotic and liquified. The adenomas differed in color from normal gland, most often appearing paler, but a few lesions were purplish or yellow. Only one tumor was a macroadenoma, and the remainder of the tumors (27) were 5 mm or less. Tumors that were submitted to immunohistochemical staining were uniformly ACTH-positive.

In the eight cases in which an adenoma was not pathologically verified, the surgeon either removed what was thought to be an adenoma or performed a total or subtotal hypophysectomy. Only three of these patients (37%) were cured, as opposed to 28 cures for the 28 patients (100%) with verified adenomas. Overall, 31 of the 36 patients (86%) who underwent transsphenoidal surgery for Cushing's disease were cured (biochemically and clinically) (Figure 1). Clinical cure was defined as reversal or marked reduction in the symptoms and signs of hypercortisolism. This included weight loss, redistribution of body fat, resolution or marked lessening of proximal muscle weakness, fading of dermatologic manifestations, and either correction or lessening of hypertension and glucose tolerance. Clinical cures were confirmed by laboratory evidence of correction of the hypercortisolism (Tables 2–5). All cured patients required

\*For six patients with  $\leq 50\%$  suppression, metyrapone stimulation (750 mg every four hours) indicated that the Cushing's syndrome had a pituitary origin.

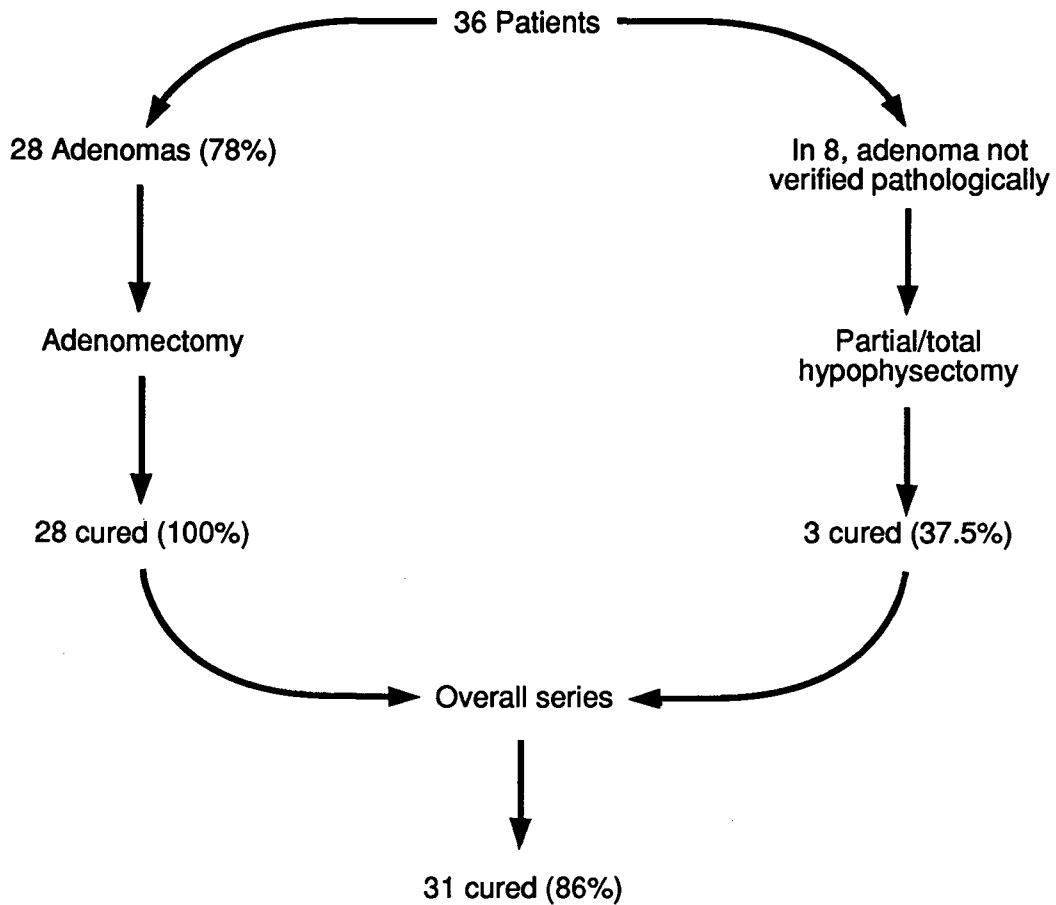


FIGURE 1. Surgical results.

cortisone-replacement therapy postoperatively. Glucocorticoid therapy was discontinued after four to 12 months except for patients with permanent hypopituitarism. Permanent loss of pituitary function was not seen in any patient undergoing selective adenectomy.

Of the five patients not cured after the initial operation, two subsequently underwent total hypophysectomy and three underwent adrenalectomy. One patient required both a hypophysectomy and adrenalectomy.

There was no operative mortality in this group. The average hospital stay was nine days. Cerebrospinal fluid (CSF) rhinorrhea developed in six patients (16.7%); all required reoperation for repair of the leak. Meningitis then developed in two of these patients and aspiration pneumonia developed in another. Diabetes insipidus developed in 16 of the 36 (44%), but it later cleared in all

but one. Another patient suffered a perforated nasal septum. One patient survived an exceedingly stormy postoperative course due to massive epistaxis from rupture of a previously undiagnosed berry aneurysm of the internal carotid artery. Retrospective review of the patient's preoperative intravenous digital subtraction angiogram demonstrated bilateral mirror aneurysms of the internal carotid arteries. Both aneurysms were successfully obliterated, one by direct clipping and the other by carotid ligation.

Follow-up has ranged from four to 120 months (mean, 45 months). There have been three recurrences after an initial biochemical and clinical cure. All three patients had histologically verified microadenomas and were treated by selective adenectomy. All recurrences developed 20 months or more after the initial surgery (Table 3).

**TABLE 2**  
PATIENTS WITH PITUITARY ADENOMAS VERIFIED BY PATHOLOGIST AND CURED AT LAST FOLLOW-UP

Patient number	Type of surgery	Date of surgery	Tumor-stain ACTH	Preoperative 17-oh FC (mg/24h)	Date	Postoperative 17-oh FC (mg/24h)	Date	Plasma cortisol	Date	ACTH stimulation test	Comments	
1	SA	8/7/79	ND	12.7	224	5/80	3.9	8/84	7.0		In 1/83, normal growth hormone and cortisol rise with insulin hypoglycemia	
2	TH	8/30/78	ND	8.0	247	10/81 8/84	<2	10/86	<2.5		Hypopituitarism. On T4 and cortisone. Cured by 10/86	
3	TH	3/1/79	ND	11.6	116			10/86	<2.5		Hypopituitarism. On T4 and cortisone. Cured by 10/86	
4	SA	5/10/79	ND	44	1445	8/86	50				Normal FC yearly since 1986	
5	SA	3/31/80	ND	23.8 18.2	616	8/83 10/85	55 60		8/80 10/80	<2.5—>3.3 <2.5—>7.8	Off cortisone by 8/80	
6	TH	12/3/79	ND	28.6	256	2/80	0.6	12.3	9/87	8.1	On permanent replacement with T4 and cortisone	
7	TH	7/8/80	ND	10.4	170	10/83	2.6	46.8	10/83	<2.5	On replacement for hypopituitarism in 10/86	
8	TH	3/29/76	ND	14.8	244	11/78	1.2		11/78	3.2	Hypopituitarism. On T4 and cortisone	
9	SA	12/10/79	ND	16.2	135	7/80 8/83	<10.6 2.3	2/82 5/83	5.5 5.5		Off cortisone by 6/82	
10	SA	8/27/81	+	34.8	1600 1033	4/82 4/83	60 59	4/83	10.0		Normal exam in 4/84. Off cortisone by 4/82	
11	SA	7/10/81	+	16.5	275 209	3/82 7/83	65 72	7/83	7.2		Off cortisone by 12/81	
12	SA	1/27/82	ND	14.8	684 793	6/83 8/84	27 4.0	6/83	8.2		Baby boy born 4/84. Well, 11/84	
13	SA	2/5/82	+	6.9	207 234	5/86	114	5/85 6/82	21 <2.5		Off cortisone by 11/82	
14	SA	8/24/83	+		557	11/86	101	4/87	15.7 (8 A.M.) 6.4 (4 P.M.)		Cured by 4/87	
15	SA	9/9/83	+		153	5/84	7.5	11/83	<2.5	5/84 8/85	4.6—>14.8 21.4—>37.7	Off cortisone by 4/84
16	SA	2/29/84	+		410	3/85 7/86	56 71		4/84 8/84	<2.5—>8 3.8—>11.7	Off cortisone by 10/84	
17	SA	6/16/84	+	37.6	166	2/85	58	6/84 8/84	<2.5 <2.5	11/84 2/85	4.1—>11.2 5.7—>21.1	Off cortisone by 1/85
18	SA	2/2/84	+	30	416	3/85 3/86	51 2	3/85	5.3	9/84	<2.5—>11.8	Off cortisone by 9/84
19	SA	11/1/85	+		246 177			3/86 5/86	6.5 11.6	11/85	<2.5—>4.7	Off cortisone by 4/86
20	SA	5/2/86	+	9.8	276 320	6/87	16		6/86 7/86	<2.5—<2.5 <2.5—<2.5	Off cortisone by 6/87	
21	SA	5/16/86			344 293				8/86	2.5—>4.7	On cortisone 4/87	
22	SA	2/27/86	+	11.5	252				8/86 11/86	<2.5—>4.5 <2.5—>4.5	On cortisone 6/87	
23	SA	10/29/84	+		482	10/86	3.5				Off cortisone by 4/85	
24	SA	3/7/86	+		442				7/86	<2.5—>10.4	Patient with Bilateral berr aneurysms	
25	SA	5/16/86	also + strongly for prolactin	14.6	860	2/87 8/87	48.1 54.4		7/86 10/86	<2.5—>11.9 <2.5—>11.6	Off cortisone by 11/86	

SA = selective adenomectomy, TH = total hypophysectomy, and FC = free cortisol.

**TABLE 3**  
PATIENTS WITH PATHOLOGIC VERIFICATION OF ADENOMA, BUT WITH RECURRENT OR PERSISTENT CUSHING'S DISEASE

Patient number	Type of surgery	Date of surgery	Tumor ACTH stain	Preoperative 17-oh (mg/24h)	FC	Date	Postoperative 17-oh (mg/24h)	FC	Comments
26	SA	8/18/78	ND	13.4	171	6/79	6.1	54	Off cortisol by 1/79. By 10/81, clinical features of Cushing's disease were returning. Bilateral adrenalectomy performed 6/12/81. Bilateral hyperplasia confirmed. Adrenal weight, 15.7 g. No pituitary tumor shown by magnetic resonance imaging on 9/87
						11/79	4.0	70	
						8/80	8.3		
						11/81	10.1	182	
						2/82	15.3	449	
27	SA	10/6/81	+ (Adenoma)	23.3	319	2/82	12.5	313	Off cortisol by 12/82. Lost to follow-up until 1/85. By then, clinical features of Cushing's disease were present. Bilateral adrenalectomy performed 3/29/85. Bilateral hyperplasia confirmed. Adrenal weight, 20.8 g
						4/82	4.9	49	
28	SA	2/3/77	ND	21.4 34.5	144 172	1/85		602	Metyrapone given from 6/81 to 5/82. Because of severe obesity, known coronary disease, and clinically apparent mild Cushing's disease, no definitive therapy was given. Underwent coronary bypass grafts of four vessels on 4/23/85
						7/79	8.4	58	
						7/80	10.7	189	
						6/81	15.6	165	
						9/82	14.7	275	
						4/83	30	263	
						7/85		139	
						1/87		81	

SA = selective adenomectomy and FC = free cortisol.

**TABLE 4**  
PATIENTS WITH NO PATHOLOGIC VERIFICATION OF PITUITARY ADENOMA, BUT IMPROVED OR CURED

Patient number	Type of surgery	Date of surgery	Preoperative 17-oh (mg/24h)	FC	Date	Plasma cortisol	Comments
29	TH	7/26/79	14.8	274	8/79	7.1	Surgeon identified probable adenoma. Pathologist could only identify a normal pituitary. Patient clinically cured by 4/84
			14.3	306	3/80	9.6	
					4/84	<2.5	
30	Near TH	3/13/86		246	3/18/86	<2.5	Unsuccessful bilateral adrenalectomy performed in Buffalo (left adrenal gland shattered). Hyperplasia confirmed by 3/85. Recurrence of signs and symptoms by 11/85. Pituitary hyperplasia; + stain for ACTH. Hypertension, plethora, round face, psychiatric symptoms, acne, and other symptoms had lessened or were no longer apparent by 5/87
				300	3/19/86	<2.5*	
31	TH	1/28/82	13.4	123	2/3/82	<2.5	Definite severe clinical Cushing's disease plus psychosis. Died less than one year later when a spontaneous bowel perforation developed while patient was staying in a chronic psychiatric facility. No pituitary tumor could be pathologically identified. Surgeon saw a small necrotic area that was lost in suction
			13.0		2/4/82	<2.5	

TH = total hypophysectomy and FC = free cortisol

\* Urine for cortisol levels were: 5/86, 187; 5/87, 191. The 17-oh measurement on 5/87 was 11.8 mg/g creatinine.

TABLE 5

PATIENTS WITH NO PATHOLOGIC VERIFICATION OF PITUITARY ADENOMA AND NOT CLINICALLY OR CHEMICALLY BENEFITTED BY PITUITARY SURGERY

Patient number	Type of surgery	Date of surgery	ACTH	Preoperative		Date	Postoperative		Comments
				17-oh	FC		17-oh	FC	
				(mg/24h)			(mg/24h)		
32	SA TH	3/12/80 11/12/80	89±17	18.3	83	4/80	18	166	First operation (pathology report) — possible pituitary adenoma. Second operation — probably pituitary hyperplasia. Bilateral adrenalectomy performed in 6/84 at another hospital. Petrosal sinus sampling in 84 showed gradient from pituitary
						8/80	8.7	137	
						9/80	12.1	99.3	
						1/80	9.9	170	
33	SA (TH attempted)	7/12/82	54±42	26	566	11/82 12/82	19.8 11.3*		Bilateral adrenalectomy performed in 1/83. Adrenal weight, 9.7 g. Patient cured after adrenal surgery. No menses before or after giving birth on 5/28/85. Ectopic source of ACTH or corticotropin-releasing factor not identified
34	TH	4/19/79	102±17	22.5	621	5/79	55.7	1,900	Bilateral adrenalectomy performed in 7/79. Despite multiple extensive investigations through 10/86, no ectopic source of ACTH or corticotropin-releasing factor was identified.
35	TH (attempted)	6/27/79	20	11.7	724	9/79	15.2		Bilateral adrenalectomy performed in 4/80. Adrenocortical hyperplasia confirmed. Adrenal weight, 16.2 g. Patient remains well with no evidence of ectopic ACT-secreting tumor
						11/79	18.8†	56	
						11/79	25.3		
36	SA	1/5/84	94		210	3/84		268	Bilateral adrenalectomy performed in 6/84. Adrenocortical hyperplasia confirmed. Adrenal weight, 10.8 g. Ectopic source of ACTH not identified
						3/84		367	

SA = selective adenomectomy, TH = total hypophysectomy, and FC = free cortisol.

\* Six plasma cortisol values, from 13 to 42, were recorded from 7/19/82 to 7/29/82.

† Plasma cortisol value = 23.3.

## DISCUSSION

Transsphenoidal resection of ACTH-secreting microadenomas comes close to being the ideal treatment for Cushing's disease. If a microadenoma can be identified and totally resected, the hypercortisolism can be corrected and normal pituitary function preserved most of the time. Specific data pertaining to postoperative pituitary function are not available, but Kageyama et al<sup>6</sup> noted that "functional recovery of pituitary hormones became much more prominent in most cases within several months of operation." Chandler et al<sup>8</sup> also commented that "patients with selective resections have not suffered loss of existing preoperative pituitary function."

The clinical features, preponderance of females, and

mean age (41 years) found in our series were similar to those in previous reports.<sup>3,4,8</sup>

Although high-resolution CT scans of the sella turcica frequently demonstrated indirect signs of tumor (46%), abnormalities such as tilted stalk or sloping floor were not often useful to the surgeon in localizing the tumor intraoperatively. The lack of success in imaging the tumors may reflect the fact that most adenomas found in this series measured less than 5 mm. Kageyama et al<sup>6</sup> found CT evidence of adenoma in only six of 19 adenomas (47%) measuring less than 5 mm.

Standard radiographic studies have not been highly accurate in the localization of these micro-tumors. Pituitary surgery was recommended based on the combination of endocrine and radiologic data, with the endocrine



TABLE 6  
SERIES COMPARISON

Reference	Patients (N)	Adenomas (%)	Cure Rate (%)	
			Overall	Recurrent
Bigos et al (1980) <sup>2</sup>	24	87	67	8
Salassa et al (1982) <sup>3</sup>	98	90	80	5
Boggan et al (1983) <sup>4</sup>	100	82	78	4
Lüdecke and Niedworok (1985) <sup>5</sup>	100	88	90	5
Kageyama et al (1985) <sup>6</sup>	100	93	91	7
Fahlbusch et al (1986) <sup>7</sup>	101	96	74	14
Chandler et al (1987) <sup>8</sup>	34	82	74	NA
Bay and Sheeler (1988)	36	78	86	9.7

data weighing more heavily in the final decision. The role of magnetic resonance imaging for demonstrating microadenomas remains to be defined.

All patients had hypercortisolism as shown by preoperative endocrine testing and all showed the pattern typical of pituitary origin (*Tables 2–5*). Endocrine results were equivocal initially in a few patients, necessitating a second round of testing.

Of the 36 patients in this series, adenomas were identified, removed, and pathologically verified in 29 (78%). Twenty-seven of these tumors were microadenomas. This is comparable to the 64% reported by Boggan et al,<sup>4</sup> the 74% reported by Chandler et al,<sup>8</sup> and the 71% reported by Salassa et al.<sup>3</sup> The data are not exactly comparable because each of these prior series combined pathologically proved adenomas with “presumed” adenomas (based on surgical findings).

Pathological verification of adenoma based on tiny bits of tissue is difficult, as demonstrated by Fahlbusch et al.<sup>7</sup> In their series, microadenomas were removed at surgery in 96 patients. Adenomas were pathologically verified in 75 (78.1%). In the remainder, findings included normal gland, diffuse hyperplasia, and in 12 cases, no tumor tissue was available.

The incidence of microadenoma identification in our series improved with experience and the designation of a single surgeon (J.W.B.). From 1976 to 1981, adenomas were identified by four surgeons in 14 of 20 cases (70%), and from 1982 to 1986, by a single surgeon in 14 of 16 cases (87.5%). These figures are significant since the cure rate is 100% in those patients in which an adenoma was successfully identified and removed (28 of 28). These results are comparable to other series that report cure rates between 94% and 96% for patients with a microadenoma.<sup>3,4,6</sup> Our single patient with a macroadenoma was surgically cured.

In the eight patients in which no adenoma was pathologically verified, the operative technique varied. Total hypophysectomy was not routinely performed. If the surgeon thought that an adenoma was removed, the gland was not removed. If the rapid-frozen section revealed focal hyperplasia, the involved half of the gland was resected. If no abnormalities were detected by surgical inspection or frozen-section pathologic review, a hypophysectomy was done. Only three of these eight patients were cured (37%) (*Tables 4 and 5*). The best way to manage patients in which a definite adenoma cannot be found during surgery is unclear. We generally favor a total hypophysectomy. This aggressive approach seemed warranted in this group of seriously ill patients.

The major morbidity in our series was due to postoperative CSF fistulas encountered in six patients (16.7%). This figure is higher than the one reported by Boggan et al<sup>4</sup> and Lüdecke and Niedworok<sup>5</sup>; both reported CSF leaks in only two of 100 patients. The incidence of CSF fistulas in our series was also higher than that noted in all other pituitary adenoma patients undergoing transsphenoidal surgery at the Cleveland Clinic during the same time period (three out of 96). Prior pituitary radiation and total hypophysectomy increase the risk of a CSF leak. No CSF fistulas were encountered in the last four years of the series.

The late recurrence rate in initially cured patients is unknown since the transsphenoidal procedure has been widely used in this patient population for less than 10 years. Our recurrence rate of 9.7% (three of 31 initially cured) is compared with data from other series in *Table 6*.

The five patients not cured and with no pathologic verification of tumor represent a special subgroup. Some of these patients may have occult ectopic production of ACTH or corticotropin releasing factor, although this has not been verified in any of the five despite a follow-

up of as long as eight years in two cases and despite multiple investigations. In such cases, therapy may be misdirected to the pituitary gland when the problem is elsewhere. Consequently, Findling and Tyrrell,<sup>12</sup> Oldfield et al,<sup>13</sup> and Howlett and Rees<sup>14</sup> suggest that a differentiation

can be made by inferior petrosal sinus sampling. Further investigation of this approach, however, is necessary.

JANET W. BAY, MD  
931 Chatham Lane  
Columbus, Ohio 43221

#### REFERENCES

1. Cushing H. The basophil adenomas of the pituitary body and their clinical manifestations (pituitary basophilism). *Johns Hopkins Med J* 1932; **50**:137-195.
2. Bigos ST, Somma M, Rasio E, et al. Cushing's disease: management by transsphenoidal pituitary microsurgery. *J Clin Endocrinol Metab* 1980; **50**:348-354.
3. Salassa RM, Laws ER Jr, Carpenter PC, Northcutt RC. Cushing's disease—50 years later. *Trans Am Clin Climatol Assoc* 1982; **94**:122-129.
4. Boggan JE, Tyrrell JB, Wilson CB. Transsphenoidal microsurgical management of Cushing's disease. *J Neurosurg* 1983; **59**:195-200.
5. Lüdecke DK, Niedworok G. Results of microsurgery in Cushing's disease and effect on hypertension. *Cardiology* 1985; **72**(suppl 1):91-94.
6. Kageyama N, Kuwayama A, Takahashi T, Negoro M, Ichihara K. Diagnosis, treatment and postoperative results of Cushing's disease. *Neurosurg Rev* 1985; **8**:177-183.
7. Fahlbusch R, Buchfelder M, Müller OA. Transsphenoidal surgery for Cushing's disease. *J R Soc Med* 1986; **79**:262-269.
8. Chandler WF, Scheingart DE, Lloyd RV, McKeever PE, Ibarra-Perez G. Surgical treatment of Cushing's disease. *J Neurosurg* 1987; **66**:204-212.
9. Burch W. A survey of results with transsphenoidal surgery in Cushing's disease (letter). *N Engl J Med* 1983; **308**:103-104.
10. Nolan FM, Sheeler LR, Hahn JF, Hardy RW. Therapeutic problems with transsphenoidal pituitary surgery for Cushing's disease. *Cleve Clin Q* 1982; **49**:199-207.
11. Tucker HM, Hahn JF. Transnasal, transeptal sphenoidal approach to hypophysectomy. *Laryngoscope* 1982; **92**:55-57.
12. Findling JW, Tyrrell JB. Occult ectopic secretion of corticotropin. *Arch Intern Med* 1986; **146**:929-933.
13. Oldfield EH, Chrousos GP, Schulte HM, et al. Preoperative lateralization of ACTH-secreting pituitary microadenomas by bilateral and simultaneous inferior petrosal venous sinus sampling. *N Engl J Med* 1985; **312**:100-104.
14. Howlett TA, Rees LH. Is it possible to diagnose pituitary-dependent Cushing's disease? *Ann Clin Biochem* 1985; **22**:550-558.