

Surgery for intractable epilepsy

Clinicopathologic correlates in 60 cases

MELINDA L. ESTES, MD; HAROLD H. MORRIS, III, MD; HANS LÜDERS, MD; ALDEN W. DUDLEY JR., MD; RONALD P. LESSER, MD; DUDLEY S. DINNER, MD; DIANE FRIEDMAN, RN, CS; JOSEPH F. HAHN, MD; ELAINE WYLLIE, MD

■ The pathologic findings in 60 consecutive patients with intractable epilepsy who consecutively underwent surgery at The Cleveland Clinic Foundation (1979–1984) were analyzed in an attempt to define pathologic findings influencing surgical outcome. Statistically significant predictors of outcome were sought from variables including macroscopic lesions, microscopic abnormalities, and the absence of significant pathologic findings. A higher percentage of patients (82%) with macroscopic temporal lobe lesions had an excellent result (seizure reduction >90%) than did the group with no significant pathologic findings (60%), but the differences were not statistically significant. The authors also found that the group of patients who had only temporal lobe resections had a higher percentage of excellent results (70%) than did the group of patients having epilepsy surgery for other areas of the brain (42.5%). This difference, however, was not statistically significant ($P = .10$).

□ INDEX TERM: EPILEPSY, NEUROSURGERY □ CLEVE CLIN J MED 1988; 55:441–447

IN 1886 Horsley¹ reported successful surgical treatment of partial epilepsy. Since that time, temporal lobectomy for epilepsy has been performed at many institutions.^{2–17} The outcome of surgery, in terms of seizure reduction, has been linked to several variables, including surface electroencephalography (EEG),^{17,18} electrocorticography,^{17,19} pathologic findings,^{2,20} and stereoencephalography.^{7,9,19}

The purpose of this study is to report clinical and pathologic data in a series of patients with intractable epilepsy treated at The Cleveland Clinic Foundation. The study group includes 60 patients who consecutively

underwent surgery for epilepsy from 1979 through 1984. This report focuses on the pathologic findings and relates them to outcome.

METHODS

The patient population includes 32 males and 28 females with a mean age of 23.1 years (range 3–41 years). Fifty-eight patients had complex partial seizures with or without secondary generalization, and two patients had simple partial seizures with or without secondary generalization.

All patients had medically refractory seizures for more than one year, despite treatment with appropriate anticonvulsants at therapeutic and/or subtoxic blood levels.

Patients with brain lesions demonstrated on CT scans were not excluded from this series unless the seizures

From the Departments of Pathology (M.L.E.), Neurology (H.H.M., H.L., R.P.L., D.S.D., D.F., E.W.), and Neurosurgery (J.F.H.), The Cleveland Clinic Foundation. Submitted for publication April 1987; accepted Aug 1987. Alden W. Dudley Jr., MD, is now with Baylor College of Medicine and Veterans' Administration Medical Center, Houston, TX 22030.

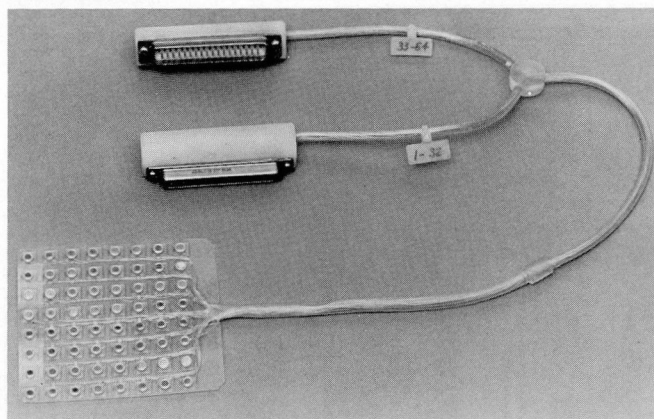


FIGURE 1. Electrode array (8 x 8 cm) with amphenol connectors. Each 3-mm similar steel electrode is 1 cm from its neighbors.

reason for surgery was removal of the structural abnormality.

Patients underwent prolonged EEG with simultaneous video recording for detailed analysis of clinical seizures. Standard 10/20 electrode positions plus closely spaced surface electrode clusters were used to help localize the epileptogenic focus on the scalp before intracranial electrodes were implanted.²¹ The surface distribution of ictal and interictal activity was used to determine optimal location of the intracranial electrodes. Nasopharyngeal and sphenoidal electrodes were frequently used. Ethmoidal electrodes were occasionally employed.

The intracranial electrodes consisted of 3-mm-diameter stainless-steel discs embedded in a 1.5-mm-thick Silastic "plate" (Figure 1). The center-to-center distance was 1 cm. Electrode arrays of 1 x 4, 4 x 4, 4 x 6, 4 x 11, and 8 x 8 cm were employed.^{15,17} Each electrode was connected by a 0.1-mm Teflon-insulated wire. The wires were collected into a Silastic-coated cable at the base of the electrode array. The large electrode arrays were placed subdurally directly on the pia-arachnoid of the brain through a large cranial opening. At times electrode array was sutured to the dura to prevent movement. The electrode cable exited the skull through a burr hole at the edge of the cranial opening and exited the scalp through a stab wound distant to the area. The cable was connected to the EEG equipment with amphenol connectors.

Cortical electrical stimulation of, as well as recording evoked potentials from, the cortex was carried out with the subdural electrodes using methods previously de-

scribed in detail.^{15,22-24} In this manner, cortical "maps" of functional areas (speech and the motor sensory strip) were made so that these areas could be avoided at the time of surgery. These studies were done over several days in the neurophysiology laboratory.

Recording from cortical electrodes was done both referentially (cortical electrode to Cz) and with bipolar montages (cortical electrode to cortical electrode). Up to five 19-channel Grass Model 8 electroencephalographic machines were used simultaneously to record the electrocorticogram. Synchrony was ensured with an electronic clock that delivered the time signal simultaneously to all machines²⁵ or by use of a common channel. Simultaneous video/EEG recording was done during stimulation and recording sessions.

Interictal sharp waves from the cortex as well as spontaneous seizures were analyzed to determine the location and extent of the epileptogenic area. Beginning in 1984, patient evaluation was assisted by a DEC PDP 11/44 computer with an automatic spike detection program.²⁶

Because temporal lobectomy was the most common procedure, we describe the technique in detail. Dominant-temporal-lobe resection of up to 8 cm and non-dominant-temporal-lobe resections as large as 10 cm were performed in selected patients. Before the electrodes were removed, the leptomeninges were coagulated along the borders of dissection while the speech area, as defined by the results of electrical stimulation, was avoided. Dissection was begun posteriorly with an oblique incision through the lateral temporal cortex. The incision was carried through the white matter to the temporal horn of the lateral ventricle. The ventricular plane was then followed anteriorly to the ventricular tip. The anterior mesial structures (amygdala) were then excised with the lateral temporal lobe. The ventricle was then used as a landmark, and the more posterior mesial structures, including the hippocampus, were removed, usually by suction. Approximately 2 mm of superior temporal gyrus was spared to preserve the middle cerebral vessels. After resection, electrocorticography was done in the operating room; if epileptogenic activity was seen and additional cortex could safely be removed without jeopardizing functional areas, the surgery was extended to include a subpial resection of the involved cortex.

The pathologic specimens consisted of frontal, parietal, temporal, or occipital lobes. The specimens were received from the operating room oriented on a diagram of the cerebral hemisphere. When available, mesial temporal structures were received separately

TABLE 1
 PATHOLOGIC FINDINGS (N = 47) AND SEIZURE REDUCTION (N = 46) AFTER TEMPORAL LOBECTOMY

Case	Side	Mesial structures removed	Mesial structures examined	Pathologic findings	% Seizure reduction	Follow-up (months)
1	R	—	—	Hamartoma	100 or AO	84
4	R	—	—	AVM,* SPG	>90	73
6	R	—	—	Subarachnoid	100 or AO	72
31	L	—	—	Low-grade	75–90	58
2	L	+	—	NSP		
11	R	+	—	3+ HT, SPG	75–90	18
19	L	+	—	SPG	<75	60
20	L	+	—	Vascular	100 or AO	58
26	L	+	—	NSP	75–90	60
44	R	+	—	SPG	>90	54
74	R	+	—	SPG	>90	37
78	R	+	—	SPG	>90	36
85	L	+	—	SPG	<75	12
87	R	+	—	3+ HT, SPG	—†	—†
97	R	+	—	SPG	<75	35
100	L	+	—	Low-grade	100 or AO	33
118	R	+	—	3+ HT, SPG	100 or AO	26
156	R	+	—	SPG	100 or AO	28
158	L	+	—	NSP	100 or AO	22
244	L	+	—	SPG	100 or AO	10
275	R	+	—	3+ HT, SPG	100 or AO	9
305	L	+	—	3+ HT, SPG	100 or AO	6
343	R	+	—	Pleomorphic Xanthoastrocytoma	100 or AO	11
				SPG*		
3	R	+	+	SPG	75–90	63
9	L	+	+	MTS, SPG	<75	62
15	L	+	+	3+ HT, SPG	>90	49
35	L	+	+	3+ HT, SPG	75–90	48
42	L	+	+	Hamartoma,* SPG	100 or AO	58
60	L	+	+	NSP	<75	42
70	L	+	+	NSP	100 or AO	44
75	L	+	+	SPG	<75	43
95	R	+	+	SPG	<75	51
108	R	+	+	SPG	100 or AO	28
111	L	+	+	SPG	>90	31
137	L	+	+	SPG	100 or AO	21
198	R	+	+	SPG	100 or AO	22
206	R	+	+	Low-grade Astrocytoma, SPG	100 or AO	16
				SPG		
210	L	+	+	SPG	100 or AO	14
221	R	+	+	3+ HT, SPG	100 or AO	13
226	L	+	+	SPG		
228	R	+	+	AVM,* SPG	100 or AO	22
232	L	+	+	Low-grade Astrocytoma,* SPG	<75	23
				MTS		
238	L	+	+	MTS	100 or AO	12
254	R	+	+	MTS, SPG	100 or AO	8
255	L	+	+	SPG	100 or AO	9
288	L	+	+	Hamartoma,* SPG	100 or AO	6
303	L	+	+	SPG	>90	9

R = right; L = left; AVM = arteriovenous malformation; SPG = subpial gliosis; NSP = no significant pathologic findings; 3+ HT = 3 + heterotopia; MTS = mesial temporal sclerosis; AO = auras only.

* Macroscopic pathologic features

† Lost to follow-up

TABLE 2
PATHOLOGIC FINDINGS (N = 13) AND SEIZURE REDUCTION (N = 12) IN EXTRATEMPORAL RESECTION

Case	Surgical site(s)	Pathologic findings	% Seizure reduction	Follow-up (months)
33	Frontal	SPG	<75	54
58	Frontal	Hamartoma, SPG	>90	48
80	Frontal	NSP	>90	36
160	Frontal	SPG	75-90	18
199	Frontal	SPG	>90	16
203	Frontal	SPG	100 or AO	16
347	Frontal	Hamartoma, SPG* (Neurofibromatosis)	75-90	6
68	Occipital	SPG	—†	—†
109	Occipital	SPG	<75	42
16	Parietal	NSP	>90	6
200	Frontal and Temporal	MTS, SPG	<75	12
237	Frontal and Temporal	SPG	<75	6
360	Frontal and Temporal	Vascular sclerosis, SPG	<75	9

SPG = subpial gliosis; NSP = no significant pathologic findings; MTS = mesial temporal gliosis; AO = auras only.

* Macroscopic pathology

† No follow-up

TABLE 3
PATHOLOGIC FINDINGS IN 47 PATIENTS WITH TEMPORAL LOBECTOMY*

	No. patients (%)	Outcome			Average follow-up (months)
		Excellent	Good	Poor	
MACROSCOPIC					
Low-grade astrocytoma (including 1 pleomorphic xanthoastrocytoma)	5 (11)	3	1	1	—
Arteriovenous malformation	2 (4)	2	—	—	—
Vascular cicatrix	1 (2)	1	—	—	—
Hamartoma	2 (4)	2	—	—	—
Subarachnoid cyst	1 (2)	1	—	—	—
Total	11 (23)	9	1	1	39.1
MICROSCOPIC					
SPG only	19 (40)	12	2	5	—
3+ HT (all with SPG)	8 (17)	5	2	—	—†
MTS	3 (6)	2	—	1	—
Hamartoma	1 (2)	1	—	—	—
Total	31 (66)	20	4	6	30.4
No significant pathologic findings	5 (11)	3	1	1	38.4

SPG = subpial gliosis; 3+ HT = 3+ heterotopias; MTS = mesial temporal gliosis.

* 47 specimens, mesial structures removed (by suction) in 43; portions of mesial structures available for examination in 24 of 43.

† Follow-up available for only 7 of 8 patients.

and similarly oriented. The specimens were anchored and fixed in Hollande's solution (formalin was used before 1984) for three hours. For each specimen, measurements were taken, gross examination was performed, and a sketch was made on the appropriate lobe diagram, i.e., right lateral temporal, right mesial temporal, left frontal, etc. The ventral margin was inked, and the specimen was serially sectioned and

sections sequentially numbered at 0.5-cm intervals. The specimens were routinely processed after fixation and were imbedded in paraffin. Multiple 10- μ m hematoxylin- and eosin-stained sections were examined.

All of the specimens were examined by one author (MLE). The pathologic findings were categorized into macroscopic (seen with naked eye or CT scan), microscopic, and no significant pathologic abnormality. The

TABLE 4
PATHOLOGIC FINDINGS IN 13 PATIENTS WITH EXTRATEMPORAL RESECTIONS

	No. patients (%)	Outcome			Average follow-up (months)
		Excellent	Good	Poor	
MACROSCOPIC					
Hamartoma (neurofibromatosis)	1 (8)	—	1	—	—
Vascular sclerosis	1 (8)	—	—	—	—
Total	2 (15)	0	1	1	8
MICROSCOPIC					
SPG only	7 (54)	2	1	3	—*
MTS†	1 (8)	—	—	1	—
Hamartoma	1 (8)	1	—	—	—
Total	9 (69)	3	1	4	26.5
No significant pathology	2 (15)	2	—	—	21.0

SPG = subpial gliosis; MTS = mesial temporal gliosis.

* Follow-up available for only 6 of 7 patients.

† Patient had both temporal and frontal resection

specimens were graded 0–3+ with regard to the number of deep-white-matter heterotopic neurons (HT) present. Three plus HT was defined as mature neurons within the deep white matter in multiple (>20) high power fields (hpf), 2+ as neurons in several (5–20) hpf, and 1+ as rare heterotopic neurons. Three plus HT was considered abnormal.

FOLLOW-UP

Postoperatively, the patients were discharged on a regimen of a single anticonvulsant, usually carbamazepine, with a dosage sufficient to produce a therapeutic blood level.

Most patients underwent a follow-up EEG, speech evaluation, neuropsychological testing, and visual field evaluation six months postoperatively. Subsequent follow-up information was obtained either by outpatient visits or telephone.

Seizure reduction of >90%, absence of seizures, or auras only was considered an excellent result. A reduction of 75–90% was considered a good result, and a reduction of <75% a poor result.

RESULTS

Forty-seven patients had either a left or right temporal lobectomy; 46 patients could be followed, with a mean follow-up time of 33.3 months (range 6–84 months). Results were excellent in 70%, good in 13%, and poor in 17% (Table 1).

Thirteen patients had resections of brain other than the temporal lobe; seven patients underwent resections of the frontal lobe (two occipital, one parietal, and three both frontal and temporal). Twelve patients could be followed, with a mean follow-up time of 22.4 months (range 6–54 months). Results were excellent in 42.5%, good 17%, and poor in 42.5% (Table 2).

Of the 47 temporal lobe specimens (excluding the three patients with frontal and temporal lobectomies), there were 11 macroscopic lesions, 31 microscopic lesions, and five lobes showing no significant pathologic features (Table 3). Portions of mesial structures were received and examined in 24 of these patients (Table 1).

Of the 13 “nontemporal” specimens (including three patients with frontal and temporal lobectomies), nine showed microscopic abnormalities, two macroscopic lesions, and two no significant pathologic features (Table 4).

In the 46 patients who underwent temporal lobectomy and were followed, nine (82%) of the 11 patients with macroscopic lesions had an excellent outcome in reduced seizure frequency, with an average follow-up of 39.1 months (range 6–72 months). Thirty patients of the 31 with microscopic temporal lobe abnormalities were available for follow-up, with a mean follow-up of 30.4 months (range 6–84 months). Of these 30 patients 67% (20) had an excellent outcome, 13% (4) a good outcome, and 20% (6) a poor outcome. Of the five patients with no significant pathologic findings, all were followed; 60% (3) had an excellent result, 20% (1) a good result, and 20% (1) a poor result.

Tables 3 and 4 show the pathologic findings. In 24 cases portions of mesial structures identified by the neuropathologist, variably including hippocampus, were available for examination. Mesial temporal sclerosis (MTS) was seen in only three patients of the temporal lobe group.

The most common pathologic abnormality was subpial gliosis (SPG), which was seen in 28 patients or 60% of the temporal lobe group. Specimens from 19 patients (40%) in the temporal lobe group revealed SPG as the only pathologic abnormality. Many of the specimens showed mild to moderate chronic meningeal inflammation over the lateral cortical surface, caused by the subdural electrode array.

Pathologic abnormalities and their ability to predict outcome were evaluated for the macroscopic pathology group compared with the microscopic or no significant pathology groups; there were no significant differences (Fisher's exact test). Likewise, the microscopic pathology group was compared with the no significant pathology group, and there was no significant difference.

Of all temporal lobectomies, 32 (70%) had an excellent result, whereas only 5 (42%) of the extratemporal resections had an excellent result. This difference approached but did not reach statistical significance ($P = 10$) (Fisher's exact test).

Of the temporal lobe group as a whole, 54% became seizure free or had auras only: 73% of the macroscopic lesion subset, 47% of the microscopic lesion subset, and 60% of the no significant pathology subset. These differences were not statistically significant.

DISCUSSION

In this series no single pathologic lesion or group (macroscopic, microscopic) of lesions significantly correlated with outcome of surgery. Patients having temporal lobe resection for macroscopic abnormalities seemed to do best (82% excellent outcome) in contrast to patients with no significant pathologic findings (60% excellent outcome). The overall results for patients with extratemporal resections (42% excellent outcome) was worse than for those with only temporal lobectomies (70% excellent outcome).

In this study there were four cases of MTS, including only three among the 24 patients whose temporal lobe specimens had tissue of mesial origin available for pathologic examination. This low incidence (12.5%)

is undoubtedly related to the surgical technique employed (see methods) in which suction is used to resect all or part of the mesial temporal lobes. Mathieson²⁷ found only a 16% incidence of hippocampal sclerosis in 857 temporal lobes at the Montreal Neurologic Institute (MNI). Our surgical technique is similar to that used at MNI. This finding contrasts with the approximately 47% incidence of MTS reported by Falconer,² who used an en bloc resection technique in a series of 100 patients. Using a similar en bloc technique, the UCLA group has reported a 61% incidence of MTS.²⁰ Margerison and Corsellis²⁸ reported a 40% incidence of MTS at autopsy in 55 patients with chronic epilepsy.

We found an 11% incidence of low-grade gliomas in our temporal lobe specimens. This result is close to the 12% reported by Mathieson²⁷ but is less than the 25% incidence mentioned by Glaser⁸ and Spencer et al.²⁹

Five of our 47 patients who underwent temporal lobectomy had no significant pathologic findings. This incidence of 11% may be artificially high since mesial structures were not available for pathologic evaluation in three of the five cases. Even in series where an en bloc resection technique has been used, 10–23% have shown no significant pathologic features.^{2,20} In the large series from MNI with a resection technique similar to ours, 20% showed no significant pathologic features.²⁷ Our finding that these patients seem to have a worse prognosis for seizure reduction agrees with other studies,^{2,20} but the difference was not statistically significant.

SPG was the most frequent pathologic abnormality and was seen in 60% of our temporal lobectomy patients. SPG was associated with a wide variety of other lesions, including tumors, arteriovenous malformations, and MTS. We believe SPG is a nonspecific abnormality and, in this respect, is similar to the occasional heterotypic neurons found in resected temporal lobes.

We have observed "microdysgenesis"^{30,31} in many of our lobectomy specimens. In particular, we were interested in the numbers of heterotypic neurons in the deep white matter. It appears that patients with 3+ HT form a distinct subset; this distinction is important because, in our experience, 1–2+ HT is found in brains of nonepileptic individuals, a finding in agreement with that of Lyon and Gastaut.³³ Eight patients in our series had 3+ HT (all with associated SPG), and six (75%) had an excellent result.

The origin of the heterotypic neurons is unclear. The neurons may remain in the white matter during out-

ward migration from the periventricular germinal matrix³¹ or perhaps migrate inwardly into the white matter in response to extrinsic influences, such as trauma or toxins. As Lyon and Gastaut suggest, controlled morphometry is needed to confirm our observation.³²

The pathologic lesions seen are probably not the "primary" lesions responsible for epilepsy because none is common to all cases of epilepsy and all of the lesions have been found in nonepileptic patients. We

must, therefore, look to ultrastructural,³³ Golgi,³⁴ and neurochemical studies to further elucidate the pathology of intractable epilepsy.

MELINDA L. ESTES, MD
 Department of Pathology
 The Cleveland Clinic Foundation
 One Clinic Center
 9500 Euclid Avenue
 Cleveland, Ohio 44195

REFERENCES

- Horsley V. Brain surgery. *Br Med J* 1886; 2:670-675.
- Falconer MA. Genetic and related aetiological factors in temporal lobe epilepsy: a review. *Epilepsia* 1971; 12:13-31.
- Jensen I. Temporal lobe surgery around the world. *Acta Neurol Scandinav* 1975; 52:354-373.
- Van Buren JM, Ajmone-Marsan C, Mutsuga N, Sadowsky D. Surgery of temporal lobe epilepsy. *Adv Neurol* 1975; 8:155-196.
- Bhatia R, Kollevold T. A follow-up study of 91 patients operated on for focal epilepsy. *Epilepsia* 1976; 17:61-66.
- Jensen I, Vaernet K. Temporal lobe epilepsy: follow-up investigation of 74 temporal lobe resected patients. *Acta neurochir* 1977; 37:173-200.
- Wieser HG, Bancaud J, Talairach J, Bonis A, Szikla G. Comparative value of spontaneous and chemically and electrically induced seizures in establishing the lateralization of temporal lobe seizures. *Epilepsia* 1979; 20:47-59.
- Glaser GH. Treatment of intractable temporal lobe-limbic epilepsy (complex partial seizures) by temporal lobectomy. *Ann Neurol* 1980; 8:455-459.
- Spencer SS. Depth electroencephalography in selection of refractory epilepsy for surgery. *Ann Neurol* 1981; 9:207-214.
- Wieser HG, Yasargil MG. Selective amygdalohippocampectomy as a surgical treatment of mesiotemporal limbic epilepsy. *Surg Neurol* 1982; 17:445-457.
- Ojemann GA. Neurosurgical management of epilepsy: a personal perspective in 1983. *Appl Neurophysiol* 1983; 46:11-18.
- Rasmussen TB. Surgical treatment of complex partial seizures: results, lessons, and problems. *Epilepsia* 1983; 24(suppl1):S65-S76.
- Goldring S, Gregorie EM. Surgical management of epilepsy using epidural recordings to localize the seizure focus: review of 100 cases. *J Neurosurg* 1984; 60:457-466.
- Cahan LD, Sutherling W, McCulloch MA, Rausch R, Engel J Jr, Crandall PH. Review of the 20-year UCLA experience with surgery for epilepsy. *Cleve Clin Q* 1984; 51:313-318.
- Lesser RP, Dinner DS, Luders H, Morris HH III. Differential diagnosis and treatment of intractable seizures. *Cleve Clin Q* 1984; 51:227-240.
- Ojemann GA, Dodrill CB. Verbal memory deficits after left temporal lobectomy for epilepsy. *J Neurosurg* 1985; 62:101-107.
- Wyllie E, Lüders H, Morris HH, et al. Clinical outcome after complete or partial cortical resection for intractable epilepsy. *Neurology* 1987; 37:1634-1641.
- Kennedy WA, Hill D. The surgical prognostic significance of the electroencephalographic prediction of Ammon's horns sclerosis in epileptics. *J Neurol Neurosurg Psychiatry* 1958; 21:24-30.
- Engel J Jr, Driver MV, Falconer MA. Electrophysiological correlates of pathology and surgical results in temporal lobe epilepsy. *Brain* 1975; 98:129-156.
- Lieb JP, Engel J Jr, Brown WJ, Gevins AS, Crandall PH. Neuropathological findings following temporal lobectomy related to surface and deep EEG patterns. *Epilepsia* 1981; 22:539-549.
- Morris HH, Luders H. Electrodes. *Electroencephalographr Clin Neurophysiol* 1985; 37(suppl):3-26.
- Lesser RP, Luders H, Dinner DS, Kahn J, Cohen L. The location of speech and writing functions in the frontal lobe area: results of extraoperative cortical stimulation. *Brain* 1984; 107:275-291.
- Morris HH, Luders H, Lesser RP, Dinner DS, Hahn J. Transient neuropsychological abnormalities (including Gerstmann's syndrome) during cortical stimulation. *Neurology* 1984; 34:877-883.
- Luders H, Lesser RP, Hahn J, Dinner DS, Klem G. Cortical somatosensory evoked potentials in response to hand stimulation. *J Neurosurg* 1983; 58:885-894.
- Ives J. 'Time-scribe': a universal time writer for any EEG/polygraph chart recorder. *Electroencephalogr Clin Neurophysiol* 1984 57:388-391.
- Gotman J, Ives JR, Gloor P. A computer system for prolonged EEG recordings of ictal and interictal activity in epilepsy. [In] Akimoto H, Kazamatsuri H, Seino M, Ward A, eds. *Advances in Epileptology: XIII Epilepsy International Symposium*. New York, Raven Press, 1982, pp 167-172.
- Mathieson G. Pathology of temporal lobe foci. *Adv Neurol* 1975; 11:163-185.
- Magerison JH, Corsellis JAN. Epilepsy in the temporal lobes: a clinical electroencephalographic and neuropathological study of the brain in epilepsy, with particular reference to the temporal lobes. *Brain* 1966; 89:499-530.
- Spencer DD, Spencer SS, Mattson RH, Williamson PD. Intracerebral masses in patients with intractable partial epilepsy. *Neurology* 1984; 34:432-436.
- Meencke H-J, Janz D. Neuropathological findings in primary generalized epilepsy: a study of eight cases. *Epilepsia* 1984; 25:8-21.
- Meencke H-J, Janz D. The significance of microdysgenesis in primary generalized epilepsy: an answer to the considerations of Lyon and Gastaut. *Epilepsia* 1985; 26:368-371.
- Lyon G, Gastaut H. Considerations on the significance attributed to unusual cerebral histological findings recently described in eight patients with primary generalized epilepsy. *Epilepsia* 1985; 26:365-367.
- Brown WJ. Structural substrates of seizure foci in the human temporal lobe (a combined electrophysiological, optical microscopic and ultrastructural study). [In] Brazier MAD, ed. *Epilepsy: Its Phenomena in Man*. New York, Academic Press, 1973, pp 339-374.
- Scheibel ME, Scheibel AB. Kippocampal pathology in temporal lobe epilepsy. A Golgi survey. [In] Brazier MAD, ed. *Epilepsy: Its Phenomena in Man*. New York, Academic Press, 1973, pp 311-337.