

Extensive alopecia areata

Results of treatment with 3% topical minoxidil

RICHARD E. RANCHOFF, MD; WILMA F. BERGFELD, MD, FACP; WILLARD D. STECK, MD, FACP; STEVEN J. SUBICHIN, MD

■ A 3% topical minoxidil solution was used to treat 31 normotensive persons (13 male, 18 female) with extensive alopecia areata. After 15 months, three patients (14%) had 75%–100% regrowth, 13 (59%) had some form of regrowth, and nine (41%) had no regrowth. In the initial three-month double-blind portion of the study, minoxidil was not shown to be more effective than placebo. Biopsy specimens from eight patients who underwent biopsy prior to treatment, after three months, and posttreatment showed no significant change in peribulbar or perivascular inflammation. Prominent, new anagen follicles were observed. The 3% topical minoxidil was generally well tolerated and skin irritation was minimal. Blood pressure monitoring revealed no significant changes in diastolic or systolic pressures. Minoxidil is a relatively safe treatment for extensive alopecia areata and may be effective in the treatment of some cases of recalcitrant disease.

□ INDEX TERMS: ALOPECIA AREATA; MINOXIDIL □ CLEVE CLIN J MED 1989; 56:149–154

MINOXIDIL (2,4-diamino-6-piperidinopyrimidine-3-oxide), a potent peripheral vasodilator, is used orally for severe hypertension and has been noted to induce reversible hypertrichosis in a majority of treated patients.¹ The excess hair growth is most prominent on

alone or vehicle with 3% minoxidil. From the 4th to the 15th month, all patients received 3% minoxidil solution. Scalp biopsies were done prior to treatment, during treatment at three months, and at the end of the study.

PATIENTS AND METHODS

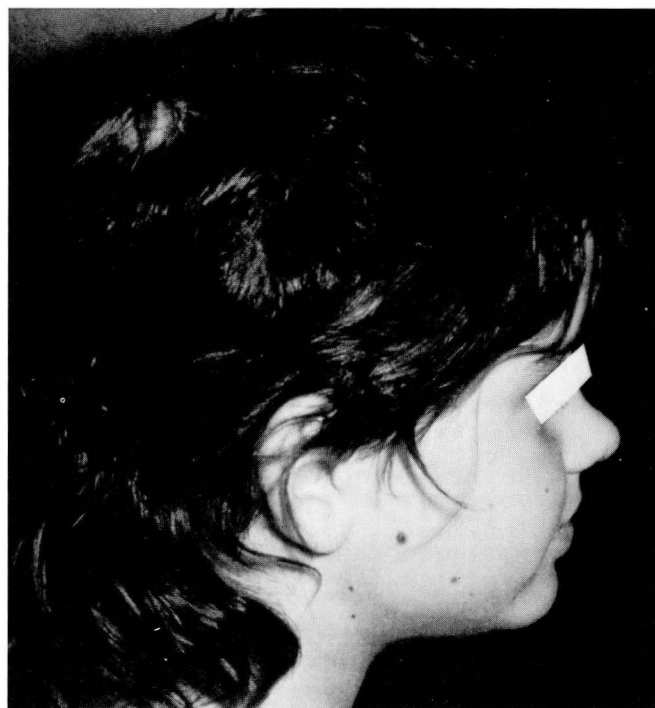
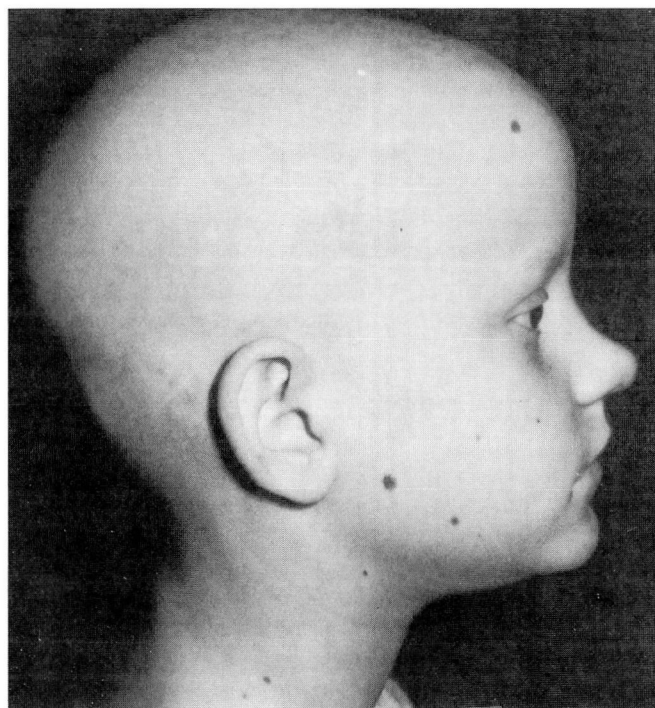
Thirty-one normotensive patients with extensive alopecia areata entered the study. Patient age ranged from 8 to 60 years; 13 (42%) were male and 18 (58%) were female; 30 (97%) were white and one (3%) was black. Of the 31 patients beginning this study, seven had extensive alopecia areata, 10 had alopecia totalis, and 14 had alopecia universalis. Nine of the 31 patients did not complete the study. Of the 22 patients completing the study, seven had extensive alopecia areata, six had alopecia totalis, and nine had alopecia universalis.

In this 15-month study the initial three months served as a double-blind study in which patients received vehicle alone or vehicle with 3% minoxidil.

■ See also the editorial by Fiedler (pp 122-123)

the temples, sideburn areas, glabella, back and extremities.² Previous studies have given mixed results.²⁻¹¹ We report the results of a 15-month study using 3% topical minoxidil solution; the initial three months served as a double-blind study in which patients received vehicle

From the Departments of Dermatology (R.E.R., W.F.B., W.D.S.) and Biostatistics and Epidemiology (S.J.S.), The Cleveland Clinic Foundation, Cleveland, Ohio. Submitted Nov 1987; revision accepted Sep 1988.



A, B

FIGURE 1. Right side of scalp of patient 18 (8 years old with extensive alopecia) prior to (A) and after (B) treatment; 75%–100% regrowth category.

From the 4th to the 15th month, all patients received 3% minoxidil solution. Half of the patients were randomly chosen to undergo scalp biopsies, which were done at the start of the study, during treatment at three months, and at the end of the study. Of the eight patients who underwent all three biopsies, four were in the placebo group and four were in the 3% minoxidil group.

The vehicle consisted of 30% propylene glycol USP, 50% ethanol USP, and 20% purified water USP. The active solution contained 3% minoxidil, 30% propylene glycol USP, 50% ethanol USP, and 17% purified water USP.

The solution was applied to the entire scalp in the morning and evening with a Dab-O-Matic Mesh Applicator Top. The patients were instructed to cover the treatment sites with petrolatum after the evening application.

Regrowth was grouped into five categories: 0%, 1%–25%, 25%–50%, 50%–75%, and 75%–100% regrowth.

The patients' blood pressures, weights, respirations, pulses, treatment sites, and adverse reactions were monitored every month for the first six months and then every two months after that until the end of the study.

Laboratory data (including complete blood count, urinalysis, and alkaline phosphatase, total bilirubin, blood urea nitrogen, calcium, chloride, cholesterol, creatinine, glucose, phosphorus, potassium, protein, serum aspartate aminotransferase, sodium, thyroxine, thyroid stimulating hormone, and uric acid levels) were taken at 0, 12, 24, 40, 48, and 64 weeks. Photographs were obtained at 0, 12, 24, 40, and 64 weeks. Electrocardiograms were obtained at the start and at the end of the study. Serum minoxidil and minoxidil glucuronide levels were measured by radioimmunoassay at the same time intervals as routine laboratory tests.

For specific variables, means for placebo and minoxidil groups were compared using unpaired *t* tests. Changes in inflammation or blood vessel size (open *v* closed) over the course of the treatment were compared using an exact binomial test. Fisher's exact test was used to compare the amount of regrowth (none versus any) in younger and older subjects at 64 weeks and in placebo versus minoxidil at 12 weeks. One-way analysis of variance was used to compare the mean durations of disease in different growth categories. Note that the small number of subjects studied may give insufficient statistical power to detect differences in some cases.

A, B

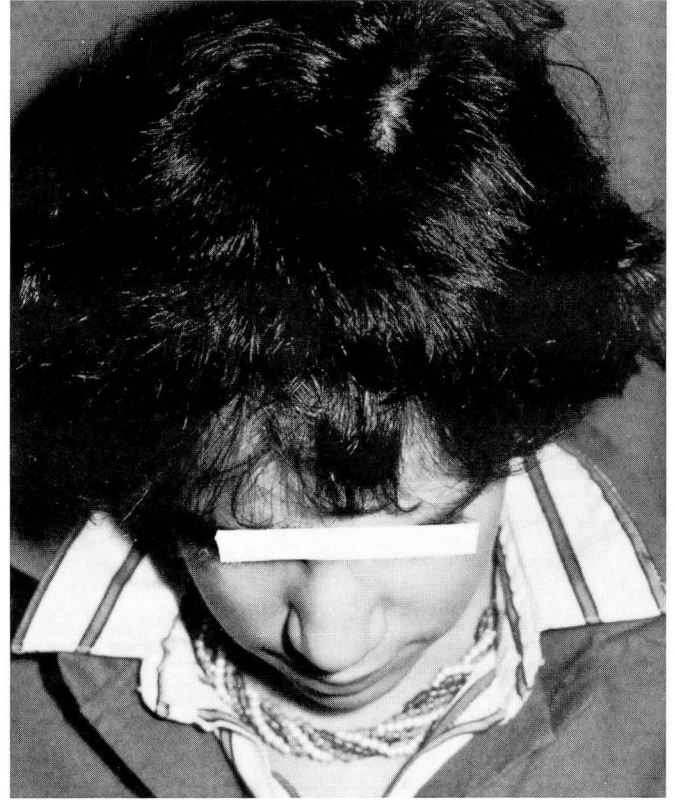
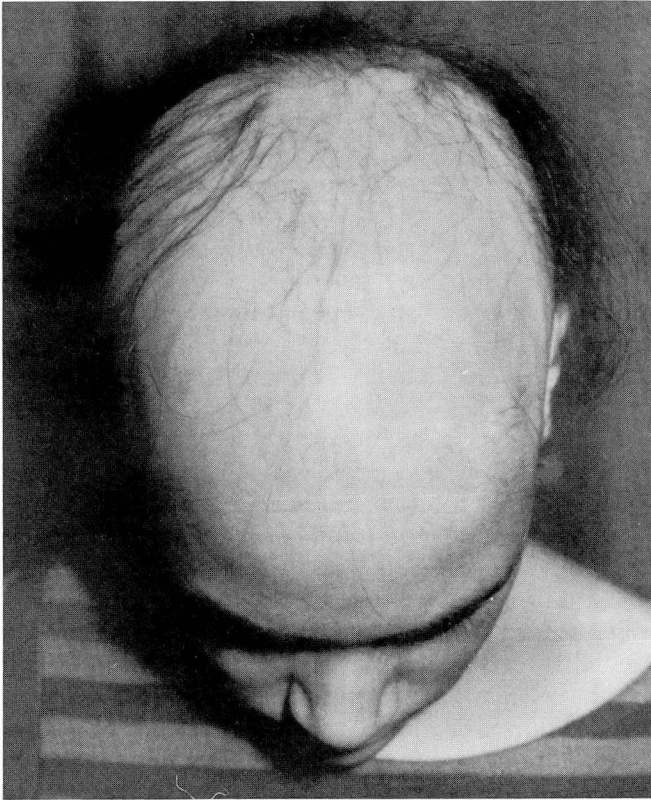


FIGURE 2. Vertex of scalp of patient 2 (15 years old with extensive alopecia areata) prior to (A) and after (B) treatment; 75%–100% regrowth category.

A, B

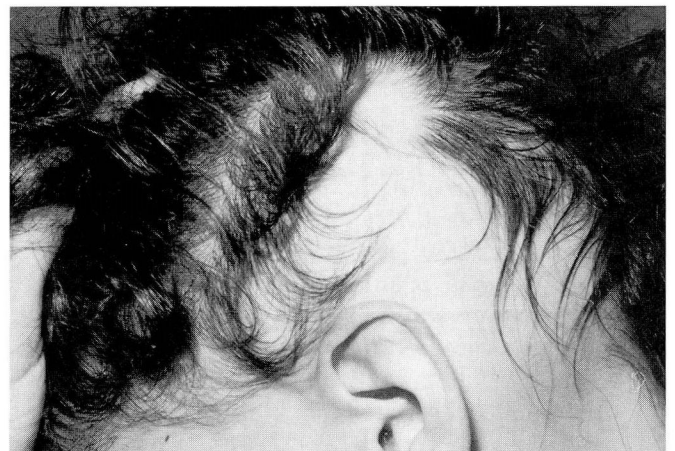
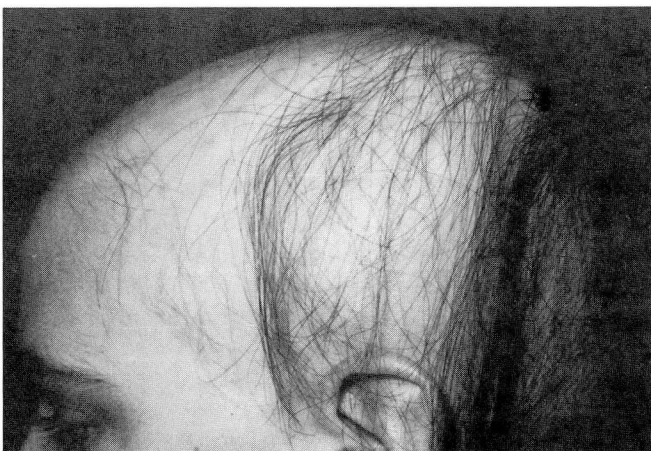

FIGURE 3. Left side of scalp of patient 2 prior to (A) and after (B) treatment.

RESULTS

Thirty-one normotensive patients initially entered the study. Nine patients dropped out of the study, of whom eight were lost to follow-up.

Twenty-nine patients completed the double-blind 12-week portion of the study. There was no significant regrowth difference between placebo and 3% minoxidil solution at 12 weeks ($P=.14$).

Twenty-two patients completed the 15-month study.

TABLE 1
RESPONSE TO TOPICAL MINOXIDIL BY AGE

Age (yr)	0%	1%–25%	25%–50%	50%–75%	75%–100%
8–19		2		1	3
20–29	1	1	1		
30–39	3	1	1	1	
40–49	3	2			
50–60	2				

TABLE 2
PERIBULBAR INFLAMMATION AT BASELINE AND 64 WEEKS

Baseline	64 Weeks	
	Yes	No
Yes	4	1
No	1	2

TABLE 3
PERIVASCULAR INFLAMMATION AT BASELINE AND 64 WEEKS

Baseline	64 Weeks	
	Yes	No
Yes	3	2
No	1	2

Three patients (14%) had 75%–100% regrowth, 13 (59%) had some regrowth, and nine (41%) had no regrowth. None of the patients went without a wig (Figures 1–3). When the age category of the patient was analyzed according to the percent of regrowth, younger patients (less than 30 years old) had a significantly ($P=.03$) better response to topical minoxidil (Table 1). There were no significant differences among the mean duration of disease in the different growth categories ($P=.59$).

One patient, 60 years old, was dropped from the study when dyspnea on exertion and chest pain developed while the patient was using the fourth bottle of minoxidil. Cardiac catheterization revealed coronary artery disease unrelated to minoxidil treatment.

Other side effects noted were pruritus, erythema, dryness, stinging, burning, and mild folliculitis. Most of these side effects were mild and resolved spontaneously with continuation of the topical minoxidil or with low-potency topical corticosteroids. Two patients were presumed to have allergic contact dermatitis to the topical minoxidil solution, but had negative patch tests to 3%, 5%, 10% minoxidil in petrolatum, 4%, 10%, 30% aqueous propylene glycol solution, and ethanol 95%. One patient had an episode of erythema nodosum

during treatment. A lymphocyte transformation test to minoxidil was negative and the patient continued the minoxidil without recurrence.

One asymptomatic 15-year-old patient had an electrocardiographic change

from normal to early repolarization variant. One patient had hypertension that presented as vertigo during the study and resolved after treatment with hydrochlorothiazide, 25 mg daily. Finally, one 19-year-old woman had chest pain that was attributed to a long history of premature ventricular contractions. She continued in the study without further difficulty.

Eleven patients were randomly chosen to undergo scalp biopsies. Eight patients completed all three biopsies; three more patients completed a pretreatment and three-month biopsy. Five of the eight patients completing all three biopsies had pretreatment and posttreatment peribulbar inflammation (Table 2). Six of the eight showed no change in the amount of peribulbar inflammation from baseline to 64 weeks. There was no significant change in peribulbar inflammation with treatment ($P=.75$).

There was also no significant change in perivascular inflammation, which was present in five of eight patients initially and in four of eight at the end of the study ($P=.5$) (Table 3). Five of the eight biopsy specimens showed no change in the amount of perivascular inflammation from baseline to 64 weeks.

There was evidence of new anagen formation and increased follicular diameter (Figures 4 and 5). There was no significant change in dermal blood vessel lumina prior to treatment or after 64 weeks ($P=1.0$). Blood vessel lumina remained open throughout the study.

When placebo and minoxidil-treated groups were compared, we found no significant change in systolic or diastolic blood pressure, pulse, respiratory rate, or weight from baseline to 12 weeks or baseline to 64 weeks ($P>.05$).

DISCUSSION

We report the results of a 15-month study using 3% topical minoxidil to treat patients with extensive alopecia areata, alopecia totalis, or alopecia universalis. Scalp biopsies were done prior to treatment, during treatment at three months, and at the end of the study. All subjects had extensive alopecia areata; 16 of 22 patients who

A, B

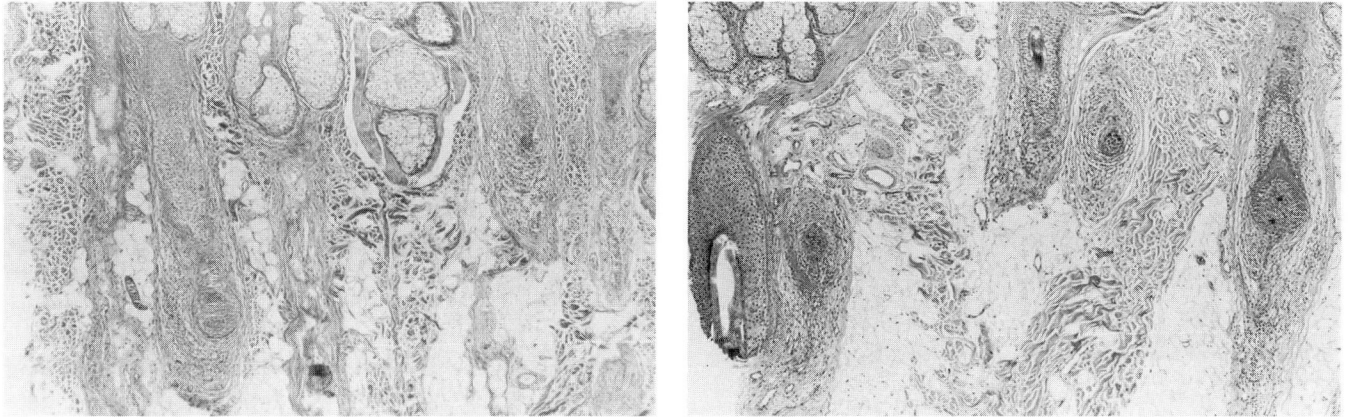


FIGURE 4. Pretreatment (A) and posttreatment (B) biopsy specimens from patient 15 showing new anagen formation but continued peribulbar inflammation ($\times 40$).

A, B

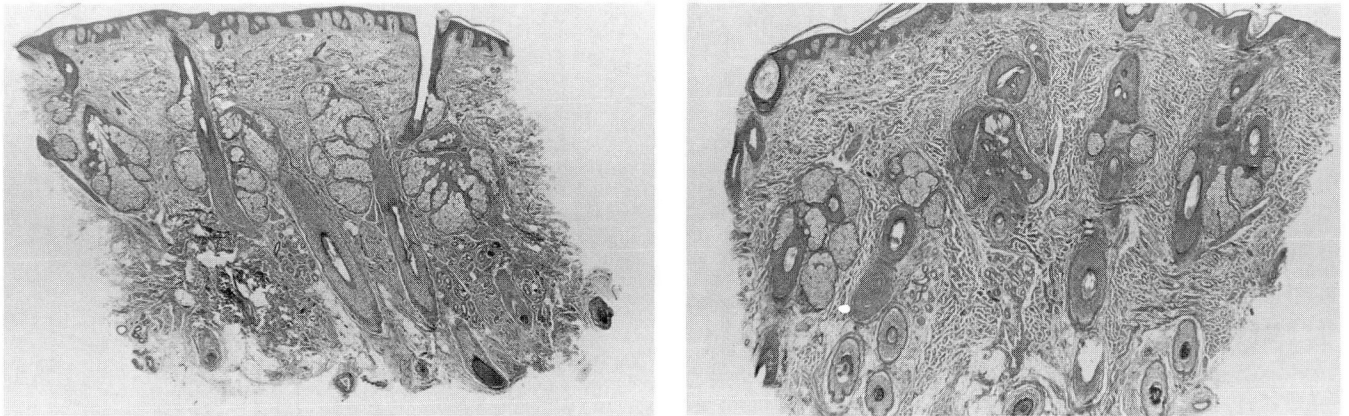


FIGURE 5. Pretreatment (A) and posttreatment (B) biopsy specimens from patient 17 showing new anagen formation ($\times 20$).

finished the study had alopecia totalis or universalis. Fourteen percent of our patients had marginal, cosmetically acceptable scalp hair regrowth. None of the patients could go without a wig. Fifty-nine percent of the patients had some regrowth; 41% had no regrowth. Younger patients had a better response to topical minoxidil than older patients.

Results of other studies have varied. Weiss et al,⁹ in a series of 48 patients, observed that 25 patients (52%) had terminal hair regrowth and of those, 11 (23%) had cosmetically acceptable regrowth. Fenton and Wilkinson³ reported that 16 of 26 (61%) patients treated with 1% minoxidil had cosmetically acceptable regrowth. Vanderveen et al² reported that none out of 10 patients with alopecia areata had regrowth with either 1% or 5% minoxidil. Fiedler-Weiss et al¹² reported a better response to 5% minoxidil than to 1% minoxidil; 6% had cosmetically acceptable regrowth.

Histologically, there was no significant change in blood vessel lumina opening, peribulbar inflammation, or perivascular inflammation. There was evidence of new anagen formation, and an increased diameter of the hair follicle. Fenton and Wilkinson³ reviewed a few posttreatment biopsy specimens and suggested that the disease is still active despite regrowth. Weiss et al⁹ reported decreased perifollicular lymphocytic infiltrate, increased hair follicle diameter, and opening up of previously closed dermal blood vessels. The perivascular infiltrate remained unchanged. Our study concurs with that of Weiss et al⁹ in that there was no change in perivascular infiltrate and an increase in hair follicle diameter. However, we were unable to find a change in peribulbar inflammation or change in lumina of dermal blood vessels.

When placebo and minoxidil groups were compared, we found no significant change in mean systolic or dias-

tolic blood pressure, pulse rate, respiratory rate, or weight from baseline to either 12 or 64 weeks. We originally reported a decrease in blood pressure with the use of topical minoxidil¹³; however, in retrospect, when the minoxidil blood levels and the double-blind code were taken into account, this was not significant.

Throughout the study, there were no major adverse reactions. The one patient who had dyspnea on exertion and chest pain was found by catheterization to have coronary artery disease. His symptoms were, therefore, not likely to be due to the minoxidil. Early repolarization variant developed on the electrocardiogram of one 15-year-old patient. Olsen et al¹⁴ reported similar changes in patients with male-pattern alopecia treated with minoxidil. Whether this was caused by the minoxidil solution or a normal benign variant in a young patient is unclear.

The mechanism of action of minoxidil is unknown. Its mode of action may be by increasing cutaneous blood flow.¹⁵ Cohen¹⁶ reported that minoxidil has a mitogenic effect on epidermal cells and immunosuppressive effects on lymphocytes, suggesting an immunologic effect.

A difficulty with our study was the short three-month period of the double-blind portion of the study. To make a definitive statement concerning the efficacy of 3%

topical minoxidil, a longer double-blind period may be necessary. In addition, a study using topical minoxidil on half of the scalp may be inadequate because of the systemic effects of any absorbed minoxidil.

Our results of 14% marginal, cosmetically acceptable regrowth may have been lower than those reported in other studies since alopecia in the majority of our patients had been unresponsive to other treatments (dinitrochlorobenzene, topical anthralin, intralesional steroids, and oral steroids). In our experience, alopecia areata has a cyclic pattern of activity with shed, growth, shed, and regrowth. It has been apparent in the long-term minoxidil study that patients whose disease is responsive to minoxidil may have increased activity of their alopecia areata, but will have regrowth with continuation of the minoxidil.

ACKNOWLEDGMENT

This investigation was supported by a grant from the Upjohn Company, Kalamazoo, Michigan, which supplied the minoxidil solution and the Dab-O-Matic Mesh Applicator Top equipment.

We wish to thank George Williams, Ph.D. and Gerald Beck, Ph.D. of the Department of Biostatistics and Epidemiology, Cleveland Clinic Foundation, for their help in the statistical analysis of the data; Linda Langford, research coordinator; Patricia Menendez, research nurse; Carol White, medical transcriptionist; Flora Williams, photographer; and Jonathan Bass, M.D., Dermatopathology Fellow for their participation in the study.

REFERENCES

1. Linas SL, Nies AS. Minoxidil. *Ann Intern Med* 1981; **94**:61-65.
2. Vanderveen EE, Ellis CN, Kang S, et al. Topical minoxidil for hair regrowth. *J Am Acad Dermatol* 1984; **11**:416-421.
3. Fenton DA, Wilkinson JD. Topical minoxidil in the treatment of alopecia areata. *Br Med J* 1983; **287**:1015-1017.
4. Fenton DA, Wilkinson JD. Alopecia areata treated with topical minoxidil. *J R Soc Med* 1982; **75**:963-965.
5. King CM, Harrop B, Dave VK. Topical minoxidil in the treatment of alopecia areata (letter). *Br Med J* 1983; **287**:1380.
6. Maitland JM, Aldridge RD, Main RA, White MI, Ormerod AD. Topical minoxidil in the treatment of alopecia areata (letter). *Br Med J* 1984; **288**:794.
7. Hindson C, Spiro J, Taylor A, Pratt E. Topical minoxidil in the treatment of alopecia areata (letter). *Br Med J* 1984; **288**:1087.
8. Weiss VC, West DP, Muller CE. Topical minoxidil in alopecia areata. *J Am Acad Dermatol* 1981; **5**:224-226.
9. Weiss VC, West DP, Fu TS, et al. Alopecia areata treated with topical minoxidil. *Arch Dermatol* 1984; **120**:457-463.
10. White SI, Friedman PS. Topical minoxidil lacks efficacy in alopecia areata (letter). *Arch Dermatol* 1985; **121**:591.
11. Frenz G. Topical minoxidil for extended areate alopecia. *Acta Derm Venereol (Stockh)* 1985; **65**:172-175.
12. Fiedler-Weiss VC, West DP, Cuner M, Rumsfield JA. Topical minoxidil dose response effect in alopecia areata. *Arch Dermatol* 1986; **122**:180-182.
13. Ranchoff RE, Bergfeld WF. Topical minoxidil reduces blood pressure (letter). *J Am Acad Dermatol* 1985; **12**:586-587.
14. Olsen EA, Weiner MS, DeLong ER, Pinnell SR. Topical minoxidil in early male pattern baldness. *J Am Acad Dermatol* 1985; **13**:185-192.
15. Mitchell AJ, Krull EA. Alopecia areata: pathogenesis and treatment. *J Am Acad Dermatol* 1984; **11**:763-775.
16. Cohen RL, Cook B, Weiss VC, Stinson AY, West DP, Chambers DA. Mitogenic and immune suppressive effects of minoxidil on epidermal cells and lymphocytes in vitro (abst). *J Invest Dermatol* 1983; **80**:307.