

# Facial fuzz and funny findings

## Facial hair causing otalgia and oropharyngeal pain

FRANCIS A. PAPAY, MD; HOWARD L. LEVINE, MD; WILLIAM A. SCHIAVONE, DO

■ Three patients with referred otalgia and/or oropharyngeal pain due to ectopic facial hair found in either the external auditory canal or oropharynx were treated at the Cleveland Clinic Foundation, Department of Otolaryngology and Communicative Disorders. In each of these patients, annoying symptoms were relieved by simple removal of the misplaced facial hair. Sensory nerve innervation of the external ear and oropharynx and their interrelationship in referred pain are described in detail following the case reports.

□ INDEX TERMS: EARACHE; HAIR; OROPHARYNX □ CLEVE CLIN J MED 1989; 56:273-276

**R**EFERRED otalgia is a common occurrence in patients with oropharyngeal and laryngeal inflammation secondary to infectious and neoplastic processes. Approximately 50% of all pain experienced in the ear originates from other sources.<sup>1</sup> Referred otalgia can be explained by the interrelationship of sensory nerve innervations of the auricle, external auditory meatus, and oropharynx. The external ear has multiple sensory innervations from cranial nerves V, VII, IX, and X and cervical nerve roots C<sub>2</sub> and C<sub>3</sub>. Because of multiple sensory innervation, pain can commonly be referred to the ear from distant anatomic sources. For similar reasons, other anatomic sites of the head and neck, such as the oropharynx, may have referred pain from an irritative focus in the external auditory canal. The following three case reports highlight each of these examples.

From the Departments of Otolaryngology and Communicative Disorders (F.A.P., H.L.L.) and Cardiology (W.A.S.), The Cleveland Clinic Foundation, Cleveland, Ohio. Submitted May 1988; accepted Oct 1988.

Address reprint requests to Howard L. Levine, MD, Department of Otolaryngology and Communicative Disorders, Cleveland Clinic Foundation, One Clinic Center, 9500 Euclid Avenue, Cleveland, Ohio 44195-5034.

### CASE REPORTS

#### Case 1

A 34-year-old male attorney complained of a persistent nonproductive cough and sensation of a lump in the right hypopharynx for approximately 4 months. The patient denied any prodromal symptoms of upper respiratory inflammation at the outset of his cough. He did not relate the cough to any specific time of day or activity, such as talking or eating. He denied any history of asthma, dysphagia, odynophagia, or otalgia. There was no history of reflux esophagitis, dyspepsia, or hiatus hernia. He had previously seen several physicians and had had normal physical and radiographic examinations of the head, neck, and lungs. He denied any history of tobacco or alcohol use.

Physical examination of the head and neck was unremarkable except for hair imbedded in cerumen lying against the right tympanic membrane. This was removed during this initial examination. The remainder of the head and neck examination was within normal limits except for an erythematous area within the larynx.

After removal of the cerumen-imbedded hair the patient was scheduled for a barium examination of the

esophagus and reexamination in 3 weeks. At that time flexible laryngoscopy was to be performed after evaluation of the barium examination.

Upon return to the outpatient clinic the patient stated that his cough had totally resolved within one day after cleaning of his right ear at the previous visit. On reexamination with a fiberoptic laryngoscope the larynx was completely normal. The barium examination was also normal. The patient has continued to be free of his symptoms.

## Case 2

A 37-year-old male cardiologist complained of left otalgia with unilateral crunching sound upon chewing and swallowing. This was bothersome, especially with placement of his stethoscope ear pieces during auscultation of patients. The cardiologist additionally complained of intermittently increased otalgia and sharp pain in the preauricular region. There was a concomitant ipsilateral sound with pitch characteristics described as a pericardial or pleural rub in his left ear. He denied any history of recent external otitis, otitis media, or sore throat.

Examination of the patient did not elicit symptoms of auricular pain with motion of the tragus. Externally there were no signs of any obvious otic discharge or lymphadenopathy palpable in the neck. On examination of the left external auditory meatus, clipped scalp hair was found positioned against the left tympanic membrane. Upon questioning, the patient stated the symptoms first occurred shortly after having a hair cut. Under magnification with the microscope, a 6-mm long scalp hair clipping that was imbedded in the tympanic membrane was removed using alligator forceps. After removal of the hair clipping, the patient acknowledged immediate relief of the otalgia and crunching sound in the left ear. At follow-up there had been no recurrence of symptoms.

## Case 3

A 45-year-old male bearded surgeon complained of a right-sided dull aching pain of the ear and oropharynx associated with odynophagia. The patient stated he first noticed these symptoms while performing surgery three days earlier. During and after the surgical procedure the surgeon felt that he had to clear his throat continuously due to a sensation of a mass in the right oropharynx. He could not relate the severity of his otalgia and oropharyngeal pain to mastication and speaking.

Upon examination the bilateral external otic canals were free of any foreign material. There were no signs of any obvious otic inflammation. The oral examination

did reveal a misplaced facial hair, presumably from the patient's beard, imbedded in the right base of tongue at the region of the lingual tonsils, posterior to the sulcus terminalis. This was removed by indirect mirror and alligator forceps. The rest of the head and neck examination was within normal limits.

Immediately after removal of the hair, there was relief of the otalgia and odynophagia. The patient recalled that his misplaced beard hair might have become imbedded during surgery when, with surgical mask on, he inhaled to speak.

## DISCUSSION

In these cases of referred otalgia and atypical oropharyngeal pain, symptoms were caused by misplaced facial hair irritating areas of sensory innervation that ultimately referred pain to the auricle, external ear canal, and middle ear cleft. Understanding the pathogenesis of symptoms in each of these cases necessitates knowledge of the sensory nerve innervation of the oropharynx, auricle, and middle ear. Since the auricle, external ear canal, and surrounding regions are embryologically formed from the first and second branchial arches, it is logical to assume that the referred pain in these areas would often be associated with the trigeminal nerve (nerve of first branchial arch) and the facial nerve (nerve of the second branchial arch).<sup>1-3</sup> However, the external canal and middle ear cavity are innervated by several cranial nerves in addition to the trigeminal and facial nerves. Therefore, it is possible that referred otalgia can also arise from other regions with similar sensory innervation. Adjacent cutaneous regions of the auricle are supplied by cervical nerve roots C<sub>2</sub> and C<sub>3</sub>. Referred pain from these regions of the external ear may originate in nerve stimuli from distant anatomic sites also supplied by cervical nerve roots C<sub>2</sub> or C<sub>3</sub>.

Figure 1 illustrates the special and general sensory nerve innervations of the head and neck regions that are pertinent to referred otalgia or heterotopic pain of the external ear canal. The sensory innervation of the ear includes contributions from the fifth, seventh, ninth, and tenth cranial nerves and the cervical plexus. The fifth cranial nerve, through its auriculotemporal branch of the mandibular division, supplies the skin of the anterior and superior external auditory canal wall, helical crus, and tragus. The auricular branch of the tenth cranial nerve (Arnold's nerve), together with branches of the seventh and ninth cranial nerves, supplies the posterior inferior portions of the external auditory canal, conchal concavity, and external surface of the tympanic

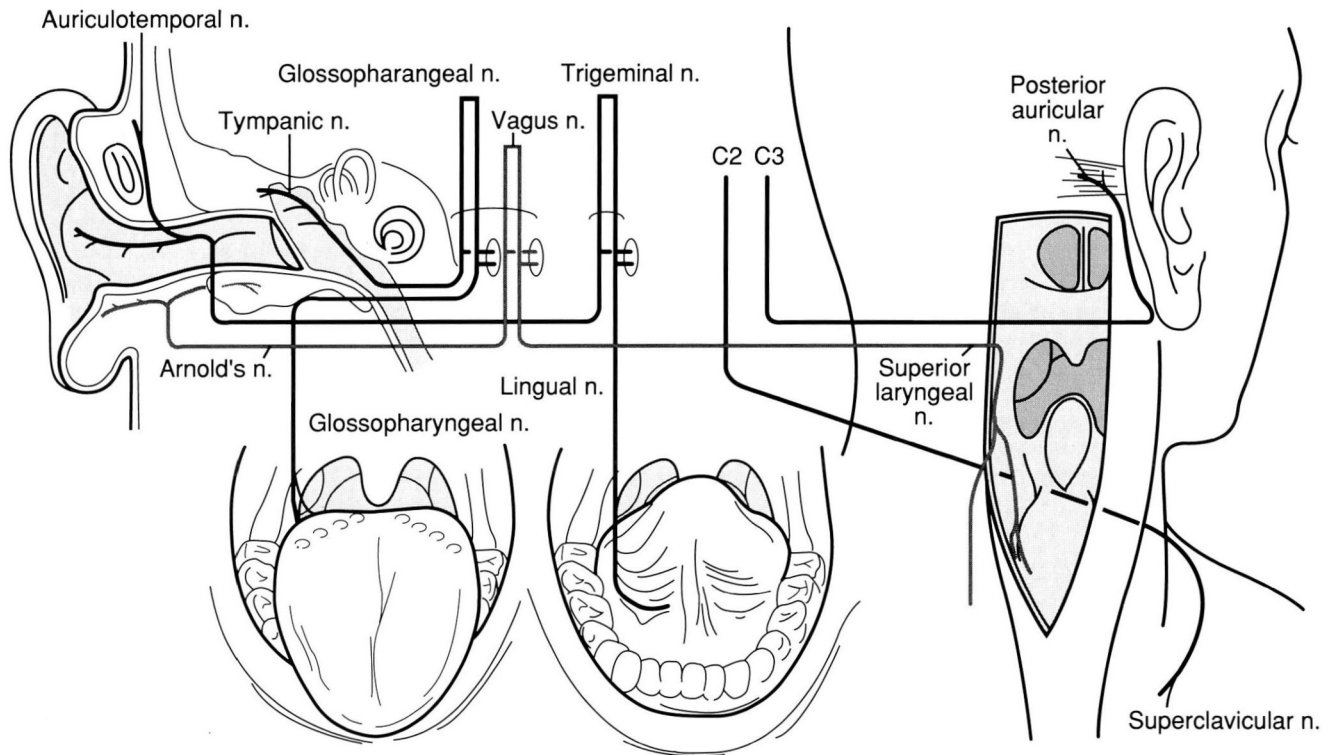


FIGURE 1. The special and general sensory nerve innervations of the head and neck regions that are pertinent to referred otalgia or heterotopic pain of the external ear canal.

membrane. The posterior auricle and adjacent mastoid regions are supplied by a mixture of the greater auricular nerve (cervical nerve root 3) and the seventh cranial nerve. Subauricular and mastoid areas also contain overlapping communications with the lesser occipital nerve (cervical nerve root 2 and 3).

The sensory innervation of the middle ear constitutes the tympanic plexus. This plexus is formed by the tympanic branch of the ninth cranial nerve (Jacobson's nerve) with contributions from the superior and inferior caroticotympanic branches of the sympathetic plexus of the internal carotid artery. The tympanic branch of the ninth nerve additionally supplies the medial side of the tympanic membrane.

Because of the various multisensory innervations and communications of these cranial and cervical nerves, it is easy to understand the complexity and difficulty in diagnosis of heterotopic and homotopic otalgia.

In Case 1, the patient's referred supraglottic sensation may best be described as vagal referred pain originating from the auricular nerve of Arnold (a branch of the vagus nerve) in the external auditory canal. The referred sensation via interthalamic connections is thought to be transmitted as referred pain from the superior laryngeal nerve of vagal origin, supplying sensation to the supraglottic and inferior pharyngeal mucosal surfaces. The phantom dysphagia described by the patient disappeared once the irritation was removed from the sensory region of Arnold's nerve. This case of referred supraglottic dysesthesia represents the opposite correlate of referred otalgia via vagal sensory pathways.

Case 2 describes a case of otalgia produced by ectopic hair in the external auditory canal against the tympanic membrane without any referred oropharyngeal or supraglottic discomfort. The pain was vague and at times intermittently sharp, with associated pain around the

external auricle. The referred pain associated with the inflammatory focus at the tympanic membrane can best be illustrated by observing the sensory afferent pathways of the trigeminal nerve and their relation to sensation of the auricle and tympanic membrane.

Case 3 illustrates referred otalgia and oropharyngeal pain from an oropharyngeal sensory focus supplied by the glossopharyngeal nerve. The inflammatory focus in this case was the base of tongue, and the referred focus in the middle ear was due to mixed sensory perceptions from Jacobson's nerve traversing the middle ear cleft and supplying sensation to the middle ear mucosa.

It is interesting to note that these patients had referred pain from inflammatory foci caused by ectopic facial hair. Two of the patients had occupations that may have further introduced these ectopic facial hairs into the areas of irritation. The surgeon wearing a full beard most likely introduced his beard hair into his lingual tonsillar region while inhaling during surgery. The cardiologist may have further driven his hair clippings into the auditory meatus

after his hair cut by placing the stethoscope ear pieces into the external auditory meatus.

Ectopic facial hair is not uncommonly found in the external auditory canal during routine examination for otalgia. However, otic pain associated with these misplaced hairs is uncommon.<sup>4,5</sup>

---

#### SUMMARY

---

Three cases illustrate how facial hair can cause irritative foci of the oropharynx and external ear that subsequently lead to referred otalgia and oropharyngeal pain. When the otologic examination is normal but the patient complains of ear pain, a generalized otolaryngologic examination should be extended with careful examinations of known anatomical regions that may elicit referred otalgia or oropharyngeal pain. A simple office ear cleaning and foreign body removal can save the patient further diagnostic study, expense, and annoyance.

---

#### REFERENCES

---

1. Davies J. Embryology and anatomy of the head, neck, face, palate, nose and paranasal sinuses. [In] Paparella MM, Shumrick DA, eds. *Otolaryngology*. Vol. 1. 2d ed. Philadelphia, WB Saunders, 1980, pp 63–123.
2. Chasin WD. Otolgia. [In] Bluestone CD, Stool SE, Arjona SK, eds. *Pediatric Otolaryngology*. Vol. 1. 1st ed. Philadelphia, WB Saunders, 1983, pp 213–222.
3. Hughes GB. Referred otalgia. [In] Hughes GH, ed. *Textbook of Clinical Otolaryngology*. New York, Thieme-Stratton, 1985, pp 339–343.
4. Wolff AP, May M, Nuell D. The tympanic membrane: a source of the cough reflex. *JAMA* 1973; 223:1269.
5. Schiavone WA, Levine HL. Hair clippings in the external auditory canal: Ah, there's the rub (letter). *N Engl J Med* 1988; 318:54.