

DONALD G. VIDT, MD AND ALAN W. BAKST, PHARM D, RPH, EDITORS

Thrombolytic therapy

A review (Part 2 of 2)

JAMES H. STEWART, MD; JEFFREY W. OLIN, DO; ROBERT A. GRAOR, MD

ALTHOUGH thrombolytic agents have been used for several years for myocardial infarction and for venous thromboembolic disease (discussed in Stewart JH, Olin JW, Graor RA. Thrombolytic therapy: a review [part 1 of 2]. *Cleve Clin J Med* 1989; 56:189–196), other indications for using thrombolytic agents have recently emerged. This review discusses use of thrombolytic agents to treat occlusions of peripheral arteries and bypass grafts, arteriovenous fistulas, and non-hemorrhagic stroke. Methods of monitoring therapy and possible complications are also delineated.

PERIPHERAL ARTERIAL OCCLUSIONS

Thrombosis of native atherosclerotic arteries, thrombosis of bypass grafts, and emboli are the most common causes of acute arterial insufficiency. Thrombosis may be accompanied by sudden onset of pain and eventually paresthesia and paralysis; alternatively, arterial insufficiency may be accompanied by intermittent claudication that worsens, leading to pain when at rest or to ischemic ulcerations.

Intravenous streptokinase therapy for peripheral arterial occlusions was first used in 1959.⁸² In the 1960s and early 1970s, many investigators used intravenous streptokinase^{83–85}; however, the rate of successful thrombolysis was only 55%. Bleeding complications were com-

mon; in one series, death occurred in 7% of patients.⁸³ Because of these poor early results, thrombolytic therapy was suggested for use only in patients who were poor surgical candidates.⁸⁶

Several reports in the 1960s described intra-arterial administration of streptokinase for acute arterial occlusions.^{87–89} The technique was modified in 1974 such that the tip of the catheter was placed just above or into the clot.⁹⁰ Streptokinase was infused at 1,000–10,000 IU/h for a period ranging from one day to two weeks. Fifty-nine percent of patients had total or partial clot lysis, and major bleeding occurred in 12%.⁹⁰

The intra-arterial technique was further modified by McNamara and Fischer.⁹¹ In this technique, a 5-F end-hole catheter is inserted retrograde into the contralateral femoral artery (when treating iliac or common femoral disease) or antegrade into the ipsilateral artery (when treating more distal disease). The guide wire is advanced as far into the clot as possible, and the 5-F catheter is advanced over the guide wire several centimeters into the clot (*Figure 4*). The guide wire is then removed, and the thrombolytic agent is infused directly into the clot. The usual dosage is 5,000–10,000 IU/h of streptokinase or 4,000 IU/min of urokinase until initial recanalization occurs; thereafter, 1,000 IU/min of urokinase is given until complete lysis or no further lysis occurs. The dosage of tissue plasminogen activator (t-PA) in experimental protocols has been 0.05–0.1 mg/kg/h.

Concomitant heparin administration at 1,000 IU/h is advocated by McNamara and Fischer⁹¹ in order to decrease the incidence of pericatheter thrombus formation. An effective alternative in many cases is to use a high flow rate through the intra-arterial catheter, producing reflux of the thrombolytic agent around the

From the Department of Peripheral Vascular Disease, The Cleveland Clinic Foundation. Submitted June 1988; accepted Oct 1988.

Address reprint requests to J.W.O., Department of Peripheral Vascular Disease, The Cleveland Clinic Foundation, One Clinic Center, 9500 Euclid Avenue, Cleveland, Ohio 44195.

catheter.

A pooled analysis of the use of streptokinase, urokinase, and t-PA in treating peripheral arterial occlusions is shown in *Table 2*. The rate of thrombolysis is substantially greater with either urokinase or t-PA than with streptokinase. Similarly, bleeding complications occur more frequently in patients given streptokinase than in patients treated with urokinase or with t-PA. Furthermore, in our experience, low-grade fever developed in 42% of patients receiving streptokinase; in 14% of patients, other minor reactions developed including nausea, vomiting, and mild decreases in systolic blood pressure.¹⁰¹

The largest published series using urokinase to treat peripheral arterial occlusions is that of McNamara and Fischer.⁹¹ Eighty-five patients representing 93 occlusions were treated with urokinase (1,000–4,000 IU/h) and heparin (1,000 IU/h). Sixty-one patients had recanalization within two hours; all these patients had complete clot lysis ($P < .01$), whereas complete clot lysis occurred in 39% of patients who did not have recanalization within two hours ($P < .025$). In all cases, advance of the guide wire through the entire length of the occlusion indicated a soft thrombus and predicted successful clot lysis. Percutaneous transluminal angioplasty was performed in 78% of patients (after urokinase infusion) to correct the problem that caused the arterial occlusion. Only 6.5% of patients had major bleeding complications. After six months, patency had been maintained in 59% of patients who had successful lysis.¹⁰⁷ Factors predicting long-term patency included size of vessel and whether a critical stenosis remained after thrombolysis.

Three retrospective series^{102–104} have compared intra-arterial streptokinase therapy and urokinase therapy. In these series, clot lysis occurred in 80% of patients receiving urokinase as compared with 52% of patients receiving streptokinase. The complication rate was also substantially higher in the group receiving streptokinase.

T-PA

We previously described 55 patients with native peripheral arterial occlusions or bypass graft thrombosis who received human recombinant t-PA at a dosage of 0.05–0.1 mg/kg/h.^{105,106} The t-PA was infused continuously into the clot for a mean of 4.7 hours (range, 1–8 hrs). Thrombolysis occurred in 51 patients (93%), major complications occurred in four patients (7.2%), and one patient already receiving heparin anticoagulation therapy had an intracranial hemorrhage 48 hours after being given t-PA. After thrombolysis, surgery or percutaneous

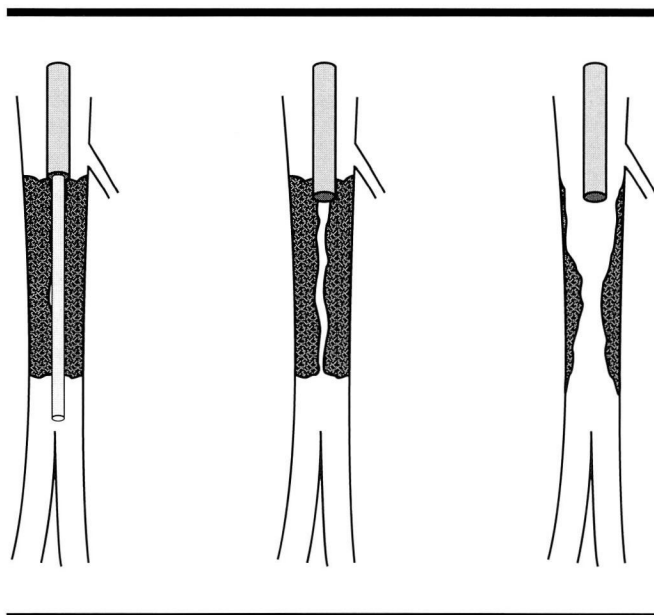


FIGURE 4. Intra-arterial technique for thrombolytic infusion therapy. Guide wire is passed through thrombus (left). Infusion catheter is passed into thrombus, and guide wire is removed (middle). Infusion is complete (right).

transluminal angioplasty was done in 57% of patients, and 31% required long-term anticoagulation. Thus, thrombolysis often uncovered anatomic lesions (residual arterial stenosis) which, if not properly treated, would lead to rethrombosis of the native artery or of the bypass graft.

In a recent study,¹⁰⁸ 22 patients who received t-PA for thrombosis of an infrainguinal extremity bypass graft were matched with a group of 38 patients who had primary surgical thrombectomy. Patients were identical to one another with regard to age, presence or absence of diabetes, smoking, and type of graft used. T-PA lysed thrombus in 100% of patients. Mean duration of graft patency was 231 ± 211 days in patients receiving t-PA as compared with 136 ± 254 days in patients who had primary surgery ($P = .01$). Secondary procedures (surgery or percutaneous transluminal angioplasty) were done in 20 (92%) of 22 patients receiving t-PA. The relative risk of amputation was 2.97 times that in patients receiving primary surgical repair compared to patients receiving t-PA. Eighty-six percent of grafts remained patent at 30 days in patients receiving t-PA, compared with 42% in patients receiving surgery ($P = .001$). Unfortunately, the beneficial effects evident in the t-PA group were present only during the first year, after which no differences were seen in graft patency.

TABLE 2
 POOLED ANALYSIS OF STREPTOKINASE, UROKINASE, AND TISSUE PLASMINOGEN ACTIVATOR (t-PA) TO TREAT PERIPHERAL ARTERIAL OCCLUSIONS

Drug/References	No. infusions	Duration of infusion (h)	Successful thrombolysis (%)	Major complications
Streptokinase ^{90,92-104}	474	40	316 (67)	88 (19)
Urokinase ^{91,102-104}	162	30	130 (81)	19 (12)
t-PA ^{105,106}	55	4.7	51 (93)	4 (7.2)

Clearly, thrombolytic therapy should not be used for peripheral arterial occlusions if the patient has substantial sensory or motor impairment of the ischemic limb. This impairment indicates that the ischemia is "limb-threatening," and such a patient may incur irreversible damage after only a few more hours of ischemia. In this situation, surgical thrombectomy, embolectomy, or other revascularization is the preferred treatment.

Thrombolysis may not occur when the clot is more than 30 days old, firm, or highly calcified. Thrombi more than 30 days old can be lysed; however, complete clot dissolution generally becomes less likely, the older the clot. Other reasons for failure of thrombolysis include calcified hard atherosclerotic lesions in the thrombus or inability to position the catheter tip directly into the clot. Patients with a high titer of antistreptococcal antibodies may be resistant to treatment with streptokinase.

Thrombolytic agents are useful adjuncts to surgery and to percutaneous transluminal angioplasty. These agents further define the anatomy by restoring flow to the smaller distal runoff vessels and improve short-term graft patency by decreasing outflow resistance.

Intraoperative thrombolysis

Use of intraoperative thrombolytic agents has recently been advocated as an adjunct to surgical revascularization.¹⁰⁹ This practice is generally reserved for patients in whom distal thrombectomy is unfeasible or incomplete. Various techniques can be used, including bolus administration into the distal artery via cutdown or cannulation of the popliteal artery and vein after application of a tourniquet (i.e., regional infusion).

Intra-arterial thrombolytic agents may help to identify the anatomy when native arteries are thrombosed. These agents may allow the surgeon clearer visualization of the distal runoff bed, thereby providing a target for bypass surgery. When a bypass graft becomes occluded, thrombolysis allows clinicians to identify the cause of thrombosis and, consequently, to devise a rational treatment plan. In some situations, the distal anastomosis is stenotic and can be surgically dilated or

revised (Figure 5); in other instances, the entire bypass graft must be replaced. Without thrombolysis, the best mode of therapy may not be evident. Avoiding catheter embolectomy or thrombectomy so as not to disrupt the intima of the vessel wall (and thus accelerate atherosclerosis) may be beneficial.

ARTERIOVENOUS FISTULAS AND GRAFTS

Use of thrombolytic agents has effectively restored flow to thrombosed arteriovenous fistulas and grafts. In an early experience of ours, 45 (71%) of 63 patients had successful thrombolysis with the use of streptokinase. When the thrombus was less than four days old, 40 (87%) of 46 thrombi were lysed, whereas only five (29%) of 17 patients had successful lysis when the thrombus was more than four days old ($P < .001$).¹⁰¹

Our technique is to insert an 18-gauge angiocath into the fistula or graft retrograde toward the arterial anastomosis. The thrombolytic agent is then infused. Many patients must have secondary surgical revision or percutaneous transluminal angioplasty because of stenosis at the anastomotic site.

STROKE

Although thrombolytic therapy has been used aggressively to treat acute myocardial infarction, venous thromboembolism, pulmonary embolism, and peripheral arterial occlusions, the use of these agents in stroke is at a very early stage. One reason for this is the fear of intracranial hemorrhage developing during thrombolytic therapy. The benefits and risks of thrombolytic therapy for stroke were recently reviewed.¹¹⁰ Several ongoing trials are using t-PA in acute stroke; it is too early to know whether this therapy will effectively reverse the signs and symptoms of stroke and whether the risk/benefit ratio is acceptable.

MONITORING THROMBOLYTIC THERAPY

Much controversy surrounds the issue of how thrombolytic therapy should be monitored.¹¹¹ In general, the easiest method of monitoring would be use of thrombin time to establish existence of a lytic state. A lytic state can also be reflected by prothrombin time, by activated

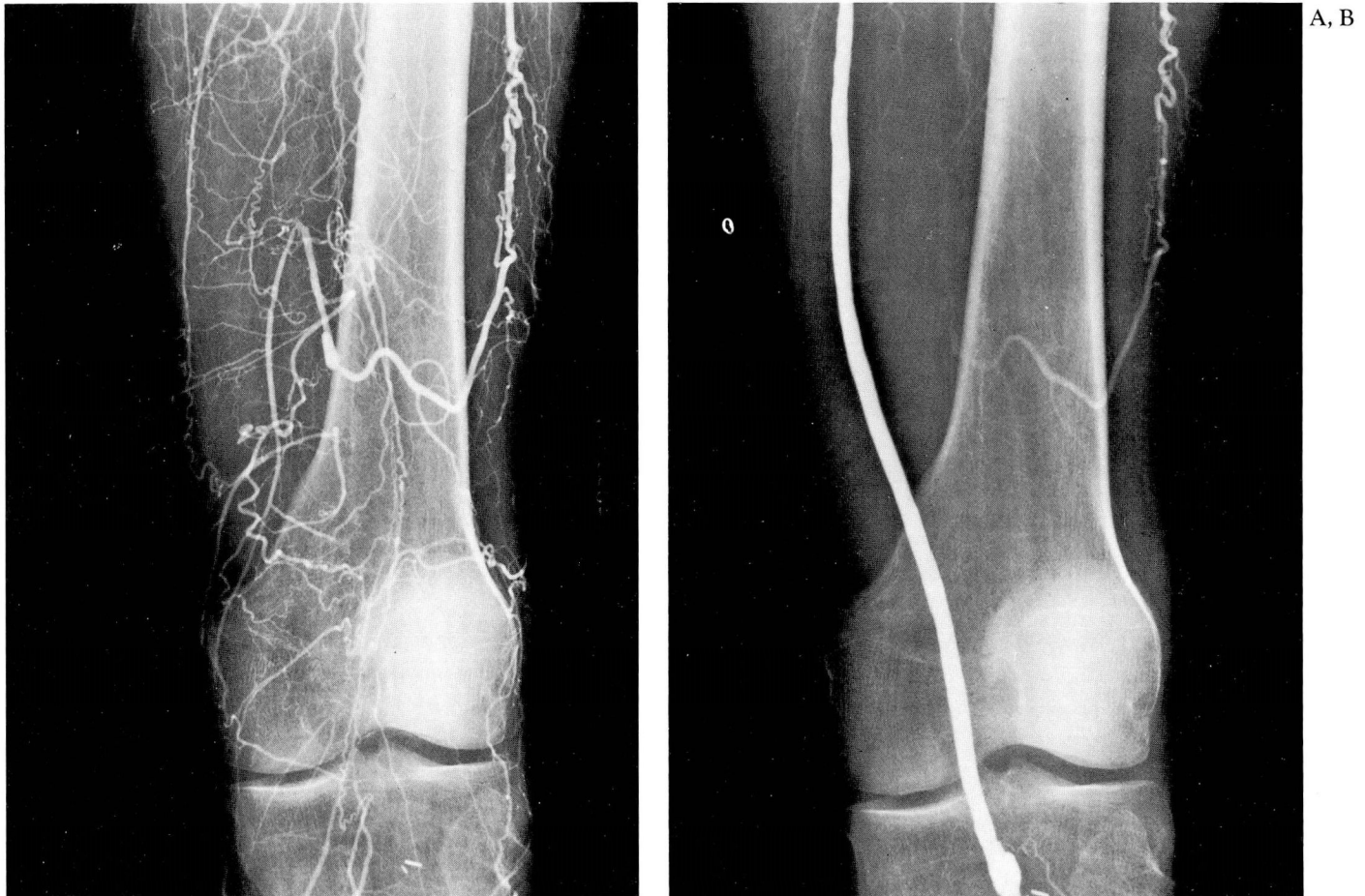

FIGURE 5A. Thrombosis of in situ saphenous-vein femoral-popliteal bypass. Note collateral from profunda femoris and poor distal reconstitution of vessels. FIGURE 5B. Patency of bypass is restored after four hours of t-PA administration. Stenotic distal anastomosis (not shown here) required revision to maintain patency of bypass.

thromboplastin time, or by clotable fibrinogen assay. With the exception of the latter assay, these methods are not very sensitive or specific. Furthermore, laboratory evaluation to establish presence of a lytic state does not indicate clot lysis or herald complications.^{112,113} Laboratory analysis informs the clinician that the intended reaction of plasminogen activator is occurring. To determine whether clot lysis has occurred, the investigator must look for presence of circulating fibrin fragments including D-dimer and B-BETA₁₅₋₄₂ subunits. However, the levels of these fragments are of little value for clinical monitoring. Instead, we generally measure thrombin time, fibrinogen level, and hematocrit twice daily.

If potential bleeding is a concern, the fibrinogen assay may be evaluated to determine whether adequate fibrinogen will be available if bleeding begins. In general, 100–150 mg/dL of fibrinogen is required for hemostasis.

An acceptable fibrinogen level may indicate that adequate fibrinogen is available for hemostasis if bleeding occurs in a compressible area.

COMPLICATIONS OF THROMBOLYSIS

Causes

Complications from thrombolytic agents result from several factors including nonspecific proteolysis, anticoagulant effects, and the thrombolytic effects of these medications. Nonspecific proteolysis occurs after plasmin is formed: various proteins have lysine or arginine binding sites where plasmin can attach and produce its proteolytic effect. These proteins include fibrin in the targeted clot, circulating fibrinogen, and coagulation factors V and VIII as noted earlier.¹¹¹ The anticoagulant effect of thrombolytic agents is created as coagulation

TABLE 3
CONTRAINDICATIONS TO THROMBOLYTIC THERAPY

Absolute	
Active bleeding	
Central nervous system pathology	
Stroke within 6 months	
Intracranial-intraspinal surgery, eye surgery, or trauma within 6 months	
Intracranial neoplasm or aneurysm	
Relative	
Surgery (except lower-extremity vascular surgery) or organ biopsy within 10 days	
Puncture of noncompressible vessels within 10 days	
Recent gastrointestinal bleeding whose cause remains uncorrected	
Severe, uncontrolled hypertension	
Recent trauma (including CPR)	
Infective endocarditis	
Pregnancy and postpartum period	
Hemostatic defects	
Questionable	
Arterial aneurysmal disease	
Knitted Dacron vascular grafts	
Prosthetic devices (cardiac valves, vena cava filter)	
Recent bone-marrow biopsy	
Atheroembolic disease	
Present menstruation	
Left ventricular thrombus	

factors and fibrinogen become depleted and fibrin/fibrinogen degradation products are generated: degradation products of fibrin and of fibrinogen may act as circulating anticoagulants. Of further significance to potential bleeding associated with thrombolytic therapy is the fact that pathologic thrombi and physiologic thrombi are lysed by plasmin, causing most bleeding to occur at sites of previous vascular invasion (e.g., needle puncture sites).

Contraindications

The absolute and relative contraindications for use of thrombolytic agents are shown in *Table 3*. Thrombolytic agents should be used only if the benefits of a successful outcome outweigh potential risks.

No therapeutic agent free of complications has been identified. Therefore, it is safe to say that if a drug has proven efficacy, it probably has associated potential complications. Furthermore, in patients receiving thrombolytic agents, it is difficult to evaluate whether a complication is a result of the drug itself, a result of the invasive procedure (e.g., angiography) needed to plan therapy, or a result of lost vascular integrity (e.g., in puncture of the vessel wall or in stroke). Retroperitoneal and intracranial bleeding may occur without known prior vascular defects and without apparent iatrogenic

cause. Meticulous care must be taken during procedures in patients receiving either anticoagulants or thrombolytic agents.

Bleeding

Attempts to identify thrombolytic dosages not accompanied by substantially lowered fibrinogen levels or altered coagulation profile have been elusive. Data acquired in several computer-assisted pharmacodynamic studies¹¹⁴⁻¹¹⁶ show that depletion of alpha-2 antiplasmin precedes decrease in fibrinogen levels. Freely circulating plasmin may then more effectively degrade fibrinogen and theoretically may place the patient at higher risk for clinically significant bleeding.

As a result of the aforementioned changes in the coagulation and fibrinolytic systems, bleeding is the major side effect of thrombolytic therapy and is probably the main hindrance to acceptance of this therapy. The problem of bleeding was addressed during the urokinase/streptokinase pulmonary embolism trials, wherein investigators found that aside from bleeding at sites of invasive procedures during therapy, complications were unusual.¹¹⁷

Bleeding at catheter entry sites (when the catheter was used for treatment of arterial and myocardial infarction) is the most common complication seen in patients treated with thrombolytic agents. Regardless of severity of the induced coagulopathy, fewer bleeding complications of lytic therapy will result for patients who have complete vascular integrity. Bleeding complications due to the trauma of invasive procedures can be minimized by limiting the number and frequency of arterial and venous punctures. Risk of puncture-site bleeding can be minimized by limiting manipulation of the catheter and by keeping the extremity immobile while the catheter is in place. The standard Seldinger technique of arterial catheterization should be modified such that, whenever possible, only the superficial wall of the artery is punctured. Eliminating the posterior-wall puncture can reduce hematoma formation at the puncture site. Direct pressure can usually control bleeding at the catheter entrance site.

Intra-arterial catheterization is almost always used in patients receiving thrombolytic agents for peripheral arterial occlusion. Bleeding at the catheter entry site occurs in 0-45% of patients in whom intra-arterial catheterization is used. The lower frequency of bleeding complications occurring when urokinase or t-PA is used has only recently been noted. Streptokinase accounted for the highest rate of bleeding complications noted in these series (*Tables 1* [in part 1] and 2).

A study by Tennant et al¹¹⁸ compared bleeding frequency in patients receiving urokinase and patients receiving streptokinase within six hours after acute myocardial infarction. The incidence of hemorrhagic complications with urokinase use was 11%; for streptokinase, 29%. Incidence of major complications requiring cessation of drug therapy and acute intervention to prevent bleeding was 2% for urokinase and 20% for streptokinase. Fibrinogen levels under 100 mg/dL were present in 2 (6%) of 34 patients receiving urokinase and in 19 (66%) of 29 patients receiving streptokinase ($P<.001$). A study done at the Cleveland Clinic using thrombolytic therapy for venous thromboembolism also showed a statistically significant difference in major bleeding complications, i.e., no bleeding complications for urokinase and a 17% incidence for streptokinase¹¹⁹ ($P<.01$).

Intracranial bleeding

The most feared complication, intracranial bleeding, has been seen in a small number of patients. Its incidence is low but may vary with individual drugs. Although it is difficult to quantify exactly the percentage of patients who will have intracranial bleeding when given a particular activator, approximately 1%–2% of patients receiving streptokinase appear to have had spontaneous or induced intracranial bleeding. The exact frequency with which this occurs in patients receiving t-PA or urokinase is unknown.

Antigenic reactions

Other complications, including antibody-induced reactions, have been noted. T-PA and urokinase do not appear to induce antibody production and therefore have not been associated with the mild febrile and urticarial reactions that develop after streptokinase, a highly antigenic substance, has been given. Approximately half of patients who receive streptokinase over a period of 24 to 48 hours have adverse antigenic responses. Approximately 10%–40% of patients who receive urokinase or t-PA have nausea and, occasionally, vomiting.^{101,119} It is difficult to determine the extent to which such nonspecific phenomena are caused by these medications and not by other medications (e.g., narcotics) that patients may receive during infusion therapy.

Fragmentation and embolization

Fragmentation and distal embolization during thrombolytic treatment for intra-arterial or deep venous thrombosis is relatively unusual. Conceptually, the risk of pulmonary embolism should not increase in patients

treated for deep venous thrombosis. Because the clot is lysed through absorption of drug onto the surface of the clot, the free edge of the clot should lyse first, with detachment from the endothelial surface occurring last.

Pulmonary emboli develop in some patients despite anticoagulation or thrombolysis. When peripheral arterial infusions are given, distal embolization results from clot fragmentation (i.e., after partial thrombolysis) or from mechanical effects of catheter manipulation or infusion force. Most often these events remain clinically silent. Patients who have clinical manifestations or angiographic findings of distal embolic occlusions respond well to continued lytic therapy.^{105,106}

Catheter-induced thrombosis

Catheter-induced thrombosis has not been common in our patients and usually occurred when the catheter was placed in a long segment of artery that had poor outflow. This stagnant column of blood may become thrombotic unless the activator is infused in a volume adequate to cause significant reflux flow or concurrent heparin therapy is given.

SUMMARY

Thrombolytic therapy has effectively increased survival and has salvaged myocardium in patients who have acute myocardial infarction. Use of this therapy has broadened to patients who have venous thromboembolic disease, occlusions of peripheral arteries and bypass grafts, and arteriovenous fistulas and grafts. Thrombolytic agents have recently been used to treat acute stroke.

In the last 20 years, enormous advances have been made in understanding thrombus formation and thrombolysis. Three agents are currently FDA-approved for use, and more are on the horizon. As experience with these agents increases and thrombolytic agents become more effective and safer, the use of thrombolysis will increase. However, prospective randomized double-blind trials must first be performed comparing streptokinase, urokinase, and t-PA with standard surgical approaches and percutaneous transluminal angioplasty. Only by performing these studies can we define the safest and most effective regimen for particular diseases.

ACKNOWLEDGMENT

We wish to thank Micheline Watt for secretarial assistance in the preparation of this manuscript.

REFERENCES

82. Fletcher AP, Sherry S, Alkjaersig N, Smyrniotis FE, Jick S. The maintenance of a sustained thrombolytic state in man. II. Clinical observations on patients with myocardial infarction and other thromboembolic disorders. *J Clin Invest* 1959; **38**:1111-1119.
83. Amery A, Deloof W, Vermynen J, Verstraete M. Outcome of recent thromboembolic occlusions of limb arteries treated with streptokinase. *Br Med J* 1970; **4**:639-644.
84. Poliwoda H, Alexander K, Buhl V, et al. Treatment of chronic arterial occlusions with streptokinase. *N Engl J Med* 1969; **280**:689-692.
85. Martin M. Thrombolytic therapy in arterial thromboembolism. *Prog Cardiovasc Dis* 1979; **21**:351-374.
86. Fratantoni JC, Ness P, Simon TL. Thrombolytic therapy: current status. *N Engl J Med* 1975; **293**:1073-1078.
87. Clark MC, Howell M, Hawkey C, et al. Arterial occlusions treated with streptokinase. *Postgrad Med J* 1965; **41**:96-100.
88. Hirsh J, O'Sullivan EF, Gallus A, et al. Thrombosis in a patient with chronic thrombocytopenia: successful treatment with intra-arterial infusion of streptokinase. *Med J Aust* 1969; **2**:1304-1306.
89. McNicol GP, Douglas AS. Treatment of peripheral vascular occlusion by streptokinase perfusion. *Scand J Clin Lab Invest* 1964; **16**(suppl 78):23-29.
90. Dotter CT, Röscher I, Seaman AJ. Selective clot lysis with low-dose streptokinase. *Radiology* 1974; **111**:31-37.
91. McNamara TO, Fischer JR. Thrombolysis of peripheral arterial and graft occlusions: improved results using high-dose urokinase. *AJR* 1985; **144**:769-775.
92. Katzen BT, van Breda A. Low dose streptokinase in the treatment of arterial occlusions. *AJR* 1981; **136**:1171-1178.
93. Totty WG, Gilula LA, McClennan BL, Ahmed P, Sherman L. Low-dose intravascular fibrinolytic therapy. *Radiology* 1982; **143**:59-69.
94. Berni GA, Bandyk DF, Zierler RE, Thiele BL. Streptokinase treatment of acute arterial occlusion. *Ann Surg* 1983; **198**:185-191.
95. Mori KW, Bookstein JJ, Heeney DJ, et al. Selective streptokinase infusion: clinical and laboratory correlates. *Radiology* 1983; **148**:677-682.
96. Becker GJ, Rabe FE, Richmond BD, et al. Low-dose fibrinolytic therapy: results and new concepts. *Radiology* 1983; **148**:663-670.
97. Katzen BT, Edwards KC, Albert AS, van Breda A. Low-dose direct fibrinolysis in peripheral vascular disease. *J Vasc Surg* 1984; **1**:718-722.
98. Wolfson RH, Kumpe DA, Rutherford RB. Role of intra-arterial streptokinase in treatment of arterial thromboembolism. *Arch Surg* 1984; **119**:697-702.
99. Van Breda A, Robison IC, Feldman L, et al. Local thrombolysis in the treatment of arterial graft occlusions. *J Vasc Surg* 1984; **1**:103-112.
100. Kakkasseril JS, Cranley JJ, Arbaugh JJ, Roedersheimer LR, Welling RE. Efficacy of low-dose streptokinase in acute arterial occlusion and graft thrombosis. *Arch Surg* 1985; **120**:427-429.
101. Graor RA, Risius B, Denny KM, et al. Local thrombolysis in the treatment of thrombosed arteries, bypass grafts, and arteriovenous fistulas. *J Vasc Surg* 1985; **2**:406-414.
102. Belkin ML, Belkin B, Bucknam CA, Straub JJ, Lowe R. Intraarterial fibrinolytic therapy. Efficacy of streptokinase vs urokinase. *Arch Surg* 1986; **121**:769-773.
103. Van Breda A, Katzen BT, Deutsch AF. Urokinase versus streptokinase in local thrombolysis. *Radiology* 1987; **165**:109-111.
104. Koltun WA, Gardiner GA Jr, Harrington DP, Couch NP, Mannick JA, Whittemore AD. Thrombolysis in the treatment of peripheral arterial vascular occlusions. *Arch Surg* 1987; **122**:901-905.
105. Graor RA, Risius B, Lucas FV, et al. Thrombolysis with recombinant human tissue-type plasminogen activator in patients with peripheral artery and bypass graft occlusions. *Circulation* 1986; **74**(suppl):115-120.
106. Graor RA, Risius B. Thrombolysis with recombinant human tissue-type plasminogen activator in patients with peripheral artery and bypass graft thrombosis. [In] Sobel BE, Collen D, Grossbard EB, eds. *Tissue Plasminogen Activator in Thrombolytic Therapy*. New York, Marcel Dekker, 1987, pp 171-204.
107. McNamara TO, Bomberger RA. Factors affecting initial and 6 month patency rates after intraarterial thrombolysis with high dose urokinase. *Am J Surg* 1986; **152**:709-712.
108. Graor RA, Risius B, Young JR, et al. Thrombolysis of peripheral arterial bypass grafts: surgical thrombectomy compared with thrombolysis. A preliminary report. *J Vasc Surg* 1988; **7**:347-355.
109. Comerata AJ. Intra-arterial thrombolytic therapy. [In] Comerata AJ. *Thrombolytic Therapy*. Orlando, Grune & Stratton, 1988.
110. Del Zoppo GJ, Zeumer H, Harker LA. Thrombolytic therapy in stroke: possibilities and hazards. *Stroke* 1986; **17**:595-607.
111. Shafer KE, Santoro SA, Sobel BE, Jaffe AS. Monitoring activity of fibrinolytic agents: a therapeutic challenge. *Am J Med* 1984; **76**:879-886.
112. Elliot MS, Immelman EJ, Jeffery P, et al. A comparative randomized trial of heparin versus streptokinase in the treatment of acute proximal venous thrombosis: an interim report of a prospective trial. *Br J Surg* 1979; **66**:838-843.
113. O'Donnell TF Jr, Browse NL, Burnand KG, Lea Thomas M. The socioeconomic effects of an iliofemoral venous thrombosis. *J Surg Res* 1977; **22**:483-488.
114. Chmielewska J, Ranby M, Wiman B. Evidence for a rapid inhibitor of tissue plasminogen activator in plasma. *Thromb Res* 1983; **31**:427.
115. Tiefenbrunn AJ, Graor RA, Robison AK, Lucas FV, Hotchkiss A, Sobel BE. Pharmacodynamics of tissue-type plasminogen activator characterized by computer-assisted simulation. *Circulation* 1986; **73**:1291-1299.
116. Sobel BE, Gross RW, Robison AK. Thrombolysis, clot selectivity, and kinetics. *Circulation* 1984; **70**:160-164.
117. Urokinase-Streptokinase Pulmonary Embolism Trial. Phase 2 results. *JAMA* 1974; **229**:1606-1613.
118. Tennant SN, Dixon I, Venable TC, et al. Intracoronary thrombolysis in patients with acute myocardial infarction: comparison of the efficacy of urokinase with streptokinase. *Circulation* 1984; **69**:756-760.
119. Graor RA, Young JR, Risius B, et al. Comparison of cost effectiveness of streptokinase and urokinase in the treatment of deep vein thrombosis. *Ann Vasc Surg* 1987; **1**:524-528.