



MELINDA L. ESTES, MD, EDITOR

## A 29-year-old renal transplant patient with multiple brain lesions

MELINDA L. ESTES, MD; RICHARD A. RUDICK, MD; T. EDGAR HUANG, MD; MARK RORICK, MD; SCOTT A. ROSENBLOOM, MD

### CASE PRESENTATION

A renal transplant patient, a 29-year-old right-handed man, was admitted to the Cleveland Clinic in February 1987, with a history of progressive right-sided weakness and inability to walk. Magnetic resonance imaging scans showed multiple brain lesions.

The patient's medical history was significant, including transphenoidal pituitary ablation five years previously and juvenile-onset, insulin-dependent diabetes mellitus from age eight, with subsequent retinopathy and end-stage renal disease. For 20 months beginning in February 1985, the patient underwent hemodialysis.

He received a cadaveric renal transplant in late October 1986. His immediate postoperative course was unremarkable, and he was treated with standard immunosuppressive therapy: cyclosporine A (500 mg), azathioprine (50 mg), and prednisone (20 mg) (total daily doses). One month after the operation, he was admitted with fever and decreased renal function. Results of a renal biopsy revealed acute cellular rejection. His renal function improved after treatment with intravenous methylprednisolone for three days and OKT3 for seven days, in addition to his regular immunosuppressive therapy. No cause for a transient fever was determined, and he was discharged. Over the next two

months, he was treated with oral nystatin and hydrogen peroxide for oral candidiasis and suspected esophageal candidiasis.

In January 1987, he was evaluated for severe leukopenia (WBC, 1,200/ $\mu$ L). Results of a bone marrow biopsy showed hypocellularity, with decreased granulopoiesis and left shift. Drug-induced leukopenia was suspected, and azathioprine, sulfathiazole-trimethoprim, and ranitidine were discontinued. His leukopenia resolved. He continued taking cyclosporine (220 mg every 12 hr) and prednisone (15 mg each day).

The gradual onset of right-sided weakness was noted two weeks prior to admission. He was hospitalized briefly in January 1987 for removal of four impacted wisdom teeth. Postoperatively, he had a swollen maxilla, but was not febrile and had no evidence of infection.

The patient had felt "weakness" during his hospitalization for the dental procedure; however, his physicians had not observed focal weakness. Since being discharged after his dental procedure, his weakness progressed. His balance was poor. He was falling to the right and required a cane to walk. He was unable to write with his right hand. Over the same time, he noted episodic difficulty talking and some memory loss. He also experienced dizziness and mild headache. He denied fever, chills, nausea or vomiting, loss of vision, or paresthesia.

### Physical examination

On admission, his temperature was 37° C; pulse, 84 bpm; respiration, 18; blood pressure, 118/70 mmHg; and weight, 54 kg. He was pale but in no acute distress. No skin lesions were noted. There was no adenopathy. Ear drums were normal. Sinus tenderness or oral thrush was not evident. The neck was supple. Carotid pulses were

From the Departments of Pathology (M.L.E., T.E.H.), Neurology (R.A.R., M.R.), and Radiology (S.A.R.), The Cleveland Clinic Foundation. Submitted for publication April 1988; accepted Oct 1988.

Address reprint requests to M.L.E., Department of Pathology, The Cleveland Clinic Foundation, One Clinic Center, 9500 Euclid Avenue, Cleveland, Ohio 44195.

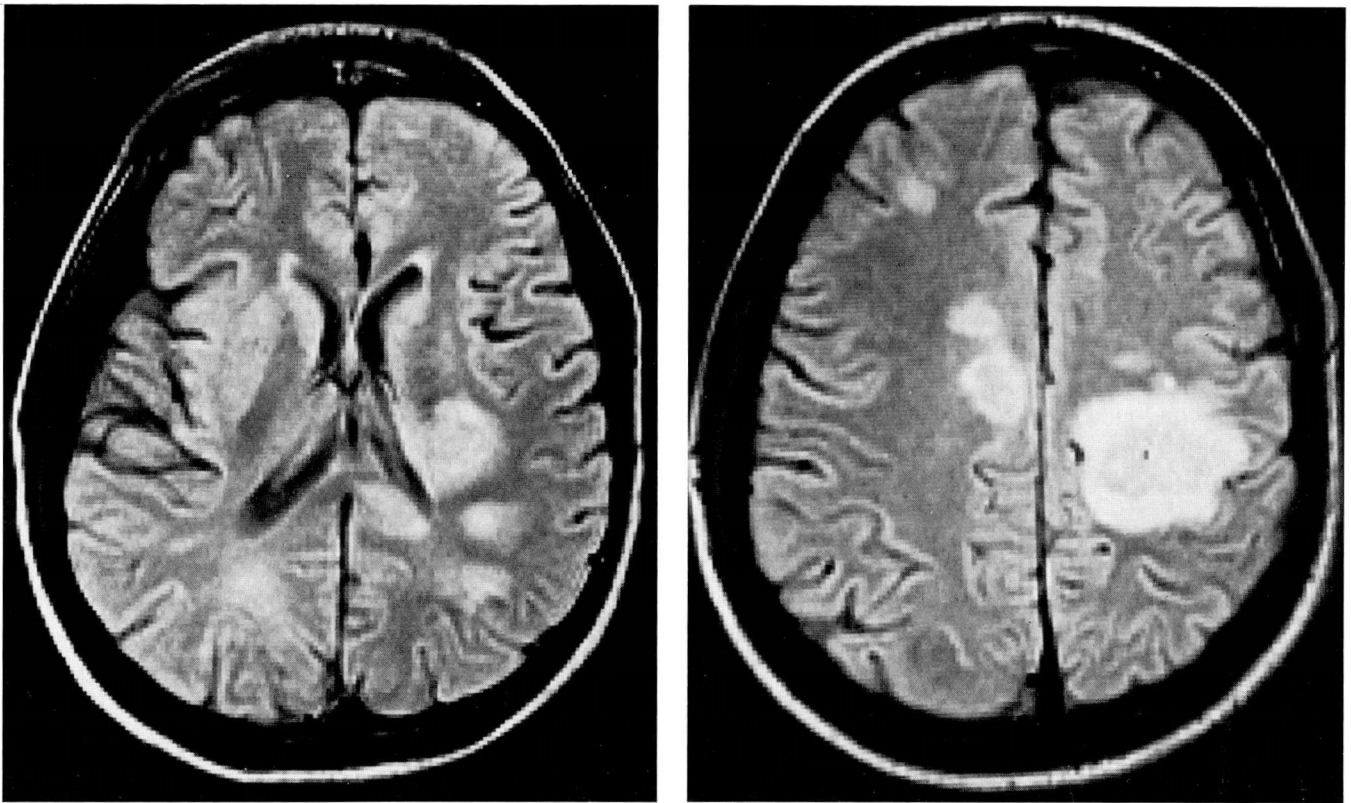


FIGURE 1A. MR image shows multiple hemispheric lesions with surrounding edema. FIGURE 1B. MR image shows bilateral hemispheric lesions of the white matter.

normal, without bruits. Lungs were clear. The cardiac examination revealed a grade II systolic ejection murmur. His abdomen and extremities were normal. Neurologically, he was alert and oriented. He had word-finding difficulty, but was able to read. Repetition and memory were intact. Pupils were 3 mm, equal, and reactive to light. Extraocular movements were full, with bilateral horizontal and rotary nystagmus on lateral gaze. Facial sensation and corneal reflexes were intact. A widened palpebral fissure was present on the right. The motor examination revealed mild hemiparesis of the right extremities, with increased tone and resting tremor. Reflexes were increased on the right without a Hoffman's sign or clonus: 3+/3 biceps, 3+/3 brachioradialis, 3+/2 triceps, 4+/4+ quadriceps, and 2+/2 gastrocnemius. A right Babinski sign was noted. Cerebellar function was intact.

#### Laboratory studies

Laboratory studies disclosed the following values: WBC, 9,100/ $\mu$ L, with 76% neutrophils, 4% bands, 13% lymphocytes, 4% monocytes, and 2% eosinophils; he-

matocrit, 29.3%; platelets, 398,000/ $\mu$ L; sodium, 140 mg/100 mL; potassium, 4.6 mg/100 mL; chloride, 100 mg/100 mL; bicarbonate, 27 mg/100 mL; glucose, 132 mg/100 mL; BUN, 39 mg/100 mL; and creatinine, 2.0 mg/100 mL. The rest of the blood chemistry studies, prothrombin time, and partial thromboplastin time were normal. Urinalysis showed positive glucose reaction. The chest radiograph obtained on admission was normal. A CT head scan, also obtained on admission, revealed bilateral hemispheric lesions. One day after admission, a CT-guided needle brain biopsy yielded insufficient tissue for diagnosis. Eight days after admission, a second surgical procedure was performed.

#### CLINICAL DISCUSSION

*Dr. Scott A. Rosenbloom:* Axial spin-density MR images of the brain show multiple foci of increased signal bilaterally, involving primarily the white matter (Figure 1). There is some surrounding vasogenic edema associated with several of these lesions, but only minimal mass effect is present.

*Dr. Richard A. Rudick:* In summary, this patient experienced a three-week progressive neurologic illness dominated by focal symptoms referable to a left hemispheric lesion. He had multicentric parenchymal mass lesions seen by CT scan, which enhanced strongly after intravenous administration of contrast agent. He presumably underwent open brain biopsy for definitive diagnosis after a needle biopsy failed to yield adequate tissue for diagnosis.

When considering the diagnostic possibilities and choosing from them the likely diagnosis, one must consider several aspects of the illness that provide clues. First, the course of this man's illness was one of subacute progression. This type of course is seen most commonly in infections, tumors, and in some types of inflammatory diseases. Second, the features on neurologic examination and brain imaging all suggest that the process in this instance was a multicentric CNS parenchymal one, further narrowing the likely diagnoses.

The clinical setting is critically important in this case: multifactorial immunosuppression, principally affecting cell-mediated immunity. He had juvenile-onset diabetes. He was a recent renal transplant recipient. He had been on corticosteroids, cyclosporine, and anti-T3 monoclonal antibody therapy. He had recently been leukopenic. Corticosteroids have long been known to suppress cell-mediated immunity, rendering most patients anergic. Steroid recipients have an increased incidence of bacterial infections and reactivation of latent infections, such as tuberculosis. Azathioprine seems to preferentially affect natural killer cells and parent subpopulations bearing antigen Leu11.<sup>1</sup> Cyclosporine selectively inhibits T-cell effector systems. It inhibits interleukin-2 production and consequently inhibits T-cell proliferation.<sup>2</sup> Monoclonal antibody treatment with anti-T3 antibody results in selective T-cell functional ablation, at least temporarily. In aggregate, this man's CNS lesions occurred in the face of profound suppression of cellular immunity. Although the list of disorders that result in multicentric parenchymal lesions is long, the combination of clinical course, neurologic features, and clinical setting suggests he suffered from an intracranial infection or tumor.

Several conditions can be dismissed quickly but should be considered since they can present with a subacute course and/or multiple parenchymal lesions. Large-vessel atherosclerotic cerebrovascular disease is more common in diabetics and in patients with chronic renal failure, but neither the course nor the distribution of lesions suggest this diagnosis. There does not appear to be evidence of systemic vasculitis and although one

cannot rule out granulomatous vasculitis confined to the CNS, this seems unlikely in view of the patient's age, lack of severe headache, and lack of encephalopathic features. Finally, the demyelinating diseases, multiple sclerosis, adrenoleukodystrophy, and adult-onset metachromatic leukodystrophy, each have characteristic features that were lacking in this patient.

Thus, the differential diagnosis appears to rest between infectious diseases and brain tumors.

Tumors affecting the brain parenchyma in a multicentric fashion include metastatic carcinoma, malignant melanoma, and lymphoma, among others. Brain lymphoma is a particularly common pathological entity in patients with immune deficiency states of all types.

Brain lymphoma has been reported in renal transplant recipients and in various other conditions characterized by immunodeficiency.<sup>3</sup> Primary CNS lymphoma has been reported as a common phenomenon in patients with acquired immune deficiency syndrome (AIDS).<sup>4</sup> In the face of systemic lymphoma, parenchymal involvement usually results from extension from leptomeninges. In the face of immunosuppression, however, this tumor may present as multicentric parenchymal lesions. The diagnosis is based on histopathologic features, so that diagnosis of primary CNS lymphoma cannot be made with confidence based on this man's clinical features.

Infections of various sorts should be seriously considered in this patient. Multicentric bacterial brain abscesses are unlikely here, since they usually occur in the setting of an obvious source of bacteremia or sepsis, such as bacterial endocarditis or intra-abdominal abscess. Furthermore, patients with bilateral parenchymal brain abscesses generally appear in toxic condition and encephalopathic, although patients with unicentric brain abscess may not show systemic signs of infection.

Fungal infections, for example *Candida*, *Aspergillus*, or *Histoplasma* infection, should be considered in any immunosuppressed patient with multiple brain lesions. Most such patients present with systemic evidence for pulmonary or other systemic infection, with delirium, fever, and seizures. Fungal infection seems unlikely.

Several opportunistic infections need serious consideration. First, cerebral toxoplasmosis is a distinct possibility here. *Toxoplasma gondii* is an obligate intracellular parasite, which is a common but benign human pathogen usually causing an inapparent or subclinical infection. In the presence of immunosuppression, however, a fulminant neurologic disease may occur.

The illness usually presents in an immunosuppressed patient with multifocal brain lesions that characteristically exhibit ring-enhancement following intravenous

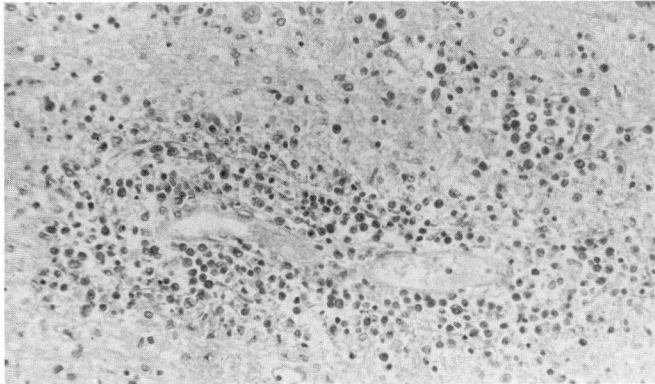


FIGURE 2. Hematoxylin-eosin-stained section of cerebral white matter shows perivascular distribution of abnormal lymphoid cells (×200).

contrast enhancement. Clinically, the illness may present with an encephalitis syndrome, but often presents in individual patients with focal neurologic syndromes. The diagnosis can be made presumptively on the basis of a characteristic clinical setting, enhancing focal lesions on CT scan, and a high toxoplasma IgG antibody titer. It should be emphasized, however, that some immunosuppressed patients with cerebral toxoplasmosis do not have high levels of toxoplasma antibodies.<sup>5</sup> Treatment with pyrimethamine and sulfonamides may result in rapid clinical and radiographic resolution, further supporting a presumptive diagnosis. Definitive diagnosis requires the presence of characteristic neuropathologic features. This diagnosis appears likely on the basis of a clinical setting of immunosuppression and the neurological and radiographic features.

The most common cause of parenchymal brain infection caused by a virus is herpes simplex, which most commonly occurs sporadically in otherwise healthy individuals, and presents clinically as encephalitis and radiographically as a temporal lobe mass. This patient has neither. Various other neurotropic viruses present ordinarily as meningitides.

Other neurotropic viruses appear to be pathogenic only in patients with immunosuppression. Prominent among them is the JC strain of human papovavirus, the etiologic agent in progressive multifocal leukoencephalopathy. Papovaviruses, particularly the JC strain, represent a conceptually important category of viral brain infection. This virus is ubiquitous in nature, and most Americans have serum antibody, suggesting subclinical infection with the virus. The virus has been recovered from cadaveric renal tissue, suggesting the possibility that it remains latent in kidney. The mechanism of

reactivation is unclear, but in the setting of immunosuppression, patients present with rapidly progressive multicentric white matter lesions, hence the name "progressive multifocal leukoencephalopathy."

The illness has been observed in patients with lymphoproliferative and myeloproliferative tumors, with granulomatous diseases, in the face of pharmacologic immunosuppression, in patients with autoimmune diseases, and in AIDS patients. In the latter condition, papovaviruses appear to be a significant pathogen.<sup>4,6</sup> Patients present with altered mental function, visual disturbance, motor weakness, and cerebellar syndromes. The CT scan shows multiple lucent areas in the hemispheric white matter. The lesions tend to have ragged borders and usually do not enhance after contrast material administration. This reflects the noninflammatory nature of the pathologic process. The disease is relentlessly progressive; 70% of patients die within six months of onset. The diagnosis is made on the basis of immunohistochemical analysis of brain tissue.

It seems most likely that this man suffered from an opportunistic infection or a tumor associated with multifactorial immunosuppression. The most likely infectious agent is *T gondii*, based on clinical and radiographic features. The other principal diagnostic possibility is multicentric brain lymphoma, but this seems less likely because of the multiplicity of lesions and rapidity of the clinical course.

I think the procedure was an open brain biopsy, and the pathologic features most likely those of cerebral toxoplasmosis.

---

#### PATHOLOGICAL DISCUSSION

---

*Dr. T. Edgar Huang:* This case is an example of a primary CNS lymphoma arising on the background of immunosuppression, renal transplantation, and systemic chemotherapy. The second brain biopsy showed a diffuse infiltration of atypical lymphoid cells in both cortex and white matter, with tight perivascular cuffs and concentric reticulin proliferation (*Figure 2*). The neoplastic cells extended centrifugally, decreasing in density at the periphery. Only scattered neoplastic cells were seen at the advancing tumor edge, admixed with reactive astrocytes. Immunohistochemical staining for lymphocytic markers showed the neoplastic cells to be positive for CLA, LN1, and LN2, a pattern consistent with B-cell lymphoma.

It may be extremely difficult to make a frozen-section diagnosis of primary CNS lymphoma without clinical information and a high index of suspicion. Microscopic

differential diagnosis includes glial neoplasms (astrocytoma, glioblastoma, pleomorphic oligodendroglioma, ependymoma), metastatic small blue-cell neoplasms (oat-cell carcinoma, neuroblastoma), and viral encephalitis.

There are three common features in primary CNS lymphomas: tight perivascular cuffing by tumor cells, concentric reticulin proliferation, and attendant reactive lymphocytes.<sup>7-10</sup> Several less specific features may be helpful: the presence of scattered reactive astrocytes, individual tumor-cell necrosis, areas of necrosis without peripheral palisading, fibrous thickening of the vascular wall, and secondary subependymal or meningeal spread with desmoplasia. Immunostaining for lymphocyte markers to demonstrate monoclonality is necessary to establish the diagnosis. This requires special tissue handling; communication between the surgeon and the pathologist is crucial.

Primary CNS lymphoma constitutes 0.5% to 2% of intracranial neoplasms.<sup>7-10</sup> Grossly, the tumor often presents as a discrete mass (often multiple), with little or no mass effect or perilesional edema.<sup>7-10</sup> The cut surface of the mass is gray to tan, granular, with necrosis and hemorrhage, and may be discrete from or confluent with adjacent brain. The neoplasm may also cross the corpus callosum in a butterfly-shaped distribution simulating glioblastoma multiforme.<sup>7</sup> When tumor secondarily invades the meninges, discrete nodules are usually formed. This feature is different from diffuse spread seen in meningeal infiltration by a systemic lymphoma.<sup>7</sup>

### Pathogenesis

*Dr. Melinda L. Estes:* The finding of a primary CNS lymphoma in this young man raises three interesting points for discussion:

1. The length of time from transplantation to tumor occurrence,
2. The development of primary CNS lymphoma with the patient's background of immunosuppressive therapy with cyclosporine A, azathioprine, OKT3, and steroids, and
3. The potential role of Epstein-Barr virus (EBV) in the induction of lymphoma.

Development of neoplasm in patients undergoing organ transplantation is well known.<sup>11</sup> The average interval between transplantation and tumor development in patients undergoing conventional immunotherapy is five years. In patients treated with cyclosporine, the average interval for tumor development is two years.<sup>12</sup> Shorter intervals of two<sup>13</sup> and six months<sup>14</sup> have been reported.

Extranodal development of non-Hodgkin's lymphoma is common in transplant patients treated with conventional immunotherapy. However, only 53% of a group of 58 patients with lymphoma following cyclosporine treatment had extranodal involvement by lymphoma.<sup>12</sup> Of the 58 patients in this study, only two had CNS involvement. Many unusual features are seen in lymphoma occurring after transplantation. These include a large percentage of large-cell and immunoblastic lymphomas, as well as frequent confinement of the tumor to the CNS.<sup>15</sup>

The occurrence of primary CNS lymphoma in a renal transplant patient raises the question of the role of EBV infection in tumor induction. EBV genomes have been isolated from primary CNS lymphomas.<sup>16,17</sup> Van Dieën-Steenvoorde et al reported a case in which EBV nuclear antigen was found in tumor cells in a pediatric renal transplant patient without accompanying serologic confirmation of EBV infection.<sup>17</sup> EBV is known to selectively infect B lymphocytes, and in the immunocompetent patient, this proliferation is usually self-limited. However, in an immunosuppressed transplant patient, there is impaired T-cell function and decreased natural killer-cell function, which may allow an EBV-induced B-cell proliferation to proceed unchecked.<sup>18</sup> Our patient shows no serologic evidence for EBV infection (EBV titer, 1:80); however, lymphoma developing in a transplant recipient or other immunosuppressed patient should always raise the suspicion of a recent, persistent, or reactivated EBV infection.

### Treatment

*Dr. Mark Rorick:* The patient was given 4,500 rads (cGy) of whole-brain radiation with a 1,000-rad (1000-cGy) boost to the largest lesion in the left parietal lobe. Subsequent MR studies showed regression in tumor size. He has regained some function of his right extremities but continues to have severe nonfluent aphasia. His renal function has remained stable on low-dose prednisone (5 mg, twice daily).

The mean survival in primary CNS lymphoma without treatment is three months.<sup>19</sup> Surgery is usually limited to subtotal resection or biopsy.

Whole-brain radiotherapy, often with booster doses to the primary tumor, has been the main therapeutic modality. There has been great variability in radiation dosages given to patients, with a range of 2,000 to 6,000 rads (cGy) being utilized.<sup>20-28</sup> After an initial remission, the tumor usually recurs, with a mean survival after radiotherapy of 14 to 15 months and a five-year survival rate of only 4%.<sup>19,25,26</sup> The site of relapse is usually within the

area of previous irradiation, with only 6% failing in the spinal axis.<sup>20</sup> Patients given cranial-spinal radiotherapy have no greater survival than those given only cranial radiotherapy.<sup>23</sup> Elective radiation of the spinal axis therefore is recommended only in cases with clinical involvement or positive CSF cytologic studies.<sup>25</sup>

While chemotherapy has clearly been effective in systemic lymphoma, little information is available concerning its efficacy in CNS lymphoma. Chemotherapeutic agents have been used mainly as an adjuvant to radiotherapy or when relapse occurs after radiotherapy. Most current protocols combine radiotherapy and chemotherapy. A variety of protocols have used steroids, methotrexate, and conventional agents such as vincristine and cytosine arabinoside (Ara-C).

Results of treatment protocols have been presented in a case-report format, with no large series comparing treatment modalities. Steroid treatment alone has been shown to produce dramatic remissions but without long-term survival.<sup>29,30</sup>

Conventional chemotherapeutic agents are not effective due to their inability to traverse the blood-brain barrier. High-dose methotrexate given systemically may penetrate the blood-brain barrier more effectively than other agents. A single reported case had a remission of 12 months after therapy with intravenous methotrexate

and citrovorum rescue given in protocol over an eight-month period.<sup>31</sup> Intra-arterial osmotic blood-brain-barrier modification with mannitol prior to methotrexate was given to 12 patients, with a one-year survival of 75%.<sup>8</sup> Blood-brain-barrier modification to increase drug delivery to tumor tissue is, however, controversial, and interest in this component of therapy has waned. In experimental tumor models, intra-arterial mannitol infusions produced a greater increase in drug concentration (including methotrexate) in normal cortex than in tumor.<sup>32,33</sup> Intrathecal methotrexate has been used to bypass the blood-brain barrier, with variable responses, including a remission of four years in one case.<sup>10,19,34,35</sup>

Development of leukoencephalopathy is a risk of any chemotherapy, especially after initial radiotherapy. Chemotherapeutic treatment of CNS lymphoma remains problematic due to limited experience and failure to demonstrate increased survival without toxicity.

#### Final diagnosis

Malignant large-cell lymphoma, B-cell type.

---

#### ACKNOWLEDGMENT

We wish to thank Mrs. Denise Egleton for preparation of the manuscript.

---

#### REFERENCES

1. Fahey JL, Sarna G, Gale RP, Seeger R. Immune interventions in disease. *Ann Intern Med* 1987; **106**:257-274.
2. Kermani-Arab V, Salehmoghaddam S, Danovitch G, Hirji K, Rezal A. Mediation of the antiproliferative effect of cyclosporine on human lymphocytes by blockade of interleukin 2 biosynthesis. *Transplantation* 1985; **39**:439-442.
3. Penn I. Depressed immunity and the development of cancer. *J Exp Immunol* 1981; **46**:459-474.
4. Snider WD, Simpson DM, Nielsen S, Gold JWM, Metroka CE, Posner JB. Neurological complications of acquired immune deficiency syndrome: analysis of 50 patients. *Ann Neurol* 1983; **14**:403-418.
5. Navia BA, Petito CK, Gold JWM, Cho E-S, Jordan BD, Price RW. Cerebral toxoplasmosis complicating the acquired immune deficiency syndrome: clinical and neuropathological findings in 27 patients. *Ann Neurol* 1986; **19**:224-238.
6. Blum LW, Chambers RA, Schwartzman RJ, Streletz LJ. Progressive multifocal leukoencephalopathy in acquired immune deficiency syndrome. *Arch Neurol* 1985; **42**:137-139.
7. Bonnin JM, Garcia JH. Primary malignant non-Hodgkin's lymphoma of the central nervous system. *Pathol Annu* 1987; **22**:353-375.
8. Neuwelt EA, Frenkel EP, Gumerlock MK, Brazier R, Dana B, Hill SA. Development in the diagnosis and treatment of primary CNS lymphoma: a prospective series. *Cancer* 1986; **58**:1609-1620.
9. Jiddane M, Nicoli F, Diaz P, et al. Intracranial malignant lymphoma: report of 30 cases and review of the literature. *J Neurosurg* 1986; **65**:592-599.
10. Vakili ST, Muller J, Shidnia H, Campbell RL. Primary lymphoma of the central nervous system: a clinicopathologic analysis of 26 cases. *J Surg Oncol* 1986; **33**:95-102.
11. Penn I. Malignancies associated with immunosuppressive or cytotoxic therapy. *Surgery* 1978; **83**:492-502.
12. Penn I. Cancers following cyclosporine therapy. *Transplantation* 1987; **43**:32-35.
13. Case records of the Massachusetts General Hospital (Case 31-1987). *N Engl J Med* 1987; **317**:295-306.
14. Case records of the Massachusetts General Hospital (Case 42-1986). *N Engl J Med* 1986; **315**:1079-1086.
15. Hertel BF, Rosai J, Aranha G. Activation of melanocytic nevi in patients with malignant melanoma (abst). *Lab Invest* 1977; **36**: 340.
16. Hochberg FH, Miller G, Schooley RT, Hirsch MS, Feorino P, Henle W. Central-nervous-system lymphoma related to Epstein-Barr virus. *N Engl J Med* 1983; **309**:745-748.
17. Van Diemen-Steenvoorde R, Donckerwolcke RAMG, Kluin PHM, Kapsenberg JG, et al. Epstein-Barr virus related central nervous system lymphoma in a child after renal transplantation. *Int J Pediatr Nephrol* 1986; **7**:55-58.
18. Hanto DW, Frizzera G, Gajl-Peczalska J, Purtilo DT, et al. The Epstein-Barr virus (EBV) in the pathogenesis posttransplant lymphoma. *Transpl Proceed* 1981; **13**:757-760.
19. Henry JM, Heffner RR Jr, Dillard SH, Earle KM, Davis RL. Primary malignant lymphomas of the central nervous system. *Cancer* 1974; **34**:1293-1302.
20. Murray K, Kun L, Cox J. Primary malignant lymphoma of the central nervous system: results of treatment of 11 cases and review of the literature. *J Neurosurg* 1986; **65**:600-607.
21. Sagerman RH, Collier CH, King GA. Radiation therapy of microgliomas. *Radiology* 1983; **149**:567-570.
22. Di Marco AD, Rosta L, Campostrini F, Bonetti A, Palazzi M, Garusi G. The role of radiation therapy in the management of primary non-Hodgkin's lymphomas of the central nervous system: clinical study of 10 cases. *Tumori* 1986; **72**:565-573.
23. Loeffler JS, Ervin TJ, Mauch P, et al. Primary lymphomas of the central nervous system: patterns of failure and factors that influence survival. *J Clin Oncol* 1985; **3**:490-494.

24. Gonzalez DG, Schuster-Uitterhoeve ALJ. Primary non-Hodgkin's lymphoma of the central nervous system: results of radiotherapy in 15 cases. *Cancer* 1983; **51**:2048-2052.
25. Littman P, Wang CC. Reticulum cell sarcoma of the brain: a review of the literature and a study of 19 cases. *Cancer* 1975; **35**:1412-1420.
26. Berry MP, Simpson WJ. Radiation therapy in the management of primary malignant lymphoma of the brain. *Int J Radiat Oncol Biol Phys* 1981; **7**:55-59.
27. Kawakami Y, Tabuchi K, Ohnishi R, Asari S, Nishimoto A. Primary central nervous system lymphoma. *J Neurosurg* 1985; **62**:522-527.
28. Yasunaga T, Takahashi M, Uozumi H, et al. Radiation therapy of primary malignant lymphoma of the brain. *Acta Radiol (Oncol)* 1986; **25**:23-28.
29. Singh A, Strobos RJ, Rothballer AB, Reddy V, Puljic S, Poon TP. Steroid-induced remissions in CNS lymphoma. *Neurology* 1982; **32**:1267-1271.
30. Todd FD II, Miller CA, Yates AJ, Mervis LJ. Steroid-induced remission in primary malignant lymphoma of the central nervous system. *Surg Neurol* 1986; **26**:79-84.
31. Ervin T, Canellos GP. Successful treatment of recurrent primary central nervous system lymphoma with high-dose methotrexate. *Cancer* 1980; **45**:1556-1557.
32. Heisiger EM, Voorhies R, Basler GA, Lipschutz L, Shapiro WR. Comparison of <sup>14</sup>C methotrexate (<sup>14</sup>C-MTX) delivery of intravenous vs intracarotid (IC) route without or with IC mannitol in experimental rat brain tumors as measured by quantitative autoradiography (QAR)(abst). *Proc Assoc Cancer Res* 1984; **25**:363.
33. Warnke PC, Blasberg RG, Groothuis DR. The effect of hyperosmotic blood-brain barrier disruption on blood-to-tissue transport in ENU-induced gliomas. *Ann Neurol* 1987; **22**:300-305.
34. Herbst KD, Corder MP, Justice GR. Successful therapy with methotrexate of a multicentric mixed lymphoma of the central nervous system. *Cancer* 1976; **38**:1476-1478.
35. Abelson HT, Kufe DW, Skarin AT, et al. Treatment of central nervous system tumors with methotrexate. *Cancer Treat Rep* 1981; **65**(suppl 1):137-140.

