



Atheroembolic renal disease: association with renal arterial stenosis

DONALD G. VIDT, MD; GEORGE EISELE, MD; GORDON N. GEPHARDT, MD; RAYMOND TUBBS, DO; ANDREW C. NOVICK, MD

■ In elderly patients with generalized atherosclerosis and longstanding hypertension, progressive renal insufficiency should suggest renal artery occlusive disease and/or renal cholesterol embolization. Renal cholesterol embolization is not an absolute contraindication to successful surgical revascularization. Renal cholesterol emboli were identified in biopsy specimens obtained in 24 cases at the Cleveland Clinic from 1978 to 1986, and renal artery stenosis was an associated finding in 19. Clinical manifestations of generalized atherosclerosis were common, including ileofemoral atherosclerosis (18), coronary artery disease (16), carotid occlusive disease (15), and carotid occlusive disease with a history of stroke (8). Evidence of embolic events in other organs was common. Hypertension worsened before biopsy in 21 patients with and without renal artery stenosis. Surgery or angiography definitely or probably contributed to renal failure in 16. Of 12 who underwent surgical revascularization of a renal artery, renal function improved in five, remained stable in five, and worsened in one. Renal function improved in the three patients undergoing dialysis before revascularization, and two were able to discontinue dialysis.

□ INDEX TERMS: RENAL ARTERIAL OBSTRUCTION; RENAL ARTERY, DISEASES □ CLEVE CLIN J MED 1988; 56:407-413.

RENAL cholesterol embolization is an often unsuspected cause of renal failure in the elderly. It is frequently fatal, although recent case reports have documented a few survivors.¹⁻³ Renal atheroembolism occurs in the setting of diffuse abdominal atherosclerosis, and a relationship can be established between the severity of the aortic atherosclerosis and the incidence of atheroembolic renal disease. Renal cholesterol emboli will develop in up to 30% of persons

with severe aortic disease, but in only 1% of persons with mild aortic atheromatous disease.⁴⁻⁶ While spontaneous embolization does occur, surgical manipulation of the aorta or diagnostic angiographic procedures have been increasingly recognized as causal events capable of precipitating an episode.⁷⁻¹¹

The disease process that affects the abdominal aorta may also involve the renal arteries, leading to the development of renovascular hypertension and often to progressive renal failure. Intervention through surgical revascularization (SR) or percutaneous transluminal renal angioplasty (PTRA) offers the potential for cure or improvement of hypertension and for preservation of renal function.¹²⁻¹⁵

If concomitant atheroembolism of the renal circulation has contributed to the hypertension or to compromised renal function, then interventional procedures

From the Departments of Hypertension and Nephrology (D.G.V.), Pathology (G.N.G., R.T.), and Urology (A.C.N.), The Cleveland Clinic Foundation, and the Division of Nephrology (G.E.), Albany Medical College, New York. Submitted Feb 1989; accepted Feb 1989.

Address reprint requests to D.G.V., Department of Hypertension and Nephrology, The Cleveland Clinic Foundation, One Clinic Center, 9500 Euclid Avenue, Cleveland, Ohio 44195.

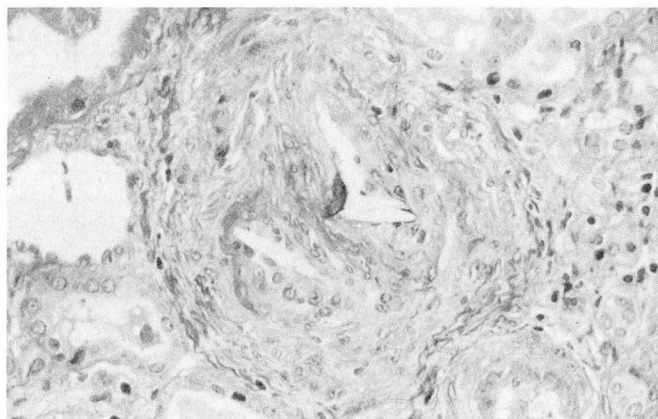


FIGURE 1. Kidney biopsy demonstrating cleft-like spaces characteristic of the cholesterol component of atheroemboli in an arteriolar segment. The lumen of the vessel is occluded by atheroemboli.

might not be warranted. On the other hand, since microembolization does not necessarily progress to irreversible renal failure, correction of hemodynamically significant stenosis by SR or PTRAs may be justified. Few case reports have commented on the association of significant renal artery stenosis (RAS) and its possible role in the progressive renal failure usually noted with renal cholesterol embolization.^{7,16-18}

This study retrospectively reviews 24 documented cases of renal cholesterol embolization, in an effort to establish the frequency of associated RAS. The prognosis in response to medical therapy or SR was determined and risk factors and events possibly precipitating renal cholesterol embolization were analyzed.

MATERIALS AND METHODS

A retrospective review of all renal biopsies performed at the Cleveland Clinic from 1978 to 1986 yielded 24 cases in which renal cholesterol emboli were identified (Figure 1). Renal arteriograms were available prior to renal biopsy in all patients. Bilateral RAS was present in 15 and unilateral RAS was observed in four, while the renal arteries were normal or revealed only trivial stenosis in five patients. In four, one renal artery was totally occluded. Baseline serum creatinine concentrations were determined during a period of stable renal function several years to two years prior to biopsy.

To identify precipitating events, a graph of serum creatinine *v* time was plotted for each case. On these plots, each significant event was noted, including surgical procedures or diagnostic arteriographic procedures.

TABLE 1
ATHEROSCLEROTIC RISK FACTORS (N = 24)

| | |
|------------------------------------|----|
| Aortic: atherosclerosis | 24 |
| Hypertension ≥ 4 yrs duration | 24 |
| Cardiac | |
| Left ventricular hypertrophy | 17 |
| Coronary artery disease | 16 |
| Congestive heart failure | 13 |
| Angina pectoris | 11 |
| Prior myocardial infarction | 5 |
| Cerebral | |
| Transient ischemic attack | 12 |
| Carotid occlusive disease | 15 |
| Stroke | 8 |
| Peripheral vascular | |
| Iliofemoral atherosclerosis | 18 |
| Claudication | 12 |
| Cigarette smoking | 22 |
| Exogenous obesity | 10 |
| Diabetes mellitus (adult onset) | 2 |
| Cholesterol ≥ 240 mg/dL | 7 |

Review of these event lines enabled a judgment of whether any single intervention was a probable precipitating event for deterioration of renal function. The indication for renal biopsy was noted in each case, as was the presence or absence of associated cardiovascular risk factors, including a history of hypertension and any evidence of worsening of hypertension prior to renal biopsy.

Responses to intervention (medical or surgical) were determined by changes in serum creatinine concentration; this was noted at the time of the latest available follow-up. Effects of intervention on blood pressure control were determined both by evaluation of blood pressure measurements and by changes in the number of antihypertensive medications required; these were also noted at the time of latest follow-up. Clinical follow-up was accomplished, where available, to and including March 1988.

RESULTS

There were 19 men and five women in the study; their average age was 62 years (range, 45-75 years). Seventeen of the 24 patients were >60 years of age at the time of biopsy. The renal biopsy was performed for the evaluation of unexplained renal insufficiency in nine patients, at the time of SR in 14, and to assist in establishing the prognosis in one patient with progressive renal insufficiency. An earlier biopsy on that patient revealed no cholesterol emboli.

Arterial hypertension requiring pharmacologic therapy was present in all 24 patients and was of >4 years duration in 21 individuals (Table 1). Two patients had a

documented onset of hypertension within six months of renal biopsy (ages 54 and 71 years) and in only 10 of 24 patients was a definite family history of hypertension obtained. In 21 patients, increasing difficulty controlling blood pressure was evidenced by higher recorded pressures and increased drug requirements, usually occurring within six months of renal biopsy. In one patient, the clinical picture of malignant hypertension was observed. The mean blood pressure of the group at the time of renal biopsy was 188/97 mmHg (ranges: systolic, 150–230 mmHg; diastolic, 70–120 mmHg). Worsening of hypertension was independent of the presence of RAS, since it was also observed prior to biopsy in four of the five patients without evidence of RAS.

Other atherosclerotic risk factors

The mean baseline serum creatinine concentration in 24 patients was 2.0 mg/dL (range, 1.0–6.5 mg/dL) (Table 2). At the time of renal biopsy, four patients were already on dialysis, and serum creatinine concentrations had increased by 20% or more from baseline in 20 of the 24 patients, including four of the five patients without RAS. The mean serum creatinine concentration for 20 patients not on dialysis at the time of renal biopsy was 4.4 mg/dL (range, 1.5–14.6 mg/dL). The five patients without RAS were among the group demonstrating an increase in serum creatinine prior to renal biopsy.

A review of event lines relating interventional procedures to changes in serum creatinine concentrations suggested that an episode of atheroembolism was directly related to a surgical or angiographic procedure in seven individuals (Figure 2). In nine, a review of the event lines suggested a probable causal relationship to a surgical or angiographic procedure (Figure 3) and, in the remaining eight cases, a causal relationship could not be established (Figure 4). Though aspirin and/or dipyridamole (Persantine) were frequently employed in the ongoing clinical care of patients, there was no evident causal relationship between either agent and subsequent cholesterol embolization. The use of heparin or coumarin derivatives was not associated with cholesterol embolization in this group of patients.

Arteriographic evidence of aortic atherosclerosis was present in all 24 patients, with associated abdominal aortic aneurysms in seven individuals (Table 1). Iliofemoral atherosclerosis was observed in 18, with a history of intermittent claudication noted in 12 individuals. Left ventricular hypertrophy was present in 17 patients as shown by electrocardiogram, echocardiogram, or at the time of cardiac catheterization. Coronary arteriography had been performed in 17 individuals, de-

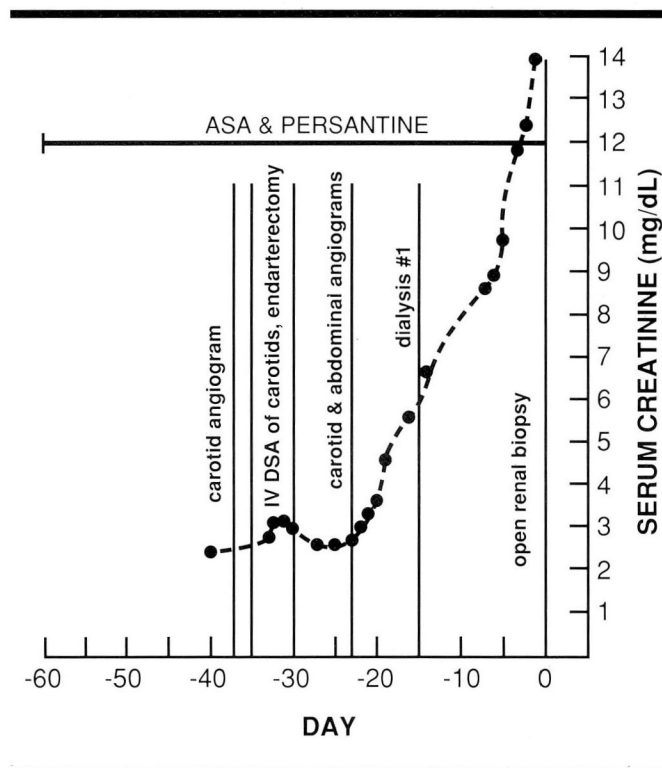


FIGURE 2. Patient #2 event line. Acute renal failure that progressed relentlessly suggests a direct causal relationship with a diagnostic procedure.

monstrating significant coronary artery disease in 16 and no significant disease in one. In the remaining seven patients, coronary arteriography was not performed. Eleven patients provided a history of symptomatic angina pectoris, and prior myocardial infarctions were demonstrated by electrocardiograms in five. Four patients had undergone coronary artery bypass surgery and, in 13, a history of congestive heart failure was documented. A prior cerebrovascular accident had occurred in eight patients, while in 12, history of transient ischemic attacks was noted. Fifteen patients had a history of carotid occlusive disease documented by ultrasound, arteriography, or digital subtraction arteriography. In 10, prior carotid endarterectomies had been performed.

A history of heavy cigarette smoking was observed in 22 patients, with a mean pack-year history of 56 years. One individual had a long history of pipe smoking and one was a nonsmoker. Exogenous obesity (greater than 120% of ideal weight) was observed in 10 patients. A diagnosis of adult-onset diabetes mellitus was established in only two individuals. A serum cholesterol determination was available in all patients from several days to

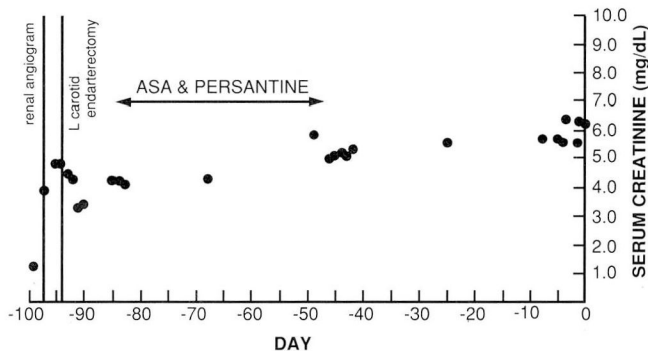


FIGURE 3. Patient #4 event line. A probable causal relationship with an arteriographic procedure is suggested by progressive renal failure over a three-month period of observation.

several months prior to renal biopsy. The mean serum cholesterol was 229 mg/dL (range, 97–445 mg/dL), but only seven had a serum cholesterol concentration exceeding 240 mg/dL.

In eight patients, livedo reticularis to the buttocks, back, thighs, legs, or feet was evident, and in four, embolic events to the toes (purple toes) were documented. Retinal emboli (Hollenhorst plaques) were observed in four patients, and one major artery embolus to a femoral artery was documented.

A variety of gastrointestinal syndromes have been associated with cholesterol embolization. In this study population, gastrointestinal symptoms included hemorrhagic gastritis in five, undiagnosed upper gastrointestinal bleeding in one, pancreatitis in one, and a mesenteric embolus in one. In six individuals, a history of undiagnosed abdominal pain was elicited.

Medical management

Of nine patients managed medically, one was lost to follow-up and three on dialysis died after periods of two to eleven and a half months (Table 2). Follow-up was obtained for periods of six to 80.4 months in five patients following diagnosis by renal biopsy of renal cholesterol embolization.

Renal function improved in one (Patient 7, creatinine 7.6 to 4.0 mg/dL) at 14 months of follow-up. Renal function remained stable in two (Patients 8 and 9 after follow-ups of 19.3 and 80.4 months), and two patients were on dialysis at the time of latest follow-up (Patients 5 and 6).

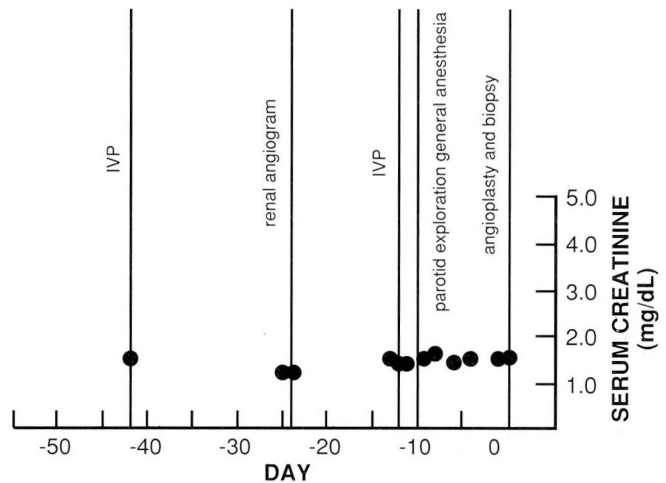


FIGURE 4. Patient #9 event line. Renal insufficiency remained stable over time despite several surgical and diagnostic procedures. A causal relationship could not be established.

Follow-up of blood pressure in these five patients revealed a decrease in drug requirements in two and unchanged requirements for antihypertensive drugs in three. The decrease in medication requirements for one patient on maintenance dialysis after six months of follow-up may have been a reflection of controlled intravascular volume.

Results of interventional therapy

Of two patients who underwent PTR, one was lost to follow-up and the other showed significant improvement in renal function and unchanged antihypertensive drug requirements after 20 months of follow-up. Follow-up was not available in one patient who underwent a nephrectomy.

Twelve patients underwent SR of a renal artery. Follow-up was available for 11 patients for 2 to 65.9 months. At latest follow-up, improved renal function as determined by decreased serum creatinine concentrations was evident in five (Patients 14, 17, 18, 19, and 24). Renal function remained stable in five (Patients 15, 16, 20, 21, and 22) and showed progression, e.g. greater than 20% rise in serum creatinine concentration, in one (Patient 23).

It is notable that three patients were on maintenance hemodialysis prior to surgical revascularization. Renal function improved and enabled discontinuation of dialysis in two, while the third patient showed no im-

TABLE 2
RENAL FUNCTION DATA AND OUTCOME

| Patient no. | Serum creatinine (mg/dL) | | | Procedure | Follow-up (mo) |
|-----------------------------|--------------------------|--------|-----------|-----------|----------------|
| | Baseline | Biopsy | Follow-up | | |
| Medical management | | | | | |
| 1 | 2.1 | D | LTF | - | - |
| 2 | 2.4 | 14.6 | D | - | 2† |
| 3 | 1.0 | 5.8 | D | - | 2† |
| 4 | 1.1 | 6.2 | D | - | 11.5† |
| 5 | 2.8 | 6.0 | D | - | 6 |
| 6 | 1.4 | 3.6 | D | - | 6.5 |
| 7 | 1.2 | 7.6 | 4.0 | - | 14 |
| 8 | 1.5 | 2.6 | 2.4 | - | 19.3 |
| 9 | 1.5 | 1.5 | 1.5 | - | 80.4 |
| Interventive therapy | | | | | |
| 10 | 1.0 | 2.8 | LTF | PTRA | - |
| 11 | 1.3 | 6.0 | 2.8 | PTRA | 20 |
| 12 | 2.9 | 2.1 | LTF | Nx | - |
| 13 | 1.8 | 3.0 | LTF | SR | - |
| 14 | 2.8 | D | 2.5 | SR | 2 |
| 15 | 2.3 | D | D | SR | 2.6 |
| 16 | 1.7 | 2.3 | 2.3 | SR | 6.0 |
| 17 | 6.5 | 7.6 | 4.0 | SR | 7.3 |
| 18 | 1.0 | D | 2.7 | SR | 10.6 |
| 19 | 1.0 | 3.1 | 2.1 | SR, Nx | 11.3 |
| 20 | 2.0 | 2.1 | 2.1 | SR | 22.7 |
| 21 | 2.1 | 1.8 | 1.5 | SR, Nx | 28.1 |
| 22 | 2.4 | 2.7 | 2.2 | SR | 34.6 |
| 23 | 2.7 | 3.0 | 4.0 | SR | 59.7 |
| 24 | 2.4 | 3.1 | 1.9 | SR, Nx | 65.9 |

† = died

D = dialysis, LTF = lost to follow-up, PTRA = percutaneous transluminal renal angioplasty, SR = surgical revascularization, and Nx = nephrectomy.

TABLE 3
RENAL FUNCTIONING FOLLOWING SR

| Follow-up (mo) | Preoperative | |
|----------------|--------------|-----------|
| | Preoperative | Follow-up |
| 11 | 8 | 10 |
| Mean: 22.7 | 3.2* | 2.5† |

*3 patients on dialysis

†1 patient on dialysis

provement and remained on dialysis at latest follow-up.

Pharmacologic requirements for control of blood pressure were subsequently reduced in two patients and unchanged in six of the 11 SR patients. While three individuals showed increased drug requirements for control of blood pressure at latest follow-up, two of these patients had been followed-up for five years or longer.

As evidenced in Table 3, mean follow-up for 11 patients undergoing surgical revascularization was 22.7 months. The mean preoperative serum creatinine concentration was 3.2 mg/dL in eight patients not on dialysis prior to surgery. As noted, three of the 11 patients re-

quired maintenance hemodialysis preoperatively. At latest follow-up, the mean serum creatinine concentration in 10 patients was 2.5 mg/dL, with one patient remaining on maintenance hemodialysis despite technically successful SR.

The operative procedures for the 12 patients undergoing renal artery revascularization were as follows: splenorenal bypass in five, hepatorenal bypass in two, iliac-renal bypass in two, endarterectomy plus patch angioplasty in one, aorto-renal anastomosis in one, and a branch revascularization plus autotransplant in one. In three, a contralateral nephrectomy was also performed.

DISCUSSION

Patients with diffuse atherosclerosis that affects the aorta constitute a population at risk for renal cholesterol embolization. Few reports have noted significant RAS in association with renal cholesterol embolization. In a recent report on atheromatous renal disease and renal failure, the renal failure was considered mainly due to atheromatous RAS in 22 of 32 patients.¹⁹ Yet in more

than half the group with RAS, biopsy or angiographic evidence of cholesterol embolization was observed, suggesting a clear association with RAS in this population.

In our study of 24 patients with biopsy evidence of renal cholesterol emboli, significant RAS was a finding in 19 patients. In older persons with generalized atherosclerosis and longstanding hypertension, progressive renal insufficiency should suggest the possibility of renal artery occlusive disease and/or renal cholesterol embolization. Confirmation of either is not possible without appropriate arteriography and/or renal biopsy.

Clinical and/or angiographic evidence of significant arteriosclerotic occlusive disease in major vessels other than the kidney is important and should raise the suspicion of RAS in this population. In addition to aortic atherosclerotic obliterans, observed in all patients, significant ilio-femoral atherosclerosis obliterans was present in 18 patients, two-thirds of whom had intermittent claudication.

A history consistent with clinically apparent coronary artery disease was evident in 22 of 24 patients on the basis of a history of angina pectoris and electrocardiographic evidence of prior myocardial infarction and/or angiographic evidence of coronary occlusive disease. Extracranial carotid occlusive disease was suggested by a history of transient ischemic attacks or stroke in 18 of 24 patients, confirmed by carotid ultrasound or arteriographic studies in 15 individuals. Nine individuals had already required carotid endarterectomies prior to biopsy, and one additional patient underwent the procedure after biopsy, following a transient ischemic attack. This association has contributed to the high risk formerly associated with operative treatment of renovascular disease and has clearly contributed to the late mortality observed in these patients.^{20,21}

An aggressive approach to preliminary screening and correction of existing coronary or cerebrovascular occlusive disease, and more effective surgical revascularization techniques that avoid operation on a badly diseased aorta, have led to a more acceptable surgical morbidity and mortality.²²⁻²⁵ Only two patients in this series were treated with PTRAs. Our experience and that of others suggests limited value of PTRAs in patients with ostial atherosclerotic lesions.²⁶⁻²⁸

The presence of longstanding hypertension in this population is not surprising. Recent onset (within six months) of hypertension in two patients (ages 54 and 71 years) and recent worsening of established hypertension, usually within six months of renal biopsy, represent well-recognized clinical clues suggestive not only of renal cholesterol emboli but also of progressive renal arterial

occlusion. Recent worsening of hypertension observed in four patients without RAS clearly implicates renal cholesterol embolization as an inciting event. In the remaining patients, progressive hypertension was possibly due to atherosclerotic disease of the renal arteries and cholesterol embolization.

Progressive renal failure was evidenced in 20 of 24 patients prior to renal biopsy; four were already on maintenance dialysis. Renal failure associated with RAS is also well recognized.¹⁵ A review of event lines relating interventional procedures to changes in renal failure suggested, from the rapidity of renal failure (*Figure 1*), that atheroembolism was associated in seven individuals. The rapid decline in renal function observed would not be expected from the natural history of atherosclerotic RAS, short of sudden arterial occlusion.

The role of nephrotoxicity of contrast media must be considered in the differential diagnosis of rapidly progressive renal failure following contrast-enhanced procedures in patients with impaired renal function. The suspicion of cholesterol embolization should be heightened when renal function fails to improve after one to two weeks. Renal function did not return to the pre-procedure baseline in these seven patients and, where available, urinary sediment changes were not consistent with contrast-medium-induced acute renal failure (dirty brown casts). The retrospective nature of this study does not allow comment regarding clinical and experimental observations of high eosinophil counts, thrombocytopenia, and low serum complement levels, which might have helped implicate renal cholesterol embolization.^{16,29}

Of 11 SR patients followed for an average of 22.7 months, improvement in renal function was seen in five, including two patients in whom dialysis was discontinued after successful SR. In these five patients, RAS clearly contributed to the renal failure and, in two, must be considered a treatable cause of end-stage renal disease. In the remainder, renal function was unchanged after SR, including one patient on dialysis at the time of SR who derived no benefit from surgery (Patient 15).

Two patients were treated with PTRAs and one for whom follow-up was available showed improved renal function during a follow-up of 20 months. Persistence of some degree of renal impairment following intervention suggests that cholesterol embolization contributed to the renal failure. Obviously, other factors can also be considered likely contributors to renal failure in this population including: advanced age, generalized atherosclerosis and arteriolar nephrosclerosis, and unilateral intervention (PTRAs or SR) despite evidence of

bilateral RAS in many patients.

It was not surprising that technically successful PTRAs or SRs did not result in persistent improvement in pharmacologic requirements for blood pressure control in the majority of patients. Hypertension requiring two or more drugs was present at the time of intervention. Uncontrollable hypertension is unusual with currently available drugs, as evidenced by an average blood pressure of 188/97 mmHg in 24 patients prior to renal biopsy. It is apparent that both the progressive renal failure and hypertension represent an admixture of cholesterol embolization and hemodynamically significant RAS in most patients (19 of 24).

It is clear that both atherosclerotic renovascular disease and/or renal cholesterol embolization must be considered in older patients with generalized arteriosclerosis and longstanding hypertension who present with progressive renal insufficiency. Recent worsening of hypertension is characteristic of either diagnosis; rapid or in-

sidious progression of renal failure in association with a surgical procedure or diagnostic radiologic procedure should suggest renal cholesterol embolization.

We have demonstrated that SR or PTRAs can improve renal function in patients with atherosclerotic renovascular disease despite the presence of renal cholesterol embolization. In patients with atherosclerotic renovascular disease, progressive renal insufficiency, and suspected renal cholesterol embolization, a period of observation would seem appropriate to determine whether stabilization or spontaneous improvement in renal function is likely to occur. If renal functional impairment continues to progress, interventional management, preferably SR, should be considered.

ACKNOWLEDGMENT

The authors wish to acknowledge their gratitude for the assistance of Helen Thams and Ray Borazanian in the preparation of this manuscript.

REFERENCES

- Smith MC, Ghose MK, Henry AR. The clinical spectrum of renal cholesterol embolization. *Am J Med* 1981; 71:174-180.
- Ho SW-C, Thatcher GN, Matz LR. Reversible renal failure due to renal cholesterol embolism. *Aust NZ J Med* 1982; 12:531-533.
- McGowan JA, Greenberg A. Cholesterol atheroembolic renal disease: report of 3 cases with emphasis on diagnosis by skin biopsy and extended survival. *Am J Nephrol* 1986; 6:135-139.
- Thurlbeck WM, Castleman B. Atheromatous emboli to the kidneys after aortic surgery. *N Engl J Med* 1957; 257:442-447.
- Jones DB, Iannaccone PM. Atheromatous emboli in renal biopsies: an ultrastructural study. *Am J Pathol* 1975; 78:261-270.
- Flory CM. Arterial occlusions produced by emboli from eroded aortic atheromatous plaques. *Am J Pathol* 1945; 21:549-565.
- Harrington JT, Sommers SC, Kassirer JP. Atheromatous emboli with progressive renal failure: renal arteriography as the probable inciting factor. *Ann Intern Med* 1968; 68:152-160.
- Ramirez G, O'Neill WM, Lambert R, Bloomer HA. Cholesterol embolization: a complication of angiography. *Arch Intern Med* 1978; 138:1430-1432.
- Eisenberg RL, Bank WO, Hedgcock MW. Renal failure after major angiography. *Am J Med* 1980; 68:43-46.
- Rosansky SJ, Deschamps EG. Multiple cholesterol emboli syndrome after angiography. *Am J Med Sci* 1984; 288:45-48.
- Zatuchni J, Patel HK, Chiemchanya S. The "blue toe" syndrome with renal atheroembolism and failure. *Angiology* 1985; 36:209-214.
- Schefft P, Novick AC, Stewart BH, Straffon RA. Renal revascularization in patients with total occlusion of the renal artery. *J Urol* 1980; 124:184-186.
- Madias NE, Kwon OJ, Millan VG. Percutaneous transluminal renal angioplasty: a potentially effective treatment for preservation of renal function. *Arch Intern Med* 1982; 142:693-697.
- Libertino JA, Zinman L, Breslin DJ, Swinton NW, Legg MA. Renal artery revascularization: restoration of renal function. *JAMA* 1980; 244:1340-1342.
- Novick AC, Textor SC, Bodie B, Khauli RB. Revascularization to preserve renal function in patients with atherosclerotic renovascular disease. *Urol Clin North Am* 1984; 11:477-490.
- Cosio FG, Zager RA, Sharma HM. Atheroembolic renal disease causes hypocomplementaemia. *Lancet* 1985; 2:118-121.
- Retan JW, Miller RE. Microembolic complications of atherosclerosis: literature review and report of a patient. *Arch Intern Med* 1966; 118:534-545.
- Case records of the Massachusetts General Hospital. Case 25-1967. *N Engl J Med* 1967; 276:1368-1377.
- Meyrier A, Buchet P, Simon P, Fernet M, Rainfray M, Callard P. Atheromatous renal disease. *Am J Med* 1988; 86:139-146.
- Hunt JC, Strong CG. Renovascular hypertension: mechanisms, natural history and treatment. *Am J Cardiol* 1973; 32:562-574.
- Gifford RW Jr, McCormack LJ, Poutasse EF. The atrophic kidney: its role in hypertension. *Mayo Clin Proc* 1965; 40:834-852.
- Franklin SS, Young JD, Maxwell MH, et al. Operative morbidity and mortality in renovascular disease. *JAMA* 1975; 213:148-153.
- Novick AC, Straffon RA, Stewart BH, Gifford RW, Vidt D. Diminished operative morbidity and mortality in renal revascularization. *JAMA* 1981; 246:749-753.
- Novick AC, Pohl MA, Schreiber M, Gifford RW Jr, Vidt DG. Revascularization for preservation of renal function in patients with atherosclerotic renovascular disease. *J Urol* 1982; 129:907-911.
- Olin JW, Vidt DG, Gifford RW Jr, Novick AC. Renovascular disease in the elderly: an analysis of 50 patients. *J Am Coll Cardiol* 1985; 5:1232-1238.
- Grim CE, Luft FC, Yune HY, Klatte EC, Weinberger MH. Percutaneous transluminal dilatation in the treatment of renal vascular hypertension. *Ann Intern Med* 1981; 95:439-442.
- Geyskes GG, Puylaert CBAJ, Oei HY, Dorhout Mees EJ. Follow-up study of 70 patients with renal artery stenosis treated by percutaneous transluminal dilatation. *Br Med J* 1982; 287:333-336.
- Hayes JM, Risius B, Novick AC, et al. Experience with percutaneous transluminal angioplasty for renal artery stenosis at the Cleveland Clinic. *J Urol* 1988; 139:488-492.
- Kasinath BS, Lewis EJ. Eosinophilia as a clue to the diagnosis of atheroembolic renal disease. *Arch Intern Med* 1987; 147:1384-1385.