

Thrombolytic therapy for renal artery occlusions: a preliminary report

JEFFREY W. OLIN, DO; ROBERT A. GRAOR, MD; JESS R. YOUNG, MD

■ Percutaneous transluminal angioplasty and renal artery revascularization have been successful in controlling blood pressure and preserving renal function in patients with atherosclerotic renal artery stenosis. In addition, thrombolysis appears promising for treatment of patients with total occlusion of renal artery bypass grafts. More experience will be necessary to define its role in native renal artery occlusions. The authors describe successful thrombolysis in two of three patients given thrombolytic therapy for total occlusion of renal arteries.

□ INDEX TERMS: FIBRINOLYTIC AGENTS; RENAL ARTERY OBSTRUCTION, DRUG THERAPY □ CLEVE CLIN J MED 1989; 56:432-438

ATHEROSCLEROTIC renal artery stenosis was previously thought to be rare. However, as our population ages, generalized atherosclerosis and atherosclerotic renal artery disease are becoming more prevalent.¹ Percutaneous transluminal angioplasty (PTA),²⁻⁴ renal revascularization alone,⁵⁻⁷ and renal revascularization with aortic replacement⁸⁻¹⁰ are being performed with increasing frequency both to control high blood pressure and to preserve renal function. We recently administered thrombolytic agents to three patients to treat total occlusion of a renal artery to a solitary functioning kidney.

CASE REPORTS

Case 1

A 56-year-old black man had increasing bilateral hip claudication that occurred when he walked even a short

distance (i.e., less than half a block). He had mild coronary atherosclerosis, which had been shown radiographically at cardiac catheterization. His blood pressure had been poorly controlled for 14 years. The patient had a BUN of 23 mg/dL and serum creatinine level of 2.3 mg/dL; urine sediment test showed albuminuria (2+), and microscopic examination showed no abnormalities. An arteriogram revealed chronic occlusion of the aorta distal to the takeoff of the right renal artery. The right renal artery was markedly stenotic (>90%) at its origin (Figure 1A). The left renal artery was not visualized. The celiac axis showed mild narrowing near the origin, the superior mesenteric artery was widely patent, and a large collateral artery reconstituted the inferior mesenteric artery.

An aorto-bifemoral bypass was performed with revascularization of the right kidney using a 6-mm Golaski microknit graft from the aortic graft to the right renal artery. The ankle/arm blood pressure ratios improved from 0.44 preoperatively to 0.69 postoperatively. The serum creatinine level increased to a peak of 4.7 mg/dL postoperatively and returned to 2.0 mg/dL when the patient was discharged from the hospital. The blood pressure remained difficult to control despite adminis-

From the Department of Vascular Medicine, The Cleveland Clinic Foundation. Submitted Jan 1989; accepted March 1989.

Address reprint requests to J.W.O., Department of Vascular Medicine, The Cleveland Clinic Foundation, One Clinic Center, 9500 Euclid Avenue, Cleveland, OH 44195.

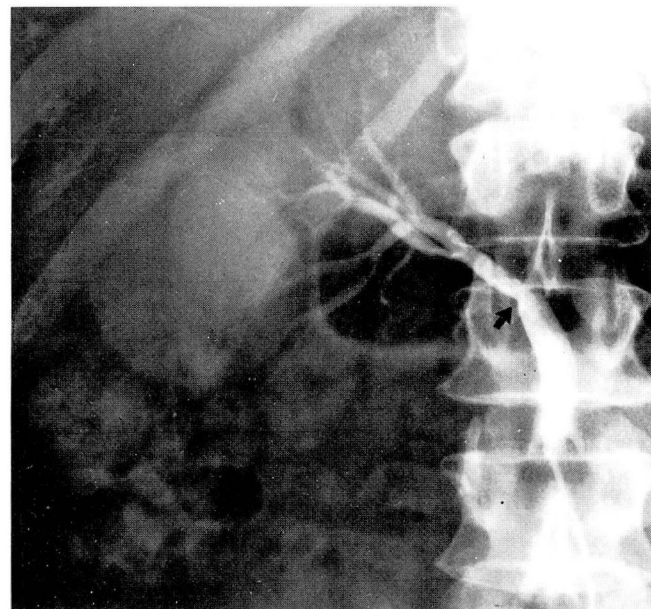
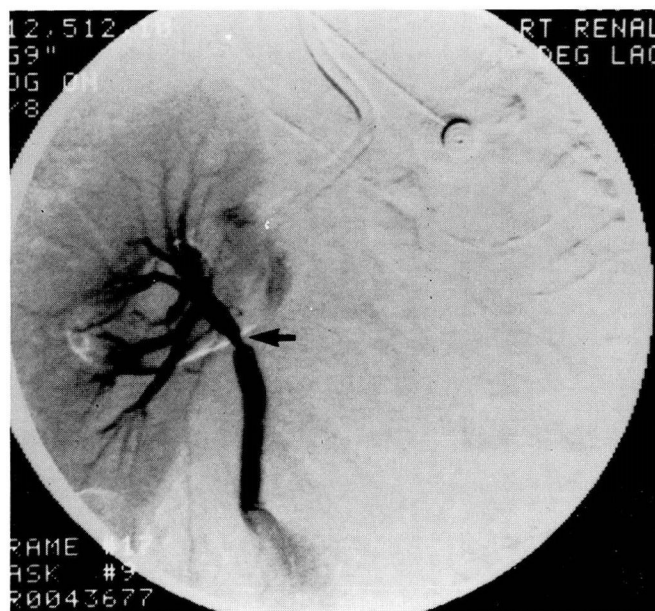
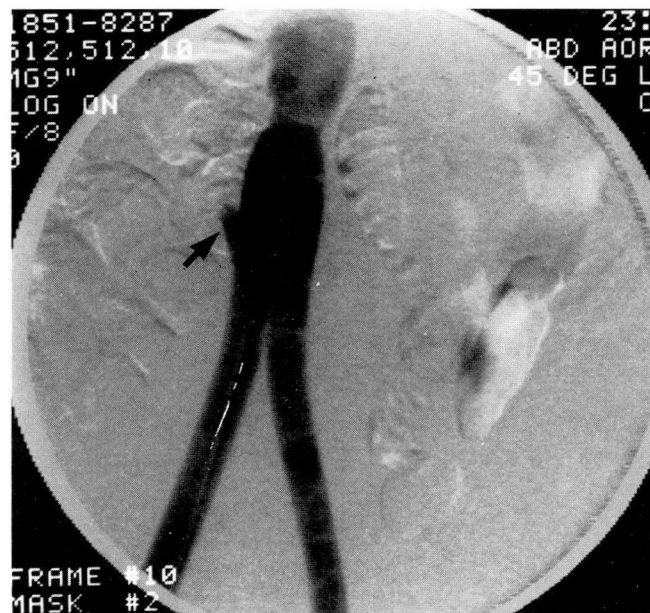
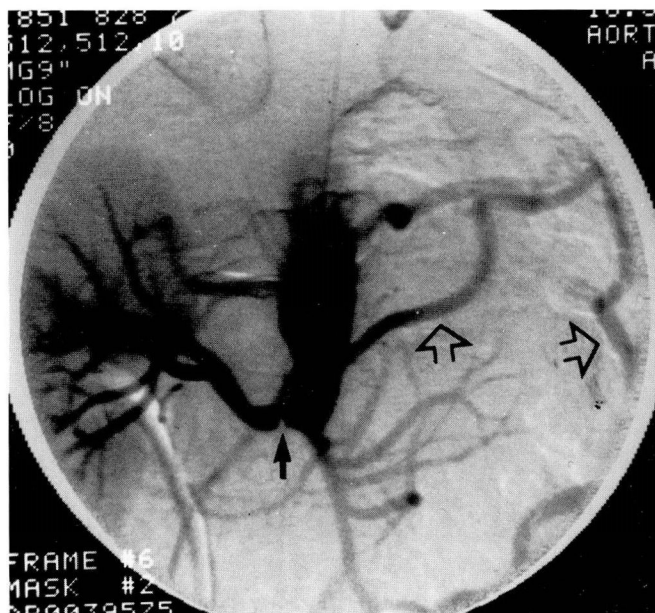
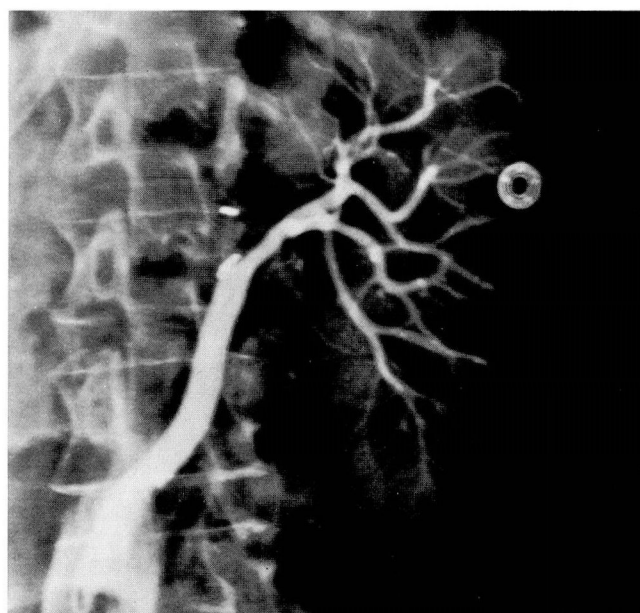
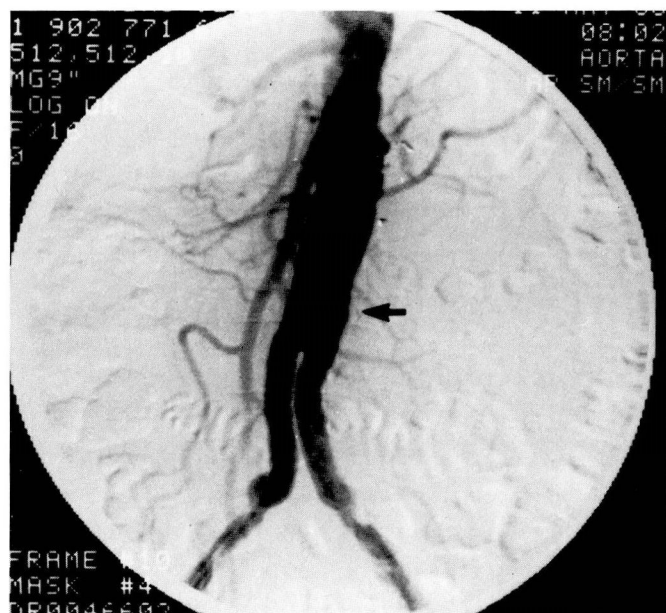
A, B
C, D

FIGURE 1A. Intra-arterial digital subtraction arteriogram shows total occlusion of aorta distal to takeoff of right renal artery. Right renal artery is severely stenotic (*solid arrow*). Superior mesenteric artery is widely patent with large collateral artery (*open arrows*) reconstituting the inferior mesenteric artery. FIGURE 1B. Intra-arterial digital subtraction arteriogram shows thrombosis of aortorenal bypass graft (*arrow*). FIGURE 1C. Arteriogram shows complete thrombolysis of right renal artery bypass graft and clinically significant stenosis at the anastomosis of the bypass graft to the native renal artery (*arrow*). FIGURE 1D. The area of stenosis at the anastomotic site was significantly improved after PTA. Mild stenosis is still present (*arrow*).

tration of the following medications: 20 mg furosemide twice daily, 50 mg atenolol daily, and 5 mg minoxidil daily.

Seven months later, the patient was transferred to the

Cleveland Clinic with acute pulmonary edema after suffering an acute myocardial infarction. He was anuric and was given emergency hemodialysis and ultrafiltration. Pre-dialysis laboratory values included: BUN, 46



A, B

FIGURE 2A. Intra-arterial digital subtraction arteriogram of aorta shows aorto-iliac graft with occlusion of the aorta and left renal artery bypass graft (arrow). FIGURE 2B. Arteriogram taken after thrombolysis of aortorenal bypass graft shows no stenosis. Cortical blood vessels appear healthy.

mg/dL; serum creatinine, 5.8 mg/dL; and serum potassium, 5.0 mEq/L. An intra-arterial digital subtraction arteriogram showed thrombosis of the right renal artery bypass graft (Figure 1B). A catheter was placed directly into the occluded graft, and urokinase was infused at 4,000 IU/min. The next day, arteriography was repeated, showing a patent aortorenal graft. However, clinically significant stenosis was seen at the anastomosis of the renal artery graft and native renal artery (Figure 1C), with a 60-mmHg gradient. PTA was successfully performed (Figure 1D), decreasing the pressure gradient to 20 mmHg. The patient remained oliguric and required periodic hemodialysis. He had several episodes of ventricular tachyarrhythmia, was hemodynamically unstable, and died one week later.

In summary, although the renal artery thrombus was successfully lysed, severe hemodynamic instability precluded recovery from the acute tubular necrosis.

Case 2

A 67-year-old white woman had a one-year history of poorly controlled hypertension. One week before admission to the Cleveland Clinic, she had visited an emergency room because of right lower quadrant pain; at that time, an abdominal aortic aneurysm was discovered by ultrasonography. At admission, the patient had blood pressure of 200/104 mmHg, a grade III/VI holosystolic

epigastric abdominal bruit, and an enlarged aorta detected by palpation. She was taking 20 mg furosemide daily and 240 mg sustained-release verapamil daily. An arteriogram showed a 3.1-cm abdominal aortic aneurysm with total occlusion of the right renal artery and more than 90% narrowing of the left renal artery. Carotid ultrasonography showed a normal left internal carotid artery and 50%–70% narrowing of the right internal carotid artery. Results of stress thallium examination (to detect asymptomatic coronary artery disease) were normal, and the serum creatinine level was 1.7 mg/dL.

The patient had aorto-iliac bypass surgery using a 5-mm Golaski microknit graft from the aortic graft site to the left renal artery. Daily administration of 100 mg atenolol was begun. At discharge from the hospital, the patient had a serum creatinine level of 1.2 mg/dL and blood pressure of 140/68 mmHg.

Six months later, the patient returned to the hospital, complaining of an 8-kg weight gain and anuria of three days' duration. Laboratory examination showed the following values: BUN, 110 mg/dL; serum creatinine, 10.6 mg/dL; serum sodium, 121 mEq/L; serum potassium, 5.3 mEq/L; and lactic dehydrogenase, 520 IU/L.

An arteriogram showed occlusion of the left renal artery graft (Figure 2A). A catheter was inserted into the occluded graft, and urokinase was infused at a rate of

A, B

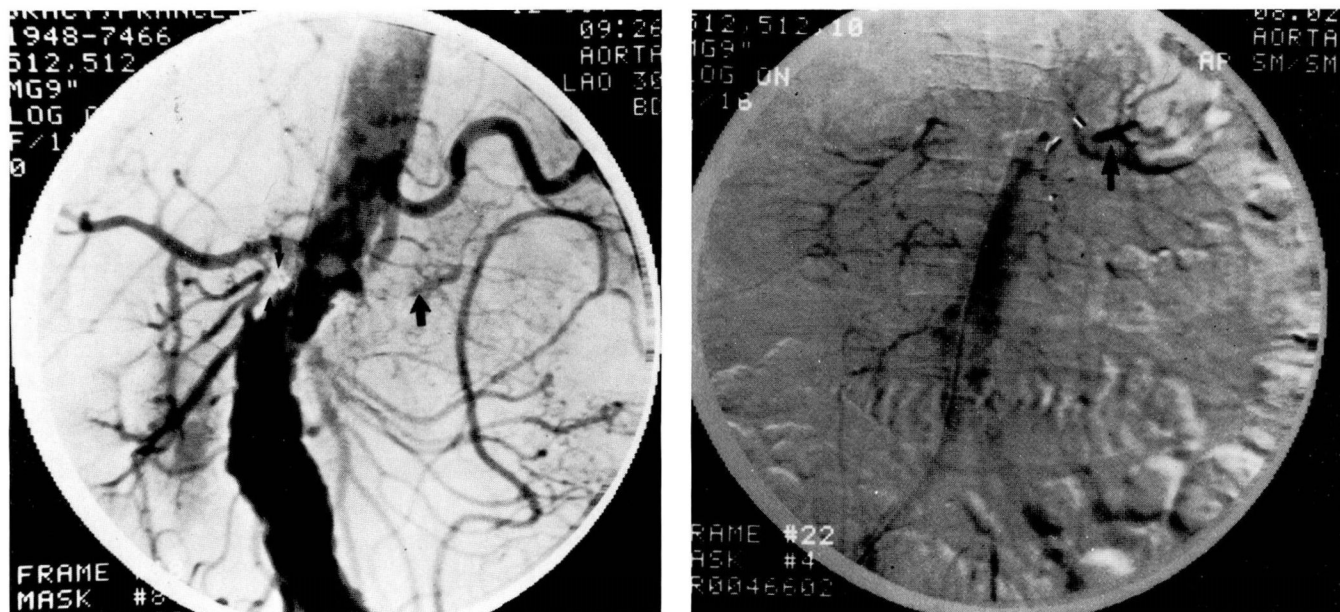

FIGURE 3A. Intra-arterial digital subtraction arteriogram shows severe aortic atherosclerosis, total occlusion of renal artery to the upper pole (*small arrow*) and subtotal occlusion of renal artery to the lower pole (*small arrow*) of the right kidney. Left renal artery is totally occluded, and distal reconstitution of the renal artery is seen (*large arrow*). FIGURE 3B. Arteriogram shows distal reconstitution of renal artery (*arrow*) after contrast medium has disappeared from aorta.

4,000 IU/min. The next morning, arteriography was repeated and showed a widely patent renal bypass graft. No stenosis was seen, and the cortical renal vessels appeared reasonably healthy (*Figure 2B*). Hemodialysis was performed one more time. The urine output increased, and BUN and creatinine levels continuously declined.

At discharge from the hospital, the patient had a BUN of 93 mg/dL and a serum creatinine level of 6.8 mg/dL. Renal function had remained stable when the patient was seen at follow-up examination nine months after thrombolysis. At that time, BUN was 49 mg/dL and serum creatinine level was 3.6 mg/dL. The patient's blood pressure had been more difficult to control, requiring 40 mg furosemide twice daily, 100 mg atenolol daily, and 20 mg nifedipine every six hours.

Case 3

A 58-year-old white woman came to the Cleveland Clinic with accelerated hypertension (blood pressure, 220/120 mmHg) and declining renal function. She had been taking furosemide, atenolol, nifedipine, and clonidine. Her serum creatinine level had risen to 3.4 mg/dL from a level of 2.8 mg/dL two months previously.

An arteriogram showed severe atherosclerosis of the abdominal aorta, total occlusion of the renal artery to

the right kidney's upper pole, and subtotal (99%) occlusion of a larger renal artery to the lower pole of the right kidney. The left renal artery was totally occluded but was reconstituted distally (*Figure 3*). Laminograms showed the right kidney to measure 12 cm in length and the left kidney, 10 cm.

The patient had several episodes of acute pulmonary edema as well as a recent myocardial infarction; we therefore determined that she would be at increased operative risk if aortic replacement and renal revascularization were attempted. Because the left kidney was deemed salvageable, a catheter was inserted into the left renal artery. A guide wire was advanced into a highly calcified, hard plaque. A catheter was inserted over the guide wire, and urokinase was infused at 4,000 IU/min. An arteriogram taken the next day showed no improvement. Urokinase therapy was discontinued, and the patient subsequently had coronary artery bypass surgery and later aortic replacement and bilateral renal endarterectomy.

DISCUSSION

Atherosclerotic renal artery stenosis, previously thought to be the cause of hypertension in only 0.4%–4% of hypertensive patients, is now commonly en-

countered.^{1,11} Some investigators have suggested that 36%–63% of patients have progression of renal artery stenosis and that total occlusion of the renal artery develops in 16% of patients.^{12–14} These data are incomplete, however, in that most patients were not studied prospectively. (Prospective studies are underway at our institution.)

The spectrum of patients with renal artery stenosis is also changing.⁷ Many patients are older and have generalized arteriosclerosis as well as severe aortic atherosclerosis. Intervention is considered more often to preserve renal function than to control blood pressure. In many patients, the aorta is so severely diseased that an aortorenal saphenous vein bypass is not technically feasible. In the presence of diffuse atherosclerosis, the celiac axis is often affected and therefore precludes either hepatorenal or splenorenal bypass. The implications of this are that many patients require aortic replacement along with renal revascularization. Whereas renal revascularization carries an operative mortality rate of approximately 2% when performed alone⁵ and aortic replacement alone carries an operative mortality of approximately 2%,^{15–16} combining these operations often results in a mortality rate of 7% for unilateral renal revascularization and 15% for bilateral renal revascularization⁹ despite careful perioperative screening for carotid and coronary atherosclerosis and correction of these extrarenal atherosclerotic manifestations before renal revascularization. Recently, one report¹⁰ described an operative mortality rate of 3% in 32 patients with severe aortorenal atherosclerosis who had combined aortic replacement and bilateral renal revascularization.

PTA is also being done with increasing frequency in patients with renal artery stenosis. In our experience and that of others, the effectiveness of PTA in treating atherosclerotic renal artery stenosis is poor.^{4,17} Osteal lesions usually cannot be dilated; when they can be dilated, stenosis often recurs rapidly. Even with non-osteal lesions, only 42% of patients have a successful clinical outcome, and 55% have recurrent stenosis.⁴ Preservation of renal function with PTA has been reported,³ but patients so treated may require repeated angioplasty because of recurrent stenosis. PTA of a totally occluded renal artery has been done successfully, but the risk of complications in this situation is much higher than when performed on a stenotic artery.^{18,19} We therefore reserve PTA of the renal arteries for patients who are at a high risk for surgical therapy but need some intervention for renal preservations, as in Case 3 or in patients with isolated focal renal artery stenosis or fibromuscular dysplasia. Recent reports have also showed the possi-

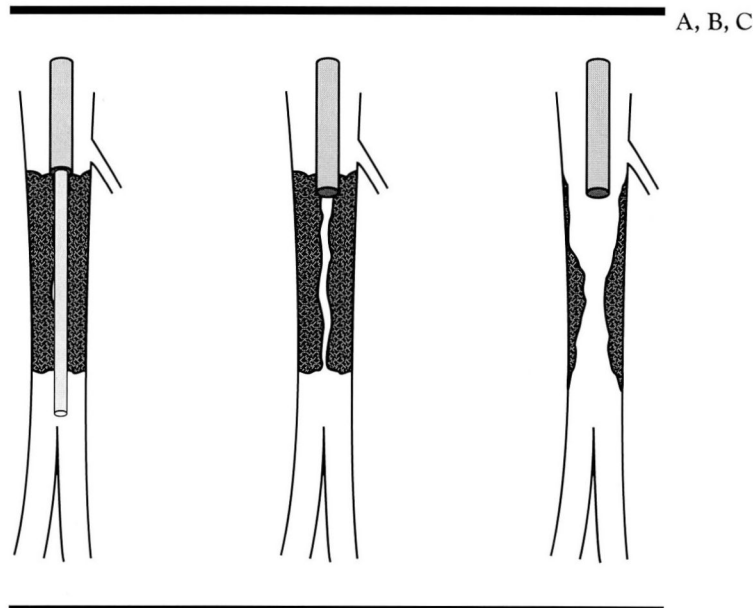


FIGURE 4. Schema of thrombolysis. **FIGURE 4A.** Guide wire is inserted into thrombus, and catheter is then advanced over guide wire several centimeters into thrombus. **FIGURE 4B.** Guide wire is removed and thrombolytic agent is infused through catheter directly into clot. **FIGURE 4C.** Thrombus is successfully lysed, leaving an area of residual stenosis from atherosclerotic plaque. Reprinted with permission.³¹

bility of using surgical revascularization to restore renal function in patients with totally occluded renal arteries.^{20–22}

We may logically assume that renal function can be restored if totally occluded renal arteries are reopened with thrombolytic therapy before irreversible renal parenchymal damage occurs. Intra-arterial administration of thrombolytic agents has restored blood flow to arteries acutely or chronically occluded by emboli or thrombus. Aortic bifurcation grafts as well as lower-extremity bypass grafts have also been successfully lysed.^{23–32} This thrombolytic technique involves inserting a guide wire into the occluded artery or graft and advancing a catheter over the guide wire several centimeters into the clot (*Figure 4*). The thrombolytic agent is then infused directly into the thrombus until complete thrombolysis occurs. If the thrombus is soft and the guide wire can be passed through the thrombus, successful thrombolysis occurs almost always; however, if the guide wire is advanced into a highly calcified atherosclerotic plaque (as in Case 3), successful thrombolysis becomes unlikely.²³

The success rate for thrombolysis in occluded leg arteries is 80%–93%.^{23,27,29,31} Generally, thrombolysis is

successful only for arterial occlusion less than 30 days old; however, thrombolysis has also occurred in chronic thrombotic occlusion of up to several months' duration.

For the kidney, the likelihood of successful thrombolysis is different than for leg arteries in that clinically significant recovery of renal function becomes less likely the longer the kidney is deprived of its blood supply. When a bypass graft to a solitary functioning kidney becomes thrombosed, irreversible renal damage occurs quickly and there may not be time for development of adequate collaterals to the kidney.³³ This situation is illustrated in Case 2; the patient recovered some renal function after three days of anuria but had doubled levels of serum creatinine after the prolonged anuria.

Thrombosis of a renal artery graft to a solitary functioning kidney often causes anuria; in addition, the patient may become acutely fluid overloaded and azotemic, as shown in the first two cases. This situation is easily recognizable and emergency arteriography and subsequent intra-arterial thrombolysis can be performed. In this situation, the probability of restoring renal function is high. In Case 1, in which renal artery thrombosis was caused by stenosis at the anastomotic site, angiography showed thrombolysis; nevertheless, the patient's unstable hemodynamic status precluded his recovery from acute tubular necrosis, and he subsequently died of underlying cardiovascular instability.

Case 2 is an excellent example of the usefulness of rapid angiography and thrombolysis in restoring renal function. In this patient, no demonstrable cause of renal artery thrombosis was identified.

The long-term patency of renal bypass grafts is unknown because no prospective studies have used serial arteriography to determine patency rates. In a series from our institution, six (5.7%) of 105 renal artery bypass grafts became occluded.⁹ This figure may represent underestimation. In another group of patients who had 254 surgical revascularizations, 11 (4.3%) later had renal artery thrombosis or stenosis at the anastomotic site.⁷ We may conclude, therefore, that more patients may benefit from thrombolysis of renal artery bypass grafts; these patients must be identified early enough for renal function to be salvaged.

Totally occluded native renal arteries also are not uncommon.^{1,34} In patients affected by this condition, occlusion develops slowly and thus allows collaterals to develop; acute loss of renal function is thereby prevented although the renal artery has become totally occluded.³³ Because these occlusions often progress slowly and do not produce symptoms, the problem in this situa-

tion is to achieve timely identification of candidates for thrombolysis. We decided to attempt the procedure in one patient (Case 3) because surgical revascularization would have placed her at increased operative risk. Predictors of renal salvage included distal late reconstitution of the renal artery by collaterals, presence of a late phase nephrogram, and kidney size greater than 9 cm in length on laminograms. When the guide wire was inserted, a calcified hard atherosclerotic lesion was encountered. Past experience has shown that these lesions are successfully lysed in only 20% of cases.²³ A trial of urokinase was given, but thrombolysis did not occur.

There have been several reports on the use of low-dose streptokinase (5,000–10,000 U/h) intra-arterially for renal artery thromboembolism^{35–37} or thrombosis after an attempted percutaneous transluminal angioplasty of the renal arteries.³⁵ In many of these situations, renal function was successfully salvaged. The situation in our patients was different in that thrombolysis was used for bypass graft thrombosis or thrombosis to a native renal artery secondary to atherosclerosis.

Urokinase was administered to all three patients because it is superior to streptokinase for treating peripheral arterial occlusions and causes fewer bleeding complications.^{26,27,31,32} Tissue plasminogen activator may be equally effective but has not been studied in this setting.^{29,31,32}

Thrombolytic therapy is absolutely contraindicated if the patient has active internal bleeding, has had a stroke less than two months previously, or has any intracranial or intraspinal process. Relative contraindications include major surgery done less than 10 days previously, organ biopsy done less than 10 days previously, puncture of noncompressible vessels, recent cardiopulmonary resuscitation, recent gastrointestinal bleeding whose cause remains uncorrected, recent trauma, pregnancy, and uncorrected hemostatic defects.³² The patient's blood pressure should always be under control before thrombolytic therapy is considered.

More experience is necessary before we can define the exact role of thrombolytic therapy in treating completely occluded renal arteries and bypass grafts. Based on our early experience with three patients, thrombolysis appears promising and may be effective in preserving or restoring renal function in some patients affected by advanced atherosclerosis.

We believe thrombolysis should be attempted if the usual clues to renal salvageability are present and if insertion of a guide wire shows the thrombus to be soft. If the thrombus is hard and highly calcified, it would be best to seek other forms of interventional therapy.

ACKNOWLEDGMENT

We wish to thank Micheline Watt for her expert secretarial assistance in the preparation of this manuscript.

REFERENCES

- Olin JW, Melia M, Young JR, et al. Prevalence of atherosclerotic renal artery stenosis in patients with generalized atherosclerosis. Unpublished.
- Sos TA, Pickering TG, Sniderman K, et al. Percutaneous transluminal renal angioplasty in renovascular hypertension due to atheroma or fibromuscular dysplasia. *N Engl J Med* 1983; **309**:274-279.
- Madias NE, Kwon OJ, Millan VG. Percutaneous transluminal renal angioplasty: a potentially effective treatment for preservation of renal function. *Arch Intern Med* 1982; **142**:693-697.
- Hayes JM, Risius B, Novick AC, et al. Experience with percutaneous transluminal angioplasty for renal artery stenosis at the Cleveland Clinic. *J Urol* 1988; **139**:488-492.
- Novick AC, Straffon RA, Stewart BH, Gifford RW, Vidt D. Diminished operative morbidity and mortality in renal revascularization. *JAMA* 1981; **246**:749-753.
- Olin JW, Vidt DG, Gifford RW Jr, Novick AC. Renovascular disease in the elderly: an analysis of 50 patients. *J Am Coll Cardiol* 1985; **5**:1232-1238.
- Novick AC, Ziegelbaum M, Vidt DG, et al. Trends in surgical revascularization for renal artery disease: ten years experience. *JAMA* 1987; **257**:498-501.
- Dean RH, Keyser JE 3d, Dupont WD, Nadeau JH, Meacham PW. Aortic and renovascular disease: factors affecting the value of combined procedures. *Ann Surg* 1984; **200**:336-344.
- Tarazi RY, Hertzner NR, Beven EG, O'Hara PJ, Anton GE, Krajewski LP. Simultaneous aortic reconstruction and renal revascularization: risk factors and late results in eighty-nine patients. *J Vasc Surg* 1987; **5**:707-714.
- O'Mara CS, Maples MD, Kilgore TL, et al. Simultaneous aortic reconstruction and bilateral renal revascularization: is this a safe and effective procedure? *J Vasc Surg* 1988; **8**:357-366.
- Gifford RW Jr. Evaluation of the hypertensive patient: emphasis on detecting curable causes. *Milbank Memorial Fund Q* 1969; **37**:170-186.
- Wollenweber J, Shepes SG, Davis GD. Clinical course of atherosclerotic renovascular disease. *Am J Cardiol* 1968; **21**:60-71.
- Stewart BH, Dustan HP, Kiser WS, et al. Correlation of angiography and natural history in evaluation of patients with renovascular hypertension. *J Urol* 1970; **104**:231-238.
- Schreiber MJ, Pohl MA, Novick AC. The natural history of atherosclerotic and fibrous renal artery disease. *Urol Clin North Am* 1984; **11**:383-392.
- Hertzner NR, Young JR, Kramer JR, et al. Routine coronary angiography prior to elective aortic reconstruction: results of selective myocardial revascularization in patients with peripheral vascular disease. *Arch Surg* 1979; **114**:1336-1344.
- Hertzner NR, Beven EG, Young JR, et al. Coronary artery disease in peripheral vascular patients: a classification of 1000 coronary angiograms and results of surgical management. *Ann Surg* 1984; **199**:223-233.
- Dean RH, Callis JT, Smith BM, Meacham PW. Failed percutaneous transluminal renal angioplasty: experience with lesions requiring operative intervention. *J Vasc Surg* 1987; **6**:301-307.
- Olin JW, Wholey M. Rupture of the renal artery nine days after percutaneous transluminal angioplasty. *JAMA* 1987; **257**:518-520.
- Puiglaert CBA, Mali WB, Rosenbusch G, et al. Delayed rupture of renal artery after percutaneous transluminal angioplasty. *Radiology* 1986; **159**:635-637.
- Schefft P, Novick AC, Stewart BH, Straffon RA. Renal revascularization in patients with total occlusion of the renal artery. *J Urol* 1980; **124**:184-186.
- Zinman L, Libertino JA. Revascularization of chronic totally occluded renal artery with restoration of renal function. *J Urol* 1977; **118**:517-521.
- Alexander RH, Brient BW. Revascularization of kidneys with totally occluded renal arteries. *South Med J* 1982; **75**:1087-1092.
- McNamara TO, Fischer JR. Thrombolysis of peripheral arterial and graft occlusions: improved results using high-dose urokinase. *AJR* 1985; **144**:769-775.
- Katzen BT, Edwards KC, Albert AS, van Breda A. Low-dose direct fibrinolysis in peripheral vascular disease. *J Vasc Surg* 1984; **1**:718-722.
- van Breda A, Robison JC, Feldman L, et al. Local thrombolysis in the treatment of arterial graft occlusions. *J Vasc Surg* 1984; **1**:103-112.
- Graor RA, Risius B, Denny KM, et al. Local thrombolysis in the treatment of thrombosed arteries, bypass grafts, and arteriovenous fistulas. *J Vasc Surg* 1985; **2**:406-414.
- van Breda A, Katzen BT, Deutsch AS. Urokinase versus streptokinase in local thrombolysis. *Radiology* 1987; **165**:109-111.
- McNamara TO, Bomberger RA. Factors affecting initial and 6 month patency rates after intraarterial thrombolysis with high dose urokinase. *Am J Surg* 1986; **152**:709-712.
- Graor RA, Risius B, Lucas FV, et al. Thrombolysis with recombinant human tissue-type plasminogen activator in patient with peripheral artery and bypass graft occlusions. *Circulation* 1986; **74**:115-120.
- Graor RA, Risius B, Young JR, et al. Thrombolysis of peripheral arterial bypass grafts: surgical thrombectomy compared with thrombolysis: a preliminary report. *J Vasc Surg* 1988; **7**:347-355.
- Olin JW, Graor RA. Thrombolytic therapy in the treatment of peripheral arterial occlusions. *Ann Emer Med* 1988; **17**:1210-1215.
- Stewart JH, Olin JW, Graor RA. Thrombolytic therapy: a review (part 2 of 2). *Cleve Clin J Med* 1989; **56**:290-296.
- Abrams HL, Cornell SH. Patterns of collateral flow in renal ischemia. *Radiology* 1965; **84**:1001-1012.
- Gifford RW Jr, McCormack LJ, Poutasse EF. The atrophic kidney: its role in hypertension. *Mayo Clin Proc* 1965; **40**:834-852.
- Cronan JJ, Dorfman GS. Low dose thrombolysis: a nonoperative approach to renal artery occlusion. *J Urol* 1983; **130**:757-759.
- Gagnon RF, Horosko F, Herba MJ. Local infusion of low-dose streptokinase for renal artery thromboembolism. *Can Med Assoc J* 1984; **131**:1089-1091.
- Skinner RE, Hefty T, Long TD, et al. Recovery of renal function in a solitary kidney after intra-arterial thrombolytic therapy. *J Urol* 1989; **141**:108-110.