

RE: HYPOCOMPLEMENTEMIC URTICARIAL VASCULITIS IN A PATIENT WITH CHRONIC OBSTRUCTIVE PULMONARY DISEASE AND PULMONARY SILICOSIS

From: C. VAUGHN STRIMLAN, MD
 JOSEPH LIPUT, MD
 MICHAEL STEVENS, MD
 Department of Medicine
 Divisions of Dermatology and Pulmonary Disease
 Mercy Hospital of Pittsburgh
 Pittsburgh, Pennsylvania 15219

The association of hypocomplementemic urticarial vasculitis with chronic obstructive pulmonary disease is well documented.^{1,2} Recently, we evaluated a patient with hypocomplementemic urticarial vasculitis who developed chronic obstructive pulmonary disease and pulmonary silicosis.

A 55-year-old man was hospitalized complaining of severe shortness of breath at rest. He had had progressive dyspnea on exertion for approximately 18 months before admission. He denied hemoptysis, wheezing, or chest pains. He had an 80 pack-year smoking history. He had worked for 30 years as a painter and sandblaster. Occupational exposures included paint fumes, sand, and silica dust. His medical history was significant for hypocomplementemic urticarial vasculitis since 1978. At that time, the patient was evaluated for a nine-month history of urticaria and a 20-year history of arthralgias. There were diffuse urticarial lesions of the trunk, hands, arms, and legs. His chest radiograph was normal in 1978. There was no history of Raynaud's phenomenon, photosensitivity, seizures, or pleuritic chest pains. There was no history of angioedema or family history of urticaria. Physical examination revealed urticarial lesions of the trunk, hands, arms, and legs. A skin biopsy specimen was obtained of a left upper back lesion and findings were consistent with hypocomplementemic urticarial vasculitis. The epidermis showed a subepidermal bulla. Within the dermis there was a dense infiltrate of neutrophils and eosinophils within the walls of vascular spaces, consistent with leukocytoclastic angiitis. Another skin biopsy specimen was examined by direct immunofluorescence and showed granular deposits of C3 along the dermal-epidermal junction and in blood vessels. No fi-

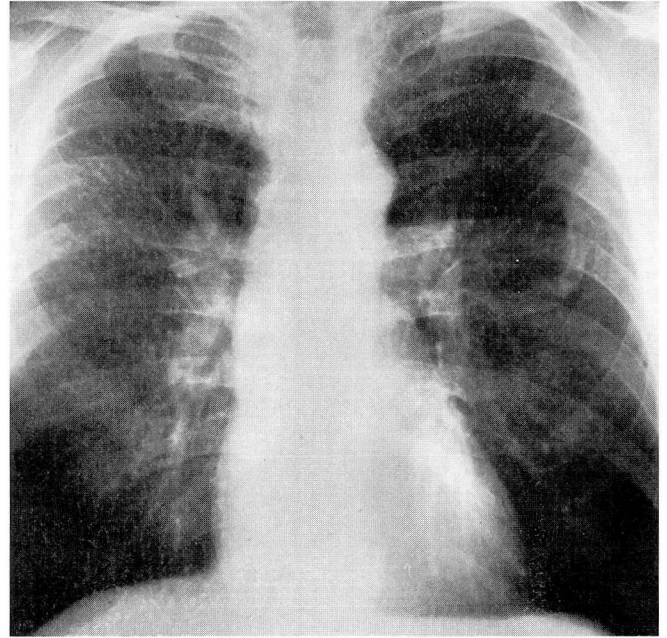


FIGURE 1. Chest radiograph showing silicosis.

brin or immunoreactants were detected. The C3 level was 68 $\mu\text{g/mL}$ (normal range 120–170 $\mu\text{g/mL}$). The C4 level was 10.8 $\mu\text{g/mL}$ (normal range 14–51 $\mu\text{g/mL}$). Other laboratory studies were as follows: RA titer 1:20; ANA, RPR, and HBsAg negative; sedimentation rate 17 mm/hr; CBC 9,300 white blood cells and a normal differential white count; hemoglobin 15 g/dL; hematocrit 47%; urinalysis and multiphasic screen normal; C1 prime esterase inhibitor activity 50% of normal control; and cryoglobulins trace-positive.

Physical examination revealed a middle-aged man in respiratory distress. Urticarial lesions were found on the trunk, arms, and legs. Diffuse wheezes were heard bilaterally. The remainder of the physical examination was unremarkable. The chest radiograph showed a tortuous aorta. Cardiac silhouette was normal. There was a diffuse fine micronodular pattern in the upper four lung zones consistent with an ILO International Pneumoconiosis Classification of 1/1 p/p in four upper zones. Findings on the chest radiograph were compatible with simple silicosis (Figure 1). Pulmonary function studies revealed a moderately severe obstructive ventilatory

pattern. The forced vital capacity was 2.62 L or 64% of predicted normal. The FEV₁ was 1.62 L per second or 51% of predicted normal. The % FEV₁ was 62% of predicted normal, and the % FEV₃ was 96% of predicted normal. The FEF_{25%-75%} was 0.92 L/sec or 29% of predicted normal. Arterial blood gases at rest, breathing room air, showed moderately severe arterial hypoxemia. The pO₂ was 64 mmHg, pCO₂ 42 mmHg, pH 7.42, and O₂ saturation 93%. The patient was treated with low-flow oxygen therapy, intravenous and oral theophylline preparations, and inhaled bronchodilators. Prednisone and naproxen were administered for the cutaneous and joint manifestations. Improvement was rapid, and the patient was discharged two days after admission on a regimen of oral bronchodilator medications.

Follow-up pulmonary function studies two years later showed further airway obstruction. The forced vital capacity was 1.48 L or 51% of predicted normal. The FEV₁ was 0.70 L/sec or 33% of predicted normal. The % FEV₁ was 35% and the % FEV₃ 64% of predicted normal. The FEF_{25%-75%} was 0.28 L/sec or 7% of predicted normal. The patient's clinical course was one of progressive respiratory insufficiency, and he subsequently died of respiratory failure.

Schwartz et al¹ reported 16 patients with hypocomplementemic urticarial vasculitis. Of these 16 patients, eight developed chronic obstructive lung pulmonary disease at a young age despite low total pack years of smoking history. The authors inferred that the development of chronic obstructive pulmonary disease was probably due to a combination of cigarette smoking and the underlying vasculitic disease. Zeiss et al² reported on five patients with hypocomplementemic

vasculitic urticarial syndrome. Two patients had pulmonary problems; one had bronchial asthma and the other, a 47-year-old woman, died of respiratory failure and autopsy findings revealed pulmonary emphysema. Falk³ reported a case of severe chronic obstructive pulmonary disease in a woman with a chronic idiopathic urticarial vasculitis and severe dyspnea. Pulmonary function studies revealed a very severe obstructive ventilatory pattern. An open lung biopsy confirmed acute neutrophilic vasculitis involving pulmonary venules; the pattern was similar to that in a skin biopsy specimen from an urticarial lesion. These case reports suggest an association between hypocomplementemic urticarial vasculitis and chronic obstructive pulmonary disease.

The pathogenesis of pulmonary silicosis has been well documented in numerous review articles.⁴⁻⁶ The silica phagocytized by pulmonary alveolar macrophages probably releases free radicals and lysosomal enzymes. The persistence of silica in lung tissue by these mechanisms may result in inflammatory changes, parenchymal lung damage, and fibrosis.

Our patient had a well-documented combination of hypocomplementemic urticarial vasculitis, chronic obstructive pulmonary disease, and simple silicosis. We believe that his chronic obstructive pulmonary disease was produced by a combination of the destructive effects of cigarette smoking and vasculitis. The development of pulmonary silicosis may be related to the vasculitis and the decreased pulmonary clearance mechanisms seen with severe chronic obstructive pulmonary disease. The precise etiologic mechanisms leading to this combination of immune disorders in this particular patient remain unclear.

REFERENCES

1. Schwartz HR, McDuffie FC, Black LF, Schroeter AL, Conn DL. Hypocomplementemic urticarial vasculitis: association with chronic obstructive pulmonary disease. *Mayo Clin Proc* 1982; **57**:231-238.
2. Zeiss CR, Burch FX, Marder RJ, Furey NL, Schmid FR, Gewurz H. A hypocomplementemic vasculitic urticarial syndrome: report of four new cases and definition of the disease. *Am J Med* 1980; **68**:867-875.
3. Falk DK. Pulmonary disease in idiopathic urticarial vasculitis. *J Am Acad Dermatol* 1984; **11**:346-352.
4. deShazo RD. Current concepts about the pathogenesis of silicosis and asbestosis. *J Allergy Clin Immunol* 1982; **70**:41-49.
5. Doll NJ, Stankus RP, Barkman HW. Immunopathogenesis of asbestosis, silicosis, and coal workers' pneumoconiosis. *Clin Chest Med* 1983; **4**:3-14.
6. Ziskind M, Jones RN, Weill H. Silicosis. *Am Rev Resp Dis* 1976; **113**:643-665.