

Pathology of childhood epilepsies

HEINZE-JOACHIM MEENCKE, MD

Infantile spasms (West syndrome, Lennox-Gastaut syndrome), childhood absence epilepsy (pyknolepsy) and juvenile myoclonic epilepsy (impulsive petit mal) all belong to those epilepsies that have somewhat imprecisely also been called childhood epilepsies.

These generalized epilepsies have common biologic parameters and common features in the symptomatology of seizures. There are, however, clearly defined differential criteria. The comparable genetic background, the marked age dependency, and electroencephalographic (EEG) criteria belong to the common biologic parameters. Common features of seizure symptoms are bilaterality, preponderance of trunk motor symptoms, suddenness of commencement and termination, and lack of vegetative phenomena as well as sensory and psychic experiences. These common features contrast with the differential criteria, which have, in each case, a distinctive age of onset and a specific syndrome-related symptomatology. Furthermore, there are differences in the natural course and the therapeutic response of the different generalized epilepsies.

There are several neuropathologic reports about epilepsies in general, with a broad range of nonspecific findings concerning etiology; but there are only a few syndrome-related neuropathologic studies. The discrepancy between clinical relevance and frequency of generalized epilepsy syndromes, and the small number of pathologic studies is striking (Table 1).

Nearly 40 studies of infantile spasms have been made, with a total of about 160 cases, but there are only four studies of the Lennox-Gastaut syndrome with 17 cases, three reports of childhood absence epilepsy with 14 cases, and two reports of juvenile myoclonic

epilepsy with four cases.

A lack of sufficient neuropathologic data leads to the assumption that the brain is unaffected—e.g., in primary (idiopathic) generalized epilepsies—on the basis mainly of neurologic and EEG findings. A preliminary study of generalized epilepsies using magnetic resonance imaging shows, however, a high rate of atrophy, even in the so-called primary (idiopathic) generalized epilepsies (Table 2).

These extratemporal atrophies are predominantly localized in the parietal region. There seems to be no correlation with occurrence or frequency of generalized tonic-clonic seizures.

This paper relates the neuropathologic findings of our own studies and those in the literature to the different syndromes. It is intended to define from the pathologic point of view the common features and differentiating criteria of these epilepsies with age-dependent seizures.

INFANTILE SPASMS (WEST SYNDROME)

In our study of 24 brains of children who suffered from West syndrome, the clinical seizure syndrome was very narrowly defined.¹

Age at onset ranged from 2 to 12 months (average age, 3.5 months). As expected, we noted a broad spectrum of morphologic changes. Metabolic diseases were found in some patients, as well as various developmental disturbances ranging from severe maldevelopments, such as encephalocele, to very slight disturbances of the neural architecture, termed microdysgenesis (Figure 1).

Among the ischemic lesions, we found a large variety of changes, including circumscribed areas of complete necrosis, which appeared in some cases as porencepha-

Neurologische Klinik, Universitätsklinikum Rudolf-Virchow, Standort Charlottenburg, Freie Universität Berlin, West Germany.

TABLE 1
NEUROPATHOLOGICAL STUDIES OF PATIENTS WITH
GENERALIZED EPILEPSIES WITH AGE-DEPENDENT SEIZURES

Syndrome	Number of reported studies	Number of reported cases	Number in current study
Infantile spasms	40	163	24
Lennox-Gastaut syndrome	4	17	12
Childhood absence epilepsy (pyknolepsy)	3	14	12
Juvenile myoclonic epilepsy (impulsive petit mal)	2	4	3

TABLE 2
MORPHOLOGICAL FINDINGS WITH MAGNETIC RESONANCE
TOMOGRAPHY IN GENERALIZED EPILEPSIES

	n	Neocortical atrophy		Cerebellar atrophy
		Localized	Diffuse	
Juvenile myoclonic epilepsy	16	8	3	3
Childhood absence epilepsy	7	5	2	1
Lennox-Gastaut syndrome	5	3	—	2

TABLE 3
NEUROPATHOLOGICAL FINDINGS IN PATIENTS WITH
INFANTILE SPASMS, AND THE TIME OF THEIR
MANIFESTATION

Embryofetal lesions (n=6)

- Microdysgenesis (n=3)
- Pachygyria
- Encephalocel
- Metabolic

Embryofetal and peri/postnatal lesions (n=10)

- Microdysgenesis (n=9)
- Heterotopia
- Micrencephalia
- Microgyria
- Neuronal necrosis
- Scars
- White matter sclerosis
- Marmorate state
- Cerebellar atrophies

Peri/postnatal lesions (n=8)

- Neuronal necrosis
- Scars
- Lobular sclerosis
- Porencephalia
- White matter sclerosis
- Cerebellar atrophies

lia, lobular sclerosis, ulegyria, and selective neuronal necrosis, either localized or widespread, slight or severe (Table 3).

That ischemic lesions are among the causative factors of West syndrome is even shown in the selective

neuronal necrosis, which in particular has been interpreted mainly as a consequence of seizures. No correlation was found between tonic-clonic seizures and selective neuronal necrosis (Table 4).

Furthermore, no correlation was noted between duration of hypsarrhythmia and selective neuronal necrosis (Table 5). This indicates that the pattern and extent of ischemic lesions are not influenced by the duration of the neurophysiologic activity itself.

On the other hand, it is remarkable that there appeared to be no correlation between the distribution pattern of the lesions and the distinct clinical course of West syndrome. Independent of the type of seizure, at the beginning of the epilepsy and during the transition to myoclonic atstatic petit mal, we noted a heterogeneous distribution pattern of ischemic lesions of the neocortex, hippo-

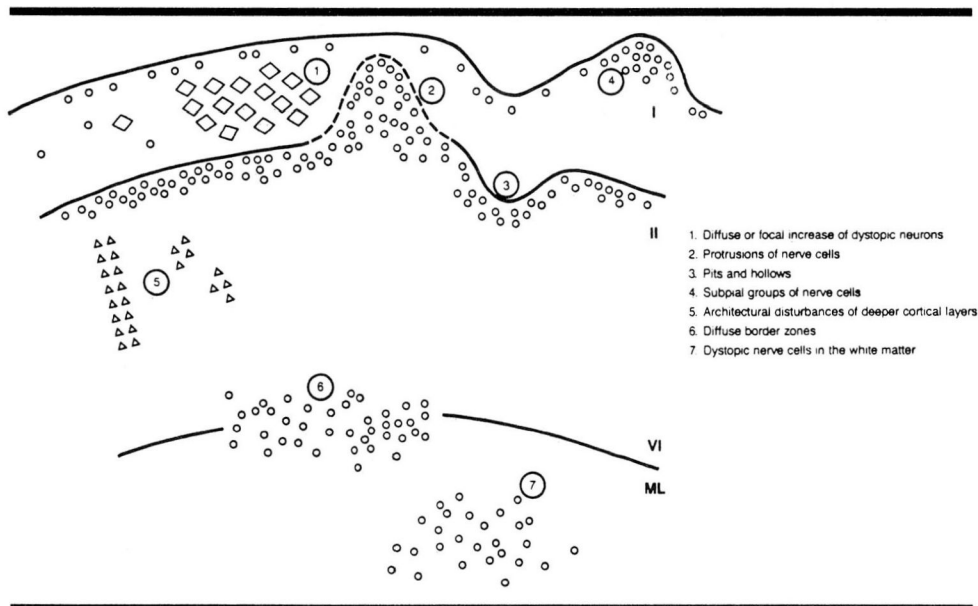


FIGURE 1. Heteromorphism of the microdysgenesis.

campus, thalamus, and cerebellum (Table 6).

In spite of the confused manifold neuropathologic findings, three main categories can be perceived, if one looks at time of manifestation. One group is associated with exclusively embryofetal lesions, a second group with a combination of embryofetal and peri/postnatal lesions, and a third with only peri/postnatal changes. In our material, a third of the patients have early embryofetal lesions, which can be morphologically demonstrated. If our arrangement of lesions according to time of manifestation is applied to the cases reported in the literature, we find the same range within the group of isolated peri/postnatal lesions, but a lower number (approximately 50%) of embryofetal lesions (Table 7).

Moreover, there is a high proportion of unchanged brains (11%). This is quite contrary to our observations and might be due to the fact that most of the investigators are not sure about the relevance of microdysgenesis. But in conclusion, it is remarkable that one half to two thirds of all cases have identifiable embryofetal lesions.

From our material, eight cases had no histologically identifiable developmental disturbances, and seven of these eight had possible prenatal risk factors. Lack of morphologic proof in these cases could be due to the severity of ischemic lesions being significantly higher in the group with only peri/postnatal lesions as compared with the group with isolated embryofetal lesions (Table 8).

The severity of the ischemic changes could prevent slight neuroarchitectural disturbances from being observed.

Furthermore, this group has a special clinical aspect. The severe ischemic lesions seem to have had a dominant influence on the time of manifestation of West syndrome. The age at onset of seizures for the two groups with embryofetal lesions is significantly earlier than in the group with ischemic lesions (Table 9).

LENNOX-GASTAUT SYNDROME

We were able to study 12 brains of patients with Lennox-Gastaut syndrome. The age at onset of seizures ranged from 1.5 to 5 years (average, 3.1 years).² Only

TABLE 4
RELATIONSHIP BETWEEN GENERALIZED TONIC-CLONIC SEIZURES AND THE OCCURRENCE OF "EPILEPTIC LESIONS" (SELECTIVE NEURONAL NECROSIS)

Stem	n	Patients with selective neuronal necrosis			
		Ammon's horn	Thalamus	Cerebellum	Brain
Patients with generalized tonic-clonic seizures	17	8	8	6	3
Patients without generalized tonic-clonic seizures	7	3	3	1	2

TABLE 5
DURATION OF HYPARRHYTHMIA, AND FREQUENCY AND SEVERITY OF "EPILEPTIC LESIONS" (SELECTIVE NEURONAL NECROSIS, EPN)

Duration	Age at death (months)	Severity of EPN	Topography of EPN
12 months	78	0	—
	42	++	AH, TH
	42	(+)	TH
6-12 months	10	0	—
	23	++	AH, TH, CB
	15	(+)	BS
2-6 months	10	0	—
	11	(+)	AH
	11	++	AH

Grade: 0=nothing; (+)=mild; +=moderate; ++=severe
AM=Ammon's horn; TM=thalamus; CB=cerebellum; BS=brain stem

TABLE 6
DISTRIBUTION OF SELECTIVE NEURONAL NECROSIS IN PATIENTS WITH INFANTILE SPASMS AND DIFFERENT CLINICAL COURSES

	NC	AH	TH	CB
GM → IS → MA	X		X	X
IS → GM → MA	X		X	X
IS	X		X	X
GM → IS → MA		X	X	X
BNS → GM		X	X	X
GM → BNS	X	X	X	
BNS → GM → MA	X	X	X	

NC=neocortex; AH=Ammon's horn; TH=thalamus; CB=cerebellar cortex; GM=grand mal (generalized tonic-clonic) seizures; IS=infantile spasms; MA=myoclonic-astatic seizures; X=affected region

a few neuropathologic reports of the Lennox-Gastaut syndrome have been published at the present time. From the clinical point of view, prenatal etiologic

TABLE 7
DISTRIBUTION OF THE MANIFESTATION TIME OF THE PATHOLOGICAL CHANGES IN WEST SYNDROME

	%	
	107 cases ^{16,18-54}	24 cases ¹
With embryofetal lesions	44	25
With embryofetal and peri/postnatal lesions	7	42
SUBTOTAL	(51)	(67)
With peri/postnatal lesions	38	33
With no pathologic changes	11	—

TABLE 8
SEVERITY OF ISCHEMIC LESIONS IN PATIENTS WITH INFANTILE SPASMS

Severity of ischemic lesions	No. patients with only selective neuronal necrosis	No. patients with microdysgenesis and selective neuronal necrosis
Grade 4 (most severe)	2	1
Grade 3	5	2
Grade 2	1	3
Grade 1 (least severe)	0	4

Difference between groups = $P \leq 0.025$.

TABLE 9
TIME OF ONSET OF LESIONS AND INFANTILE SPASMS

Age of onset (month)	Group I	Group II	Group III
	No. embryofetal lesions (n=6)	No. embryofetal and peri/postnatal lesions (n=10)	No. of peri/postnatal lesions (n=8)
0-4	1	1	—
2-4	5	6	—
4-6	—	2	3
6-8	—	1	2
8-10	—	—	2
10-12	—	—	1

$P > 0.1$ (not significant) for groups I and II, $P \leq 0.01$ (significant) for groups II and III.

factors were found in 15%. In most cases, severe brain pathology was found in this group, including tuberous sclerosis, cerebellar myoclonic dysenergia, Reese syndrome, puerperal eclampsia, cataracta congenita, chromosome anomalies, and metabolic diseases.

Perinatal brain lesions were found in 20% of patients who had birth trauma, asphyxia, and jaundice of

newborns. Postnatal brain lesions were seen in 15% with encephalitis, unspecific encephalopathies, and degenerative diseases. In an additional 30% to 40% of patients, symptomatic etiology was assumed without a clear-cut etiologic indication in each individual case.

Severe brain changes and metabolic diseases were not found in our group. Analysis shows that 10 of 12 brains had acute or chronic ischemic lesions (Table 10).

The cerebellum was affected in all these cases. Five patients had additional lesions. Three of these had cardiac arrest and reanimation, and one patient had a chronic meningoencephalitis with neocortical scars due to extracerebellar lesions. The different ages of the lesions indicated their different etiologies. In one case, simultaneous cerebellar and extracerebellar lesions suggested a perinatal origin, which correlated with a history of difficult delivery.

A detailed analysis of type, distribution, and age of the cerebellar lesions showed in four cases a lobular atrophy and in six cases cerebellar atrophy of the Purkinje cell type (Table 11).

The lobular atrophies showed a different phylogenetic pattern, with involvement of neocerebellar and archicerebellar parts. Atrophy of the Purkinje cell type was predominantly located within the neocerebellum.

The striking frequency of cerebellar atrophy in this syndrome, which was observed neither in the primary generalized epilepsies nor in the West syndrome, needs to be examined further in respect to etiology. There seemed to be no correlation with grand mal seizures, nor with phenytoin intoxication.

The neocerebellar Purkinje cell atrophy could indicate an inborn cerebellar atrophy. Psychomotor retardation, a characteristic of inborn atrophies, was seen in five out of six of our patients. In spite of these clinical observations and the phylogenetic pattern, the atrophies in our patients seemed not to be congenital. In general, inborn atrophy shows a macroscopically visible hypoplasia, which was not observed in these cases.

Viana and coworkers³ reported on three cases of Lennox-Gastaut syndrome that showed diffuse Purkinje cell atrophy; two of these revealed additional lobular atrophies. One case from De Biase and Guaraldi⁴ showed a prominent cerebellar hemiatrophy. It is remarkable that the few additional cases reported in the literature also had cerebellar lesions. Cerebellar pathology appears to be a prominent feature of this syndrome.

Nine of 12 cases had developmental disturbances. Seven of these had microdysgenesis, mainly with a diffuse increase of nerve cells in the molecular layer. More severe disturbances of deeper layers, as shown in

TABLE 10
PATHOLOGICAL FINDINGS IN 12 PATIENTS WITH LENNON-GASTAUT SYNDROME

Case	Brain weight(g)	Hypoxic-vascular lesions								CB		Microdysgenesis	Malformation
		NC	AH	TH	D	M	P	MO	CC	CN			
1	1210											+	
2	1220								+				
3	1080								+				+
4	1020							+	+	+			
5	1440							+	+			+	
6	1190							+	+			+	
7	1600	+	+	+	+				+				
8	1000	+	+						+				
9	1090		+					+	+	+			+
10	1265	+	+					+	+				
11	1235											+	
12	1400	+						+	+	+		+	

NC=neocortex
 AH=Ammon's horn
 TH=thalamus
 D=other diencephalon
 M=mesencephalon
 P=pons
 MO=medulla oblongata
 CB=cerebellum
 CC=cerebellar cortex
 CN=cerebellar nuclei

West syndrome, could not be demonstrated in this syndrome. Only one further case had nodular heterotopias, and one case had microencephaly. Three fourths of the cases had lesions that were related to the embryofetal period, but only four cases had a history of difficult pregnancy or a family history of epilepsy.

PRIMARY GENERALIZED EPILEPSIES

The common clinical feature of the two syndromes with age-dependent seizures, discussed in this article, is tonic-clonic seizures upon awakening. Twelve patients had childhood absence epilepsy with onset at a mean

TABLE 11
TYPE, TOPOGRAPHY, AND AGE OF CEREBELLAR LESIONS IN PATIENTS WITH LENNON-GASTAUT SYNDROME

	N	Topography	Acute/ subacute	Chronic
Lobular atrophy	2	neocerebellum		2
	1	archicerebellum		1
	1	diffuse	1	
Purkinje cell atrophy	6	neocerebellum	1	5

age of 7.5 years. Three cases had juvenile myoclonic epilepsy (impulsive petit mal) with onset at a mean age of 15.5 years.^{5,6}

Neuropathologic study showed normal brain weights. Four patients had hypoxic vascular lesions, two after cardiac arrest and two after severe arteriosclerotic changes in basal vessels of the brain. Two patients had systematic paraneoplastic cerebellar atrophies. Atrophy of unknown origin affecting the caudate nucleus was correlated with an extrapyramidal syndrome.

The most remarkable finding was microdysgenesis in 13 of 15 patients (Table 12). In two cases, the quality of the material did not permit diagnosis.

A full range of microdysgenesis has been shown in West syndrome (Figure 1). In primary generalized epilepsies, a dominant feature was the diffuse increase of neuron density with some local protrusions and diffuse cortical borders. Deeper cortical layers were not affected. Only two patients had a striking columnar architecture of the extratemporal cortex. Cohen⁷ and Bridge⁸ reported no findings in their two cases. Janz and Neimanis⁹ reported one case with juvenile myoclonic epilepsy and grand mal of awakening. They described widespread ischemic lesions, which might be consequences of cardiac arrest, and were the first to discuss developmental disturbances in this syndrome, describing dystopic Purkinje cells in the cerebellum.

In summary, the brains in primary generalized epilepsies were not unchanged. Slight neuroarchitectural disturbances were predominant. It was remarkable that no case had seizure-related ischemic lesions despite a high frequency of seizures in some cases.

EMBRYOFETAL ETIOLOGY AND MICRODYSGENESIS

Embryofetal etiologic factors correlating with microdysgenesis were prominent findings in generalized epilepsies. The microdysgenesis qualitatively exhibited a

TABLE 12
NEUROPATHOLOGICAL FINDINGS IN PATIENTS WITH PRIMARY GENERALIZED (IDIOPATHIC) EPILEPSIES

	Age	Brain weight(g)	Microdysgenesis	Malformation	Ischemic lesions	Systematic atrophy	Trauma
Childhood absence epilepsy							
1	17	1470	+				
2	23	1400	+				
3	23	1470	+				
4	25	1295	+				
5	39	1410	+			+	
6	41	1830	+				
7	41	1490	+				+
8	47	1330	+	+		+	
9	57	1390	+		+		
10	71	1250	+	+		+	
11	72	1130	+	+	+		+
12	72	1450			+		
Juvenile myoclonic epilepsy							
13	22		+				
14	32				+		
15	50	1350	+				

wide spectrum of changes, ranging from fine to diffuse increases in nerve cell density of the stratum moleculare and white matter, to marked protrusions, with a disturbance of the architecture of underlying layers of the cortex (Figure 1). They seemed to be divided differently in the separate syndromes. The significance of microdysgenesis is very controversial.^{10,11} This is due, among other factors, to the fine and diffuse changes in cell density, which are difficult to delineate. A morphometric study of nerve cell density was therefore carried out in order to get a valid picture of these fine architectural changes. Nerve cell density of the stratum moleculare of the gyrus frontalis superior (area 9), the gyrus temporalis superior (area 22), and the gyri occipitales (area 18) was calculated for all four syndromes. The cell density of the white matter of the gyrus frontalis inferior (areas 10, 45, 46) was also calculated for the primary generalized epilepsies. The morphometric methods have been described in several published studies.^{6,12,13}

Nerve cell density shortly after birth was about 15,000 cells per mm³. During the first two years of life, the number of cells decreased markedly. After the second decade, there followed a period of constant cell density, with a mean of 5000 cells per mm³, which decreased slightly in the seventh and eighth decades (Figure 2).

The first marked decrease in cell density corresponded to a reciprocal increase in brain weight (Figure 3) and cortical volume (Figure 4).

Increase in density was thus due to development of

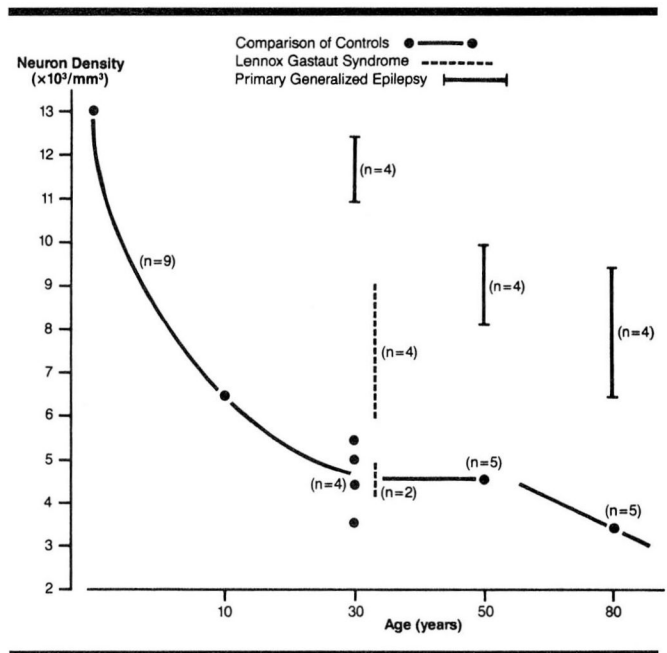


FIGURE 2. Neuron density in the stratum moleculare (frontal lobe).

the neuronal surface/outgrowth of the dendrites and glial neuropils. The renewed slight decrease in density during the last decade of life was partly a result of the differing water-binding capacity of the brain. This latter is also age-dependent, and it results in different changes in volume during processing (fixation, embed-

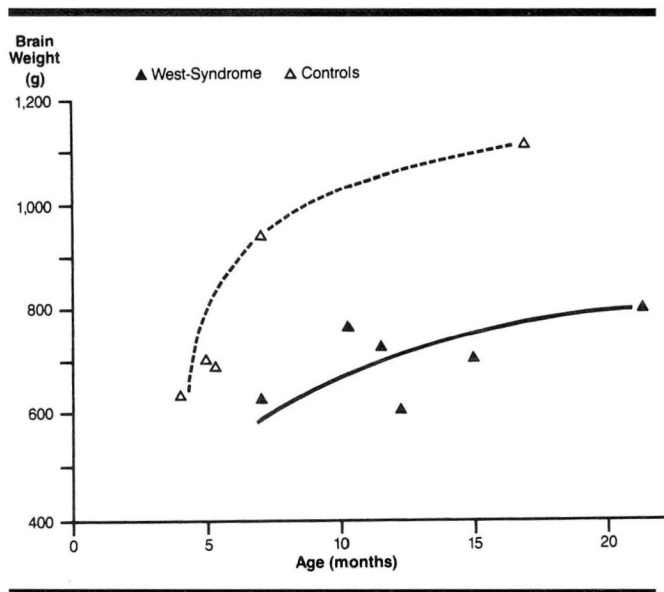


FIGURE 3. Increase of brain weight with age in controls and in patients with West syndrome.

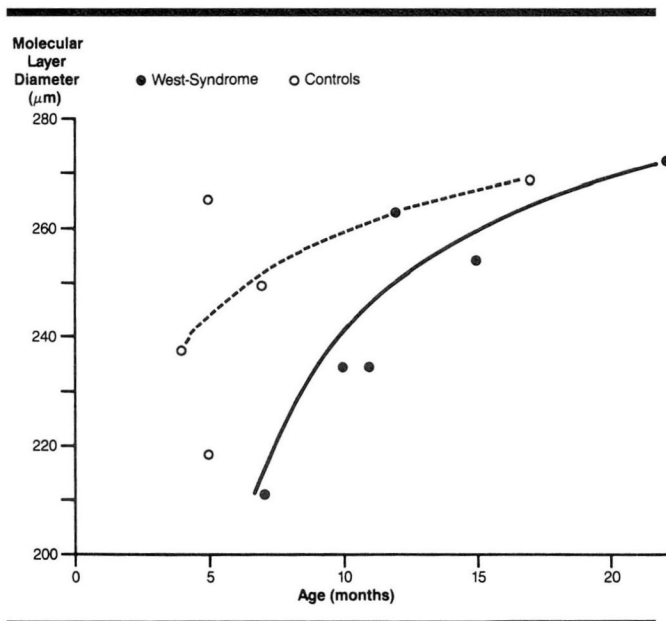


FIGURE 4. Increase of the diameter of the stratum moleculare in patients with West syndrome and in controls.

ding, staining).

There are only two previous reports with counts of the cell density of lamina I, made using the brains of middle-aged subjects. This could correspond to our phase during which the cell density was constant. Schlote¹⁴ reported 5000 cells per mm³ in the frontal cortex, without indicating the area more precisely. Haug et al¹⁵ found 4000 cells per mm³ in area 11. Therefore, the counts of our studies agree.

The group of the primary generalized epilepsies had a higher cell count in the stratum moleculare (Figure 2). Values in the third decade were twice as high as in controls of a corresponding age. Moreover, there was a notable difference in cell density as compared with that in controls, with density considered as dependent on age. Cases with primary generalized epilepsy had a decrease in density between the fourth and fifth decades, but not, as in the controls, between the fifth and eighth decades. This phenomenon could either be due to the greater vulnerability of dystopic neurons (and could thus be an expression of an earlier aging process) or it could be an expression of a delayed postmaturing effect. On the whole, the morphometric study confirmed that the cell density of primary generalized epilepsies is significantly higher than that in normal brains.

Because of the age distribution in patients with Lennox-Gastaut syndrome, only the third decade could

be studied. This group included four cases with a significant increase in nerve cells. Two cases had density values that lay in the range of those in the controls (Figure 2).

In evaluating cell density in patients with West syndrome, it must be realized that we are dealing with the developmental period in which there is a marked change in cell density depending on changes in brain weight and volume. The increase in brain weight and volume in patients with West syndrome was markedly less than that in controls of the same age (Figures 3 and 4), but the development of nerve cell density was not significantly different. The same marked decrease in density in the first two years of life was seen in the epilepsy group as well as the control group (Figure 5).

However, when the absolute cell count was recalculated from the different change in volume, a lower absolute cell count was found in patients with West syndrome. This finding and the fact that in this syndrome more frequent architectural disturbances of the deeper cortical layers are observed gives rise to special problems of etiology. First, the changes in brain volume, which correlated with a lower cell count, can in West syndrome be caused by early cell loss and retarded development of the neuronal surface. Indications of an impaired development have already been made by Huttenlocher.¹⁶ Second, the reduced cell

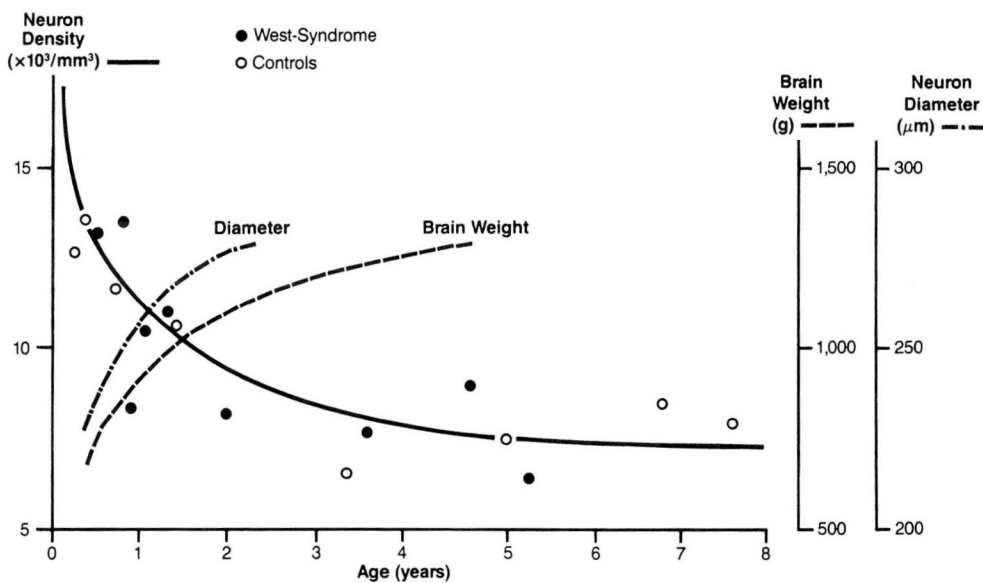


FIGURE 5. Neuron density, diameter and brain weight in the stratum moleculare (frontal lobe), in patients with West syndrome and in controls.

count in West syndrome could indicate a different, perhaps exogenous, etiology of brain changes, which could thus be differentiated from the etiology of cases with primary generalized epilepsies and some cases with Lennox-Gastaut syndrome.

Measurement of cell density in the white matter of the gyrus frontalis inferior likewise showed a significant increase in cell density in patients with primary generalized epilepsy, when compared with controls of the same age.¹²

Two areas with dystopic nerve cells (stratum moleculare and the subcortical white matter) can thus also be morphometrically ascertained (Figure 6).

Should dystopic neurons indicate disturbed migration and should a common etiopathologic factor be responsible, then the point in time when the pathologic influence has an effect should be between the fifth and seventh months.

How can differences in the expression of microdysgenesis between the West syndrome and the primary generalized epilepsies be explained? Wolf et al¹⁷ showed that there are two different mechanisms of cortical development. The predominant mechanism (the inside-outside principle) applies only to the excitatory golgi neuron (type I). On the other hand, the cortex is continuously populated by golgi type II neurons in, for example, nonpyramidal nerve cells, which

are inhibitory gamma aminobutyric acid (GABA)-ergic cells. According to their appearance and the measured values (i.e., size of nucleolus) of the neurons in cases with diffuse increase of density, these cells appear to be predominantly of the golgi II type. The origin of microdysgenesis seems thus to be influenced by two mechanisms that are possibly differently involved in the various epilepsy syndromes and can be an expression of different etiopathogenetic factors.

CONCLUSION

Summarizing the morphologic findings diagrammatically, we find secondary generalized epilepsies at one extreme, or pole, and primary generalized epilepsies at the other. We thus obtained a diagram with two anticlinal lines that cross each other (Figure 7).

The phenomenologic expression of a secondary or primary generalized epilepsy depends upon type and

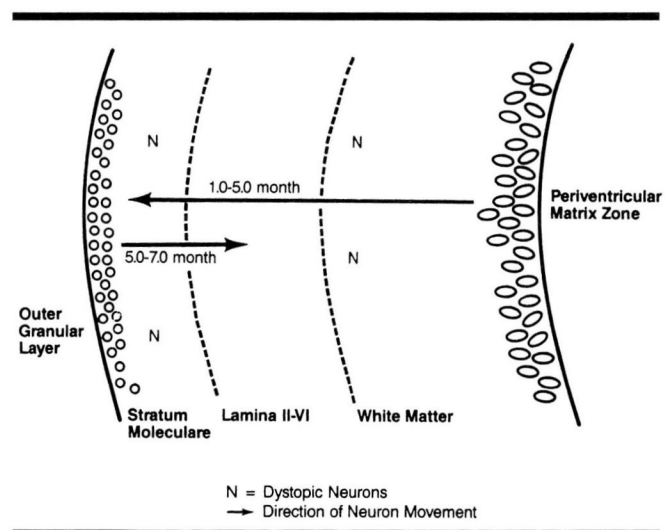


FIGURE 6. Position of dystopic neurons in patients with primary generalized epilepsies.

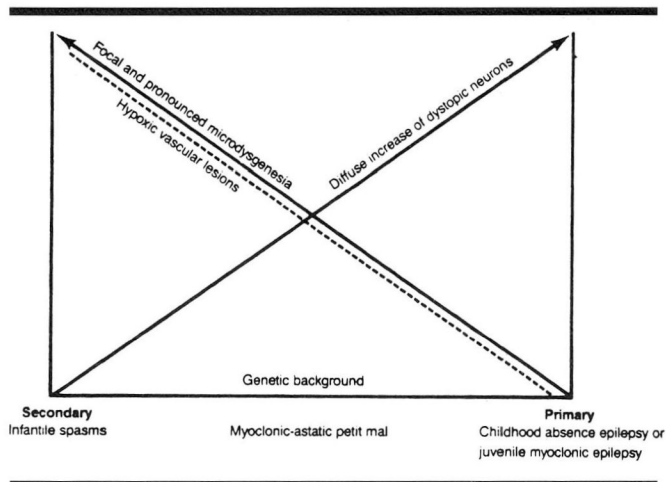


FIGURE 7. Morphology of generalized epilepsies in respect to etiology.

extent of microdysgenesis. We found diffuse nonpyramidal dystopic neurons most prominent in primary generalized epilepsy. On the other hand, more focal, deeper layers affecting developmental disturbances were seen in secondary generalized epilepsies. Parallel to the microdysgenesis runs the curve of causative exogenous hypoxic vascular lesions. It must be noted, however, that in individual cases, prenatal disturbances of development and peri/postnatal ischemic lesions can be complementary to each other.

The extent and quality of pathologic changes of the gray matter can determine the respective epilepsy syndrome. A fine disturbance of brain development (diffuse microdysgeneses) certainly permits late pene-

trance of genetic background. Severe microdysgenesis or ischemic lesions can be so predominant that the clinical seizure is manifested early and occurs in a form that corresponds with the biodevelopmental degree of maturity of the brain.

Our study has demonstrated developmental disturbances in the generalized epilepsies described. These disturbances were apparent from morphologic studies of the brain. Although these developmental disturbances were different in intensity, time of manifestation, and pathogenesis, the significance of developmental disturbances could not be denied in all four syndromes with age-related seizures. This observation supports the idea, based on clinical and neurophysiologic observations, that these epilepsies are nosological entities. The study also underscores the multifactorial causes of these epilepsies and the dependence of the various syndromes on the differing intensity of the morphologic changes. Thus microdysgeneses, as early embryofetal lesions, are certainly the most important condition for characterizing various age-dependent syndromes of the generalized epilepsies. Any correlation between genetic disposition and microdysgenesis remains an open question.

H. J. MEENCKE, MD
Neurologische Klinik
Universitätsklinikum Rudolf-Virchow
Standort Charlottenburg
Freie Universität Berlin
Spandauer Damm 130
D-1000 Berlin 19
West Germany

REFERENCES

1. Meencke HJ, Gerhard C. Morphological aspects of aetiology and the course of infantile spasms (West-Syndrome). *Neuropediatrics* 1985; **16**:59-66.
2. Meencke HJ, Veith G. Neuropathologische Aspekte des myoklonisch-astatischen Petit mal (Lennox-Syndrom). [In] Kruse R, ed. *Epilepsie* 84, Reinbek, Einhorn-Press, 1985, pp 305-313.
3. Viani F, Strada GP, Riboldi A, Manghi E, Rossotti V, Allegranza A: Aspetti neuropatologici della sindrome di Lennox-Gastaut: Considerazioni su tre casi. *Revista di Neurologia* 1977; **47**: 1-35.
4. De Biase G, Guaraldi GP. Sulle necrosi neuronali elettive in coao el epilepsia: atrofia del cervelletto e sindrome di lennox. *Arch Vecchi* 1970;**5**:56-81.
5. Meencke HJ, Janz D. Neuropathological findings in primary generalized epilepsy: A study of eight cases. *Epilepsia* 1984; **25**:8-21.
6. Meencke HJ. Vergleichend klinisch-neuropathologische Untersuchung generalisierter Epilepsien. Habilitationsschrift, Freie Universität Berlin, 1986.
7. Cohen R. A neuro pathological study of a case with petit al epilepsy. *Electroencephalogr Clin Neurophysiol* 1968; **24**:282.
8. Bridge EM. *Epilepsy and Convulsive Disorders in Children*. New York, McGraw Hill, 1949.
9. Janz D, Neimanis G. Clinico-anatomical study of a case of idiopathic epilepsy with impulsive-petit-mal and grand mal on awakening ("Aufwach-Grand mal"). *Epilepsia* 1961; **2**:225-269.
10. Meencke HJ, Janz D. The significance of microdysgenesis in primary generalized epilepsy: An answer to the considerations of Lyon and Gastaut. *Epilepsia* 1985; **26**:368-371.
11. Lyon G, Gastaut H. Considerations on the significance attributed to unusual cerebral histological findings recently described in eight patients with primary generalized epi lepsy. *Epilepsia* 1985; **26**:365-367.
12. Meencke HJ. The density of dystopic neurons in the white matter of the gyrus frontalis inferior in epilepsies. *J Neurol* 1983; **230**:171-181.
13. Meencke HJ. Neuron density in the molecular layer of the frontal cortex in primary generalized epilepsy. *Epilepsia* 1985; **26**:450-454.
14. Schlote W. Zur Gliarchitektonik der menschlichen Grosshirnrinde im Nissl-Bild. *Arch Psychiatr Nervenkr* 1959; **199**:573-595.
15. Haug H, Barmwater U, Eggers R, Fischer D, Kuhl S, Sass NL. Ana-

- tomical changes in aging brain: morphometric analysis of the human prosencephalon. [In] Cervos-Navarro J, Sarkander HJ, eds. *Brain Aging: Neuropathology and Neuropharmacology*, New York, Raven Press, 1983, vol 21.
16. Huttenlocher PR. Dendritic development in neocortex of children with mental defect and infantile spasms. *Neurology (Minneapolis)* 1974; **124**:203-210.
 17. Wolf et al. 1983, and personal communication, 1986.
 18. Bignami A, Maccagnani F, Zapella M, Tingey AH. Familial infantile spasms and hypsarrhythmia associated with leukodystrophy. *J Neurol Neurosurg Psychiatry* 1964; **29**:129-134.
 19. Bamberger PH, Matthes A. Anfälle im Kindesalter. Karger, Basel, 1959, pp 620-622.
 20. Bignami A, Zappella M, Benedetti P. Infantile spasms with hypsarrhythmia: A pathological study. *Helv Paediatr Acta* 1966; **4**:326-342.
 21. Bischoff, 1961 *Psychiat Neurol Neurochir* **64**:133-148.
 22. Bugiani O, Toso V, Gatti R, Mancardi GL, Leonardi A: Primary immunodeficiency with early encephalopathy in two siblings. *Eur Neurol* 1975; **13**:405-417.
 23. Christensen E, Melchior JC. Neuropathological findings in children with infantile spasms and hypsarrhythmia. *Dan Med Bull* 1960; **7**:121-127.
 24. Coleman M, Hart PN, Randall J, Lee J, Hijada D, Bratenshi ChG. Serotonin levels in the blood and central nervous system of a patient with sudanophilic leukodystrophy. *Neuropädiatrie* 1977; **8**:459-466.
 25. Druckmann RD, Chao D, Alvord Jr EC. A case of atonic cerebral diplegia with lissencephaly. *Neurology* 1959; **19**:806-814.
 26. Dummermuth G. Über das Syndrom der Blitz-Nick-Salaam-Krämpfe und seine Behandlung mit ACTH und Hydrocortison. II. Zwischenbilanz. *Helv Paediatr Acta* 1961; **16**: 244-266.
 27. Fisch AM, Oliveira C, Fernandes I. Contribuicao ao estudo da hipsarritmia. *Arch Neuro-psiquiatri* 1966; **24**: 15-27.
 28. Hanefeld F, Grimm B, Klopp H, Rating D, Siemes H, Stephani U, Spohr HL, Schneider H. Gibt es idiopathische BNS-Krämpfe? [In] *Epilepsie* 1980. Renschmidt H, Jungmann J (Hrsg). Thieme, Stuttgart, 1981, pp 245-252.
 29. Harper JR. Infantile spasms associated with cerebral agyria. *Dev Med Child Neurol* 1967; **9**:460-463.
 30. Harris R, Pampiglione E. EEG and histopathology of 11 children with infantile spasms. *Electroencephalogr Clin Neurophysiol* 1962; **14**:283.
 31. Janz D, Matthes A. Die Propulsiv-Petit-Mal-Epilepsie. Klinik und Verlauf der Sog. Blitz-Nick-Salaam-Krämpfe. *Ann Paediatr* 1955; (suppl):60.
 32. Jeavons PM, Bower BD. Infantile Spasms: A review of the literature and a study of 112 cases. *Clinic in Developmental Medicine* No. 15. Spastics Society and Heinemann, London, 1964.
 33. Jellinger K. Neuropathological aspects of hypsarrhythmia. *Neuropädiatric* 1970; **1**: 277-294.
 34. Kamoshita S, Mizutani I, Fukuyama Y. Leigh's subacute necrotizing encephalomyelopathy in a child with infantile spasms and hypsarrhythmia. *Dev Med Child Neurol* 1970; **12**:430-435.
 35. Kellaway P. Neurologic status of patients with hypsarrhythmia. In: Gibbs FA, *Molecules and Mental Health*. Lippincott, Philadelphia 1959, pp 134-149.
 36. Kramer W. Poliodyplasia cerebri. *Acta Psychiatr Neurol Scand* 1953; **28**:413-427.
 37. Laurence KM, Cavanagh JB. Progressive degeneration of the cerebral cortex in infancy. *Brain* 1968; **91**:261-280.
 38. Lennox WG. *Epilepsy and Related Disorders*. Little Brown and Co., Boston, 1960.
 39. Maloňe MJ, Szöke MC, Lowney GL. Globoid leukodystrophy: I. Clinical and enzymatic studies. *Arch Neurol* 1975; **32**:606-612.
 40. Marciniak M, Damska M, Wiszozor-Adamczyk B. Neuropathologic changes in the syndrome of infantile spasms. *Neuropathol Poland* 1971; **9**:211-218.
 41. Martin C, Loiseau P, Battin J-J. Encephalopathie chronique avec hypsarrhythmie, sequelle d'une anoxie neo-natale. *Arch Fr Pediatr* 1961; **18**:609-619.
 42. Millichap JG, Blickford RG, Klass DW, Backus RE. Infantile spasms, hypsarrhythmia and mental retardation: A study of aetiologic factors in 61 patients. *Epilepsia* 1962; **3**:188-197.
 43. Morse WK. Hereditary myoclonus epilepsy. Two cases with pathological findings. *Bull Johns Hopkins Hosp* 1949; **84**:116-133.
 44. Okuyama K. Neuropathological findings in eight cases of infantile spasms with hypsarrhythmia. *Dev Med Child Neurol* 1965; **7**:707-708.
 45. Paludan J. Autopsy findings in a child with infantile spasms and hypsarrhythmia with a survey of the effects of ACTH. *Dan Med Bull* 1961; **8**:128-130.
 46. Peiffer J. *Morphologische Aspekte der Epilepsien*. Springer, Berlin-Göttingen-Heidelberg, 1963.
 47. Poser CM, Low NL. Autopsy findings in three cases of hypsarrhythmia (infantile spasms with mental retardation). *Acta Paediatr (Uppsala)* 1960; **49**:695-706.
 48. Radermecker J, Toga M, Guazzi GC: Etude anatomopathologique. In: *L'Encephalopathie Myoclonique Infantile avec Hypsarrhythmie (Syndrome de West)*. Gastaut H, Roger J, Soulayrol R, Pinsard M. Masson, Paris, 1964, pp 151-168.
 49. Sinton DW, Patterson PR. Infantile spasms. A case report with clinical and pathologic correlation. *Neurology* 1962; **12**:351-360.
 50. Tchicaloff M, Deruaz J-P, Rabinowicz Th. Klinischanatomische Untersuchungen bei zwei Kindern mit myoklonisch-astatischem Petit Mal. *Z EEG-EMG* 1974; **5**:114-122.
 51. Thulin B, McTaggart D, Neuburger KT. Demyelinating leukodystrophy with total cortical cerebral atrophy. *Arch Neurol* 1968; **18**: 113-122.
 52. Tjiam AT, Stęfanko S, Schenk VWD, de Vlieger M. Infantile spasms associated with hemihypsarrhythmia and hemimegalencephaly. *Dev Med Child Neurol* 1978; **20**:779-798.
 53. Tucker JS, Solitare GB. Infantile myoclonic spasms. Clinical, electrographic, neuropathologic observations. *Epilepsia* 1963; **4**:45-59.
 54. Yakovlev PI, Wadsworth RC. Schizencephalis: a study of the congenital clefts in the cerebral mantle. II. Clefts with hydrocephalus and lips separated. *J Neuropathol Exp Neurol* 1946; **5**:169-206.