

Benign childhood epilepsy with centrotemporal spikes

PIERRE LOISEAU, MD AND BERNARD DUCHÉ, MD

MANY childhood epilepsies have a favorable outcome.¹ In some, however, prognostic factors can appear and take shape one year or more after onset of the disorder. In the case of benign partial epilepsy of childhood with centrotemporal spikes (BPEC) the clinician's situation with respect to the patient and the parents is much more optimistic. Key electroclinical criteria for an excellent prognosis are present, in most cases, immediately after the first seizure and on the first electroencephalographic (EEG) record. Also referred to as benign rolandic epilepsy of childhood, BPEC is placed in the group of localization-related (focal, local, partial) idiopathic epilepsies.²

HISTORY

The concept of BPEC as a clinical entity was slow in developing. BPEC cases were lost among major seizures, minor motor seizures and temporal lobe seizures. Early electroencephalographers noted that rolandic (centrotemporal or midtemporal) spikes were a very special EEG pattern which existed only in children and tended to disappear with increasing age.³⁻⁶ The seizures as well as the spikes vanished during puberty.⁷ Gibbs and Gibbs⁸ in 1960 were the first to correlate rolandic spikes with a common form of focal childhood epilepsy generally having a good prognosis, but they did not describe the specific clinical features of the seizures. In the sixties and early seventies, the key clinical symptoms and signs of BPEC were described in Europe⁹⁻¹⁵

From the Department of Neurology, Hôpital Pellegrin, Bordeaux, France

and in the United States.¹⁶ Since then, many papers have given more details on the clinical^{17,18} and EEG¹⁹⁻²² symptomatology, on the genetics,^{23,24} on the course,²⁵⁻²⁹ and on borderline abnormalities³⁰⁻³⁴ of the syndrome.

DEFINITION

BPEC is defined by five main characteristics:

1. It is age-related, beginning between the ages of 2 and 13.
2. It occurs in otherwise normal children having no neurologic or intellectual deficit.
3. In the majority of cases, the seizures are partial with motor signs frequently associated with somatosensory symptoms, and are sleep-related in 75% of patients.
4. The interictal EEG records display a spike focus located in the centrotemporal (rolandic) area. Background activity is normal.
5. A spontaneous remission occurs during adolescence.

GENERAL CHARACTERISTICS

BPEC is one of the commonest forms of epilepsy encountered in childhood. It represents about 8% of all the epileptic seizures under age 10,³⁵ 16% under age 15,³⁶ and 24% in children aged 5 to 14.³⁷ It is reported three³⁷ or four²⁴ times more frequently than childhood absence epilepsy. Its annual incidence was found by one group²⁴ to be 21/100,000 in children under age 15,

but only 7.1/100,000 in an epidemiologic survey in the southwest of France (in preparation).

The age at onset ranges from 2 to 13 years. In 80% of these patients, seizures appear between 5 and 10 years, with a peak at 9 years.^{14,15}

BPEC is more frequent in boys (60%) than in girls.

ETIOLOGIC FACTORS

Genetic

A much higher prevalence of epilepsy was found among close relatives of children with BPEC than in a matched control group (30% and 5%, respectively).²³ In a genetic study,²⁴ 15% of siblings had seizures and rolandic spikes, 19% of siblings had rolandic spikes without attacks, and 11% of the parents had experienced seizures in childhood but not in adult life. The data are in favor of an autosomal dominant gene with age-dependent penetrance responsible for the EEG trait. Many carriers of the gene never reach the level of clinical penetrance. There are obvious similarities between the inheritance of BPEC and that of idiopathic generalized epilepsies. The presence of generalized spike-wave discharges on the EEG of children with BPEC is another argument in favor of this hypothesis. Expression of the gene may be influenced by other genetic and environmental factors.

Acquired

In the antecedents of about 10% of children with BPEC, mild pathological events are to be noted: birth difficulties, infections of the central nervous system, head trauma, febrile seizures, etc. They are found in the same proportion as expected in a total population. Environmental factors may precipitate the seizures.

CLINICAL ASPECTS

Seizure phenomena

Symptomatology. The seizure patterns vary to a great extent from child to child, and in some patients, from fit to fit. Analysis of seizure patterns in BPEC has demonstrated that, in spite of their apparent diversity, their components do not occur at random. Most reflect a preferential localization of epileptic discharges in the lower part of the pre- and postcentral suprasylvian gyri.^{16,17} The seizures may be simple partial seizures or develop into complex partial seizures or to a secondary generalization. Motor, sensory and automatic manifes-

tations in the face, mouth and throat prevail during partial seizures; hence the term "sylvian seizures" proposed by Lombroso.¹⁶ Oropharyngeal symptoms are reported by more than half the patients. They are described as follows: hypersalivation with inability to swallow; guttural sounds, alerting the parents to nocturnal seizures; involuntary movements or tonic contractions of the tongue or jaw; numbness or paresthesias of the tongue, the gums and cheek on one side; speech arrest due to tonic or clonic phenomena involving the mouth and probably also the larynx. Some of the oropharyngeal symptoms are reported by the patient when the seizure is over; others are described by witnesses. Tonic or clonic contraction of one side of the face, usually the corner of the mouth, is also frequent, isolated or associated with oropharyngeal signs or, less often, with jerks of the ipsilateral arm. Sensory-motor phenomena involving a leg, or half the body, and miscellaneous symptoms such as vertigo, blindness, flashing lights, and abdominal pain, can also occur.

The various types of seizures can be summarized as follows: (1) Brief hemifacial seizures are mainly observed in older children, when awake. (2) Oropharyngeal seizures occur in children either awake or asleep. Consciousness is preserved or is impaired either from the onset in sleeping children, or during a seizure which can generalize. (3) In about 20% of the cases, the description is compatible with generalized onset seizures, but sometimes a postictal paralysis is compatible with a secondary generalization. (4) Hemicorporal clonic seizures are the first manifestation of BPEC in younger children. They are often followed by a transient postictal paresis. (5) In a few cases, typical absence seizures can appear during the course of the illness. (6) Rare patients have experienced quite different types of seizures.

A single type of seizure tends to occur in an individual patient, but 20% to 25% of children experience two or more types of seizures.

Predisposing factors and repetition. BPEC is a sleep-dependent syndrome. In 76% of BPEC patients, seizures occur only during sleep, whether nocturnal or diurnal.^{25,30} This is a key characteristic for the diagnosis, even though in some BPEC patients, seizures occur during both sleep and wakefulness, or during the waking state alone.

Frequency of seizures is quite variable. In most patients, BPEC is a mild epilepsy. Thirteen percent²⁵ to 20%³⁰ of patients experience a single seizure, even when receiving no medication. Seizures are infrequent

in 66% of the cases.²⁵ They are repeated in clusters in 20% of the cases³⁰ (either a single initial cluster, or several clusters separated by long seizure-free intervals). However, BPEC can be severe in the short term because of the frequency of seizures, or over a long period by their recurrence, or by both. Thirteen among 61 patients (21%) had more than 10 seizures.¹³ Ten among 168 patients had very frequent attacks.³⁰ Seizures occurred over a period of 6 years in 10% of patients.³⁰ Among 38 patients, 24% had severe seizures (status epilepticus, repeated or prolonged seizures).³⁴ Two cases of drug-resistant status epilepticus have been published.¹⁸

Interictal status. Neuroradiologic examinations have in many cases always been normal. Behavioral problems are less frequent in BPEC than in other childhood epilepsies.^{25,38} They seem to be engendered mainly by the family's anxiety and restrictions on the child's activities.²⁵

EEG phenomena

Interictal EEG pattern. There is a characteristic EEG pattern which is a cornerstone of diagnosis: centrotemporal spikes on normal background activity. Many variations are possible.

These centrotemporal spikes are typically slow, diphasic, high-voltage (100 to 300 μ v) spikes, often followed by a slow wave. They recur at short intervals, isolated or more often in clusters, with a spike rhythm of about 1.5 to 3 Hz. Their highest voltage is found at either the midtemporal lead (T3 or T4) or the inferior central lead (C5 or C6). They are either specifically located in this area, or they spread to other areas, on the same side and/or on the other side (mirror focus) according to their voltage (Figures 1 and 2).

The following variations have been observed:

1. **Variations in frequency and amplitude.** In a few patients, spikes are rare (approximately one every 20 or 30 seconds), and low in amplitude. They may be difficult to see when background activity is high in

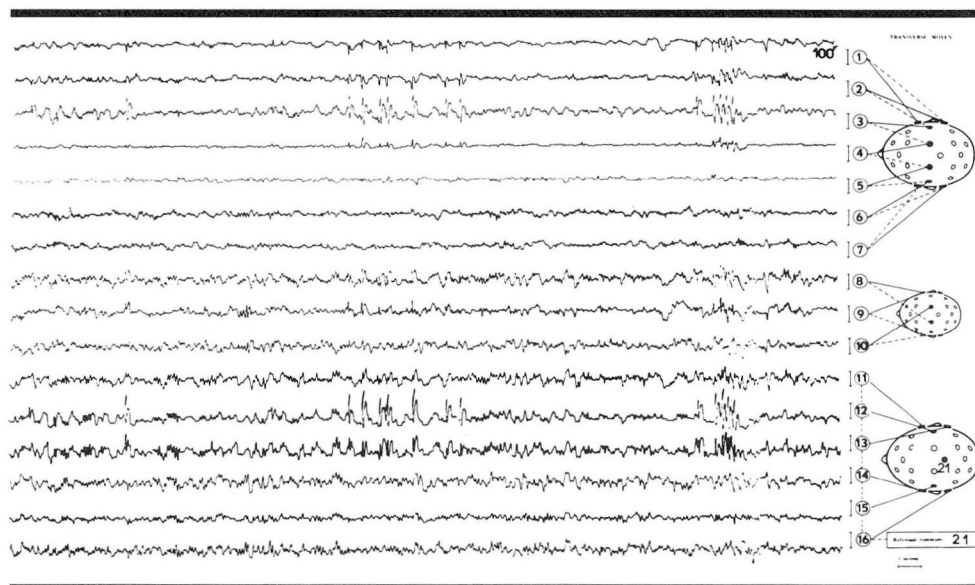


FIGURE 1. A typical interictal EEG: frequent clusters of centrotemporal spikes, with highest voltage at C₆ lead and not at the anterior temporal lead.

amplitude. On other recordings, spikes are very frequent, almost continuous, very high, occurring in rhythmic clusters with a large contralateral spread. They may be wrongly interpreted as bilateral spike waves.

2. **Morphologic variations.** The spike shape can be quite variable in each individual during the same recording.

3. **Variations in location.** Centrotemporal spikes are unilateral in 62% to 70% of patients. They can shift from one side to the other in successive recordings of the same patient. In other patients, they are bilateral, asynchronous with different rates firing or, more seldom, synchronous but with different amplitudes. They are usually located at the inferior part of the rolandic area. However, in 8% of patients, they are located at the superior part of the rolandic strip.

4. **Variations in presence.** Centrotemporal spikes can be absent in one or more recordings, at least during the waking state. They reappear in subsequent recordings with no clinical translation.^{13,36}

Other paroxysmal abnormalities can be present. In younger patients, multiple spike foci or occipital foci were found.¹⁵ Synchronous, bilateral spike-wave discharges are not infrequent, ranging from 7%^{15,25} to 13%¹³ and 20%³¹ in conventional recordings, and reaching 73% in telemetric recordings, which furthermore disclosed some 3-per-second, bilateral spike-wave

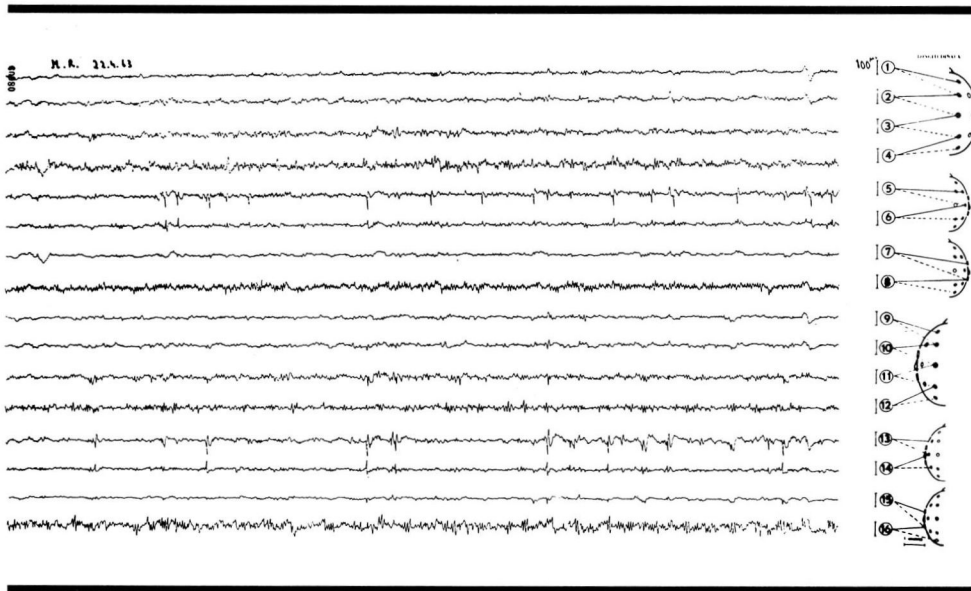


FIGURE 2. Two independent rolandic foci. No paroxysmal abnormalities on the temporal regions.

discharges lasting more than 6 seconds and accompanied by an absence seizure.

Centrotemporal spikes are not clearly enhanced by eye-opening or closure, by hyperventilation or by intermittent photic stimulation. The discharge rate is considerably increased in drowsiness and in all stages of sleep,³⁹ but morphology of spikes remains unchanged, and neither polyspikes nor bilateralization occurs.³⁷ In 30%³⁹ to 35%¹⁶ of children, spikes appear only in sleep. "Thus, a sleep record should be obtained whenever benign rolandic epilepsy of childhood is clinically suspected and the waking record is unrevealing."²⁹ All-night polygraphic sleep recordings showed that sleep organization was preserved in children with BPEC.^{22,40-42} No correlation was found between intensity of spike discharges in the EEG and frequency, length or duration of seizures.²⁵

Ictal EEG pattern. EEG recordings during seizure are very scarce.^{20,29,33,43} In each case, the EEG onset was focal, over the centrotemporal area, and then spread more or less.

DIFFERENTIAL DIAGNOSIS AND NOSOLOGIC LIMITS

Clinical and EEG data separately can suggest BPEC, but they must be combined to confirm it. Symptomatic localization-related epilepsies can produce similar

seizures. Centrotemporal spikes are not specific to epilepsy. They are often found in brain-damaged children. They also exist among normal children between the ages of 6 and 13 (1.3%) expressing difficulties in emotional or motor adaptation.³⁷

Children with neurologic or intellectual sequelae of a fixed cerebral lesion can appear to have BPEC, both in its clinical and EEG aspects. Some investigators have included them in their groups of patients. In most cases, they shared the favorable course of normal children, but some of them developed a chronic epilepsy. They do not meet the diagnostic cri-

teria for BPEC. We suggest that they be considered as a subgroup of patients with the benign partial epilepsies of childhood.

The other benign partial epilepsies of childhood and BPEC are clearly distinct. The sole diagnosis difficult to distinguish from BPEC is epilepsy with continuous spikes and waves during slow sleep.⁴³ This syndrome has a far less favorable prognosis. Confusion is possible in two situations: (1) when the rate of spike discharges during sleep is very high in a child with BPEC (however, the spike-wave index always remains far below 80%); (2) during the first months of this syndrome, when seizures mimic BPEC focal motor seizures, and the EEG during wakefulness shows centrotemporal spikes. Furthermore, the characteristic sleep EEG pattern sometimes does not appear until 1 or 2 years after onset of seizures.

MANAGEMENT

Attention has been called to the importance of a proper medical attitude in dealing with this disorder.²⁹ Most of the psychosocial problems associated with chronic epilepsy do not arise when family and teachers are encouraged to consider the child as a healthy person, not requiring restrictions or overprotection, expected to recover fully in a few years, and temporarily

under medication to control the seizures—if under medication.

As a matter of fact, the main question is which children need drug therapy. An antiepileptic treatment is necessary only in about 30% of the patients. Most of the time, it is unnecessary after a first seizure. It can be delayed even after a second seizure. Predictive factors of severity have been proposed. Partial seizures and a short interval between the first and second attack,⁴⁴ and an early onset,³⁰ forecast repeated seizures, i.e., a necessity to treat.

Duration of treatment is relatively easy to set. By definition, BPEC disappears before the age of 16, so that therapy beyond this age would be quite illogical. An earlier withdrawal is controversial. Lerman²⁹ suggested tapering off anticonvulsants after 1 to 2 years of seizure control. Therapy has been stopped without relapse in patients before age 10 or 13.²⁷ However, early withdrawal of drugs can be followed by seizures.¹³ This is not surprising. BPEC is an age-related epileptic syndrome, following its own course and tending to disappear at a certain age regardless of age at onset. It is preferable to maintain anticonvulsant drug therapy up to ages 14 to 16, at least in patients who were difficult to control and in psychologically fragile condition.

Of course, polypharmacy must be avoided in this benign epilepsy. A one-drug therapy is mandatory. The choice of a drug has to be made very carefully, with consideration of both efficacy and toxicity. Phenobarbital is certainly not the best drug. Phenytoin is quite effective,^{16,25,27} but is also a sedative. Carbamazepine is one of the first-choice drugs. It is as effective as phenobarbital and phenytoin, and has fewer side-effects.⁴⁵ However, rashes are a problem. Sodium valproate is effective in treating partial seizures and produces fewer side-effects.⁴⁶ An important point is that, when patients do not respond to treatment, it is better to accept seizures than the neurotoxic effects of heavy therapy.

REFERENCES

- Holowach J, Thurston J, Thurston DL, Hixon BB, Keller AJ. Prognosis in childhood epilepsy. Additional follow-up of 148 children 15 to 23 years after withdrawal of anticonvulsant therapy. *N Engl J Med* 1982; **306**:831–836.
- Commission on Classification and Terminology of the International League Against Epilepsy. Proposal for classification of epilepsies and epileptic syndromes. *Epilepsia* 1985; **26**:268–278.
- Gibbs EL, Gillen HW, Gibbs FA. Disappearance and migration of epileptic foci in childhood. *Am J Dis Child* 1954; **88**:596–603.
- Gastaut Y. Un élément dérivant de la séméiologie EEG: les pointes rolandiques sans signification focale. *Rev Neurol (Paris)* 1952; **87**:488–490.
- Nayrac P, Beaussart M. Les pointes-ondes prérolandiques, expression EEG très particulière (étude électro-clinique de 21 cas). *Rev Neurol (Paris)* 1958; **99**:203–205.
- Bancaud J, Collomb D, Dell MB. Les pointes rolandiques: un symptôme EEG propre à l'enfant. *Rev Neurol (Paris)* 1958; **99**:206–209.
- Courjon J, Cotte MR. Une entité électro-clinique particulière: les

LONG-TERM COURSE

Seizure prognosis

Many children with BPEC respond well to medication, but seizures are difficult to control in some patients²⁷ and/or recur for several years.^{26,30} Nonetheless, in the course of the years, the seizures stop completely, and recovery is the rule.²⁹ About 2% of patients experience seizures after recovery from BPEC.^{27,30,47} Most of these are isolated or infrequent generalized tonic-clonic seizures. They usually occur during adolescence, but sometimes much later. Partial seizures after recovery from BPEC have seldom been reported.^{48,49} Patients with further seizures do not differ in any other way from patients in whom BPEC progresses toward full recovery.^{30,47}

Social prognosis

BPEC does not impair the adult life of patients. "They grew up to become well-balanced productive citizens."²⁹ "No patient mentioned the seizure disorder as the cause of difficulty in obtaining employment."²⁷ The social adaptability of such patients is excellent. Moreover, patients who have had BPEC have showed a higher rate of success in occupational status than normal boys and girls.⁵⁰

ACKNOWLEDGMENTS

We are very grateful to Jim Sneeds for kind checking of the English text. Our warmest thanks are due to Ms M.F. Aury for her expert secretarial assistance.

PIERRE LOISEAU, MD
Hôpital Pellegrin
33076 Bordeaux Cédex,
France

- foyers pseudo-rythmiques de l'enfant. *J Med Lyon* 1959; 40:803.
8. Gibbs EL, Gibbs FA. Good prognosis of mid-temporal epilepsy. *Epilepsia* 1960; 1:448-453.
 9. Faure J, Loiseau P. Une corrélation clinique particulière des pointes rolandiques sans signification focale. *Rev Neurol (Paris)* 1960; 102:399-406.
 10. Loiseau P, Faure J. Une forme particulière d'épilepsie de la seconde enfance. *J Med Bordeaux* 1961; 138:381-389.
 11. Blom S, Brorson LV. Central spikes or sharp waves (rolandic spikes) in children's EEG and their clinical significance. *Acta Paediatr Scand* 1966; 55:385-393.
 12. Loiseau P, Cohadon F, Mortureux Y. A propos d'une forme singulière d'épilepsie de l'enfant. *Rev Neurol (Paris)* 1967; 116:244-248.
 13. Aicardi J, Chevrie JJ. Épilepsie partielle avec foyer rolandique de la seconde enfance. *Journées Parisiennes de Pédiatrie* 1969; 4:125-142.
 14. Lerman P. Benign focal epilepsy in children. *Electroencephalogr Clin Neurophysiol* 1970; 28:642.
 15. Beaussart M. Benign epilepsy of children with rolandic (centrotemporal) paroxysmal foci. *Epilepsia* 1972; 13:795-811.
 16. Lombroso CT. Sylvian seizures and mid-temporal spike foci in children. *Arch Neurol* 1967; 17:52-59.
 17. Loiseau P, Beaussart M. The seizures of benign childhood epilepsy with rolandic paroxysmal discharges. *Epilepsia* 1972; 14:381-389.
 18. Fejerman N, Di Blasi AM. Status epilepticus of benign partial epilepsies in children: report of two cases. *Epilepsia* 1987; 28:351-355.
 19. Beaumanoir A, Ballis T, Warfis G, Ansari K. Benign epilepsy of childhood with rolandic spikes. *Epilepsia* 1974; 15:301-315.
 20. Dalla Bernardina B. EEG of a nocturnal seizure in a patient with benign epilepsy of childhood with rolandic spikes. *Epilepsia* 1975; 16:497-501.
 21. Morikawa T, Osawa T, Ishihara O, Seino M. A reappraisal of benign epilepsy of children with centrotemporal EEG foci. *Brain Dev* 1979; 1:257-265.
 22. Clemens B, Olah R. Sleep studies in benign epilepsy of childhood with rolandic spikes. I. Sleep pathology. *Epilepsia* 1987; 28:20-23.
 23. Bray PF, Wisner WC. Evidence for a genetic etiology of temporal central abnormalities in focal epilepsy. *N Engl J Med* 1964; 271:926-933.
 24. Heijbel J, Blom S, Rasmuson M. Benign epilepsy of childhood with centrotemporal EEG foci: a genetic study. *Epilepsia* 1975; 16:285-293.
 25. Lerman P, Kivity S. Benign focal epilepsy of childhood. A follow-up study of 100 recovered patients. *Arch Neurol* 1975; 32:261-264.
 26. Beaussart M, Faou R. Evolution of epilepsy with rolandic paroxysmal foci: a study of 324 cases. *Epilepsia* 1978; 19:337-342.
 27. Blom S, Heijbel J. Benign epilepsy of children with centrotemporal EEG foci: a follow-up study in adulthood of patients initially studied as children. *Epilepsia* 1982; 23:629-631.
 28. Beaumanoir A, Grandjean E, Nahory A. Follow-up study of 63 patients with maturation epilepsy. *Neurol Psychiatr* 1983; 6:62-67.
 29. Lerman P. Benign partial epilepsy with centrotemporal spikes. [In] Roger J, Dravet C, Bureau M, Dreifuss FE, Wolf P, eds. *Epileptic Syndromes in Infancy, Childhood and Adolescence*. London, John Libbey, 1985; pp 150-158.
 30. Loiseau P, Duché B, Cordova S, Dartigues JF, Cohadon S. Prognosis of benign childhood epilepsy with centrotemporal spikes. A follow-up study of 168 patients. *Epilepsia* (in press).
 31. Petersen J, Nielsen CJ, Gulann NC. Atypical EEG abnormalities in children with benign partial (rolandic) epilepsy. *Acta Neurol Scand* 1983; 94(suppl):57-62.
 32. Aicardi J. The benign epilepsies of childhood. [In] Rose FC, ed. *Research Progress in Epilepsy*. London, Pitman, 1983, pp 231-239.
 33. Dalla Bernardina B, Chiamenti C, Capovilla G, Colomaria V. Benign partial epilepsies in childhood. [In] Roger J, Dravet C, Bureau M, Dreifuss FE, Wolf P, eds. *Epileptic Syndromes in Infancy, Childhood and Adolescence*. London, John Libbey, 1985, pp 137-149.
 34. Deonna T, Ziegler AL, Desplan DPA, Van Melle G. Partial epilepsy in neurologically normal children: clinical syndromes and prognosis. *Epilepsia* 1986; 27:241-247.
 35. Doose H, Sitepu B. Childhood epilepsy in a German city. *Neuropediatrics* 1983; 14:220-224.
 36. Blom S, Heijbel J, Bergfors PG. Benign epilepsy with centrotemporal foci. Prevalence and follow-up study of 40 patients. *Epilepsia* 1972; 13:609-619.
 37. Cavazzuti GB. Epidemiology of different types of epilepsy in school age children of Modena, Italy. *Epilepsia* 1980; 21:57-62.
 38. Heijbel J, Bohman M. Benign epilepsy of children with centrotemporal EEG foci: intelligence, behavior and school adjustment. *Epilepsia* 1975; 16:679-687.
 39. Blom S, Heijbel J. Benign epilepsy of children with centrotemporal EEG foci. Discharge rate during sleep. *Epilepsia* 1975; 16:133-140.
 40. Dalla Bernardina B, Beghini G. Rolandic spikes in children with and without epilepsy. *Epilepsia* 1976; 17:161-167.
 41. Ambrosetto G, Gobbi G, Sacquegna T. Rolandic spikes in children with and without epilepsy during sleep. *Waking Sleeping* 1977; 1:211-215.
 42. Dalla Bernardina B, Bondavalli S, Colomaria V. Benign epilepsy of childhood with rolandic spikes (BERS) during sleep. [In] Sterman MB, Shouse MN, Passouant P, eds. *Sleep and Epilepsy*, New York, Academic Press, 1982, pp 495-506.
 43. Tassinari CA, Bureau M, Dravet C, Dalla Bernardina B, Roger J. Epilepsy with continuous spikes and waves during slow sleep. [In] Roger J, Dravet C, Bureau M, Dreifuss FE, Wolf P, eds. *Epileptic Syndromes in Infancy, Childhood and Adolescence*. London, John Libbey, 1985, pp 194-212.
 44. Ambrosetto G, Sgro V, Caldana A, Santucci M. Fattori predittivi la frequenza di crisi nell'epilessia a parossismi rolandici. *Boll Lego It Epil* 1985; 51/52:223.
 45. Lerman P, Kivity-Ephraim S. Carbamazepine sole anticonvulsant for focal epilepsy of childhood. *Epilepsia* 1974; 15:229-234.
 46. Dean JC, Penry JK. Valproate monotherapy for partial seizures. *Epilepsia* 1987; 28:605.
 47. Beaussart M. Crises épileptiques après guérison d'une EPR (épilepsie à paroxysmes rolandiques). *Rev EEG Neurophysiol Clin* 1981; 11:489-492.
 48. Ambrosetto G, Tinuper P, Baruzzi A. Relapse of benign partial epilepsy of children in adulthood: report of a case. *J Neurol Neurosurg Psychiatr* 1985; 48:90.
 49. Lerman P, Kivity S. The benign focal epilepsies of childhood. [In] Pedley TA, Meldrum BS, eds. *Recent Advances in Epilepsy No. 3*. Edinburgh, Churchill Livingstone, 1986, pp 137-156.
 50. Loiseau P, Pestre M, Dartigues JF, Commenges D, Barbeger-Gatau C, Cohadon S. Long-term prognosis in two forms of childhood epilepsy: typical absence seizures and epilepsy with rolandic (centrotemporal) EEG foci. *Ann Neurol* 1983; 13:642-648.