



EEG evaluation for epilepsy surgery in children

HANS LÜDERS, MD; DUDLEY S. DINNER, MD; HAROLD H. MORRIS III, MD;
ELAINE WYLLIE, MD; JAIME GODOY, MD

OVER the past 10 years, an increasing interest in surgery of epilepsy has led to the development of progressively more effective methods of evaluation. At the same time, most researchers in this field have realized that the surgery usually comes too late, when the devastating effects of the disease have already left the patient with irreparable psychological scars. In the Cleveland Clinic Foundation Epilepsy Program, patients had surgery 13.6 years after seizure onset and 11.3 years after the seizures became medically intractable. This delay has led to a growing interest in identifying suitable surgical candidates at an earlier stage, which could lead to more timely surgical intervention. Plans to perform surgery at an earlier stage should naturally take into consideration the following questions. Can we reliably identify children suffering from intractable epilepsy which will remain intractable even with maturation? Are the work-up methods currently used in adults also applicable in children, or do we need to develop a completely new technique of evaluation for children? Are the results of surgery in children as successful as those in adults?

We will describe here the system of presurgical electroencephalographic (EEG) evaluation currently in use at the Cleveland Clinic Foundation, and then try to answer some of these questions. Only surgery of epilepsy in patients with partial epilepsies will be

discussed. Surgical treatments used preferentially for generalized epilepsies, such as corpus callosotomy, are taken up elsewhere in this issue (see Spencer and Spencer).

THE PRINCIPLE OF CONVERGENCE

Presurgical evaluation consists of the analysis of multitudinous factors including clinical information (for example, age of seizure onset, possible etiologic factors, other intercurrent disease, etc.), general physical and neurologic examination, neuropsychological analysis, neuroimaging, and detailed description of clinical seizures and ictal/interictal EEG data. Within this array of data, the EEG usually provides the most precise and specific information for localization of the epileptic focus and also for definition of the extent of the epileptogenic area. Equally important, however, is to determine if the EEG information and the other data are convergent. In other words, it is important that all the clinical information also points to the same conclusion as the EEG regarding the epileptogenic focus. For example, we would speak of convergent information when a patient had prolonged febrile convulsions in childhood, started with typical complex partial seizures with postictal aphasia at 5 to 10 years, has a slight deficit of processing verbal information in psychometric studies, shows a lesion compatible with left hemisphere mesial temporal sclerosis in the magnetic resonance imaging (MRI), and has an EEG focus maximum at the left sphenoidal electrode.

Section of Epilepsy and Clinical Neurophysiology (H.L., D.S.D., H.H.M., E.W., J.G.) and Section of Pediatric Neurology (E.W.), The Cleveland Clinic Foundation.

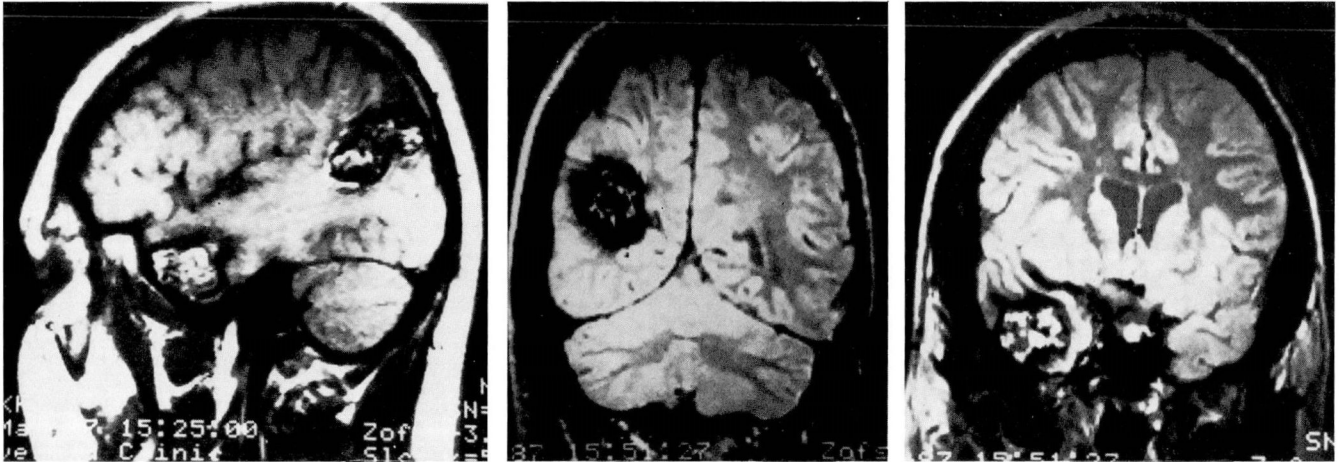


FIGURE 1. Right-sided cavernous hemangiomas (MRI).

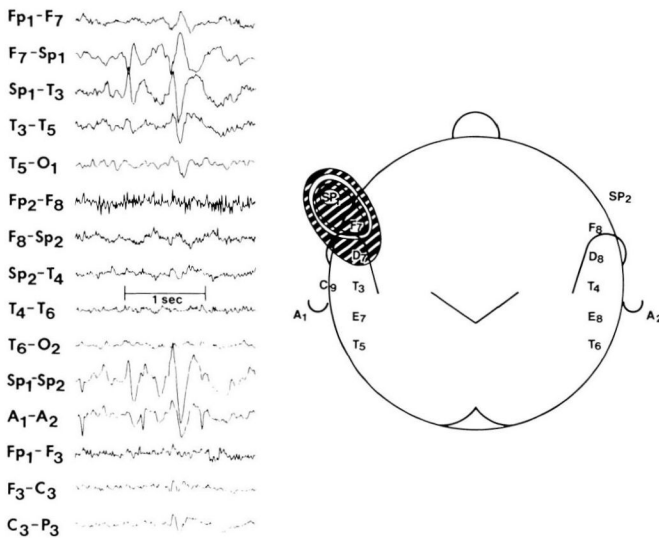


FIGURE 2. Left mesial temporal sharp waves (right temporal cavernous hemangiomas).

Nonconvergent information, on the other hand, would be the existence of a right frontal lesion in the MRI in a patient with predominantly left sphenoidal maximum interictal sharp waves, and video documentation of tonic postural seizures suggesting mesial frontal origin. Another example of a patient with nonconvergent presurgical evaluation is shown in *Figures 1 and 2*.

Nonconvergent cases like this one are extremely difficult to analyze and are not taken up here. In other words, the following discussion concentrates on analysis of presurgical EEG information and always assumes that the remainder of the presurgical evaluation pro-

vided convergent information. Careful analysis of all available information to establish that it is convergent with results of the presurgical EEG evaluation is at least as important as a detailed analysis of the EEG data.

NONINVASIVE VIDEO/EEG MONITORING

The first step in the presurgical EEG analysis is the noninvasive video/EEG monitoring.¹ It is the most essential part of the presurgical EEG work-up because it gives a general overview identifying the approximate location and extent of the epileptogenic zone or zones. It is certainly not an exaggeration to state that in most cases, success of surgery depends in great part on the quality of this preliminary noninvasive work-up.

Candidates for surgery are hospitalized; and, unless they have very frequent seizures, the anticonvulsant medication is reduced and usually also discontinued completely to increase the occurrence of ictal and interictal epileptogenic activity. Continuous video/EEG monitoring is started. Interictal epileptiform discharges are analyzed and carefully distributed, identifying where the maximum is located. This analysis indicates the possible presence of 1) a unilateral mesial temporal epileptogenic focus, 2) a clearly lateralized but extramesiotemporal epileptogenic focus (temporal convexity and extratemporal), 3) bilateral independent mesiotemporal epileptogenic foci, or 4) bilateral independent extensive epileptogenic zones or generalized diffuse epileptogenicity. These different possibilities are shown schematically in *Figure 3*.

For each of these possibilities, future evaluations call

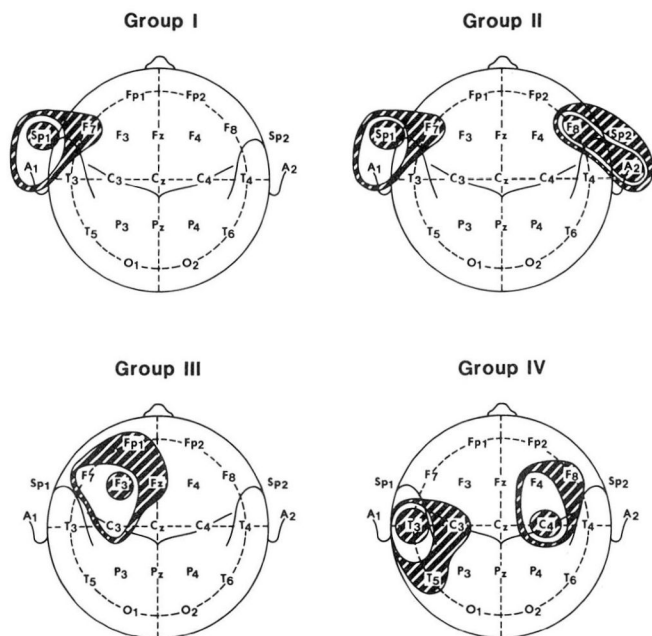


FIGURE 3. Noninvasive video/EEG monitoring.

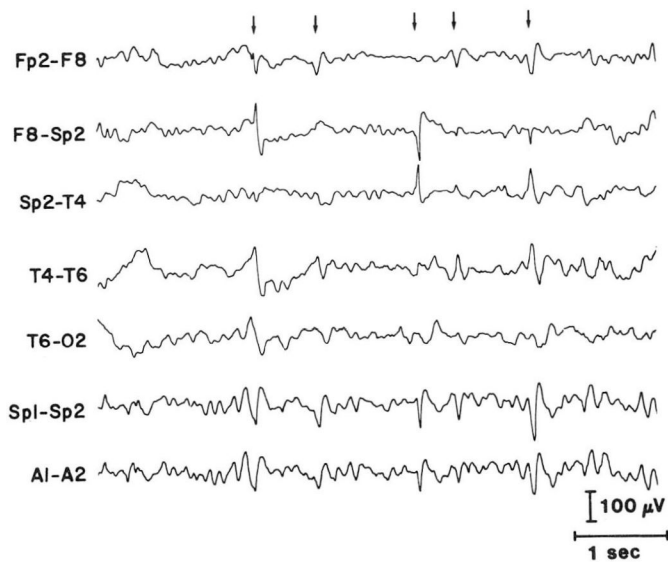


FIGURE 4. Variable spike distribution in a 37-year-old man with complex partial seizures since the age of 9 (measles encephalitis).

for quite different strategies.

It is important to analyze a sufficiently extensive sample of EEG to avoid *sampling errors*. For example, what may appear as a unique focus in the initial evaluation may eventually turn out to represent an

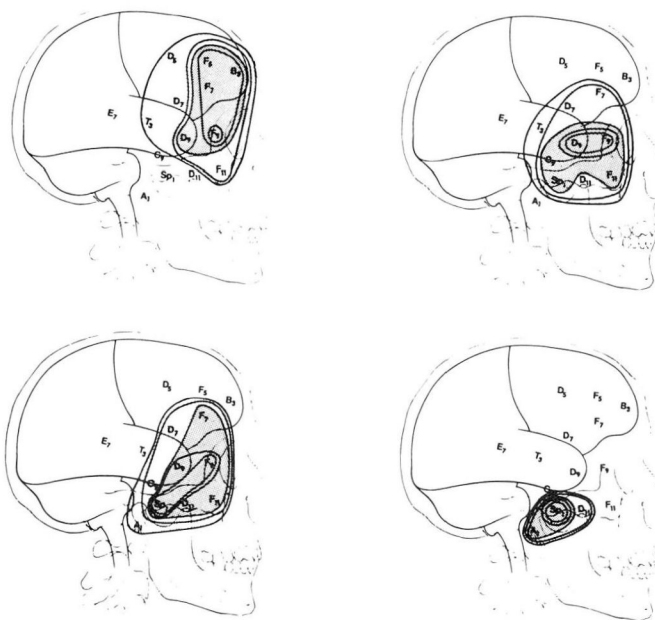


FIGURE 5. Variable spike distribution in a 37-year-old man with complex partial seizures since the age of 9 (measles encephalitis).

extensive epileptogenic zone, or bilateral independent epileptogenic foci which may be extremely variable. In some cases this variability is evident in short samples (Figures 4 and 5) but in other cases it is evident only after prolonged recordings.

The typical example is a patient who during one hospitalization (five or more days of recording) shows spikes arising exclusively from one side and, only on a second hospitalization, several spikes arising from the contralateral hemisphere. This variability of spike distribution is most probably due to existence of an extensive epileptogenic zone with multiple independent spike foci (Figure 6).

The duration of the work-up varies from one case to another; but at the Cleveland Clinic Foundation we always require a minimum of two separate five-day video/EEG monitoring sessions to assure that the collected information is consistent.

The main objective of noninvasive video/EEG monitoring is to define as precisely as possible the distribution of interictal epileptiform activity and the distribution of the ictal pattern at onset of clinical seizures. Eighteen-channel EEG recordings using a routine ("double banana") montage are used initially. The interictal epileptiform activity gives the initial orientation regarding localization of the epileptogenic focus.

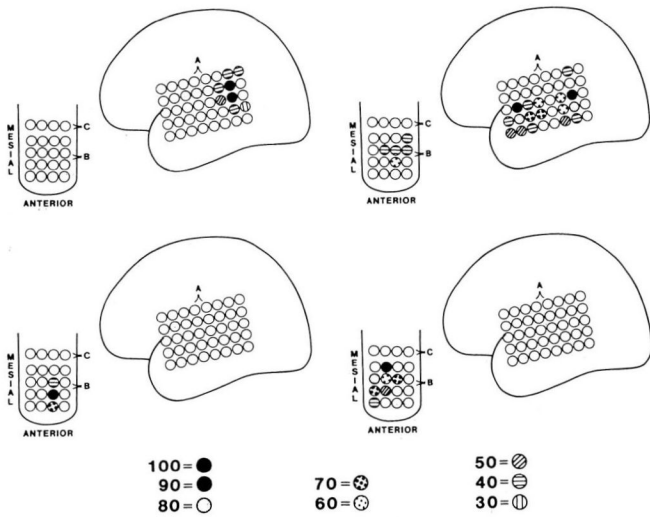


FIGURE 6. Variability of interictal sharp wave distribution in 26-year-old patient with complex partial seizures with secondary generalization since the age of 18.

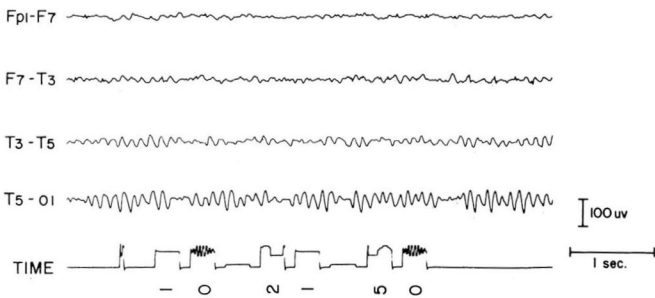


FIGURE 7. EEG time synchronization.

Additional closely spaced electrodes are then fixed in the surrounding region of the standard 10 to 20 system electrodes which show maximum activity, and a referential recording to a relatively inactive electrode is carried out.² For this purpose one or two additional 16 to 19 channel EEG machines are used. One channel of each EEG machine is always sacrificed to align the time axis of the recordings of the different EEG machines (Figure 7).³

The purpose of these referential recordings is primarily to distribute the epileptiform discharges as precisely as possible (Figures 8 and 9).

The electroencephalographer usually reviews only the routine recording identifying the epileptiform discharges. The routine EEG recording covering the whole brain is also extremely important for sampling purposes. Special distribution studies of all the sharp

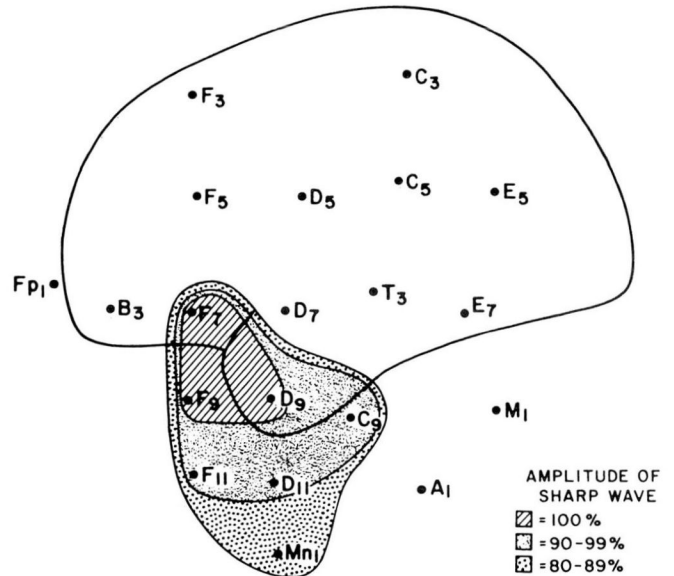


FIGURE 8. Distributions of sharp wave: 10/20 and extra electrodes.

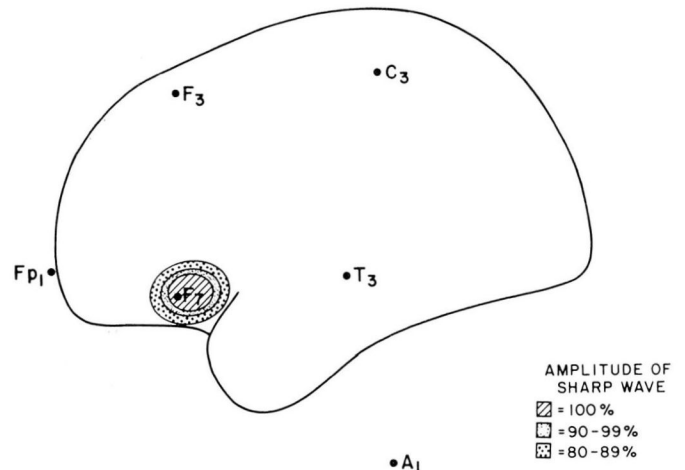


FIGURE 9. Distributions of sharp wave: 10/20 electrodes only.

waves of interest are made, using the simultaneously running referential recordings. This includes the typical sharp waves (sharp waves occurring most frequently) and also others with apparently different distributions. This system not only defines with precision the distribution of the typical spikes but also gives an estimate of its variability over time (Figures 5 and 6). Careful analysis of the routine EEG is also extremely necessary to select independent spike foci which may have a completely different distribution (for

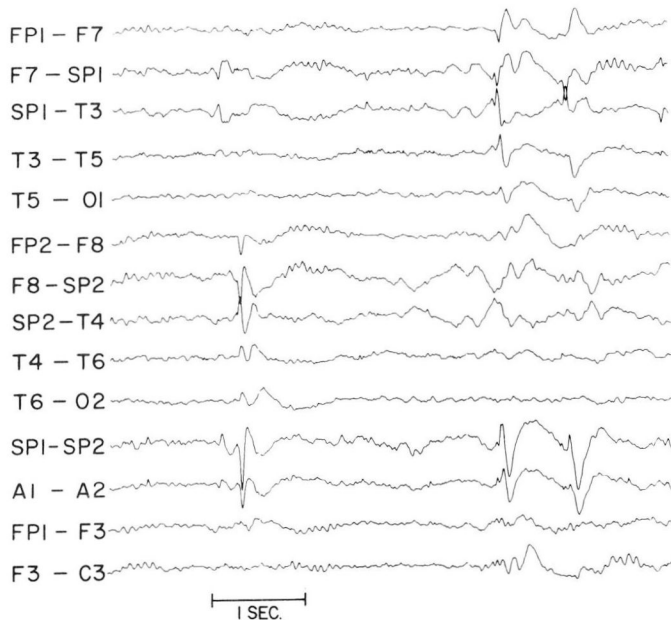


FIGURE 10. Bilateral independent mesial temporal sharp waves in 26-year-old female with complex partial seizures since the age of 5.

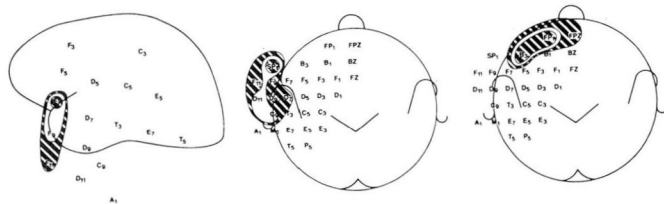


FIGURE 11. Errors of distribution due to inadequate electrode coverage: temporal vs frontal sharp waves.

example, independent right temporal foci in a case that initially had shown only left temporal foci) (Figure 10).

Distribution maps obtained from the referential recordings are considered adequate only when the maximum of the spike is surrounded in all four directions by discharges of significantly smaller activity. (The maximum of the spike is arbitrarily defined as all electrodes with discharges at least 80% higher than the electrode with the maximum (100%) discharge. (See Figure 11.)

Additional closely spaced electrodes have to be placed if the initial referential recordings yield inadequate distributions. This is extremely frequent when one is dealing with extensive epileptogenic zones or bifocal/multifocal spike foci.

Patients with complex partial seizures should rou-

tinely be evaluated with bilateral sphenoidal electrodes in addition to closely spaced electrodes placed over one or both temporal regions. In these cases the routine montage should include recordings from both sphenoidal electrodes (Figure 10). Recordings from sphenoidal electrodes are of invaluable help in identification of the frequent cases with mesial temporal epileptogenic foci.

CLASSIFICATION OF PATIENTS

Patients are then classified in four categories according to the results of this initial noninvasive video/EEG monitoring. Figure 12 shows a summary of the work-up procedure applied in these four groups of patients.

Group I: unilateral mesial temporal spike foci

This is an extremely important group that includes nearly half the patients usually found in a presurgical evaluation protocol. The characteristic feature is the occurrence of interictal sharp waves which are maximum at the sphenoidal electrodes and/or less frequent at anterior temporal electrodes (Figure 13).

Figure 5 includes a typical sharp-wave maximum at Sp2 in the lower right-hand side and a typical anterior temporal sharp wave, not maximum at Sp2, in the upper right-hand side. Foci with maximum at or more posterior than T3 or T4 are considered nonmesial temporal; they need a special evaluation (see below). The clinical seizures of patients with mesial/anterior temporal foci consist of typical psychomotor seizures (complex partial seizures). The seizure onset is usually on the same side as the interictal spike focus (even if the ictal onset is frequently much less clearly localizable than the interictal spike focus).

These cases, we feel, do not need invasive studies if the rest of the presurgical work-up information is convergent. However, to assure adequate sampling, a second week of noninvasive video/EEG recording is done before the final surgery.

In these patients, final surgery consists of a limited resection of the anterior temporal lobe (2.5 to 4.0 cm) to assure adequate access to the mesial temporal structures, followed by resection of the amygdala, the anterior portion of the hippocampus and the adjacent basal temporal structures (Figure 14).

Group II: bilateral mesial temporal spike foci

Approximately 10% to 20% of patients evaluated in epilepsy surgery centers are found in this group. It

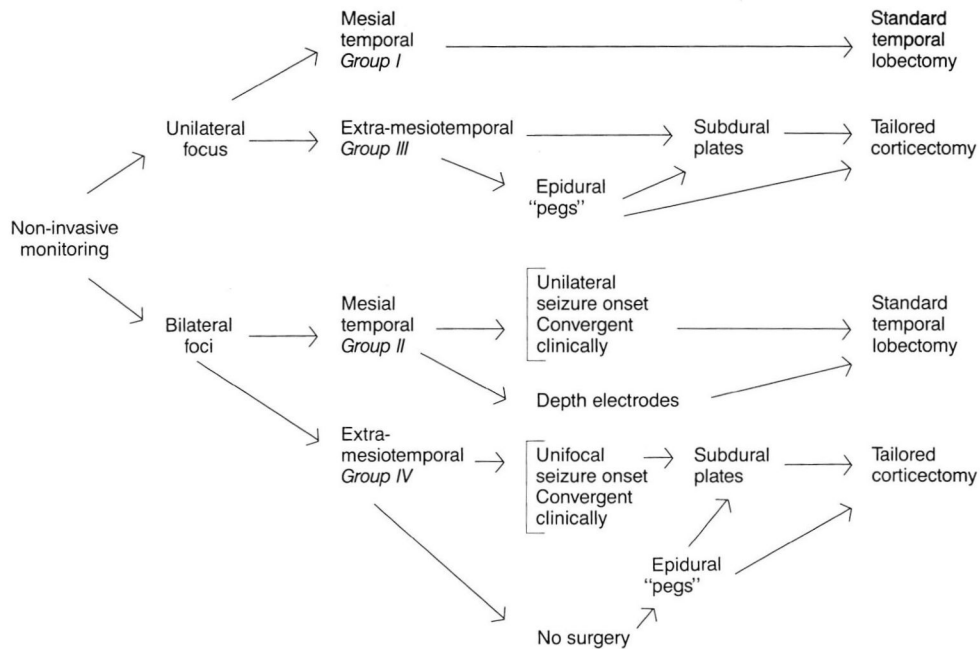


FIGURE 12. Summary of procedure for classification of patients.

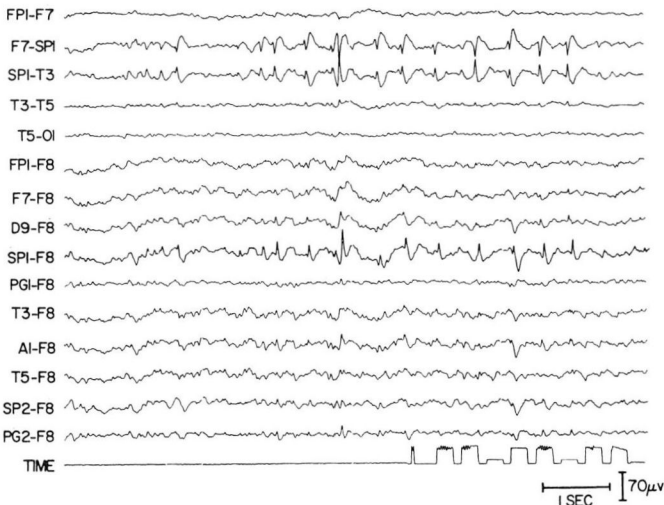


FIGURE 13. Mesial temporal sharp waves in 24-year-old patient with 10-year history of complex partial seizures.

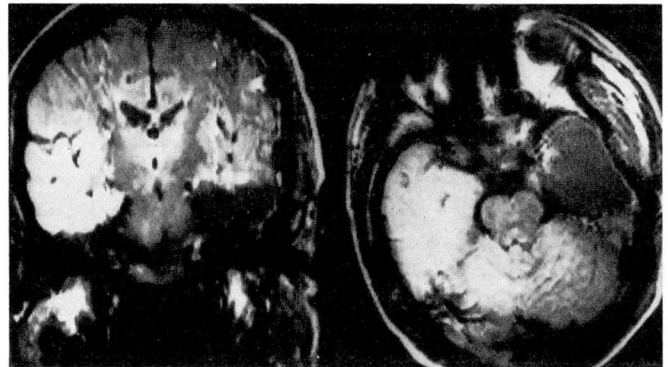


FIGURE 14. Standard anterior temporal lobectomy (with amygdalo-hippocampectomy).

includes a number of subgroups represented mainly but not exclusively by the following:

- a. Patients with spike foci arising independently from the left and right mesial temporal and/or anterior temporal region. Patients with bilateral independent sharp waves are frequently considered for a standard temporal lobectomy without

additional invasive recordings (see Group I) if they have (1) seizures which on scalp recordings arise consistently from one hemisphere and (2) other convergent clinical evidence strongly pointing to the same hemisphere from which the seizures arise (for example, an MRI lesion in the mesial temporal lobe).

- b. Patients with unilateral mesial and/or anterior temporal interictal spikes and complex partial seizures apparently arising from the contralateral hemisphere.

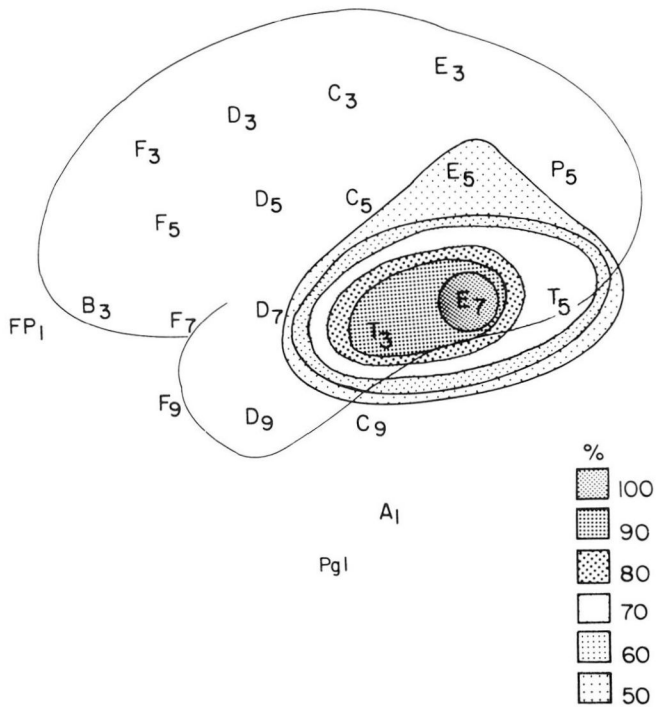


FIGURE 15. Distribution of interictal sharp waves in a patient with complex partial seizures arising from the convexity of the left temporal lobe.

Patients in this group require evaluation with bilateral *depth electrodes* to determine the side of seizure origin. The surgical resection performed in cases where depth recordings demonstrate consistent unilateral origin of seizures is identical to surgery in which the scalp recording demonstrates a unilateral mesial temporal focus.

Group III: unilateral nonmesiotemporal epileptogenic focus or zone (temporal convexity and extratemporal)

This category includes all cases in which the focus is clearly lateralized but not maximum at mesial temporal electrodes (sphenoidal or nasopharyngeal electrodes) and/or anterior temporal electrodes (temporal electrodes located anterior to T3/T4) (Figure 15).

These cases tend to be significantly more complicated than mesial temporal epilepsies. Attempts to localize the focus with scalp electrodes are frequently difficult even if focus lateralization is usually possible. In some cases, no clearly defined ictal and/or interictal epileptiform discharges are visible with scalp electrodes. This is due to (1) muscle artifact during the seizures which obscures the EEG activity, or (2) ex-

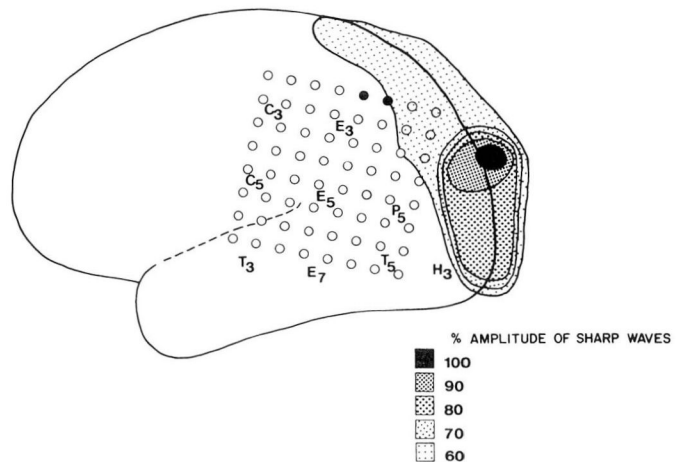


FIGURE 16. Seizure onset (scalp and subdural electrodes).

tremely limited spike foci (usually over the motor strip), or (3) poorly synchronized multifocal spike foci which do not reflect at surface electrodes. Many of these cases are eventually evaluated with subdural electrodes.

In the infrequent cases within this category which show with scalp electrodes a well-defined focus of relatively limited area of distribution, the next step in the evaluation consists of the placement of subdural electrodes covering the focus and its immediate surrounding area.⁴ EEG recordings from subdural electrodes then permit exact definition of the extent of the epileptogenic focus (defined by the distribution of the interictal sharp waves) and of the origin of the seizures. In addition, electrical stimulation and other neurophysiologic methods permit exact delineation of the functional areas in the immediate surrounding or, occasionally, in the epileptogenic focus itself.^{5,6}

Unfortunately, many of the cases included in this category have relatively extensive foci, or foci which are extremely difficult to localize with scalp electrodes. In these cases, scalp recordings do not provide information sufficient for making a decision on where to place a plate of subdural electrodes. Attempts to use this technique in spite of these limitations not infrequently fail to provide the required information. In occasional cases, the focus is missed completely. More frequently the focus is at the periphery of the subdural plate and, therefore, its maximum and certainly the extent of the epileptic focus cannot be determined (Figure 16).

Recently we have been using epidural “pegs,” since they are less invasive, as a preliminary evaluation in an

attempt to better define localization of the focus before attempting placement of subdural electrodes. The method consists of the placement of 10 to 15 epidural peg electrodes through a small scalp incision and burr holes (around 4 to 5 mm). Preliminary results with this method are good. We hope that in many cases it will permit better identification of the approximate margins of the epileptic zone, leading to more precise insertion of subdural electrodes. This, however, is not always the case. We have seen patients whose epidural pegs defined an extensive epileptogenic zone, which indicated before insertion of subdural electrodes that surgery was contraindicated.

Patients of Group III should have a tailored surgical intervention with complete resection of the epileptogenic focus as long as no functionally important tissue is included. When the epileptogenic zone overlies functionally important cortex, the resection should not extend closer than 1 cm from the functionally important cortex as defined by neurophysiologic methods.

Group IV: bilateral nonmesial temporal epileptogenic foci or zones

Resective surgery is almost invariably contraindicated in these cases. The only exception is the patient whose extensive preliminary surface work-up indicates that all seizures arise from a relatively discrete focus on one side, suggesting that the other focus or foci are clinically silent. As in all situations noted above, other clinical information and particularly the seizure type should be *convergent* with the EEG localization to a single discrete focus.

RESULTS OF EPILEPSY SURGERY IN CHILDREN

Over the past ten years at the Cleveland Clinic Foundation we have used essentially identical presurgical evaluation methods and surgical strategies in children and adults. This has allowed us to compare the methodology and results obtained in these two groups and to provide some answers to the questions listed at the start of this review.⁷ In this study 61 patients (23 children 3 to 18 years old and 38 adults 20 to 41 years

old) were evaluated with chronically implanted subdural electrodes. The only significant differences between the two groups were age at onset of seizures and the greater incidence of neuroimaging abnormalities in children. Otherwise, the two groups were similar in seizure type, frequency of abnormalities in neurologic examination, and IQ. Chronic implantation of subdural electrodes was tolerated well in adults and in children and the incidence of complications was the same in both groups. Wada tests were performed successfully in all adults and in all children with the exception of the two youngest ones, who were 3 and 4 years old. Cortical stimulation was carried out in 91% of the children and in 79% of the adults, and in all cases provided useful information. The size of the dominant or nondominant temporal lobe resections was the same in both groups. Results were also similar in adults and children, with temporal lobe patients showing a relatively higher success rate in comparison to extratemporal patients.

This study, therefore, indicates that children tolerate essentially the same presurgical work-up methodology as adults and that there is no indication that surgery of epilepsy is less successful when performed in a younger age group. A very important question that still remains, however, is the identification of seizures which continue to be intractable even with maturation. To answer this question, we need to characterize the seizures very precisely shortly after onset, using the same detailed noninvasive video/EEG work-up described above, and follow patients in a prolonged longitudinal study to establish the effect of maturation on different types of focal seizures. This method should allow us then to identify markers which permit prediction of intractability not affected by maturation. Such a study is still unavailable. However, there is some less conclusive evidence that temporal lobe epilepsy, at least, has a low spontaneous remission rate in children, as well as in adults.⁸

HANS LÜDERS, MD
 Department of Neurology
 The Cleveland Clinic Foundation
 9500 Euclid Avenue
 Cleveland, Ohio 44106

REFERENCES

1. Lesser RP, Lüders H, Morris HH, et al. Some comments regarding extracranial EEG evaluation electroencephalography. [In] Engel J, ed. *Surgical Management of the Epilepsies*. New York, Raven Press, 1987, pp 173–179.
2. Morris HH III, Lüders H, Lesser RP, Dinner DS, Klem GH. The value of closely spaced scalp electrodes in the localization of epileptiform foci: a study of 26 patients with complex partial seizures. *Electroencephalogr Clin Neurophysiol* 1986; **63**:107–111.
3. Ives JR. "Time-Scribe": A universal time-writer for any EEG/polygraph chart recorder. *Electroencephalogr Clin Neurophysiol* 1984; **57**:388–391.
4. Lüders H, Lesser RP, Dinner DS, Morris HH, et al. Commentary: Chronic intracranial recording and stimulation with subdural electrodes. [In] Engel J, ed. *Surgical Treatment of the Epilepsies*. New York, Raven Press, 1987, 297–321.
5. Lesser RP, Lüders H, Klem G, Dinner DS, Morris HH, Hahn JF, Wyllie E. Extraoperative cortical functional localization in patients with epilepsy. *J Clin Neurophysiol* 1987 **4**(1):27–53.
6. Lüders H, Dinner DS, Lesser RP, Morris HH. Evoked potentials in cortical localization. *J Clin Neurophysiol* 1986; **3**:75–84.
7. Wyllie E, Lüders H, Morris HH, Lesser RP, Dinner DS, Hahn J, Estes ML, Rothner AD, Erenberg G, Cruse R, Friedman D. Subdural electrodes in the evaluation for epilepsy surgery in children and adults (submitted to *Neuropediatrics*).
8. Wyllie E, Lüders H. Complex partial seizures in children: Clinical manifestations, and identification of surgical candidates. *Cleve Clin J Med*, 1988; **56**:S-43–S51.