



Rapid identification of the external jugular vein

MARK JAROCH, MD AND EZRA STEIGER, MD

■ The authors describe a rapid technique to identify the course of the external jugular vein based on the location of the cephalic vein or the deltopectoral groove.

□ INDEX TERM: JUGULAR VEINS □ CLEVE CLIN J MED 1990; 57:95-96

LONG-TERM Silastic catheters are being used with increasing frequency in patients requiring home intravenous therapy, including total parenteral nutrition, antibiotics, chemotherapy, and intravenous analgesics. In addition, many hospital patients require single-, double-, and triple-lumen catheters for chemotherapy and bone marrow transplantation.

Catheters can be placed percutaneously or by cutdown over a tributary vein. Venous cutdown avoids the risks of pneumothorax and major vascular bleeding, especially in patients with low platelet counts or clotting defects. Common tributary veins for cutdown include the cephalic, external jugular, and internal jugular veins. Less commonly used are saphenous veins, subcutaneous chest wall collaterals, intercostal veins, or direct placement into the right atrium.

Although we are usually able to place multilumen Silastic catheters into the cephalic vein, we have encountered a number of patients whose cephalic veins at the time of operation were not suitable for catheter insertion, either because of small vein size or thrombosis. Our next preference for catheter insertion is the exter-

nal jugular vein. While this vein may be easily seen in many patients, it can be difficult to identify if the patient is dehydrated, obese, or has a short neck.

Specific comment on the spatial relationship of these veins is not found in most standard anatomy texts. In a recent anatomic study of the cephalic vein in cadavers, a 7% incidence of communication was identified between the cephalic and external jugular veins.¹ Current literature on external jugular venous access focuses on methods for percutaneous cannulation of a visible external jugular vein. Catheter insertion by external jugular venotomy is a common technique and in most cases the vein is readily visualized.² Our description provides a simple and reliable technique to place an incision for cutdown accurately on the external jugular vein, which may not be visible or palpable at the time of operation.

TECHNIQUE

We have observed that the external jugular vein can be identified by a line drawn over the cephalic vein (or deltopectoral groove) onto the neck at a point one finger breadth above the clavicle, with the patient's head turned to the contralateral side. Dissection through a transverse incision made at this intersection will allow identification of the vein.

Figure 1 demonstrates the relationship between the deltopectoral groove and the external jugular vein. In

From the Department of General Surgery, The Cleveland Clinic Foundation.

Address reprint requests to M.J., Akron Clinic, 3600 W. Market Street, Akron, Ohio 44313.

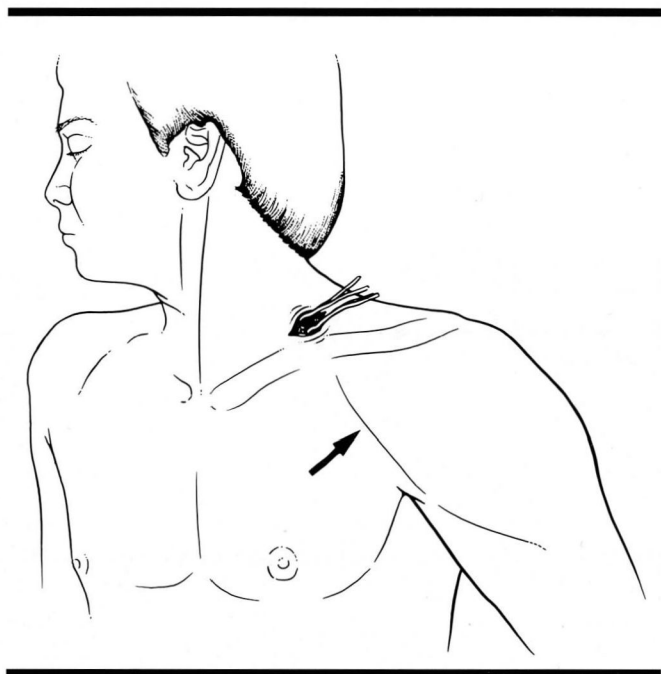


FIGURE 1. Relationship of deltopectoral groove (arrow) and external jugular vein cutdown.

the event that the external jugular vein is not suitable for catheter insertion, the incision can be extended medially for access to the internal jugular vein. *Figure 2* shows a healed incision in the deltopectoral groove (overlying the cephalic vein) pointing to a visible external jugular vein. Knowledge of this relationship facilitates identification of the vein when it is not visible.

REFERENCES

1. Chuter T, Starker PM. Placement of Hickman-Broviac catheters in the cephalic vein. *Surg Gynecol Obstet* 1988; **166**:163–164.

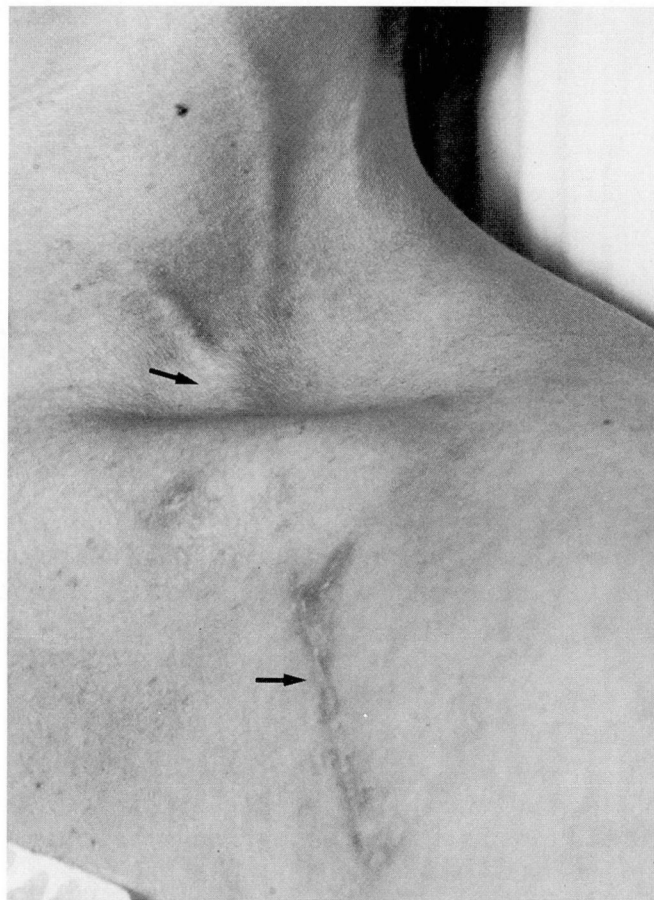


FIGURE 2. Relationship of a healed incision (lower arrow) placed over the deltopectoral groove and a visible external jugular vein (upper arrow).

2. Au FC, De Feo J, Lightfoot WP. Right atrial catheter insertion through the external jugular vein. *Surg Gynecol Obstet* 1979; **149**:735–736.