



The acute abdomen in the geriatric patient

DAVID P. VOGT, MD

■ Evaluating an elderly patient with an acute abdomen is a challenging clinical problem. The diagnosis is more difficult to secure in this age group, because it is difficult to obtain an accurate history, and physical findings are more subtle. The major factors that increase mortality include associated medical diseases, emergent operations, and delay in recognition and treatment of the problem. Patients with widespread malignancy and generalized peritonitis fare poorly, but operative mortality in the geriatric group has improved significantly because of more prompt diagnosis, aggressive resuscitation, precise monitoring, and expedient but definitive procedures. As the proportion of elderly patients in the population continues to rise, it becomes increasingly important to evaluate and manage this problem expediently.

□ INDEX TERMS: ABDOMEN, ACUTE; GERIATRICS □ CLEVELAND CLINIC JOURNAL OF MEDICINE 1990; 57:125-130

EVALUATION of acute abdomen is an especially challenging clinical problem in the elderly, although an acute abdomen requires urgent attention regardless of the patient's age. When evaluating a patient with an acute abdomen, two questions must be answered immediately: Does the patient need an operation? If so, how soon?

Management decisions about the elderly patient with an acute abdomen are complicated by issues of quality of life, both pre- and postoperatively, and by the patient's ability to give consent for operation.¹ This situation is encountered more often as the number of people older than 65 years increases. Since 1970, this population has increased 23% and now represents 11.2% of the entire US population.²

It is more difficult to establish a diagnosis in geriatric patients with acute abdominal problems. Associated

medical diseases complicate the picture further, and hospitalization is often prolonged. Despite these difficulties, the operative mortality for emergency or early operations in the elderly has declined over the last 20 years. Factors responsible for the improved survival include earlier diagnosis, appropriate but aggressive resuscitation, expedient surgery, and precise monitoring.³

ETIOLOGY

The major etiologies of the acute abdomen in the elderly include biliary disease, intestinal obstruction, perforated peptic ulcer, diverticulitis, and appendicitis (Table 1). Less frequent but more lethal problems include ruptured abdominal aortic aneurysm and acute intestinal ischemia. Pancreatitis is also encountered, usually secondary to calculous biliary disease.

An incarcerated hernia and adhesions from a prior laparotomy are the usual causes of small bowel obstruction. Large bowel obstruction in the aged is predominantly the result of colon carcinoma, although diverticulitis and sigmoid volvulus are other possibilities that should be considered.

From the Department of General Surgery, The Cleveland Clinic Foundation.

Address reprint requests to D.P.V., Department of General Surgery, The Cleveland Clinic Foundation, One Clinic Center, 9500 Euclid Avenue, Cleveland, Ohio 44195.

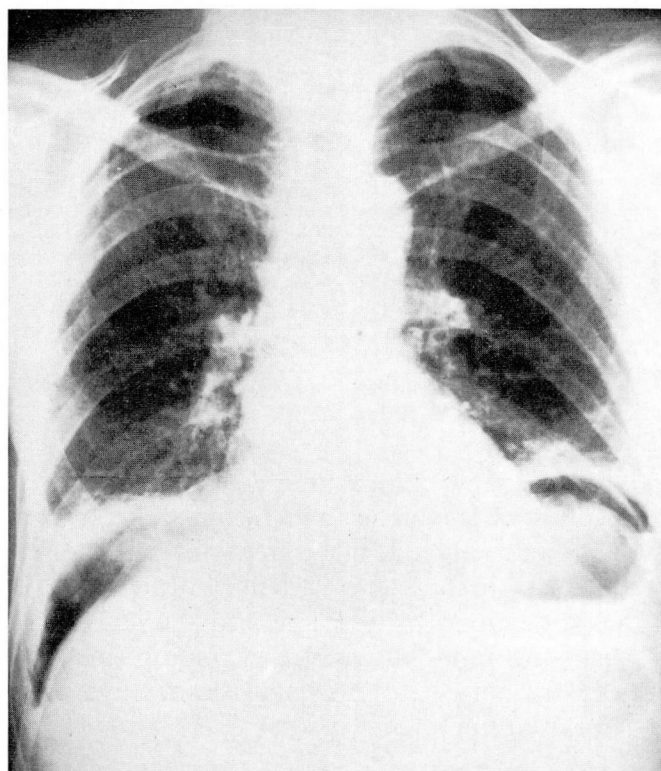


FIGURE 1. Upright chest X-ray demonstrating free air under the diaphragm in a patient with a perforated duodenal ulcer.

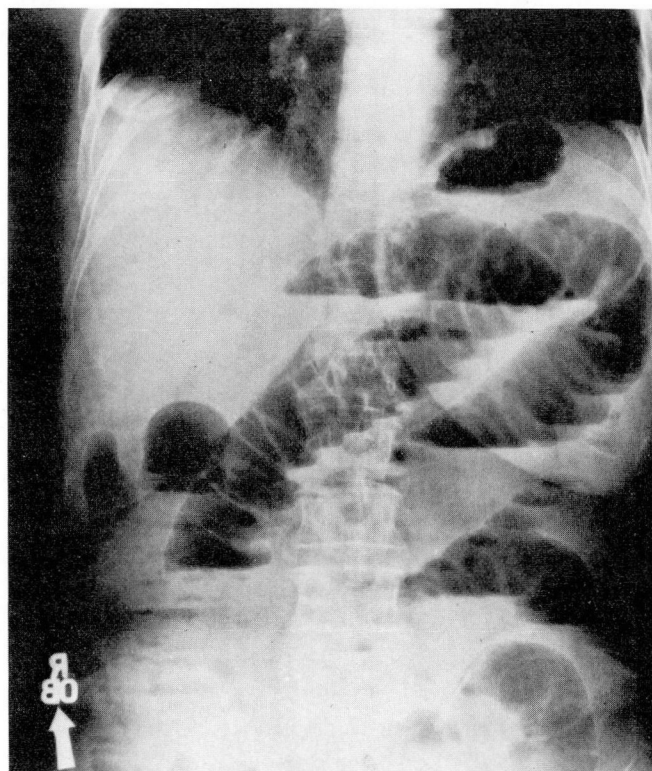


FIGURE 2. Typical "stepladder" pattern of dilated small intestine in a patient with a mechanical small bowel obstruction.

TABLE 1
CAUSES OF ACUTE ABDOMEN IN THE ELDERLY

Major causes
Biliary disease
Intestinal obstruction
Small bowel
Incarcerated hernia or adhesions from prior abdominal surgery
Large bowel
Carcinoma
Diverticulitis
Volvulus
Perforated peptic ulcer
Appendicitis
Pancreatitis secondary to calculous biliary disease
Less common but more lethal causes
Ruptured abdominal aortic aneurysm
Acute intestinal ischemia

DIAGNOSTIC WORKUP

History and physical examination

The etiology of an acute abdomen is more difficult to establish in the elderly patient for several reasons. Obtaining an accurate history from the patient may be vir-

tually impossible because of senility, previous strokes, hearing and speech difficulties, and a reluctance to seek medical aid. To interview a younger family member who has observed the development of the illness may be of great assistance. Stoicism, arthritic conditions, and inability to localize tenderness interfere with the physical examination.⁴ However, the physical examination is still of key importance in the elderly, and a thorough examiner must be able to appreciate subtle peritoneal signs. All potential hernia sites require close inspection.

Laboratory data

Routine laboratory data are important in evaluating the geriatric patient with acute abdominal pain. Studies should include a complete blood count, kidney profile, electrolytes, serum amylase, and urinalysis. Just as elderly patients often do not generate a febrile response to infection, the absence of leukocytosis does not dismiss the possibility of surgical intra-abdominal disease. A marked leukocytosis of 20,000/ μ L or greater, however, may reflect intestinal ischemia. Chronic anemia, dehydration, and electrolyte disturbances are not uncommon.

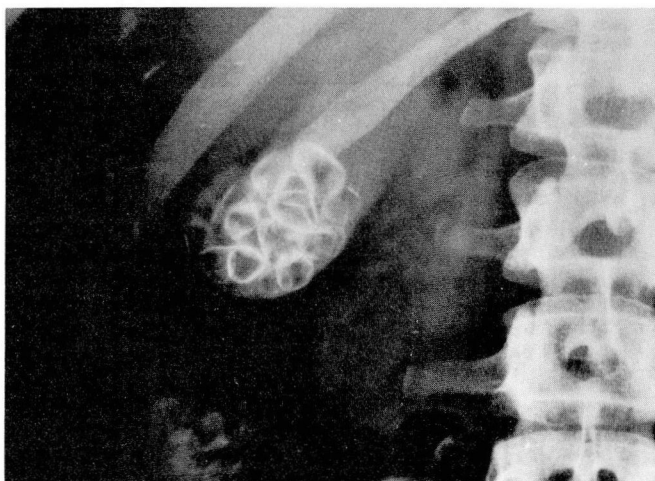


FIGURE 3. Radiopaque gallstones in the right upper quadrant.

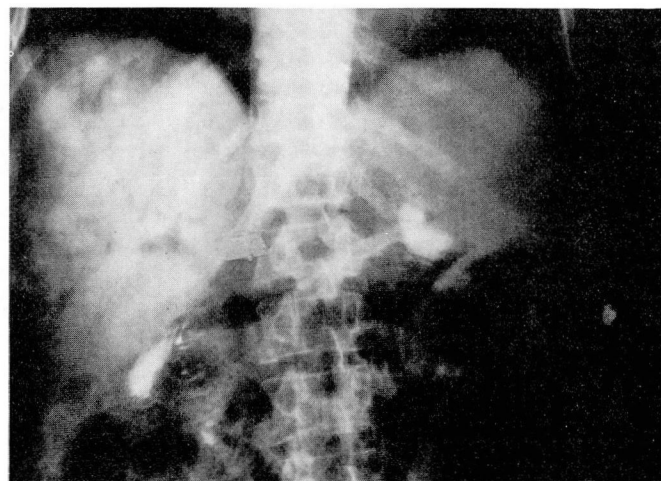


FIGURE 4. Gas in the portal venous system in the liver, indicative of intestinal gangrene.

mon, and an elevated amylase suggests acute pancreatitis. An electrocardiogram is essential since coronary insufficiency may mimic an abdominal catastrophe.

Radiographic studies

Several radiographic techniques are valuable in assessing a geriatric patient with an acute abdomen. These studies include plain films, ultrasound, hepatobiliary scanning, intravenous pyelography, and visceral angiography. Plain films may be diagnostic in up to 50% of patients by demonstrating free air indicative of gastrointestinal perforation, a stepladder pattern of air fluid levels suggesting a mechanical bowel obstruction, a radiopaque gallstone, or gas within the portal venous system associated with intestinal infarction (*Figures 1–4*).⁵ Ultrasonography is useful in evaluating the biliary tree, pancreas, and aorta. This examination claims over 90% accuracy in detecting gallstones,⁶ and abdominal aortic aneurysms can be measured accurately and noninvasively. Hepatobiliary scanning is 95% reliable in diagnosing acute cholecystitis in the nonfasting patient.⁶ A patient suspected of having renal colic requires an intravenous pyelogram (*Figure 5*). Angiograms of the superior mesenteric artery and inferior mesenteric artery are of key importance in evaluating a patient with suspected acute mesenteric insufficiency.

Operative risk

An attempt should be made to identify elderly patients who are at particularly high risk to develop intraoperative or perioperative problems. High risk factors include associated diseases such as coronary athero-

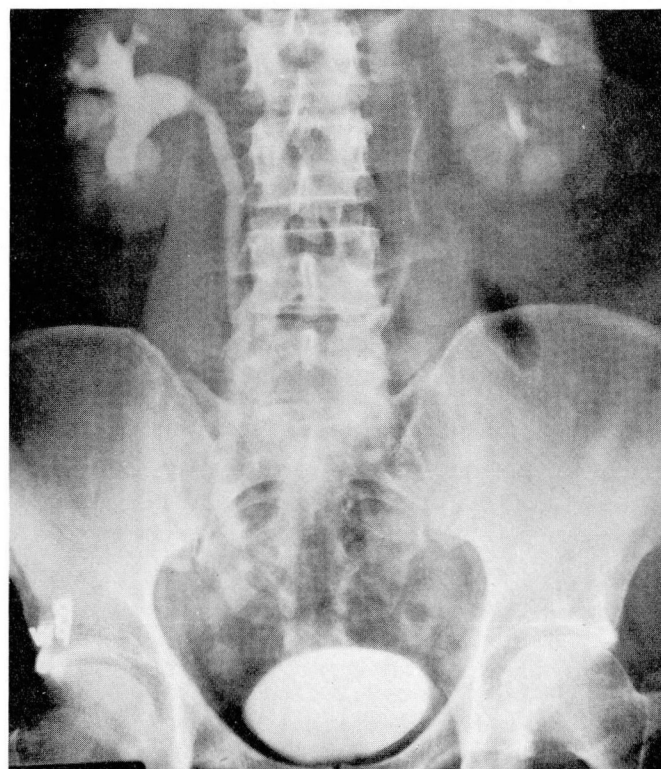


FIGURE 5. A dilated right ureter in a patient with a distal stone.

sclerosis, chronic obstructive pulmonary disease, renal insufficiency, diabetes mellitus, hypertension, and cirrhosis.⁷ Patients with severe arteriosclerotic heart disease require preoperative placement of a mean arterial

pressure line and a Swan-Ganz catheter. A temporary pacemaker may be indicated in a patient with heart block. Baseline arterial blood gases and, if possible, preoperative screening spirometry aid in the management of the patient with pulmonary disease. Occasionally, preoperative hemodialysis is necessary in patients with significant renal impairment.

MANAGEMENT

Management of the elderly patient with an acute abdomen generally falls into one of five settings:

1. The diagnosis is known, such as a ruptured abdominal aortic aneurysm, and immediate operation is indicated.
2. The diagnosis is established, and early surgery is required after appropriate resuscitation, as with a perforated ulcer or appendicitis.
3. Although the diagnosis is known, the initial management is nonsurgical, as with cholecystitis, diverticulitis, or small bowel obstruction secondary to adhesions.
4. The diagnosis is not certain, but the presence of peritonitis demands urgent exploration.
5. The diagnosis is not known, and peritonitis is not present, allowing the patient to undergo further studies and conservative management.

How much preoperative preparation and resuscitation is required depends upon which of the above categories applies. A patient with a ruptured abdominal aortic aneurysm requires simultaneous resuscitation and emergency surgery. If immediate surgery is not necessary, volume and electrolyte imbalances must be corrected. In many cases, broad-spectrum antibiotics are started, depending upon the presumed source of intra-abdominal pathology. Since elderly patients are at an increased risk to develop postoperative deep vein thrombosis, preventive measures are indicated, such as miniheparin or intermittent pneumatic stockings.⁸

Operative mortality

The operative mortality for acute abdominal surgical problems in the elderly is 15% to 20% overall. Factors affecting outcome include age, complicating diseases, timing of the operation, length of the time from onset of the problem until surgery, presence of malignancy, generalized peritonitis, and prolonged operations.³ Although chronologic age does not appear to be as important as apparent physiologic age, the geriatric patient does have less reserve, especially in the presence of sepsis.⁹ Almost 70% of patients over age 70 have a complicating obstructive pulmonary disease, diabetes mellitus,

hypertension, or renal insufficiency.³ Patients with significant associated medical diseases have roughly twice the operative mortality of their healthier counterparts.^{3,9} Mortality for emergency operation is 16% to 23%, in contrast to the 5% to 8% mortality for elective operation.^{1,3-4,9-11} As expected, patients with gastrointestinal perforations, either of the duodenum or colon, fare better if they undergo surgery less than 48 hours from the onset of symptoms.³

The decline in operative mortality in the aged over the last two decades is due to several factors. Early operations (within 48 hours of admission) allow better preoperative diagnosis, aggressive resuscitation, and fewer negative laparotomies.³ Sophisticated preoperative, intraoperative, and postoperative monitoring, especially in the intensive care unit, affords precise management of fluid replacement, arrhythmias, and congestive heart failure. The best surgical procedure is one that is accurate, expedient, and minimal but adequate.^{1,10} When possible, one-stage or definitive operations should be performed.¹ In spite of the general improvement in operative mortality in the geriatric age group, patients with widespread malignancy still do poorly.¹

SPECIFIC CAUSES

It is beyond the scope of this paper to discuss every possible etiology of the acute abdomen in the elderly. The emphasis has been placed rather on how to evaluate the elderly patient and identify the factors that increase the risk of operation. A few specific entities are discussed in more detail because they are common or because they carry a high mortality.

Biliary disease

Biliary disease is the most common problem requiring urgent operation in the geriatric age group.^{1,12} The incidence of gallstones increases with age; only 9% of patients between 30 and 40 years of age have gallstones, in contrast to 50% of patients during their eighth decade of life.¹² Approximately 20% of elderly patients will present with complicated biliary disease such as acute cholecystitis, sepsis, jaundice, or common bile duct stones.¹²

Ultrasonography and hepatobiliary scanning are the two preferred diagnostic techniques in the acute setting. The former modality may demonstrate gallstones, as well as a thickened gallbladder wall and fluid in the gallbladder area. A nucleide scan detects cystic duct obstruction, which is necessary for the development of acute cholecystitis. The latter study is accurate in over

95% of patients who have not been fasting.⁶ Preoperative resuscitation includes intravenous fluids as well as antibiotics. Although very few patients require an emergency cholecystectomy, the majority of patients should be operated on within 72 hours of admission.

Huber et al¹² reported operative mortalities of 2% and 14% in elective and emergent cholecystectomies, respectively. Similarly, Glenn¹³ reported a 9.8% operative mortality in patients over age 65 years undergoing an emergency biliary procedure. Based on these studies and others, Glenn concluded that elderly patients with truly asymptomatic stones do not require an elective cholecystectomy. However, once symptoms develop, an elective cholecystectomy is indicated. In both Glenn's and Huber's reports, the majority of postoperative deaths were the result of either cardiovascular disease or septic complications.^{12,13}

Appendicitis

Appendicitis occurs more frequently in the elderly, and up to 30% of elderly patients present with gangrene or perforation, in contrast to 15% in younger patients.¹⁴ As a result, operative mortality associated with acute appendicitis in the elderly may be as high as 12%.¹⁴ Although it is one of the most common inflammatory abdominal cavity lesions, acute appendicitis is often difficult to diagnose, especially in the elderly; it can mimic many other lesions and is a frequent cause of atypical findings on abdominal examination.

Bowel obstruction

Twenty-five percent of cases of acute abdomen in the elderly are due to bowel obstruction.¹

Small bowel obstruction. The most frequent causes of small bowel obstruction include incarcerated hernia and adhesions from a prior abdominal operation. Unfortunately, there are no clinical, laboratory, or radiographic parameters that can definitively differentiate between simple mechanical obstruction and strangulation.^{15,16} An incarcerated groin hernia requires immediate attention, and if gangrenous intestine is found, it can often be resected through the groin incision. Conservative therapy consisting of nasogastric suction and intravenous fluids is the initial approach for adhesive small bowel obstruction. However, if the patient does not demonstrate clear symptomatic improvement within 8 to 12 hours, surgical exploration is mandatory. Adequate intravenous hydration and prophylactic broad-spectrum antibiotics are essential.

Large bowel obstruction. Carcinoma, diverticulitis, and volvulus are the main etiologies of large bowel obstruction.

¹⁷ The elderly patient with a large bowel obstruction has an insidious onset of abdominal complaints and may not develop abdominal distention or vomiting for several days. In addition to abdominal distention, careful attention must be directed to any abdominal masses or rectal lesions. Nasogastric decompression and intravenous fluids are the mainstay of resuscitation. Diagnostic studies in addition to plain films include proctoscopy and a contrast study of the colon. If there is any suspicion of a perforation, water-soluble contrast such as Gastrografin should be used rather than barium. Further management depends upon the etiology of the obstruction.

An obstructing neoplasm requires laparotomy after appropriate resuscitation. If an obstructing left colon carcinoma is found, a Hartmann procedure should be performed, which consists of primary resection of the lesion, creation of an end-colostomy, and oversewing the rectal stump.¹⁷ Colonic continuity may then be reestablished after a few months.

The initial treatment for diverticulitis is conservative: nasogastric suction, intravenous fluids, and broad-spectrum antibiotics. An operation, usually a Hartmann procedure, is performed early only if the patient fails to improve after 48 hours or localized peritoneal signs become diffuse.¹⁸

A barium enema may be diagnostic for a sigmoid volvulus. The majority of patients are initially decompressed by gently passing the proctoscope through the volvulus and inserting a rectal tube. Several days later, the patient may be properly prepped for an elective sigmoid resection.⁷

Acute mesenteric ischemia

Although it is not common, acute mesenteric ischemia is the most fatal disease in the geriatric age group; the mortality rate is 80% to 100%.¹⁹ Approximately 75% of patients who develop acute intestinal ischemia are at least 70 years old.¹⁹ Emboli, thrombosis, and a low fluid state (nonocclusive ischemia) are the most frequent etiologies.¹⁹

Nonocclusive ischemia is often associated with congestive heart failure, digitalis, recent myocardial infarction, or dehydration.²⁰ Pain, often out of proportion to the physical findings, is the most frequent symptom associated with an ischemic insult to the intestine. Hypotension, tachycardia, frank peritonitis, and gastrointestinal bleeding are late signs, which carry a grave prognosis.^{19,20} Laboratory studies that are most helpful include leukocytosis, often greater than 20,000/ μ L; acidosis; and hyperamylasemia.^{19,20} Plain films of the abdo-

men may demonstrate gas in the portal venous system.

Initial resuscitation of a patient suspected of having acute mesenteric ischemia includes vigorous hydration, optimizing myocardial performance, and intravenous antibiotics. Further studies should include abdominal visceral angiography, if possible.

In patients whose angiogram demonstrates either an embolus or a thrombosis, emergent laparotomy is mandatory. Attempts should be made to revascularize the intestine and resect any nonviable portions. A second-look operation within the next 24 hours is important to assess the viability of the remaining intestine. Patients with nonocclusive mesenteric insufficiency should be treated initially with intra-arterial vasodilators, in the absence of frank peritonitis.²⁰ If there is improvement in the visceral circulation, this therapy is continued for the next 24 hours, and the angiogram is repeated. During that time, it is important to try to correct the underlying cause of the low cardiac output.

Operation is reserved for patients who develop infarctions of the gastrointestinal tract²⁰; if the majority of the intestine is found gangrenous, no resection should be performed.

POSTOPERATIVE COMPLICATIONS

Postoperative complications in the elderly are similar to those of younger patients; however, the incidence of pulmonary infections, decubitus ulcers, and deep vein thrombosis is greater.⁷ Aggressive postoperative bronchopulmonary hygiene is mandatory. Measures to reduce deep vein thrombosis and pulmonary emboli include subcutaneous heparin, intraoperative pneumatic stockings, and early postoperative ambulation.²¹

The urinary tract, surgical wound, and lungs are the most common sites of postoperative surgical sepsis in the elderly.⁷

REFERENCES

1. Reiss R, Deutsch AA, Eliashiv A. Decision-making process in abdominal surgery in the geriatric patient. *World J Surg* 1983; 7:522-526.
2. Bureau of Census. Current population reports. Series P-25, No. 870. Washington, DC, Department of Census, 1980.
3. Fenyo G. Acute abdominal disease in the elderly. *Am J Surg* 1982; 143:751-754.
4. Charlesworth D. The acute abdomen in the elderly. *Practitioner* 1972; 209:178-182.
5. Lee PW. The plain x-ray in the acute abdomen: a surgeon's evaluation. *Br J Surg* 1976; 63:763-766.
6. Rosenquist JC. Radiology of the biliary tree. *Surg Clin N Am* 1981; 61:775-786.
7. Mason JH, Gan FC, Byrne MP. General surgery. [In:] Steinberg FU, ed. *Care of the Geriatric Patient*. St. Louis, CV Mosby, 1983, pp 299-326.
8. Secker-Walker R, Potchen EJ. Radiology of venous thrombosis: current status. *Radiology* 1971; 101:449-452.
9. Stahlgren L. An analysis of factors which influence mortality following extensive abdominal operations upon geriatric patients. *Surg Gynecol Obstet* 1961; 113:283-291.
10. Herron PW, Jesseph JE, Harkins HN. Analysis of 600 major operations in patients over 70 years of age. *Ann Surg* 1960; 152:686-698.
11. Standeven A. The acute abdomen in the elderly. *Practitioner* 1979; 222:465-470.
12. Huber DF, Martin EW, Cooperman M. Cholecystectomy in elderly patients. *Am J Surg* 1983; 146:719-722.
13. Glenn F. Surgical management of acute cholecystitis in patients 65 years of age and older. *Ann Surg* 1981; 193:56-59.
14. Owens JW. Appendicitis in the elderly. *Ann Surg* 1978; 187:392-396.
15. Goldman L, Silen W. The threat of strangulation in acute intestinal obstruction. *Arizona Med* 1958; 15:337-341.
16. Silen W, Hein M. Strangulation obstruction of the small intestine. *Arch Surg* 1962; 85:137-145.
17. Greenlee HB, et al. Acute large bowel obstruction: comparison of county, Veterans Administration and community populations. *Arch Surg* 1974; 108:470-476.
18. Nunes GC, Robnett AH, Kremer RM, et al. The Hartmann procedure for complications of diverticulitis. *Arch Surg* 1979; 114:425-429.
19. Pierce GE, Brockenbrough EC. The spectrum of mesenteric infarction. *Am J Surg* 1970; 119:233-239.
20. Aldrete J, Kirklin JW, Han SY, Laws HL. Intestinal infarction complicating low cardiac output states. *Surg Gynecol Obstet* 1977; 144:371-375.
21. Sevitt S, Gallagher N. Venous thrombosis and pulmonary emboli: a clinicopathologic study in injured and burned patients. *Br J Surg* 1961; 48:475-489.