

# Disseminated cutaneous fungal infection and AIDS

HOWARD A. ORIBA, MD; JACOB S. LO, MD; WILMA F. BERGFELD, MD

■ We report a case of recalcitrant generalized cutaneous polydermatophyte and *Candida* infection in an AIDS patient who responded very poorly to topical, oral, and intravenous therapy. The patient died of respiratory arrest secondary to pneumonia 14 months after a cutaneous fungal infection developed and 12 months after AIDS was diagnosed. Extensive cutaneous fungal infections refractory to treatment may be a presenting sign of HIV infection.

□ INDEX TERMS: ACQUIRED IMMUNODEFICIENCY SYNDROME; DERMATOMYCOSES □ CLEVE CLIN J MED 1990; 57:189-191

**T**HE INCIDENCE and manifestations of cutaneous infections in patients with acquired immunodeficiency syndrome (AIDS) continue to receive increasing attention. We report an unusual presentation of recalcitrant widespread cutaneous fungal infection in an AIDS patient. We speculate that impaired cutaneous cell-mediated immunity in combination with nonfungicidal therapy can cause treatment of cutaneous fungal infections in AIDS patients to fail.

## REPORT OF A CASE

A 33-year-old homosexual man was in good health until May 1986 when he noted an erythematous, scaly plaque on his chest. He was treated initially with clotrimazole (Lotrimin) 1% cream, as prescribed by a local physician, without clinical response. In July 1986, the

patient developed an obscure febrile illness. He was subsequently found to be HIV antibody positive (ELISA confirmed by Western Blot technique) and had opportunistic infections including central nervous system toxoplasmosis, herpetic proctitis, thrush, thrush esophagitis, and cytomegalovirus viremia/viuria.

During July 1986, the patient developed additional scaly, erythematous plaques on the periorbital skin, chest, and scalp. He was evaluated in The Cleveland Clinic Foundation Department of Dermatology in September 1986, when KOH-positive scrapings confirmed the diagnosis of tinea corporis, and he was treated with griseofulvin, 250 mg by mouth twice daily. After 8 weeks of treatment without significant clinical improvement, we added topical econazole nitrate (Spectazole) cream twice daily. Again, no benefit was noted. At this time, we decided to discontinue his previous regimen and begin oral ketoconazole at 200 mg daily. After 4 weeks of oral ketoconazole therapy, no response was noted and the dose was increased to 400 mg daily. Still, no clinical benefit was noted. The patient was admitted to the Infectious Disease Service of The Cleveland Clinic Foundation in May 1987 for treatment of dehydration and altered mental status. The Department of Dermatology was asked to re-evaluate his skin. Physical examination

From the Department of Dermatology, University of California at San Francisco School of Medicine (H.A.O.) and the Department of Dermatology, The Cleveland Clinic Foundation (J.S.L., W.F.B.).

Address reprint requests to J.S.O., Department of Dermatology, The Cleveland Clinic Foundation, One Clinic Center, 9500 Euclid Avenue, Cleveland, Ohio 44195.

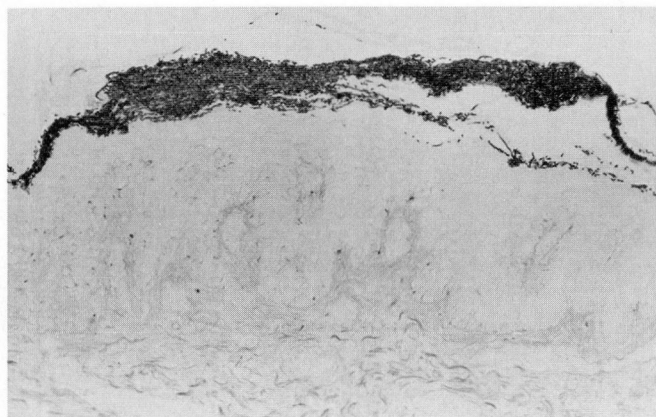


FIGURE 1. Skin biopsy specimen of the back with Gomori-methenamine-silver stain illustrating abundant hyphae in the stratum corneum. Original magnification 200 $\times$ .

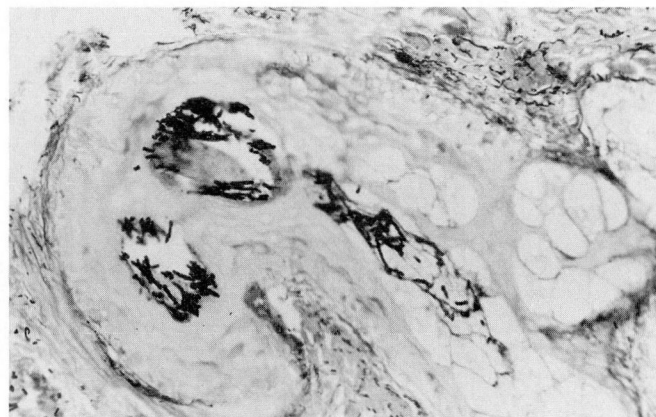

FIGURE 2. Hair follicle with abundant hyphae as demonstrated with Gomori-methenamine-silver stain. Original magnification 400 $\times$ .

revealed several scaling, minimally erythematous plaques on the forearms, back, chest, feet, and arms. There were broken hairs on his chest, legs, and scalp. A patchy alopecia was noted over the entire scalp. The left ear was noted to have diffuse erythema and some crusting. The perianal skin exhibited superficial erosions with surrounding erythema. Several erythematous scaling plaques were noted on the buttocks and groin.

KOH preparations of skin scrapings from the upper extremities, chest, legs, buttocks, scalp, and dorsal surfaces of the feet revealed the presence of nonseptate hyphae. Skin fungal cultures from numerous body sites grew four different organisms including *Microsporum canis*, *Candida albicans*, *Trichophyton mentagrophytes*, and *T. rubrum*. From the scalp, only *M. canis* and *C. albicans* were isolated. Skin biopsy specimens from the back and buttocks were obtained. Numerous fungal spores and short hyphae were observed within the stratum corneum and the hair follicles. The fungal organisms stained brilliantly with Gomori-methenamine-silver stain (Figures 1 and 2) and PAS stain. Fite-stained specimens showed no mycobacterial organisms. Typical cytopathic changes associated with *Herpes simplex* virus or cytomegalovirus infection were not identified on the skin biopsy specimens. No virus was isolated from tissue culture. His total peripheral T-cell count was 2,500 (T-helper and T-suppressor cell percentages were 2.1 and 53.6, respectively). The helper/suppressor T-cell ratio was 1:26.

During the course of hospitalization, the patient was treated with intravenous amphotericin B (10 mg/d) for 7 days for thrush esophagitis that was resistant to treatment with clotrimazole troches. His widespread derma-

tophyte infection was treated with ketoconazole, 200 mg by mouth daily, and topical econazole cream bid. He also applied clotrimazole 1% lotion to his scalp two or three times daily for his tinea capitis. This regimen, however, provided no clinical benefit. Old erythematous, scaly plaques on his trunk and extremities became thicker (Figure 3). In addition, areas of involvement became more widespread. The patient died of a five-lobe pneumonia associated with cytomegalovirus, gram-positive cocci (the species was not identified), and *Candida* 1 year after AIDS was diagnosed and 14 months after tinea corporis developed.

#### COMMENT

The cutaneous manifestations of AIDS are numerous and diverse.<sup>1,2</sup> Fungal infections, especially at the mucocutaneous sites, are commonplace. In this case, generalized cutaneous fungal infection was recalcitrant to therapy.

Several aspects of this case are noteworthy. First, we are unaware of any previous reports of generalized cutaneous fungal infections (of this degree) in patients with documented AIDS. Second, our patient harbored a polymicrobial cutaneous fungal infection. Cutaneous fungal infections in normal hosts are usually caused by only single species, not four as in this case. Third, this patient's disease did not respond to therapy.

As described above, our patient underwent a variety of therapies. Topical clotrimazole or econazole did little to contain or arrest the infection. Treatment with oral griseofulvin and ketoconazole was disappointing as well.



The dosage and length of therapy were inadequate in both treatments. It is possible that our patient may have been unable to absorb the oral preparation of the antifungal medications adequately. Since ketoconazole bioavailability depends on gastric acidity,<sup>3</sup> antacid, anticholinergic, and H<sub>2</sub> blocking agents must be avoided. Our patient was not receiving such therapy. Although malabsorption seems unlikely in this case, since he was asymptomatic, it should always be considered in an AIDS patient with weight loss and diarrhea.

Some dermatophyte infections may not respond to griseofulvin because of the dermatophyte species,<sup>4,5</sup> the sites infected,<sup>6</sup> and/or environmental factors such as high temperature and relative humidity.<sup>7</sup> Also, griseofulvin-resistant dermatophytes may develop.<sup>8</sup> Our patient's cutaneous fungal infections probably did not respond to therapy because the antifungal agents used were fungistatic and not fungicidal, and because there was a tremendous fungal load, as skin biopsies showed, that the patient's compromised immune system could not handle adequately.

#### SUMMARY

This case of recalcitrant, generalized, cutaneous polydermatophyte and *Candida* infections in an AIDS patient responded poorly to topical, oral, and intravenous therapy. Development of resistant strains of fungus may have played a role. The patient died of respiratory arrest secondary to a five-lobe pneumonia with cytomegalovirus, gram-positive cocci, and invasive in-

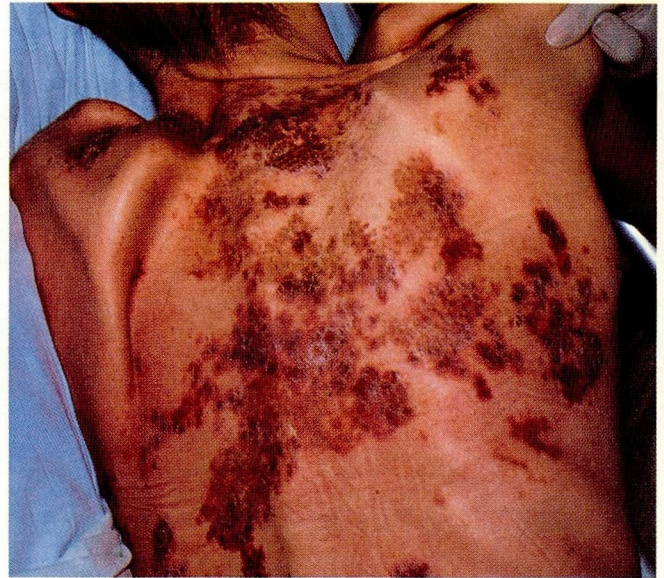

FIGURE 3. Chronic, thick, scaling plaques on the back of an AIDS patient.

fection by *Candida* species 14 months after a cutaneous fungal infection developed and 12 months after AIDS was diagnosed. Extensive cutaneous fungal infections refractory to treatment may be a presenting sign of HIV infection. Widespread cutaneous fungal infections unresponsive to treatment in individuals at high risk for HIV infection should alert the clinician to the possibility of AIDS.

#### REFERENCES

1. Penneys NS, Hicks B. Unusual cutaneous lesions associated with acquired immunodeficiency syndrome. *J Am Acad Dermatol* 1985; **13**:845-852.
2. Kaplan MH, Sadick N, McNutt NS, et al. Dermatologic findings and manifestations of acquired immunodeficiency syndrome. *J Am Acad Dermatol* 1987; **16**:485-506.
3. Physicians' Desk Reference. 42nd Edition. Oradell, NJ, Medical Economics Company, 1988, p 1076.
4. Micraelides P, Rosenthal SA, Sulzberger MB, et al. Trichophyton tonsurans infection resistant to griseofulvin: a case demonstrating clinical in vitro resistance. *Arch Dermatol* 1961; **83**:988-990.
5. Hay RJ. Chronic dermatophyte infections. I. Clinical and mycological features. *Br J Dermatol* 1982; **106**:1-7.
6. Anderson DW. Griseofulvin: biology and clinical usefulness. *Ann Allergy* 1965; **23**:103-110.
7. Shah VP, Epstein WL, Riegelman S. Role of sweat in accumulation of orally administered griseofulvin in skin. *J Clin Invest* 1974; **53**:1673.
8. Artis WM, Odle BM, Jones HE. Griseofulvin-resistant dermatophytosis correlates with in vitro resistance. *Arch Dermatol* 1981; **111**:16-19.