

Urticaria, nephritis, and pseudotumor cerebri

JEFREY LIEBERMAN, MD; GORDON GEPHARDT, MD; LEONARD H. CALABRESE, DO

■ The spectrum of chronic urticarial disease ranges from chronic urticarial skin lesions alone to well-characterized systemic lupus erythematosus with urticarial vasculitis as the major skin manifestation. Within this spectrum is the syndrome of urticarial vasculitis associated with systemic disease manifestations. There have been six previously recorded cases of urticarial vasculitis associated with pseudotumor cerebri. At least two of these have included membranoproliferative glomerulonephritis. The authors report a case of chronic urticarial disease associated with pseudotumor cerebri and membranoproliferative glomerulonephritis, but without demonstrable vasculitis. It is possible that this represents a distinct entity within the spectrum of chronic urticarial disease and can be easily screened for in clinical practice.

□ INDEX TERMS: GLOMERULONEPHRITIS; PSEUDOTUMOR CEREBRI; URTICARIA □ CLEVE CLIN J MED 1990; 57:197-201

WITHIN the spectrum of urticarial disease, there have been reports of a number of patients with a distinct clinical pathological entity designated as urticarial vasculitis.¹⁻⁹ This condition is characterized by small-vessel vasculitis seen on skin biopsy and frequently associated with depression of the early components of the classical complement pathway.^{1,9} Clinically, the syndrome is heterogeneous, ranging from vasculitis limited primarily to the skin to truly systemic illness with multi-system involvement.²⁻⁹ Six cases of urticarial vasculitis in association with pseudotumor cerebri have thus far been reported; at least two of these cases were also associated with biopsy-proved glomerulonephritis (Table 1). We have recently seen a case of chronic urticarial disease as-

sociated with pseudotumor cerebri, membranoproliferative glomerulonephritis, and hypocomplementemia, but without demonstrated vasculitis. We believe this may represent an additional nosologic entity within the spectrum of chronic urticarial disease.

CASE REPORT

A 37-year-old Hispanic woman was admitted for evaluation of a 3-month history of microscopic hematuria, proteinuria, and mixed cellular casts. For the previous 6 years, urticaria had involved much of her body surface for protracted periods. The lesions frequently involved both upper and lower extremities as well as the trunk, and persisted for many hours, though generally less than 1 day. The urticarial lesions were pruritic and painless and varied in size and shape, but were generally circular or oval and ranged from 1 cm to 10 cm. Petechiae were never noted within the lesions. An evaluation for secondary causes of chronic urticaria, including hypersensitivity skin testing, was unrevealing. There was no history of drug ingestion or precipitation by cold, heat, pressure, or sun, and no associated symptoms such as salivation, lacrimation, abdominal pain, or diarrhea

From the Departments of Rheumatic and Immunologic Disease, Immunopathology, and Anatomic Pathology, The Cleveland Clinic Foundation. Dr. Lieberman is currently Fellow, Department of Rheumatic Disease, Emory University School of Medicine, Atlanta, Georgia.

Address reprint requests to L.H.C., Section of Rheumatic and Immunologic Disease, The Cleveland Clinic Foundation, One Clinic Center, 9500 Euclid Avenue, Cleveland, Ohio 44195.

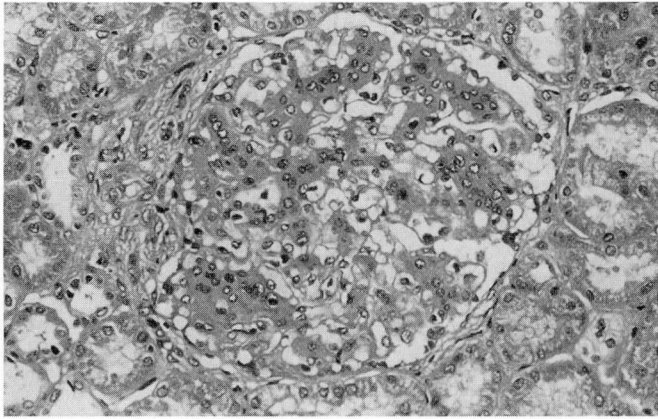


FIGURE 1. Glomerulus exhibiting hypercellularity with lobular accentuation. Hematoxylin and eosin $\times 300$.

to suggest a cholinergic component. These episodes were treated symptomatically with oral hydroxyzine and cortisone creams. Several episodes of diffuse abdominal pain over the years had resolved without treatment. Episodic arthralgias of the proximal interphalangeal joints were worse during exacerbations of her urticaria. She also described a mild intermittent frontal headache and red eyes over the previous several months. There was no history of allergy or asthma, oral ulcers, photosensitivity, pleurisy, alopecia, or Raynaud's phenomenon.

On examination, there were many large urticarial lesions, primarily on her lower extremities. She had bilateral papilledema with several scattered peripapillary hemorrhages. The joint examination was unremarkable, as was the remainder of the physical examination.

The Westergren sedimentation rate (WSR) was 73 mm/h. C1q binding assay was 73 U/mL (normal 0 U/mL to 73 U/mL). The total hemolytic complement (CH_{50}) was 15 U (normal 70 U to 190 U) and the C4 5.0 mg/dL (normal 12 mg/dL to 49 mg/dL). Negative test results included those for antinuclear antibody, anti-deoxyribonucleic acid, extractable nuclear antigen, lupus erythematosus preparation, rheumatoid factor, Raji cell assay, Sm antibody, and hepatitis B surface antigen. The blood urea nitrogen was 22 mg/dL (normal 5 mg/dL to 20 mg/dL); the creatinine 1.0 mg/dL (normal 0.3 mg/dL to 1.2 mg/dL). Urine protein excretion was 0.3 g/24 hr and glomerular filtration rate (GFR) was 66 mL/min/1.73 m² body surface. The urinary sediment demonstrated numerous red blood cell casts per high-power field.

The renal biopsy revealed membranoproliferative glomerulonephritis (Figures 1 and 2). Biopsy of the ur-

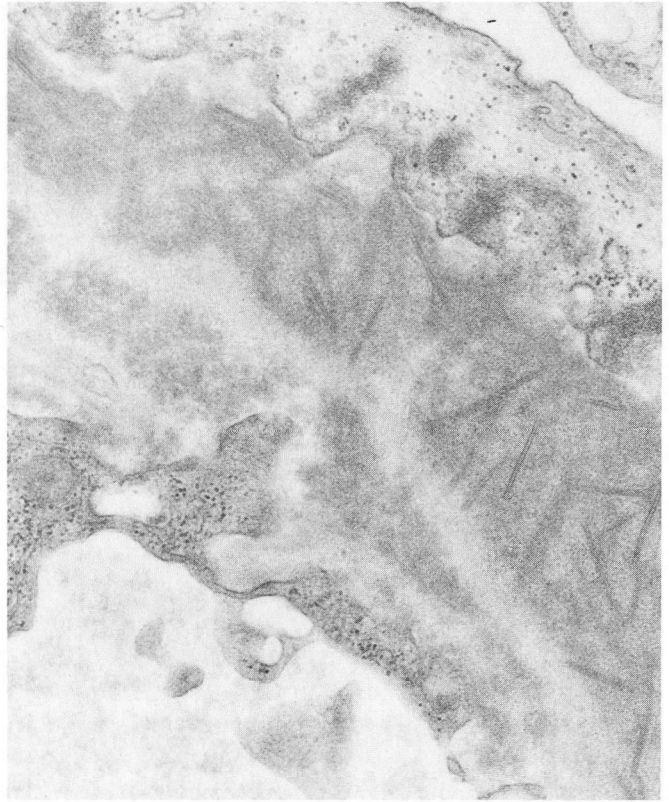

FIGURE 2. Electron photomicrograph demonstrating epimembranous and intramembranous dense deposits. The dense deposits appear to be in part tubular. There is no evidence of amyloid fibrils. Lead citrate and uranyl acetate $\times 21,000$.

ticarial lesions on two occasions, 6 months apart, showed neurophilic infiltration involving the superficial reticulodermis without evidence of vascular involvement. There was no evidence of leukocytoclasia and no eosinophilic or mast cell component was detected within the inflammatory infiltrate. Computed tomography (CT) of the brain was normal. Lumbar puncture revealed an opening pressure of 350 mmHg. Cerebrospinal fluid (CSF) showed a normal cell count and differential count. The CSF protein level was 37 mg/dL, and the glucose level was 66 mg/dL. Cultures and stains of CSF were negative.

A diagnosis of pseudotumor cerebri was based on physical examination, CT scan, and CSF findings. Acetazolamide was administered for pseudotumor cerebri and 15 mg prednisone per day for urticaria, as well as aspirin and dipyridamole for the membranoproliferative glomerulonephritis. Three months after her hospital discharge she had a flare-up of urticaria that was treated

with an increase of prednisone to 30 mg per day and addition of azathioprine, 50 mg per day. Azathioprine was added as a potential steroid-sparing agent because of the patient's refusal to take higher doses of prednisone, which were recommended for her glomerulonephritis.

The GFR 5 months after discharge was 58 mL/min/1.73 m² body surface. The serum creatinine level was 1.1 mg/dL, the WSR 23 mm/hr, and CH₅₀ 44 U/mL. The papilledema improved but was still present 12 months after discharge. Visual fields were stable.

KIDNEY BIOPSY

Light microscopy

The sections contained 15 to 20 glomeruli; two to three glomeruli exhibited global sclerosis. The remaining glomeruli exhibited marked hypercellularity with lobular accentuation. Some peripheral capillary loops appeared diminished in caliber. The peripheral glomerular basement membrane was thickened and exhibited prominent reduplication. Interstitial fibrosis and tubular atrophy were associated with these sclerotic glomeruli. The vessels were unremarkable. With the exception of the small foci of tubular atrophy, the tubules were unremarkable. A few lymphocytes were identified in the interstitial areas exhibiting fibrosis (*Figure 1*).

Immunohistochemistry

Eighteen glomeruli were present. The PAS stain demonstrated lobular accentuation and hypercellularity involving the glomeruli. There were prominent (2+ to 3+) granular deposits of IgG, IgA, IgM, and C3 in the mesangial regions and peripheral glomerular basement membranes of all glomeruli. Some deposits appeared epimembranous. Vessels and tubular basement membranes were negative for IgG, IgA, IgM, and C3.

Electron microscopy

Electron photomicrographs including three glomeruli were examined. The peripheral capillary loops exhibited prominent reduplication of the glomerular basement membrane with associated cytoplasmic interposition. There were prominent dense deposits in all peripheral capillary loops as well as mesangial regions. The deposits in the peripheral capillary loops were predominantly within the basement membrane, associated with the reduplicated portions of the membrane. Some dense deposits appeared epimembranous, and some exhibited a tubular substructure. There was proliferation of mesangial matrix and mesangial and endothelial hypercellularity. Rare neutrophils were identified in glomeru-

lar capillary loops. Small dense deposits were identified in tubular basement membranes (*Figure 2*).

DISCUSSION

The spectrum of chronic urticarial disease ranges from chronic idiopathic urticaria without histologic evidence of vasculitis^{9,10} to systemic lupus erythematosus with chronic urticarial vasculitic lesions.¹¹ Between these extremes lies the syndrome of urticarial vasculitis first described by McDuffie et al in 1973.¹ Soon after, numerous other cases of urticarial vasculitis were reported, consisting of chronic urticarial lesions with biopsy evidence of typical leukocytoclastic vasculitis, as well as signs and symptoms of systemic illness such as arthralgias, abdominal pain, renal disease, and hypocomplementemia.^{2,5,12}

Although Zeiss et al¹² used the term "hypocomplementemic vasculitic urticarial syndrome," it later became apparent that the syndrome included not only patients with low serum complement levels but also those in whom serum complement was normal.^{6,8,13}

The etiology and pathogenesis of this syndrome are not well understood, in part because of the variability of its clinical and laboratory manifestations.⁸ In addition, many patients with chronic urticarial lesions and without systemic manifestations have been found on skin biopsy to have vasculitis.^{8,9} Our case appears to be unique in that our patient had clear evidence of chronic urticarial lesions, pseudotumor cerebri, and glomerulonephritis with immune complex deposits identified on renal biopsy. However, skin biopsies on two separate occasions demonstrated no evidence of vasculitis or perivascular infiltration.

In all previously reported cases of chronic urticaria associated with either glomerulonephritis or pseudotumor cerebri, a necrotizing vasculitis was seen on skin biopsy.^{2,3,6-8,14} Our inability to find vasculitis on our skin biopsy specimens could have been due to any of four factors: 1) inadequacy of skin biopsy specimens, although both biopsies were of large and newly developed urticarial lesions; 2) coincidental appearance of chronic urticaria with pseudotumor cerebri and membranoproliferative glomerulonephritis, which seems highly unlikely in view of the similarity of our cases to previously reported ones (*Table 1*); 3) transient inactivity of the vasculitic component of the urticaria; indeed, the case reported by Drucker and Bookman³ failed to show leukocytoclastic vasculitis until a second skin biopsy was performed 1 year after the original presentation; 4) absence of vasculitis in this case. Possibly the spectrum of

TABLE 1
REPORTED CASES OF URTICARIAL VASCULITIS IN ASSOCIATION WITH PSEUDOTUMOR CEREBRI

Reference	No. pts.	Complement	Arthralgias	Glomerulonephritis	Abdominal pain	Headache
Feig et al ²	1	decreased	present	present	present	absent
Ludivico et al ⁴	1	decreased	absent	present	present	absent
Sanchez et al ⁸	3	2 decreased 1 normal	NA	NA	NA	NA
Drucker et al ³	1	*decreased	present	absent	absent	absent

*Also associated with increased cryoglobulins.
NA = Not available.

the previously described syndrome should be broadened to include chronic urticarial disease without vasculitis, in association with hypocomplementemia, glomerulonephritis, and pseudotumor cerebri.

The occurrence of pseudotumor cerebri in association with urticarial vasculitis appears to be more than coincidental, having been reported in six previous cases (Table 1). The mechanism for this association, however, is unclear. Four criteria for the diagnosis of pseudotumor cerebri have been proposed: 1) elevated intracranial pressure; 2) normal CSF; 3) signs and symptoms of elevated intracranial pressure alone, without focal signs or altered consciousness; 4) normal CT brain scan.¹⁵ Our patient fulfilled all of these criteria. Several mechanisms have been described for the development of pseudotumor cerebri: 1) increase in the rate of production of CSF; 2) decrease in the rate of absorption of CSF by the arachnoid villi; 3) a sustained increase in intracranial venous pressure; 4) an increase in cerebral blood flow or interstitial fluid volume that increases the brain volume.¹⁶

Although young overweight females appear to be predisposed to develop pseudotumor cerebri, a wide variety of etiologic factors have been associated with pseudotumor cerebri in other patients.¹⁷ These include endocrine factors (Addison's disease, hypoparathyroid states, oral contraceptives, thyroid hormone replacement, and pregnancy) and ingestion of certain medica-

tions (vitamin A, phenytoin, tetracycline, nalidixic acid).¹⁵ It therefore seems unlikely that a single pathophysiologic explanation exists.

The urticarial vasculitis associated with glomerulonephritis appears to be pathologically related to the nephritis by the mechanism of immune complex deposition.^{1,2,7,8} Immune complex deposits have been demonstrated in the choroid plexus of patients with systemic lupus erythematosus and in rats with experimentally induced serum sickness.^{18,19} Although the pathogenetic significance of these findings is not known, it is intriguing to postulate that the effects of immune complex deposition in both the choroid plexus and arachnoid villi may be related to changes in CSF dynamics that then lead to the formation of pseudotumor cerebri. Further pathologic studies of patients who have systemic immune complex disorders affecting the central nervous system with and without pseudotumor cerebri may help to clarify these relationships.

Because of the increased incidence of pseudotumor cerebri and glomerulonephritis in patients with chronic urticarial disease, it seems prudent to screen these patients for funduscopic and urinary sediment abnormalities even in the absence of demonstrable vasculitis. We suspect that the resulting information will show these elements to be associated in a pattern that will establish the place of the entity we describe within the broader spectrum of urticarial disease.

REFERENCES

- McDuffie FC, Sams WM, Maldonado JE, Andreni PH, Conn DL, Samayoa EA. Hypocomplementemia with cutaneous vasculitis and arthritis: possible immune complex syndrome. *Mayo Clinic Proc* 1973; 48:340-348.
- Feig PU, Soter NA, Yager HM, Caplan L, Rose S. Vasculitis with urticaria, hypocomplementemia and multiple system involvement. *JAMA* 1976; 236:2065-2068.
- Drucker DJ, Bookman AA. Pseudotumor cerebri in association with polyarthritides, urticaria and cryoglobulinemia. *Can Med Assoc* 1985; 132:147-149.
- Ludivico CL, Myers AR, Maurer K. Hypocomplementemic urticarial vasculitis with glomerulonephritis and pseudotumor cerebri. *Arth Rheum* 1979; 22:1024-1028.
- Gammon WR, Wheeler CE Jr. Urticarial vasculitis: report of a case and review of the literature. *Arch Dermatol* 1979; 115:76-80.
- Callen SP, Kalbfleisch S. Urticarial vasculitis: a report of nine cases and review of the literature. *Br J Derm* 1982; 107:87-93.
- Moorthy AV, Pringle D. Urticaria, vasculitis, hypocomplementemia, and immune-complex glomerulonephritis. *Arch Pathol Lab Med* 1982; 106:68-70.
- Sanchez NP, Winkelmann RK, Schroeter AL, Dicken CH. The clinical and histopathologic spectrums of urticarial vasculitis: study of forty cases. *Am Acad Dermatol* 1982; 7:599-605.
- Phanuphak P, Kohler PF, Stanford RE, Schocket AL, Carr RI, Claman

- HN. Vasculitis in chronic urticaria. *J Allergy Clin Immunol* 1980; **65**:436-444.
10. Monroe EW, Schulz CI, Maize JC, Jordon RE. Vasculitis in chronic urticaria: an immunopathologic study. *J Invest Dermatol* 1981; **76**:103-107.
 11. O'Loughlin S, Schroeter AL, Jordon RE. Chronic urticaria-like lesions in systemic lupus erythematosus: a review of 12 cases. *Arch Dermatol* 1978; **114**:879-875.
 12. Zeiss CR, Burch FX, Marder RJ, Furey ML, Schmid FR, Gewurz H. A hypocomplementemic vasculitic urticarial syndrome: report of four new cases and definition of the disease. *Am J Med* 1980; **68**:867-875.
 13. Soter N. Chronic urticaria as a manifestation of necrotizing venulitis. *N Engl J Med* 1977; **296**:1440-1442.
 14. Schultz DR, Perez GO, Volanakis JE, Victoriano P, Moss SH. Glomerular disease in two patients with urticaria-cutaneous vasculitis and hypocomplementemia. *Am J Kidney Dis* 1981; **1**:157-165.
 15. Ahlskog JE, O'Neill BP. Pseudotumor cerebri. *Ann Int Med* 1982; **97**:249-256.
 16. Fishman RA. The pathophysiology of pseudotumor cerebri: an unsolved puzzle. *Arch Neurol* 1984; **41**:257-258.
 17. Reid AC. Pseudotumor cerebri (C). *Ann Int Med* 1982; **97**:931-938.
 18. Koss MN, Chernack WJ, Griswold WR, McIntosh RM. The choroid plexus in acute serum sickness: morphologic, ultrastructural, and immunohistologic studies. *Arch Pathol* 1973; **96**:331-334.
 19. Atkins CJ, Kondon JJ, Quismorio FP, Friou GJ. The choroid plexus in systemic lupus erythematosus. *Ann Int Med* 1972; **76**:65-72.

