

# Monocytic leukemoid reaction, glucocorticoid therapy, and myelodysplastic syndrome

MANOEL MORAES, MD; JOHN WILKES, MD; JAMES N. LOWDER, MD

■ A leukemoid reaction is a complex and poorly understood response by the bone marrow to a variety of stresses; although any peripheral blood cell line may be involved, it is rarely a purely monocytic event. A case is reported of a true monocytic leukemoid reaction in a patient with myelodysplastic syndrome related to the effect of corticosteroids on the underlying marrow disorder.

□ INDEX TERMS: LEUKEMOID REACTION; GLUCOCORTICIDS □ CLEVE CLIN J MED 1990; 57:571-574

**A** LEUKEMOID REACTION by definition is leukocytosis with a peripheral blood picture that resembles chronic myeloid leukemia; it usually occurs in response to infection, inflammation, tumor, or tissue damage.<sup>1</sup> Although mature neutrophils and their precursors are most often seen, a monocytic leukemoid reaction may occur.<sup>2</sup> This case report describes a monocytic leukemoid reaction secondary to the institution of steroid therapy in a patient with chronic myelomonocytic leukemia (CMML).

## CASE REPORT

A 77-year-old white man was transferred to the Cleveland Clinic Hospital from a local hospital for evaluation of weakness, anemia, intermittent fever, and

right upper quadrant abdominal pain. He had been well until 8 years prior to admission, when he underwent a cholecystectomy. He complained shortly afterward of nonspecific intermittent right upper quadrant abdominal pain. Despite frequent hospitalizations and extensive evaluations, his symptoms remained unexplained; objective weakness and anemia persisted for 1 year prior to admission. Complete evaluation of the anemia had suggested a chronic etiology, and his hemoglobin had been maintained with infrequent transfusions.

He had lost 18 pounds during the 6 months preceding admission. During the 2-week hospitalization prior to his transfer to the Cleveland Clinic, repeated cultures, abdominopelvic computed tomography (CT), and gallium scan revealed no cause for a low-grade fever. His medical history included an abdominal aortic aneurysm repair in 1983 and radiographically diagnosed duodenal ulcers in 1972.

On admission, his temperature was 37.4°C; pulse, 84; respirations, 20; and blood pressure, 160/78 mmHg. His weight was 70 kg and his height was 190 cm. The patient was alert, but lethargic, very weak, and uncommunicative. His skin was pale, without jaundice, rashes,

From the Department of Hematology and Medical Oncology, The Cleveland Clinic Foundation.

Address reprint requests to J.N.L., Becton Dickinson Advanced Diagnostics, 225 International Circle, Cockeysville, Maryland 21030.

or nodules. No lymphadenopathy was found. The head was normal. The neck was supple. The lungs were clear and the heart was normal. The abdomen was scaphoid, with normal bowel sounds; on palpation no organ mass, tenderness, or hernia was found. Findings of the rectal and neurologic examinations were normal.

The hematologic profile on hospital admission revealed: white cell count 42,700/ $\mu\text{L}$  (64% neutrophils, 27% monocytes, 5% lymphocytes, 2% eosinophils, and 2% basophils), hemoglobin 8.9 g/dL, hematocrit 26.7%, and platelets 227,000/ $\mu\text{L}$ . Other laboratory values included: sodium, 140 mEq/L; potassium, 4.1 mEq/L; chloride, 101 mEq/L; bicarbonate, 24 mEq/L; creatinine, 1.3 mg/dL; urea nitrogen, 17 mg/dL; lactate dehydrogenase, 324 IU/L; SGOT, 36 IU/L; SGPT, 13 IU/L; alkaline phosphatase, 216 IU/L; total bilirubin, 1.2 mg/dL; prothrombin time, 13.5 seconds; partial thromboplastin time, 24.9 seconds; erythrocyte sedimentation rate, 130 mm/h; rheumatoid factor, 136 IU/mL; negative antinuclear antibody; CH50 44 units; and cryoglobulins 28  $\mu\text{g/mL}$ . Thyroid function tests, chest radiograph, and electrocardiogram were normal.

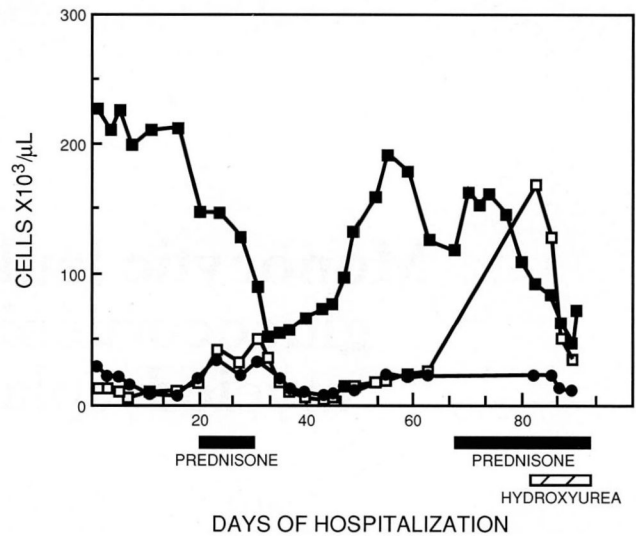
To further assess the abnormal hematologic profile, a bone marrow aspiration and biopsy were performed on the second hospital day. The marrow was hypercellular with dysplastic changes in all three cell lines and an increased monocyte count consistent with CMML. The differential showed 35% monocytes and 2% blasts.

Although the patient remained afebrile during the hospitalization, he suffered from recurrent abdominal pains, malnutrition, and depression. Enteral tube feedings were required to maintain his nutritional status.

Complete gastrointestinal endoscopy, esophageal motility, and gastric emptying studies were unrevealing. CT and ultrasonography of the abdomen revealed no abnormalities. A percutaneous liver biopsy disclosed mild, nonspecific, chronic inflammation. Clinical suspicion of giant cell arteritis led to a superficial temporal artery biopsy, which demonstrated medial scarring consistent with remote, healed temporal arteritis.

On hospital day (HD) 20, because of presumed vasculitis, the patient was started on a trial of oral prednisone, 60 mg/d, tapered over 10 days; this resulted in no clinical improvement. An exploratory laparotomy was cancelled in view of the patient's poor clinical status; a second trial of steroids, begun on HD 68, led to some improvement.

During this lengthy hospitalization, the patient's WBC count remained abnormal, with substantial fluctuations in neutrophils and monocytes (Figure 1). This was presumably the result of his primary hematologic



**FIGURE 1.** Peripheral blood counts. The absolute neutrophil count (●), absolute monocyte count (□) and platelet count (■) v the days of hospitalization are plotted. Prednisone (filled bars) was administered from hospital day 20 to 31 and from hospital day 68 until discharge. Hydroxyurea (hatched bar) was administered from day 82 until discharge.

disorder, CMML. Superimposed on these fluctuations were two dramatic increases in peripheral monocyte counts, both of which occurred after treatment with prednisone. The platelet count also fluctuated, with a substantial decline during glucocorticoid administration, followed by a rapid recovery after withdrawal of the drug. The vast majority of cells in the peripheral blood were mature and no blasts were observed during the hospitalization.

A repeat bone marrow aspiration and biopsy were performed on HD 85 to investigate whether the patient's myelodysplastic syndrome was transforming into an acute monocytic leukemia. This examination revealed 3% blasts, 40% mature monocytes, and 70% cellularity—findings inconsistent with the French-American-British (FAB) requirements for acute leukemia and representing evolution from the first bone marrow examination.<sup>3</sup> Moreover, the monocyte level in the peripheral blood at this time was 80%, or twice the level in the marrow. This suggested a preferential extrusion of these cells, although sampling error cannot be excluded. The fall in platelet count produced by the glucocorticoid administration could not be easily explained by the bone marrow findings.

This patient presented a therapeutic dilemma. He

was believed to have a vasculitis that required an indefinite period of glucocorticoid therapy. However, the high neutrophil and monocyte levels associated with glucocorticoid therapy in this patient could produce leukostasis, which has substantial morbidity in the elderly. Thus, hydroxyurea, 1,500 mg/d, was used to control the leukocyte counts during prednisone administration. Hydroxyurea therapy was initiated on HD 82 and discontinued on day 89 when the WBC declined to 40,000/ $\mu$ L.

The patient's symptoms improved, and he was discharged and evaluated with twice-weekly hemograms for several months. His condition continued to wax and wane as before. Tube feedings had been discontinued, and he was ingesting pureed food. He was still taking oral prednisone, 40 mg/d. His last WBC was 144,000/ $\mu$ L (no differential available); hemoglobin, 9.0 mg/dL; and platelet count, 66,000/ $\mu$ L. His care continued under the supervision of his personal physician.

#### DISCUSSION

The patient described in this report exhibited a monocytic leukemoid reaction to glucocorticoids. The rise in absolute monocyte count subsided after the first brief administration of prednisone, but the count increased progressively with the second administration of prednisone. The etiology of this patient's unusual response is obscure, but it is probably related to several phenomena.

Simple monocytosis, defined as more than 9% circulating monocytes, has been associated with various disorders, including acute and chronic leukemias, myelodysplastic syndromes, lymphomas, recovery from chemotherapeutic bone marrow suppression, collagen vascular disease, and a variety of infectious conditions.<sup>4</sup> This patient's myelodysplastic syndrome and undefined inflammatory condition accounted for his chronic monocytosis. Moreover, because the monocytosis was chronic, it could not be explained as a rebound monocytosis produced by the therapeutic effect of the glucocorticoid on an anti-monocyte antibody.

The granulocytosis associated with glucocorticoid administration is well known.<sup>5-7</sup> The effects of glucocorticoids on mononuclear phagocytes are less well defined. Thompson and van Furth observed an initial drop in mouse peripheral blood monocytes 6 hours after a single injection of dexamethasone.<sup>8</sup> After 24 hours, the monocyte counts were elevated above baseline. Studies in humans have confirmed these findings.<sup>5,7,9</sup> Rinehart and associates observed a fall in circulating monocytes within 2 hours of initiating a course of six 50-mg doses of prednisone at 12-hour intervals.<sup>9</sup> Between 2 and 40

hours of completing the regimen, monocyte counts were elevated or, less frequently, normal. These minor fluctuations in the absolute monocyte count in response to glucocorticoids do not explain what was observed in this patient.

The leukemoid reaction is a complex and poorly understood response by the bone marrow to stresses such as infection, inflammation, neoplasias, and drugs.<sup>10</sup> The reaction may involve any peripheral blood cell line, but it is usually characterized by an increase in absolute numbers of cells as well as the presence of immature forms generally not observed in the peripheral blood. Hill and Duncan defined a monocytic leukemoid reaction as a WBC count greater than 30,000 with monocytosis of 40% or greater, to produce an absolute monocyte count greater than 12,000/ $\mu$ L.<sup>10</sup> Monocytic leukemoid reactions have been associated with congenital syphilis and with active tuberculosis in a patient with a teratoma.<sup>11,12</sup>

A recent report of a monocytic leukemoid reaction in a patient with a myelodysplastic syndrome following cholecystectomy seems most analogous to the observations described herein.<sup>2</sup> Patients with myelodysplastic syndromes are prone to monocytosis because of qualitative and quantitative abnormalities in the bone marrow.<sup>13</sup> In response to stress, the bone marrow releases the cells that are the most abundant—in this case, monocytes. The second mechanism for elevated monocytes could be the "rebound" phenomenon proposed by Shoenfield and associates.<sup>5</sup> These authors hypothesized a steroid-induced monocytic sequestration in the bone marrow during the daily periods of highest drug levels; its release during the hours of low blood levels leads to elevated peripheral counts.

The leukemoid reaction presumably results from the secretion of large amounts of hematopoietic growth factors in response to stress. The administration of recombinant granulocyte-colony stimulating factor (G-CSF) and granulocyte macrophage-colony stimulating factor (GM-CSF) produces primarily granulocytosis, with essentially no change in the absolute monocyte counts.<sup>14,15</sup> Administered intravenously, GM-CSF can produce thrombocytopenia and has been reported to produce high monocyte counts in a patient with CMML.<sup>16</sup> GM-CSF has *in vitro* effects on the proliferation and differentiation of the monocyte marrow precursors.<sup>17</sup> Studies of acute leukemia cells have demonstrated proliferative as well as suppressive effects of various growth factors.<sup>18</sup> M-CSF, which has been studied less thoroughly than other growth factors, stimulates almost a pure monocytic proliferation *in vitro*, but appears to have less access to progenitor cell compartments *in vivo*.<sup>19,20</sup>

In this patient, the administration of glucocorticoids probably caused either physiologic or pathologic production of one or more hematopoietic growth factors. If the production was physiologic, then the disturbed differentiation and maturation of the bone marrow may have permitted an abnormally sensitive response by the monocytic line to the growth factor(s), or it may have

allowed access of M-CSF to normally isolated monocyte precursors. If an abnormally large amount of factor was produced, an induction of large amounts of M-CSF might account for this phenomenon. This phenomenon must be considered as a potential toxic effect when administering growth factors to patients with myelodysplastic syndrome.

---

#### REFERENCES

---

1. Finch SC. Neutrophilia. [In] Williams WJ, Beutler E, Erslev AJ, Lichtman MA, eds. Hematology. 3rd ed. New York, McGraw-Hill Book Company, 1983, pp 794-801.
2. Wutberg A. Case report: a monocytic leukemoid reaction in a patient with myelodysplasia. *CA: A cancer journal for clinicians* 1985; **35**:308-310.
3. Bennett JM, Catovsky D, Daniel MT, et al. Proposals for the classification of the acute leukemias. *Br J Haematol* 1976; **33**:451-458.
4. Cassileth PA. Monocytosis. [In] Williams WJ, Beutler E, Erslev AJ, Lichtman MA, eds. Hematology. 3rd ed. New York, McGraw-Hill Book Company, 1983, pp 861-864.
5. Shoenfield Y, Gurewich Y, Gallant LA, Pinkhan J. Prednisone induced leukocytosis. *Am J Med* 1981; **71**:773-777.
6. Dale DC, Fauci AS, Guerry D, Wolff SM. Comparison of agents producing neutrophilic leukocytosis in man. *J Clin Invest* 1975; **56**:808-813.
7. Fauci AS, Dale DC, Balow JE. Glucocorticosteroid therapy: mechanisms of action and clinical considerations. *Ann Intern Med* 1976; **84**:304-315.
8. Thompson J, van Furth R. The effect of glucocorticosteroids on the kinetics of mononuclear phagocytes. *J Exp Med* 1970; **131**:429-441.
9. Rinehart JJ, Sagone AL, Balcerzak SP, Ackerman GA, LoBuglio AF. Effects of corticosteroid therapy on human monocyte function. *New Engl J Med* 1975; **292**:236-241.
10. Hill JM, Duncan CN. Leukemoid reactions. *Am J Med Sci* 1941; **201**:847-857.
11. Karayalcin G, Khanijou A, Kim KY, Aballi AJ, Lanzkowsky P. Monocytosis in congenital syphilis. *Am J Dis Child* 1977; **131**:782-783.
12. Gibson A. A monocytic leukemoid reaction associated with tuberculosis and a mediastinal teratoma. *J Patholog Bacteriol* 1946; **58**:469-475.
13. Economopoulos T, Stathakis N, Maragoyannis Z, Gardikas E, Dervenoulas J. Myelodysplastic syndrome. *Acta Haematol (Basel)* 1981; **65**:97-102.
14. Groopman JE, Mitsayasu RT, DeLeo MJ et al. Effect of rH GM-CSF on myelopoiesis in the acquired immunodeficiency syndrome. *N Engl J Med* 1987; **317**:593-598.
15. Gabrilove JL, Jakubowski A, Scher H et al. Effect of G-CSF on neutropenia and associated morbidity due to chemotherapy for transitional cell carcinoma of the urothelium. *N Engl J Med* 1988; **318**:1414-1422.
16. Mertelsmann R. Personal communication.
17. Hittleman WN, Tigaud J-D, Estey E et al. Relative maturation of aneuploid and diploid elements in patients with myelodysplasia treated with GM-CSF (abstract). *Blood* 1988; **72**:121a.
18. Griffin JD, Young D, Herrmann F, et al. Effects of rH GM-CSF on proliferation of clonogenic cells in acute myeloblastic leukemia. *Blood* 1986; **67**:1448-1453.
19. Nicola NA. Hemopoietic cell growth factors and their receptors. *Annu Rev Biochem* 1989; **58**:45-77.
20. Shadduck RK, Waheed A, Wing EJ. Demonstration of a blood-bone marrow barrier to macrophage colony stimulating factor. *Blood* 1989; **73**:68-73.