

BEN H. BROUHARD, MD, EDITOR

## Lipoprotein abnormalities in the progression of renal disease

BEN H. BROUHARD, MD; MICHAEL D. CRESSMAN, DO; KIMBERLY C. IRWIN, MD; NICHOLAS T. STOWE, PHD

■ Chronic renal disease is a progressive process. Implicated factors include abnormalities of the clotting cascade, altered prostaglandin metabolism, increased dietary protein intake, and abnormalities of lipoprotein metabolism. Several animal models have associated increased serum concentrations of cholesterol and triglycerides with progressive decline in renal function. The mechanism(s) of lipid-associated renal injury are unknown but may relate to lipid uptake by glomerular mesangial cells, hyperviscosity secondary to the hyperlipidemia, and a direct effect of the lipids on the glomerular basement membrane. Patients with chronic renal disease have well recognized increases in serum lipid concentrations. Whether lowering these concentrations will delay or prevent progressive renal failure or renal histologic abnormalities is unknown, but studies are underway to evaluate the effect of lipid-lowering agents in patients at risk for chronic progressive renal disease.

□ INDEX TERMS: LIPOPROTEINS; RENAL FAILURE, CHRONIC □ CLEVE CLIN J MED 1990; 57:599-604

**R**ESearchers are expending much time and effort to determine the pathogenesis of renal disease that progresses to end-stage disease. It has been hypothesized that within a diseased kidney there are normal nephrons and diseased nephrons, and that the glomeruli of normal nephrons have increased filtering function. The hyperfiltration of these glomeruli may be one mechanism that leads to the destruction of that nephron. Other processes also have been implicated. This article,

second in the "Bench to Bedside" series, presents results of experimental studies which suggest that hyperlipidemia may promote the progression of renal disease. These data provide an avenue for future human investigation. *B.H.B.*

From the Departments of Pediatrics (B.H.B., K.C.I.), Hypertension and Nephrology (B.H.B., M.D.C., N.T.S.), Heart and Hypertension Research (B.H.B., M.D.C.), and the Nephro-Urologic Research Laboratory (N.T.S.), The Cleveland Clinic Foundation.

Address reprint requests to B.H.B., head, Section of Pediatric Research, The Cleveland Clinic Foundation, One Clinic Center, 9500 Euclid Avenue, Cleveland, Ohio 44195.

Chronic renal failure from various causes is a progressive phenomenon.<sup>1</sup> Several potentially modifiable factors may perpetuate the progression of the initial renal injury. For example, increases in dietary protein intake,<sup>2</sup> the activation of the intrarenal renin-angiotensin system,<sup>3</sup> platelet aggregation, and intrarenal clotting abnormalities<sup>4</sup> may contribute to the progression of chronic renal insufficiency to a stage of irreversible renal failure. Although it is not clear that any one of these factors is solely responsible for the self-perpetuating nature of progressive renal failure, experimental studies

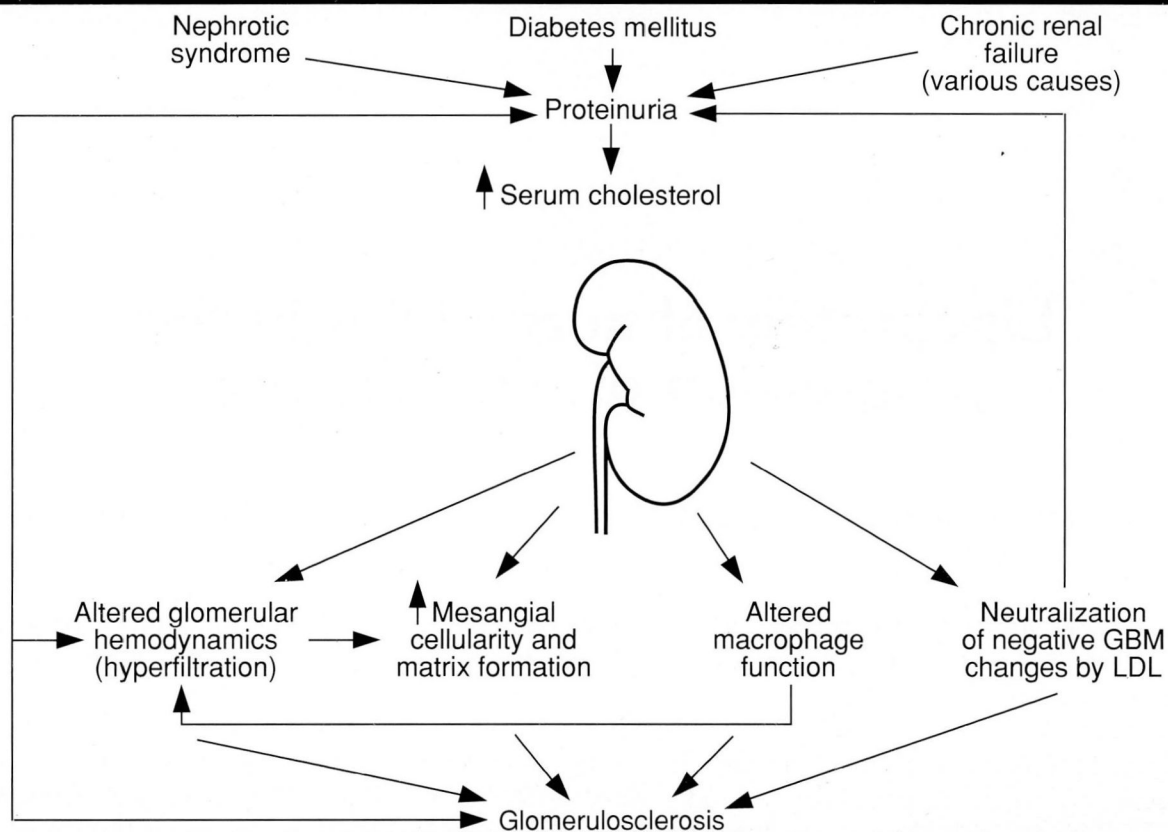


FIGURE 1. Potential mechanisms whereby increased serum cholesterol concentration promotes progressive decline in renal function.

and some clinical trials have indicated that reduced dietary protein intake<sup>5</sup> or the use of angiotensin-converting enzyme inhibitors<sup>6</sup> may slow the progressive deterioration in renal function in certain forms of chronic renal disease.

Another promising area of investigation was stimulated by the hypothesis that hypercholesterolemia can hasten the decline in renal function (Figure 1). In 1982, Moorhead and associates<sup>7</sup> suggested that chronic progressive renal disease could be mediated in part by abnormalities of lipid metabolism. These investigators proposed that with the initial renal injury and subsequent proteinuria, low-density lipoproteins (LDL) would be produced in excess by the liver and metabolized slowly in the peripheral circulation. These lipoproteins would then bind to heparan-sulfate glycosaminoglycans in the glomerular basement membrane (GBM), increasing its permeability to albumin.

Continued urinary loss of albumin with subsequent decreases in serum albumin concentration or oncotic

pressure would further stimulate hepatic lipoprotein synthesis. The mesangial cell, acting as a local reticuloendothelial system for the glomerulus, could accumulate lipids and produce excess basement membrane material, thus limiting the glomerular filtration rate (GFR). These investigators further hypothesized that progressive tubular interstitial disease could result in tubular luminal precipitation of lipoproteins, also leading to progressive renal dysfunction.

#### ENDOGENOUS HYPERLIPIDEMIA: THE OBESE ZUCKER RAT

Based on these theories, several investigators have performed studies in animal models of chronic renal disease (Table 1). The results indicate that lipids may play a prominent role in the self-perpetuating renal dysfunction of chronic renal insufficiency.

The obese Zucker rat has been used as a model of endogenous hyperlipidemia. This rodent model is associated with abnormal lipid metabolism at an early age,<sup>8</sup> with subsequent development of progressive renal

disease<sup>9,10</sup> characterized histologically by focal segmental sclerosis. In contrast, lean littermates remain normolipemic and maintain normal renal function and structure.<sup>9,10</sup>

The structural abnormality of obese Zucker rats is focal segmental sclerosis—and anomaly that can be induced with a high-cholesterol diet in a variety of animals. Experiments with the guinea pig by French and associates<sup>11</sup> demonstrated that a 1% cholesterol diet would result in severe, progressive glomerulosclerosis with cholesterol crystals in the glomerular capillaries. Similar findings were reported by Al-Shebeb and associates in the guinea pig<sup>12</sup> and Wellmann and Volk in New Zealand rabbits.<sup>13</sup>

Using a known model of chronic progressive renal disease, rats treated with the nephrotoxin puromycin aminonucleoside (PAN), Edwards<sup>14</sup> showed that high-fat diets accelerated this experimental form of glomerular disease. The disease resembles focal segmental glomerulosclerosis in humans. Using this same model, Grond and associates<sup>15</sup> demonstrated that, in rats with focal segmental glomerulosclerosis, lipids accumulated within the glomeruli and, most prominently, in the areas of glomerulosclerosis.

Studies by Diamond and Karnovsky,<sup>16</sup> using the same model of nephrotic syndrome and chronic progressive renal failure, showed accelerated progression of renal failure with high-cholesterol diets. The cholesterol-fed animals had not only significantly higher serum cholesterol concentrations, but also significantly higher urine protein excretion rates and lower inulin clearances. Renal histology demonstrated more sclerotic glomeruli, increased mesangial proliferation, and more mesangial foam cells than nonsupplemented animals.

Another experimental rat model immunizes rats against rabbit gamma globulin; the rat is then injected with rabbit anti-rat nephrotoxic serum. El-Nahas and colleagues<sup>17</sup> used the model of nephrotoxic serum

**TABLE 1**  
EXPERIMENTAL MODELS OF RENAL DISEASE AND HYPERCHOLESTEROLEMIA

Animal model	Cholesterol/ triglyceride	Histology	Protein excretion	GFR
Obese Zucker rat <sup>9,10</sup>	↑ / -	↑ ME, ↑ GS	↑	Normal
Normal rats <sup>14,25</sup>	↑ / ↓	↑ GS	↑	Normal, ↓
Guinea pig <sup>11,12</sup>	↑ / ND	↑ ME, ↑ GS	↑	Normal
Rabbit <sup>13</sup>	↑ / ND	↑ GS	ND	ND
Rats with PAN <sup>14-16</sup>	↑ / ↑	↑ GS	↑	↓
Rats with NSN <sup>17</sup>	↑ / ND	↑ GS	HD	ND

ME, mesangial expansion; GS, glomerulosclerosis; PAN, puromycin aminonucleoside nephrosis; NSN, nephrotoxic serum nephritis; ND, no data.

**TABLE 2**  
EFFECTS OF TREATMENT

Animal model	Treatment	Cholesterol/ triglyceride	GFR	Protein excretion	Histology
5/6 Nephrectomy <sup>21</sup>	Lovastatin	↓ / ↓	ND	↓	↓ GS
	Clofibrate	↓ / -	↑	↓	↓ GS
Obese Zucker rat <sup>22</sup>	Lovastatin	↓ / ↓	--	↓	↓ ME, ↓ GS
	Clofibrate	↓ / -	--	↓	↓ ME, ↓ GS
PAN rat <sup>23</sup>	Lovastatin	↓ / ↓	↑	↓	↓ GS

ND, no data; GS, glomerulosclerosis; ME, mesangial expansion; PAN, puromycin aminonucleoside nephrosis.

nephritis in rats to show a strong positive correlation between the degree of glomerulosclerosis and lipid content and the extent of renal tubular atrophy and lipid content.

Various experimental models of renal dysfunction indicate that elevated serum cholesterol concentrations from exogenous and higher cholesterol feedings and endogenous hyperlipidemia may perpetuate the initial renal dysfunction. Studies by Schmitz and colleagues<sup>18</sup> and Kasiske and associates<sup>19</sup> have confirmed that dietary cholesterol supplementation in normal rats leads to increased proteinuria and frequency of focal segmental glomerulosclerosis. After 1 month of such supplementation, not only was the GFR decreased, but structural abnormalities were evident, such as glomerular enlargement with mesangial matrix expansion and hypercellularity. Such histologic changes precede the appearance of sclerotic lesions, which are the hallmark of chronic progressive renal disease.

#### EFFECT OF LIPID-LOWERING THERAPY

The demonstration of lipid infiltration in renal glomerular, mesangial, or tubular cells in experimental

models of chronic renal disease does not prove that circulating or tissue-bound lipids or lipoproteins play a causative role in the progression of renal dysfunction. However, there is evidence for a causative role of lipid abnormalities in progressive renal disease in evaluations of treatment modalities that alter blood lipid and lipoprotein concentrations.

Kasiske and associates<sup>20</sup> used two lipid-lowering agents, lovastatin and clofibrate, to treat rats in which five-sixths of the total renal mass had been removed. Although this experimental model has limitations as an analogy for human renal disease, it has been widely used as an animal model of progressive renal disease.

Both agents reduced serum cholesterol concentrations. Compared to untreated controls, clofibrate increased glomerular filtration rate ( $0.9 \pm 0.09$  v  $1.2 \pm 0.11$  mL/min) and reduced albuminuria ( $11 \pm 4.0$  v  $62.0 \pm 10$  mg/24h). In addition to ameliorating these functional abnormalities, both agents significantly reduced the percentage of sclerotic glomeruli.

These investigators<sup>21</sup> reported similar findings in the obese Zucker rat. As with the five-sixths nephrectomy model, both agents significantly decreased both proteinuria and frequency of sclerotic lesions. Recently Harris and associates<sup>22</sup> used lovastatin to lower serum lipid concentrations in rats made nephrotic with injection of PAN and protamine sulfate. Lovastatin significantly lowered serum cholesterol concentrations and improved the GFR ( $0.82 \pm 0.41$  v  $1.83 \pm 0.42$  mL/min/kg body weight). As with the other experimental studies, the treated rats had significantly fewer sclerotic glomeruli on histologic examination as well as decreased proteinuria. Taken together, these animal studies provide compelling evidence that hyperlipidemia may be a modifiable factor in progressive renal disease (Table 2).

#### PATHOPHYSIOLOGY OF LIPID-ASSOCIATED RENAL INJURY

Mechanisms whereby elevated serum lipid concentrations adversely affect renal structure and function have not been delineated, but several theories have been proposed. Anderson and colleagues<sup>23</sup> suggested that the hyperviscosity caused by hypercholesterolemia may alter intrarenal hemodynamics. Hostetter and colleagues<sup>2</sup> proposed that hyperfiltration in intact nephrons within a damaged kidney is a self-perpetuating destructive process. This hyperfiltration is the result of increased glomerular capillary hydraulic pressure across the glomerular basement membrane. This increased transglomerular pressure is associated with proteinuria, and with mesangial matrix and cellular expansion. The com-

bination leads to focal segmental glomerulosclerosis, the histologic hallmark of progressive renal disease. The mesangial expansion impinges on the glomerular filtering surface area to further impair filtration. The result is hyperfiltration in remaining intact nephrons, perpetuating the process.<sup>24</sup>

Kasiske and co-workers<sup>19</sup> also have shown increased glomerular capillary hydraulic pressure in normal rats fed high-cholesterol diets for 8 to 10 weeks. Increases in glomerular capillary pressures are associated with the self-perpetuating destruction of the kidney and with the histologic lesion of focal segmental sclerosis.<sup>24</sup>

The mechanism by which hypercholesterolemia alters glomerular hemodynamics is unclear, but the data of Kasiske and associates<sup>19</sup> indicate that vasoconstriction of the efferent glomerular arteriole occurs with subsequent increases in glomerular capillary hydraulic pressures. Recent data from our laboratory (unpublished, 1990), using the PAN model of combined hyperlipidemia, proteinuria, and progressive renal failure, also suggest that intrarenal hemodynamics are altered. Rats made hyperlipidemic with PAN showed decreased GFRs at 8 weeks. Those treated with lovastatin showed similar decreases; among those treated with lovastatin and enalapril, an angiotensin-converting enzyme inhibitor known to decrease glomerular efferent arteriolar tone, inulin clearances were no different from those in control animals.

Anderson and colleagues<sup>23</sup> have hypothesized that the hyperviscosity of hypercholesterolemia may cause vasoconstriction of the efferent arteriole; the subsequent hemodynamic alteration—hyperfiltration—ultimately leads to nephron destruction. Other clinical hyperviscosity syndromes<sup>25,26</sup> and experimentally induced polycythemia<sup>27</sup> have also been associated with proteinuria, glomerular injury, and progressive renal disease.

Direct injury to the glomerulus from circulating lipids is another proposed explanation for the nephrotoxic effect of lipoproteins. Wasserman and colleagues<sup>28</sup> found specific receptors for human LDL on cultured rat mesangial cells. After attachment, LDL was incorporated into these cells and localized in lysosomes. Stimulation and proliferation of mesangial cells in tissue culture occurred at low LDL concentrations.

Studies using smooth muscle and endothelial cells in the peripheral vasculature have produced similar results.<sup>29</sup> Taken together, these studies and the work by Wasserman and associates suggest that mesangial cell exposure to LDL results in mesangial LDL uptake. The ensuing mesangial proliferation and subsequent reduc-

tion in glomerular capillary surface area leads to reduced glomerular filtration rate. Animal models have not produced data regarding circulating LDL concentrations; however, the mesangial uptake of LDL could have the direct effect of increased production of mesangial matrix and glomerular basement membrane. It could also increase the production of cytokines and mediators of inflammation by the mesangial cells, further damaging glomerular structure.

A direct interaction between circulating lipoprotein and the glomerular basement membrane has been proposed. The GBM has various components, including collagen IV, heparan sulfate glycosaminoglycans, and chondroitin sulfate glycosaminoglycans. The predominant glycosaminoglycan is heparan sulfate. Heparan sulfate glycosaminoglycans are lost in the urine or their synthesis is reduced in various conditions with proteinuria and progressive renal disease—for example, PAN- and streptozotocin-induced diabetes in rats.<sup>30</sup> It is this negatively charged portion of the GBM that prevents the negatively charged albumin from traversing the GBM.

Iverius<sup>31</sup> has shown that LDL is bound to heparan sulfate glycosaminoglycans under physiologic conditions by positively charged sites on the apolipoprotein B molecules. Neutralization of the negatively charged GBM by the positive apolipoprotein B could contribute to albuminuria and perpetuate the nephrotic state with further increases in serum lipid concentrations.

The progressive renal lesion of focal segmental sclerosis may be analogous to the development of atherosclerosis in the peripheral vasculature. The glomerular mesangium consists of two cell types: the macrophage and the vascular smooth muscle cell. The lipid-laden foam cells in atherosclerotic lesions are thought to be derived from circulating monocytes that have penetrated the arterial wall. The conversion of these macrophages to foam cells may require modification of LDL.

In the puromycin rat model of renal disease, Diamond<sup>32</sup> showed that with the increase in glomerular mesangial matrix there are increased numbers of foam cells identified as macrophages. Kasiske and colleagues<sup>19</sup> also demonstrated increased numbers of macrophages in glomeruli of rats fed a high cholesterol diet; these animals showed decreased GFRs and increased sclerosis on light microscopy. Other evidence suggests that the LDL within cultured macrophages increases production of prostaglandins, superoxide anions, and hydrogen peroxide, which are capable of altering glomerular hemodynamics, enhancing vascular per-

meability, and causing direct cell and tissue damage.

---

#### IMPLICATIONS FOR CHRONIC RENAL DISEASE IN HUMANS

---

Despite experimental and some theoretical evidence that lipids perpetuate chronic progressive renal disease, human data remain sparse. Avram,<sup>33</sup> evaluating renal biopsies from patients with focal segmental glomerulosclerosis, proposed that there are similarities between glomerulosclerosis and atherosclerosis. The similarities suggested a pathological link between lipid abnormalities in the kidney and those in the systemic vascular tree.

The human counterpart of various experimental animal models has been noted in morbid obesity,<sup>34</sup> familial lecithin-cholesterol acyltransferase deficiency,<sup>35</sup> and Type III hyperlipoproteinemia.<sup>36</sup> These studies suggest that the renal dysfunction associated with these conditions can be ameliorated or reversed by lowering plasma lipid concentrations.

Many patients have renal disease associated with hyperlipidemia, including diabetes mellitus, chronic renal failure, and renal transplantation. Since progressive decline in renal function may occur in all of these conditions, any therapeutic modality that alters this course would be useful. Furthermore, the dyslipidemias in these groups of patients may contribute significantly to their overall cardiovascular morbidity and mortality.

Studies are now emerging in which the hyperlipidemias in these conditions are treated specifically.<sup>37,38</sup> Kasiske and associates<sup>37</sup> demonstrated decreased total cholesterol, LDL cholesterol, and apolipoprotein B with a 6-week trial of lovastatin in 12 patients with nephrotic syndrome. Proteinuria and inulin clearance were unchanged.

Whether such studies will ultimately correlate differences in renal function or structure with treatment will require years of follow-up. Even though the agents available have limitations that may prevent their widespread use in patients with renal failure,<sup>39</sup> reduction of serum cholesterol concentrations will have a positive effect on both patient and renal survival.

---

#### COMMENT

---

Evidence shows that hyperlipidemia of exogenous or endogenous origin is associated with abnormal glomerular function and structure. The hypothesis that circulating lipoproteins play a causative role in progressive renal failure is supported by the beneficial effects of cholesterol-lowering drugs on renal function in several

animal models of chronic renal failure. For these reasons, lipid-altering therapy deserves consideration in humans with chronic renal failure. Further justification for controlled clinical trials of lipid-altering treatment in patients with chronic renal disease is based on the high prevalence of lipoprotein abnormalities and other sclerotic vascular disease in patients with chronic renal failure. Further animal studies are warranted to deter-

mine whether a specific lipoprotein, or modifications of certain lipoproteins, is particularly nephrotoxic.

#### ACKNOWLEDGMENTS

Supported by grants from the Research Programs Committee, The Cleveland Clinic Foundation, and the Ruth and James Morgan Endowment to Pediatric Research.

#### REFERENCES

- Mitch WE, Wolser M, Buffington GA, Lemann J. A simple method of estimating progression of chronic renal failure. *Lancet* 1976; 2:1326-1328.
- Hostetter TH, Olson JL, Rennke HG, Ventkutchalen MA, Brenner BM. Hyperfiltration in remnant nephrons: a potentially adverse response to renal ablation. *Am J Physiol* 1981; 241:F85-F89.
- Anderson S, Rennke HG, Brenner BM. Therapeutic advantage of converting enzyme inhibitors in arresting progressive renal disease associated with systemic hypertension in the rat. *J Clin Invest* 1986; 77:1993-2000.
- Purkerson ML, Joist JH, Greenberg JM, Day K, Hoffstein PE, Klahr S. Inhibition by anticoagulant drugs of the progressive hypertension and uremia associated with renal infarction in rats. *Thromb Res* 1982; 26:227-240.
- Brouhard BH. The role of dietary protein in progressive renal disease. *Am J Dis Child* 1986; 140:630-637.
- Heeg JE, de Jong PE, van des Hem GD, de Zeeuw D. Reduction of proteinuria by angiotensin converting enzyme inhibition. *Kidney Int* 1987; 32:78-83.
- Moorhead JF, El-Hahas M, Chan MK, Varghese Z. Lipid nephrotoxicity in chronic glomerular and tubulointerstitial disease. *Lancet* 1982; 2:1309-1311.
- Zucker LM. Hereditary obesity in the rat associated with hyperlipidemia. *Ann NY Acad Sci* 1965; 31:447-458.
- Kasiske BL, Cleary MP, O'Donnell MP, Deane WF. Effects of genetic obesity on renal structure and function in the Zucker rat. *J Lab Clin Med* 1985; 106:598-604.
- O'Donnell MP, Kasiske BL, Cleary MP, Keane WF. Effects of genetic obesity on renal structure and function in the Zucker rat. II. Micropuncture studies. *J Lab Clin Med* 1985; 106:605-610.
- French SW, Yamanaka W, Ostwald R. Dietary-induced glomerulosclerosis in the guinea pig. *Arch Pathol* 1967; 83:204-210.
- Al-Shebeb T, Fraklick J, Magil AB. Glomerular disease in hypercholesterolemic guinea pigs: a pathogenetic study. *Kidney Int* 1988; 33:498-507.
- Wellmann KF, Volk BW. Renal changes in experimental hypercholesterolemia in normal and in subdiabetic rabbits. *Lab Invest* 1971; 24:144-155.
- Edwards KGD. Why treat hyperlipidemia in patients with renal disease? [In] Schreiner GE, Winchester BD, eds. *Controversies in Nephrology*, Vol. 3, New York, Masson, 1981, pp 3-15.
- Grond J, Weening JJ, Elema JD. Glomerular sclerosis in nephrotic rats. *Lab Invest* 1984; 51:277-285.
- Diamond JR, Karnovsky MJ. Exacerbation of chronic aminonucleoside nephrosis by dietary cholesterol supplementation. *Kidney Int* 1987; 32:671-677.
- El-Nahas AM, Marshall R, Moorhead JF. Glomerulatherosis or glomerular sclerosis? *J Pathol* 1983; 140:155.
- Schmitz PG, O'Donnell MP, Kasiske BL, et al. Diet-induced hypercholesterolemia elevates glomerular capillary pressure. *Kidney Int* 1989; 35:473A.
- Kasiske BL, O'Donnell MP, Schmitz PG, Kim Y, Keane WF. Renal injury of diet-induced hypercholesterolemia in rats. *Kidney Int* 1990; 37:880-891.
- Kasiske BL, O'Donnell MP, Garvis WJ, Keane WL. Pharmacologic treatment of hyperlipidemia reduces glomerular injury in rat 5/6 nephrectomy model of chronic renal failure. *Circ Res* 1988; 62:367-374.
- Kasiske BL, O'Donnell MP, Cleary MP, et al. Treatment of hyperlipidemia reduces glomerular injury in obese Zucker rats. *Kidney Int* 1988; 33:667-672.
- Harris KPG, Purkerson ML, Yates J, Klaks S. Lovastatin ameliorates the development of glomerulosclerosis and uremia in experimental nephrotic syndrome. *Am J Kidney Dis* 1990; 15:16-23.
- Anderson S, King AJ, Brenner BM. Hyperlipidemia and glomerular sclerosis: an alternative viewpoint. *Am J Med* 1989; 87:S-34N-38N.
- Anderson S, Brenner BM. The critical role of nephron mass and of intraglomerular pressure for initiation and progression of experimental hypertension-renal disorders. [In] Laragh JH, Brenner BM, eds. *Hypertension: Pathophysiology, Diagnosis, and Management*. New York, Raven Press, 1989.
- Spear GS. The glomerulus in cyanotic congenital heart disease and primary pulmonary hypertension: a review. *Nephron* 1964; 1:238-248.
- Spear GS. Glomerular alterations in cyanotic congenital heart disease. *Bull Johns Hopkins Hospital* 1960; 106:347-367.
- Garcia DL, Anderson S, Rennke HG, Brenner BM. Anemia lessens and its prevention with recombinant human erythropoietin worsens glomerular injury and hypertension in rats with reduced renal mass. *Proc Natl Acad Sci (USA)* 1988; 85:6142-6146.
- Wasserman J, Santiago A, Rifici V, et al. Interactions of low density lipoprotein with rat mesangial cells. *Kidney Int* 1989; 35:1168-1174.
- Tauber JP, Goldminz D, Vlodavsky I, Gospodarowicz D. The interaction of high-density lipoprotein with cultured cells of bovine vascular endothelium. *J Biochem* 1981; 119:317-325.
- Moorhead JF, Wheeler DC, Varghese Z. Glomerular structures and lipids in progressive renal disease. *Am J Med* 1989; 87:S-12N-20N.
- Iverius PH. The interaction between human plasma lipoprotein and connective tissue. *J Biol Chem* 1972; 247:2607-2613.
- Diamond JR. Hyperlipidemia of nephroses: pathophysiologic role in progressive glomerular disease. *Am J Med* 1989; 87:S-25N-29N.
- Avram MM. Similarities between glomerular sclerosis and atherosclerosis in human renal biopsy specimens: a role for lipoprotein glomerulopathy. *Am J Med* 1981; 87:394-414.
- Weisinger JR, Kempson RL, Eldridge FL, Swenson RS. The nephrotic syndrome: a complication of massive obesity. *Ann Intern Med* 1974; 81:440-447.
- Moorhead JF, El-Nahas M, Hairy D, et al. Focal glomerular sclerosis and nephrotic syndrome with partial lecithin:cholesterol acyltransferase deficiency and discoidal high-density lipoprotein in plasma and urine. *Lancet* 1982; 1:936-938.
- Saito T, Sato H, Kudo K, et al. Lipoprotein glomerulopathy: glomerular lipoprotein thrombi in a patient with hyperlipoproteinemia. *Am J Kidney Dis* 1989; 13:148-153.
- Kasiske BL, Tortorice KL, Heim-Disthorf KL, Goryance JM, Rao KV. Lovastatin treatment of hypercholesterolemia in renal transplant recipients. *Transplantation* 1990; 49:95-100.
- Vega GL, Grundy SM. Lovastatin therapy in nephrotic hyperlipidemia: effects on lipoprotein metabolism. *Kidney Int* 1988; 33:1160-1168.
- Grundy SM. Management of hyperlipidemia of kidney disease. *Kidney Int* 1990; 37:847-853.