



# Electrocardiographic criteria for anterior myocardial infarction

KAREN B. JAMES, MD; TIMOTHY P. OBARSKI, DO; DONALD A. UNDERWOOD, MD

■ In a two-stage review, electrocardiographic patterns associated with anterior infarction were determined in 135 patients whose diagnoses were established by contrast ventriculography. The five most common findings were tested in 1,324 consecutive patients to assess sensitivity, specificity, and predictive accuracies for anterior myocardial infarction. The criteria were shown to have high positive predictive accuracy and specificity levels, and confirmed the value of the standard 12-lead electrocardiogram for detecting anterior myocardial injury.

□ INDEX TERMS: ELECTROCARDIOGRAPHY; MYOCARDIAL INFARCTION, ANTERIOR □ CLEVE CLIN J MED 1990; 57:618-621

**E**LECTROCARDIOGRAPHIC criteria for anterior myocardial infarction (MI) are well established. Anterior infarction is characterized by Q or QS waves in precordial leads V<sub>1</sub> through V<sub>4</sub>,<sup>1-3</sup> and anterolateral infarcts are identified by Q or QS waves in standard leads I and aVL and precordial leads V<sub>4</sub> through V<sub>6</sub>.

■ See Proudfit (pp 655-656).

Postmortem heart examination,<sup>4,5</sup> contrast ventriculography, vectorcardiography, and thallium scintigraphy<sup>6-8</sup> have been used to evaluate electrocardiographic and pathologic correlations for anterior MI. It is preferable to study these correlations in the living heart because of physiologic conditions such as preload and afterload.

Our study reevaluated the electrocardiographic diagnosis of anterior MI in two phases. First,

ventriculograms were reviewed to identify pure anterior and anterolateral infarctions, and related electrocardiograms (ECGs) were inspected to establish common wave-form patterns associated with these infarctions. Second, these electrocardiographic wave-form patterns were tested for their ability to predict the presence or absence of anterior MI in a large group of consecutive patients evaluated by contrast ventriculography.

## MATERIALS AND METHODS

In phase one, all catheterization ventriculographic reports were reviewed for the 6-month period from July through December 1983. Left ventriculograms were performed in the right anterior oblique projection using a Philips image intensifier and a 35-mm Aritecno or Ariflex camera operated at a speed of 30 frames/s.

All were reviewed for wall motion abnormalities in the anterior, anterolateral, or anteroapical aspects. Wall motion defects were coded for dyskinesia, akinesia, or mild, moderate, and marked hypokinesia. Ventriculograms were excluded if they showed an associated inferior infarction, had any suggestion of valvular dysfunction, including mitral valve prolapse, or

From the Department of Cardiology, The Cleveland Clinic Foundation.

Address reprint requests to D.A.U., Department of Cardiology, The Cleveland Clinic Foundation, 9500 Euclid Avenue, Cleveland, Ohio 44195.

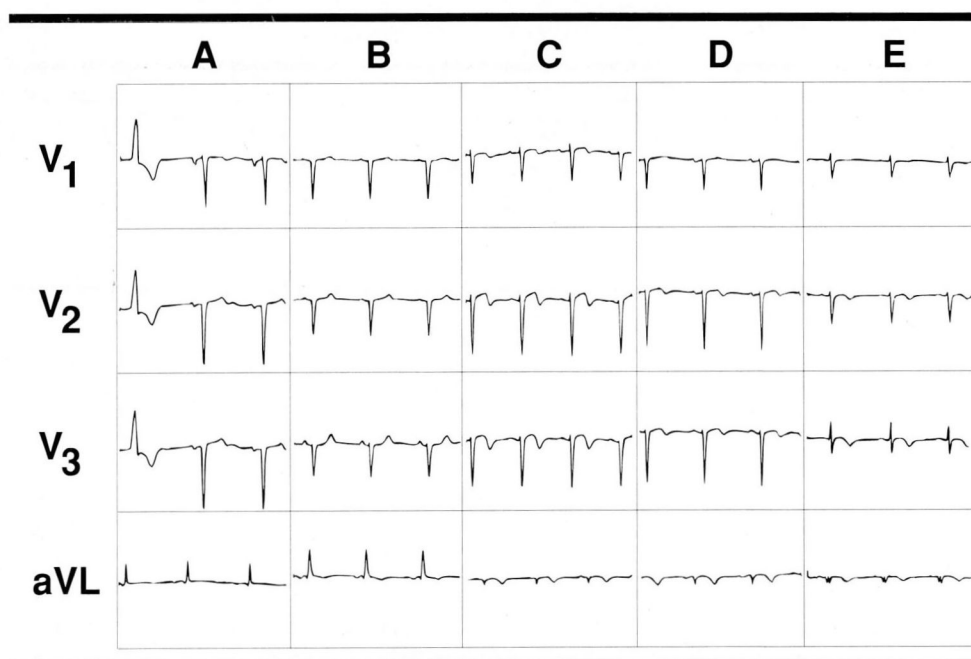


FIGURE 1. Representative electrocardiographic patterns for anterior myocardial infarction. A: QS deflection; B: Q, small R (qR pattern); C: R wave regression; D: poor R wave progression with symmetric terminal negative T waves; E: broad Q wave in aVL.

demonstrated a diffuse myocardial process. Mildly hypokinetic segments were considered normal.

In phase two, electrocardiographic QRS patterns were tested for their accuracy in detecting moderate-to-severe anterior wall motion abnormality, as documented by catheterization. A review was conducted of 1,457 consecutive catheterizations performed over the last 3 months of 1986, and correlations were made between the ventriculogram and the ECG taken within 48 hours of catheterization. Ventriculograms and ECGs were coded independently to ensure blinding of the test results. True-positive, true-negative, false-positive, and false-negative rates for anterior MI were tabulated; and sensitivity, specificity, and predictive values were calculated for each of five electrocardiographic criteria singly and together.

Of 1,457 patients, 133 were excluded because they had left bundle branch block, paced ventricular rhythm, or congenital heart disease, or because their catheterizations had been performed without a contrast ventriculogram.

## RESULTS

Initial review identified 135 patients with pure anterior infarction whose ECGs were used to establish

five criteria for anterior infarction. The five most common QRS patterns in order of decreasing frequency were: (1) QS deflection in any or all leads  $V_3$  through  $V_6$  (QS pattern); (2) Q waves of any duration and amplitude associated with R waves in leads  $V_2$  through  $V_4$  that were  $<0.3$  mV (qR pattern); (3) regression of R waves (ie, a reduction in R-wave amplitude between adjacent leads, except from  $V_5$  to  $V_6$ ); (4) poor R-wave progression (ie, minimal R-wave amplitude increase across the precordial leads with R in  $V_4$  and the precordial leads medial to it  $<0.3$  mV) associated with either symmetric T-wave inversion or biphasic T-waves with terminal symmetric inversion; (5) either Q  $>45$  ms or Q equal to 35 ms with

amplitude 25% that of R wave in aVL. Representative examples of these patterns are shown in Figure 1.

Of 1,324 patients in the test group, 149 had pure anterior infarct as assessed by ventriculography. This group included 115 true-positive examples and 34 false-negative examples. In addition, there were 21 false-positive examples and the remaining 1,154 were true-negative examples of pure anterior MI.

In the true-positive group (Table 1), the most common electrocardiographic abnormality seen in 67 of 115 patients (58%) was QS in lead  $V_3$  or leads lateral to it. Only 5 of 115 patients (4%) demonstrated Q  $>0.45$  ms or Q equal to 0.35 ms with an amplitude equal to 25% of R in aVL.

The 34 false-negative examples (Table 2) were patients whose ECGs lacked all of the five criteria for anterior MI but whose ventriculograms showed evidence of anterior MI.

The 21 false-positive examples (Table 3) were patients whose ECGs met one of the five criteria for anterior MI but whose ventriculograms failed to confirm evidence of anterior MI. The criterion found most frequently in this group (10 of 21 patients) was QS in leads  $V_3$  through  $V_6$ .

**TABLE 1**  
TRUE-POSITIVE RESULTS OF FIVE ECG CRITERIA

| Criterion   | Number (%) of patients |
|---|------------------------|
| QS pattern  | 67 (58)                |
| qR pattern  | 17 (15)                |
| R-wave regression   | 14 (12)                |
| Poor R-wave progression with T-wave changes                     | 12 (11)                |
| Q>0.45 ms or Q=0.35 ms with amplitude 25% of height of R in aVL | 5 (4)                  |

Table 4 shows the total as well as the individual sensitivities, specificities, and positive predictive values of the five patterns. The most sensitive criterion was the QS in  $V_3$  through  $V_6$  (44%), and the least sensitive was the Q in aVL (9%). The sensitivities of the remaining three criteria ranged from 17% to 22%. However, taken together, the overall sensitivity of the five criteria was 77%.

Specificity of each of the five QRS wave forms was excellent: at least 99% for each criterion.

The positive predictive value was greatest for the QS in  $V_3$  through  $V_6$  (87%) and R-wave regression (88%). Positive predictive value of any one of the five criteria was 85%. Negative predictive value for the combined criteria was 97%.

## DISCUSSION

In previous analyses of the diagnostic performance of traditional electrocardiographic criteria for anterior MI,<sup>2-4,6,9</sup> sensitivities ranged from 36% to 78%. Warner and associates<sup>6</sup> used contrast ventriculography to assess electrocardiographic criteria for anterior MI and compiled a list of the 10 best. They reported that the best criteria for identifying anterior MI were the presence of a Q wave of any magnitude or an initial R wave <20 ms in lead  $V_2$ . In their analysis, sensitivities of individual criteria ranged from 64% to 86%.

Specificities of the traditional criteria for anterior MI by prior analyses have ranged from 93% to 100%.<sup>2-4,6,9</sup> In the study by Warner and colleagues,<sup>6</sup> specificities ranged from 95% to 100%. In our study, specificities of each of the five criteria exceeded 99%, which reflected the high number of true-negative results relative to false-positive results.

In our study, the presence of any one of the criteria had a sensitivity of 77%. The most sensitive criterion (44%) was the QS pattern in  $V_3$  through  $V_6$ , and the second most sensitive (22%) was qR <0.3 mV in  $V_2$  through  $V_4$ . For coding purposes we classified mild hypokinesia as normal, despite the presence of some motion abnormality. Nevertheless, predictive accuracy was quite good.

**TABLE 2**  
FALSE-NEGATIVE ECG FINDINGS

| Finding                        | Number (%) of patients |
|--------------------------------|------------------------|
| Nonspecific ST-T changes       | 13 (38)                |
| Inferior myocardial infarction | 9 (26)                 |
| Left ventricular hypertrophy   | 5 (15)                 |
| Normal                         | 4 (12)                 |
| Right bundle branch block      | 2 (6)                  |
| Left anterior hemiblock        | 1 (3)                  |

Our sensitivity and specificity values are consistent with the observation of Arkin and co-workers<sup>10</sup> that, in ECG-ventriculography correlative studies, sensitivity increases while specificity and predictive accuracy decrease with greater degrees of left ventricular asynergy.

The overall positive predictive value of our combined five criteria was 85%. Positive predictive values are influenced by the number of false-positive results, which in turn reflect the prevalence of "disease" in a given population. Whether this value would be lower in a less selected population could not be determined from the present data.

Testing the criteria in a noncatheterization group would require another standard for anterior infarction, such as wall motion abnormalities or thallium defects. It can be argued that wall motion abnormalities do not necessarily mean scar from previous MI and that fixed thallium defects or metabolically silent positron emission tomography regions would be better standards for infarct.

False-negative ECGs in our study showed various findings, including left ventricular hypertrophy, intraventricular conduction defects, pathologic Q waves in "nonanterior" leads, and nonspecific changes. Hilsenrath and associates<sup>11</sup> described their findings in 25 patients who had electrocardiographic criteria for anterior MI but no angiographic coronary artery disease. Rheumatic valvular disease, idiopathic hypertrophic subaortic stenosis, primary myocardial disease, left ventricular hypertrophy, or no disease accounted for their false-positive results. Proudfit and Heupler<sup>12</sup> also described patients with electrocardiographic evidence of infarction but without atherosclerotic heart disease. They added mitral valve prolapse and congenital heart disease to the list of causes of false-positive electrocardiographic findings for MI. Central nervous system diseases such as brain tumor have been shown to mimic anterior MI.<sup>13</sup> Emphysema has also been reported<sup>8</sup> as a cause of an anterior MI pattern (poor R-wave progression), due to lung hyperinflation with descent of the

**TABLE 3**  
FALSE-POSITIVE RESULTS OF FIVE ECG CRITERIA

| Criterion   | Number (%) of patients |
|---|------------------------|
| QS pattern  | 10 (47)                |
| qR pattern  | 3 (14)                 |
| R-wave regression   | 2 (10)                 |
| Poor R-wave progression with T-wave changes                     | 2 (10)                 |
| Q>0.45 ms or Q=0.35 ms with amplitude 25% of height of R in aVL | 4 (19)                 |

diaphragm and lower position of the heart within the chest. Within our group of false-positive cases, 12 had mild anterior hypokinesia and were coded as "normal" despite wall motion abnormalities. Evidence for ventricular hypertrophy was seen in 6 and generalized cardiomyopathy in 1. Normal ventricles were seen in 3 patients by contrast ventriculography.

Based on the predictive accuracy of our results, we

**TABLE 4**  
SENSITIVITY, SPECIFICITY, AND POSITIVE PREDICTIVE VALUES\*

| Criterion   | Sensitivity (%) | Specificity (%) | Positive predictive value (%) |
|---|-----------------|-----------------|-------------------------------|
| QS pattern  | 44              | 99              | 87                            |
| qR pattern  | 22              | 99              | 85                            |
| R-wave regression   | 19              | 100             | 88                            |
| Poor R-wave progression with T-wave changes                     | 17              | 100             | 86                            |
| Q>0.45 ms or Q=0.35 ms with amplitude 25% of height of R in aVL | 9               | 100             | 50                            |
| Any abnormality   | 77              | 98              | 85                            |

\*149 patients with anterior infarcts

conclude that when standard and multiple criteria are used, the ECG is a reliable tool to detect anterior myocardial infarction.

#### REFERENCES

- Chung EK. Electrocardiography: practical applications with vectorial principles. Hagerstown, MD: Harper and Row, 1980, p. 108.
- McConahay DR, McCallister BD, Hallermann FJ, Smith RE. Comparative quantitative analysis of the electrocardiogram and the vectorcardiogram. *Circulation* 1970; **42**:245-249.
- Friedman HH. Diagnostic electrocardiography and vectorcardiography. New York: McGraw-Hill, 1977, p.242.
- Myers GB, Klein HA, Stofer BE. Correlation of electrocardiographic and pathologic findings in anteroseptal infarction. *Am Heart J* 1948; **36**:535-575.
- Horan LG, Flowers NC, Johnson JC. Significance of the diagnostic Q wave of myocardial infarction. *Circulation* 1971; **43**:428-436.
- Warner RA, Reger M, Hill NE, Mookherjee S, Smulyan H. Electrocardiographic criteria for the diagnosis of anterior myocardial infarction: importance of the duration of precordial R waves. *Am J Cardiol* 1983; **52**:690-692.
- DePace NL, Colby J, Hakki A-H, Manno B, Horowitz LN, Iskandrian A. Poor R wave progression in the precordial leads: clinical implications for the diagnosis of myocardial infarction. *J Am Coll Cardiol* 1983; **2**(6):1073-1079.
- Hart GJ, Barrett PA, Barnaby PF, Clark EH, Lyons NR, Burke JJ. Diagnosis of old anterior myocardial infarction in emphysema with poor R wave progression in anterior chest leads. *Br Heart J* 1981; **45**:522-526.
- Lipman BS, Massie E, Kleiger RE. Clinical Scalar Electrocardiography. Chicago: Yearbook Medical Publishers, 1972, pp.219-220.
- Arkin BM, Hueter DC, Ryan TJ. Predictive value of electrocardiographic patterns in localizing left ventricular asynergy in coronary artery disease. *Am Heart J* 1979; **97**:453-459.
- Hilsenrath J, Hamby RI, Glassman E, Hoffman I. Pitfalls in prediction of coronary arterial obstruction from patterns of anterior infarction on electrocardiogram and vectorcardiogram. *Am J Cardiol* 1972; **29**:164-170.
- Proudfit WL, Heupler FA. Electrocardiographic evidence suggestive of myocardial infarction without significant organic heart disease. *Am Heart J* 1985; **110**:448-452.
- Conetta R, Gitler B. Electrocardiographic anterior wall pseudoinfarction pattern caused by a metastatic brain tumor. *NY State J Med* 1987; **87**:125-127.