

The effects of steroid therapy on pulmonary hypertension secondary to fibrosing mediastinitis

EDWARD M. CORDASCO, JR, DO; MUZAFFAR AHMAD, MD; ATUL MEHTA MD; FELIPE RUBIO, MD

■ Mediastinal fibrosis, a rare cause of pulmonary hypertension, may produce cough, dyspnea, and hemoptysis. Steroid therapy has been suggested for individuals with progressive symptoms, but data demonstrating the efficacy of such therapy are lacking. We present a case of pulmonary hypertension secondary to fibrosing mediastinitis. Hemodynamic and scintigraphic studies performed before and after a trial of corticosteroid therapy were unable to demonstrate any therapeutic benefit from the corticosteroids. In order to achieve better use of steroids for the treatment of this disease, we suggest that similar determinations be made on other patients with mediastinal fibrosis who receive such treatment.

□ INDEX TERM: PULMONARY HYPERTENSION □ CLEVE CLIN J MED 1990; 57:647-652

PULMONARY hypertension develops in response to either accelerated blood flow through the pulmonary vascular circuit or increased pulmonary vascular resistance.¹ Reduction in the cross-sectional area of the pulmonary vascular bed, which raises vascular resistance, is usually attributed to a one of several frequently occurring, well-characterized illnesses.²⁻¹⁰ An infrequently encountered cause of pulmonary vascular compromise and hypertension is fibrosing mediastinitis.

The characteristic intense fibrosis that accompanies this process can involve the entire pulmonary circuit and may compress, infiltrate, or occlude arterial and

venous structures.¹¹ Corticosteroids have been used to treat the sclerosis in severe or progressive pulmonary hypertension produced by fibrosing mediastinitis,¹² but no objective data are available to substantiate their efficacy. Frequently, improvement is judged by a change in the patient's sense of well-being after a steroid trial rather than by objective alteration of hemodynamic or radiographic parameters.

We present a case in which fibrosing mediastinitis produced documented pulmonary hypertension. This case is unique because we used follow-up scintigraphic and hemodynamic measurements to assess the patient's response to a trial of prednisone therapy.

CASE PRESENTATION

A 34-year-old female sought evaluation for a 2-year history of episodic coughing and hemoptysis. Each bout of coughing, which was preceded by a choking sensation and retrosternal tickling, produced bright red, blood-

From the Department of Pulmonary Disease (E.M.C., M.A., A.M.), The Cleveland Clinic Foundation, and Kettering Medical Center (F.R.), Kettering, Ohio.

Address reprint requests to E.M.C., Department of Pulmonary Disease, The Cleveland Clinic Foundation, One Clinic Center, 9500 Euclid Avenue, Cleveland, Ohio 44195-5028.

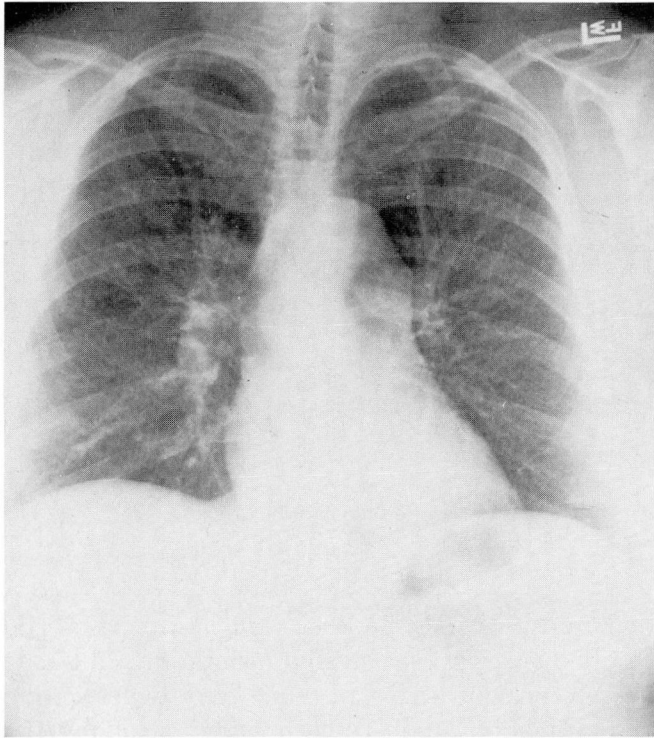


FIGURE 1. Posteroanterior chest radiograph showing mild pulmonary artery prominence.

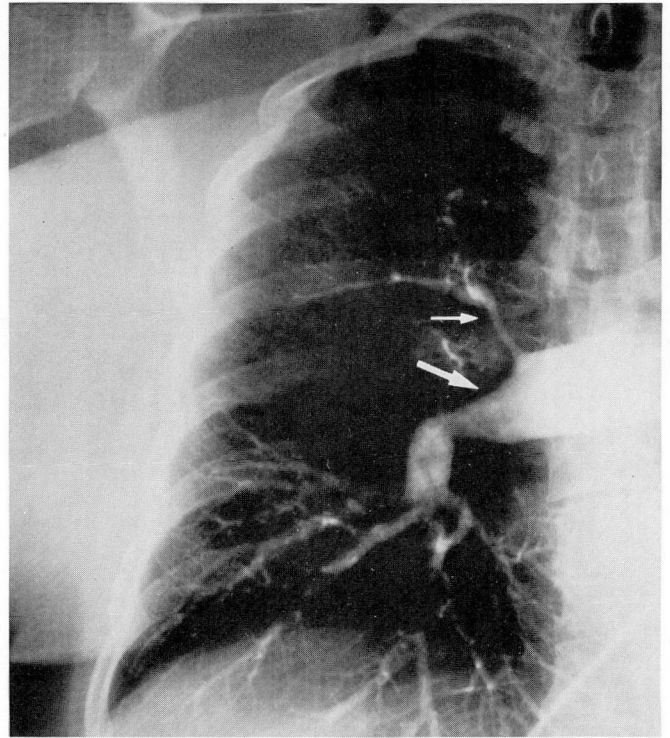


FIGURE 2. Pulmonary angiogram demonstrating concentric narrowing of the right upper lobe artery (thin arrow) and abrupt cutoff of the right middle lobe pulmonary artery (thick arrow).

streaked, sputum. Over the past year, she also noted exertional dyspnea that limited maximal activity. She was a native of southern Ohio, worked as a processor of injection molded plastic, and was an active 15 pack-year cigarette smoker. Despite several courses of antibiotics for presumed bronchitis, her symptoms persisted and she was hospitalized locally for evaluation.

At the time of hospitalization, her physical examination was unremarkable. A chest radiograph showed mild prominence of the pulmonary arteries (Figure 1). Blood tests—which included a complete blood count with differential, electrolytes, liver function tests, and coagulation parameters—were normal. Precipitin antibodies to *Histoplasma capsulatum* were negative, but a skin test was positive with 18 mm of induration. Sinus rhythm was demonstrated on an electrocardiogram. An echocardiogram showed normal ventricular and valvular function. Fiberoptic bronchoscopy revealed extrinsic right upper lobe compression and friable bronchial mucosa. Bronchial washings, cytology, and stains for fungus and acid-fast bacilli were negative.

A ventilation perfusion lung scan showed large unmatched perfusion defects in the right upper, right mid-

dle, and left lower lobes. As a result, pulmonary embolism was considered and lower extremity venograms and pulmonary angiography were performed. The venograms were normal. The pulmonary angiogram (Figure 2) showed narrowing of the right upper lobe artery, abrupt cutoff of the right middle lobe artery, and absence of the left lower lobe arterial segment. Pulmonary embolism was an unlikely diagnosis because there was no angiographic evidence of smooth and oddly shaped intraluminal filling defects producing distorted “corkscrew” vessels.

Right heart catheterization demonstrated an elevated pulmonary arterial pressure (57/17 mmHg; mean, 33 mmHg) and a normal cardiac output of 6L/min. Pulmonary wedge pressures were not obtained during catheterization because of technical difficulties. Computerized tomography of the chest demonstrated bilateral calcified hilar lymph nodes encroaching upon right and left pulmonary vascular structures (Figure 3).

The diagnosis of fibrosing mediastinitis was established, based on the combination of clinical features and laboratory findings; ie, recurrent hemoptysis, localized

friable bronchial mucosa, pulmonary hypertension with normal ventricular and valvular function, calcified lymph node compromise of pulmonary vascular structures with corresponding angiographic compression and cutoff of these same vascular areas, absence of intraluminal pulmonary or peripheral vascular filling defects, and evidence of prior *Histoplasma* exposure. Berry and co-workers,¹² in their series of patients with pulmonary hypertension secondary to fibrosing mediastinitis described an identical constellation of clinical features.

The patient received a 4-week course of oral prednisone, 60 mg every other day. She noted no recurrence of hemoptysis during therapy but her dyspnea was unchanged. Right heart catheterization and a ventilation perfusion lung scan were performed at the end of therapy. No change was noted in the pulmonary arterial pressure nor in the ventilation perfusion scan compared to pretreatment studies. In view of the patient's fixed scintigraphic perfusion defects, persistent pulmonary arterial hypertension, and persistence of symptoms, steroids were discontinued.

DISCUSSION

Fibrosing mediastinitis is an unusual sclerosing condition that impairs mediastinal organ function by compression and infiltration of localized structures. Although confined to the mediastinum, the illness may represent the regional expression of a generalized systemic, sclerosing disease.¹³ Reports that support this notion have described an association between fibrosing mediastinitis, retroperitoneal fibrosis,¹⁴⁻¹⁹ and other illnesses of a sclerosing nature, including sclerosing cholangitis, Riedel's thyroiditis, orbital pseudotumor, and constrictive pericarditis.¹³⁻²⁰ Certain connective tissue diseases (scleroderma,²¹ systemic lupus erythematosus²²), vasculitides (polyarteritis nodosa,²³ systemic necrotizing vasculitis²⁴), and drugs (ergotamine, methysergide, hydralazine, and propranolol²⁵⁻²⁷) have been specifically implicated as causes of retroperitoneal fibrosis. However, the association of these illnesses and medications with the development of fibrosing mediastinitis is less certain.

H capsulatum is the infectious agent most commonly implicated in both retroperitoneal and mediastinal fibrosis.²⁸ Tuberculosis has been less frequently identified in surgical specimens²⁸ and only a few reports attribute mediastinal fibrosis to *Aspergillus* species.^{29,30,31} Host response to caseous lymph nodes induced by these infectious agents may cause either a localized, compressive

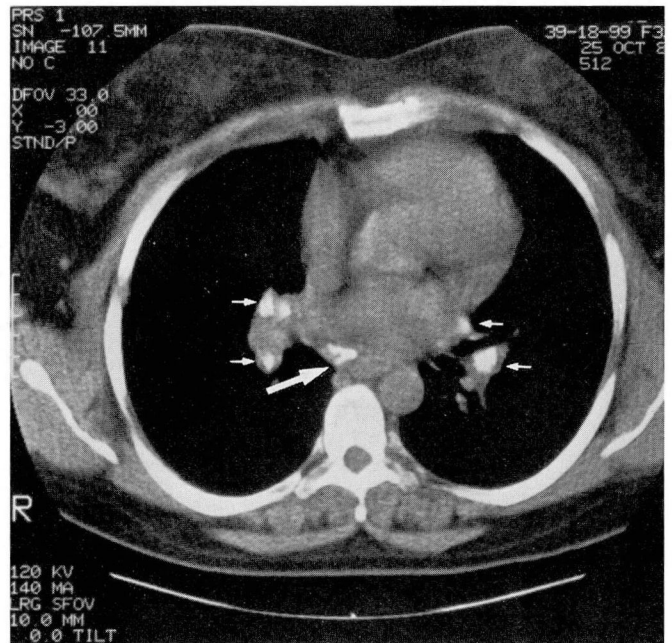


FIGURE 3. Calcified bilateral hilar lymph nodes (thin arrow) and mediastinal node (thick arrow).

mediastinal disease (mediastinal granuloma) or a diffuse illness with mediastinal structure infiltration and obliteration (fibrosing mediastinitis). Fibrotic capsular containment of caseous material within lymph nodes produces an enlarging mass separate from mediastinal structures and may account for granuloma formation. On the other hand, leakage of immunologically active lymph node material, which incites an aggressive, diffuse mediastinal sclerosis, may account for organ obliteration seen in mediastinal fibrosis. It is uncertain whether these processes represent distinct clinical entities or a spectrum of disease with evolution of the aggressive fibrosing form from the more benign granulomatous type, but support for both mechanisms can be found in the literature.^{28,32}

Clinical features

Early histopathologic features include a collagenous stroma with varying degrees of fibroblast activity and a mixed cellular inflammatory infiltrate consisting of neutrophils, plasma cells, lymphocytes, and eosinophils.^{20,33} Late histopathologic findings are characterized by an acellular, bland fibrotic mass occasionally interrupted by caseous foci.^{20,28} Whether this sequence of histopathologic change, with an initial inflammatory, cellular phase and a late acellular scar phase, supports

the notion of an underlying, primary autoimmune or cellularly mediated hypersensitivity reaction has been a matter of speculation.^{20,24,34}

Sclerotic obstruction and obliteration of mediastinal structures by fibrosing mediastinitis produces a broad spectrum of symptoms. Cough, dyspnea, and hemoptysis—the symptoms experienced by our patient—were reported to occur in 41%, 32%, and 31% of patients respectively in one series.³⁵ Contributors to the development of these symptoms include impaired ventricular function caused by vena caval obstruction, pericardial restriction, and coronary arterial fibrosis; limited ventilation and gas exchange due to airway compression and interstitial pulmonary fibrosis; and pulmonary hypertension produced by pulmonary vascular obstruction.^{11,20,35}

Arterial or venous pulmonary vascular obstruction with concomitant pulmonary hypertension has been described in a number of case reports.^{11,12,13,35-43} Angiography, operative descriptions, and surgical specimens have confirmed pulmonary vascular involvement in these cases. Although concomitant involvement of both the arterial and venous pulmonary vascular beds has been most frequently noted, solitary pulmonary venous or arterial compromise has also been reported.

Pulmonary angiograms most commonly describe occluded or cutoff vessels as well as areas of focal constriction and narrowing. Since chronic pulmonary thromboembolism may produce similar angiographic findings and pulmonary hypertension,⁴⁴ this is the other well-recognized illness to include in the differential diagnosis. However, the unusual corkscrew changes produced by oddly shaped, partially recanalized filling defects seen with chronic pulmonary embolism have not been noted in patients with fibrosing mediastinitis. Other clinical features, such as calcified hilar or mediastinal lymph nodes and mediastinal mass lesions adjacent to the vascular area of narrowing, also clarify the diagnosis.

The severity of pulmonary hypertension as documented by pressure measurements is variable and does not necessarily correlate with the degree of pulmonary vascular compromise observed on angiography or at the time of thoracic surgery. Arnett and co-workers,¹¹ in their series of patients with pulmonary hypertension and mediastinal fibrosis, suggested several mechanisms for the production of pulmonary hypertension, including pulmonary venous and arterial obstruction, thrombotic occlusion of small intrapulmonary arteries, pulmonary parenchymal fibrosis with or without vasoconstrictive hypoxemia, or a combination of these changes.

Natural history

The natural history of mediastinal fibrosis was outlined by Loyd and associates³⁵ in their review of 71 cases. Mean survival after onset of symptoms was 5.9 years and mortality rate approximated 30%. Death most frequently resulted from progressive respiratory insufficiency and cor pulmonale, although nine deaths occurred after thoracic surgical interventions, two during bronchoscopy, and two following cardiac catheterization.

The natural history and prognosis of mediastinal granuloma is less well-defined, especially since the distinction between granulomatous and fibrosing mediastinitis has not been universally embraced in the literature. Depending upon the structure or structures compromised by mediastinal granuloma, symptoms and organ dysfunction are usually self-limited or slowly progressive. Therefore, many recommend conservative treatment, reserving surgical intervention until intractable or life-threatening symptoms develop.^{20,45-47}

Treatment considerations

Symptomatic esophageal and superior vena caval obstruction produced by mediastinal granuloma has been treated safely and successfully with surgery.³⁵ On the other hand, surgical correction of mediastinal fibrosis is technically difficult and dangerous. The mortality rates reported for patients with mediastinal fibrosis who undergo surgery have ranged from 7% with thoracotomy,⁴⁰⁻⁴² to 50% with pneumonectomy,^{35,48,49} to 100% in two patients who underwent attempted airways reconstruction.⁵⁰ However, several authors have reported successful surgical outcome in patients with localized mediastinal fibrosis for control of hemoptysis and relief of superior vena caval and pulmonary vascular obstruction.⁵¹⁻⁵⁶ Therefore, surgical outcome appears to correlate best with the extent of mediastinal involvement; the discrete lesion of granulomatous disease usually proves more resectable than the extensive disease produced by mediastinal fibrosis.

Treatment with amphotericin B does not seem to alter the course or symptoms of either mediastinal or granulomatous fibrosis.³⁵ Amelioration of symptoms caused by fibrosing mediastinitis has been reported in select cases with the use of corticosteroids.^{12,13,15,57,58} The patients treated with steroids in Berry and co-workers' series¹² (Table 1) all had documented pulmonary hypertension and angiographic evidence of pulmonary vascular obstruction. In two of the three patients, symptoms improved after administration of prednisone; however, dosage and treatment duration were not clearly specified. Furthermore, no objective changes in either

TABLE 1
STEROID TREATMENT OF MEDIASTINAL FIBROSIS AND PULMONARY HYPERTENSION

Patient description	Reference	Pulmonary arterial pressure (mmHg)	Angiographic findings	Treatment	Outcome
28-year-old female with dyspnea and cough	12	87/45	Cutoff of right lower and middle lobe arteries, 80% narrowing of right main pulmonary artery	Prednisone (unspecified dose and duration)	Improved cough, dyspnea unaffected
28-year-old female with hemoptysis and dyspnea	12	70/30	Dilated left main pulmonary artery with attenuated distal vessels	Prednisone (unspecified dose and duration)	Resolution of signs and symptoms of pulmonary hypertension attributed to move to sea level
68-year-old female with dyspnea	12	70/24	Total obstruction of right pulmonary artery	Prednisone (unspecified dose and duration)	Substantial relief of cough; chest pain, dyspnea unaffected
34-year-old female with cough, hemoptysis, and dyspnea	Present case	57/17	Narrowed right upper lobe artery, cutoff of right middle and left lower lobe arterial segments	Prednisone, 60 mg qod for 1 month	No improvement in symptoms, no change in pulmonary perfusion or arterial pressure

angiographic anatomy or hemodynamics were observed during the reported period of subjective improvement.

Other case reports^{13,55,57,58} mention the use of corticosteroids (ACTH in a report by Kunkle and associates⁵⁷) in patients with fibrosing mediastinitis. Patients in these reports had evidence of airway compromise, pulmonary vascular obstruction, superior vena caval compression, or a combination of these problems, but no evidence of pulmonary hypertension. The patients improved by subjective standards after the administration of various doses of corticosteroids for varying durations of time. However, in no case was there documented objective anatomic or physiologic improvement that coincided with the subjective improvement.

RECOMMENDATIONS

Our patient's pulmonary angiogram demonstrated focal narrowing of the right upper lobe artery and cutoff of both the right middle and left lower lobe pulmonary arterial segments. Nuclear scans failed to demonstrate perfusion in these same areas of vascular compromise.

REFERENCES

- McFadden RE, Braunwald E. Cor Pulmonale. [In] Braunwald E, ed. Heart Disease: A textbook of Cardiovascular Medicine. 3rd ed. Philadelphia, WB Saunders, 1988.
- Harris P, Heath D. The Human Pulmonary Circulation. 3rd ed. New York, Churchill Livingstone, 1986, p 702.

These changes coincided with a moderate degree of pulmonary hypertension in the face of normal ventricular and valvular function. Failure to either reduce pulmonary hypertension or improve pulmonary scintigraphic perfusion was used as an objective endpoint, leading to the decision to discontinue the therapeutic trial of steroids. We arbitrarily chose a steroid trial duration of 1 month, since the literature defines no treatment interval. However, some will argue that perhaps the treatment time may not have been long enough to achieve anti-inflammatory effect.

In the absence of well-defined clinical efficacy and therapeutic guidelines we suggest that objective patient data be collected before and after steroid trials in order to more clearly define the role, if any, of steroid therapy for this disease process.

ACKNOWLEDGMENTS

We thank Ms. Carolyn Conti for her technical assistance in preparing the manuscript.

- Wagenvoort CA, Wagenvoort N. Pathology of Pulmonary Hypertension. 2nd ed. New York, John Wiley and Sons, 1977.
- Burrows B, Kettel LJ, Niden AH, Rabinowitz M, Diener CF. Patterns of cardiovascular dysfunction in chronic obstructive lung disease. N Engl J Med 1972; 286:912-918.
- Leavitt RY, Fauci AS. Pulmonary vasculitis. Am Rev Respir Dis 1986; 134:149-166.

6. Kane RD, Hawkins HK, Miller JA, Noce PS. Microscopic pulmonary tumor emboli associated with dyspnea. *Cancer* 1975; 36:1473-1482.
7. Jacques JE, Barclay R. The solid sarcomatous pulmonary artery. *Br J Dis Chest* 1960; 54:217-220.
8. Haworth SC. Primary pulmonary hypertension. *Br Heart J* 1983; 49:517-521.
9. McGoon MD, Edwards WD. Primary pulmonary hypertension: current Status. *Mod Concepts Cardiovasc Dis* 1985; 54:29-33.
10. Fuster V, Steele PM, Edwards WD, Gersh BJ, McCoon MD, Frye RL. Primary pulmonary hypertension: natural history and the importance of thrombosis. *Circulation* 1984; 70:580-587.
11. Arnett EN, Bacos JM, Macher AM, Marsh HB, Savage DD, Fulmer JD, Roberts WC. Fibrosing mediastinitis causing pulmonary arterial hypertension without pulmonary venous hypertension: clinical and necropsy observations. *Am J Med* 1977; 63:634-643.
12. Berry DF, Buccigrossi D, Peabody J, Peterson KL, Moser KM. Pulmonary vascular occlusion and fibrosing mediastinitis. *Chest* 1986; 89:296-301.
13. Comings DE, Skubi KB, Van Eyes J, Motulsky AG. Familial multifocal fibrosclerosis. Findings suggesting that retroperitoneal fibrosis, mediastinal fibrosis, sclerosing cholangitis, Reidel's thyroiditis and pseudotumor of the orbit may be different manifestations of a single disease. *Ann Intern Med* 1967; 66:884-892.
14. Buckberg GD, Dilley RB, Longmire WP, Jr. The protean manifestation of sclerosing fibrosis. *Surg Gynecol Obstet* 1966; 123:729-736.
15. Cameron DG, Ing ST, Boyle M, Mathews WH. Idiopathic mediastinal and retroperitoneal fibrosis. *Can Med Assoc J* 1961; 85:227-232.
16. Inkley SR, Abbott GR. Unilateral pulmonary arteriosclerosis. Unusual fibrous connective tissue growth, review of the literature, and discussion of possible physiological mechanisms involved in these changes. *Arch Intern Med* 1961; 108:903-915.
17. Morgan AD, Loughridge LW, Calne RY. Combined mediastinal and retroperitoneal fibrosis. *Lancet* 1966; 1:67-70.
18. Partington PF. Diffuse idiopathic fibrosis. *Am J Surg* 1961; 101:239-244.
19. Tubbs OS. Superior vena caval obstruction due to chronic mediastinitis. *Thorax* 1946; 1:247-256.
20. Hanley PC, Shub C, Lie JT. Constrictive pericarditis associated with combined idiopathic retroperitoneal and mediastinal fibrosis. *Mayo Clin Proc* 1984; 59:300-304.
21. Mansell MA, Watts RWE. Retroperitoneal fibrosis and scleroderma. *Postgrad Med* 1980; 56:730-733.
22. Lipman RL, Johnson B, Berg G, et al. Idiopathic retroperitoneal fibrosis and probable systemic lupus erythematosus. *JAMA* 1966; 196:1022-1024.
23. Hollingworth P, Denman AM, Gumpel JM. Retroperitoneal fibrosis and polyarteritis nodosa successfully treated by intensive immunosuppression. *J R Soc Med* 1980; 73:61-64.
24. Littlejohn GO, Keystone EC. The association of retroperitoneal fibrosis with systemic vasculitis and HLA-B27. A case report and review of the literature. *J Rheumatol* 1981; 8:665-669.
25. Kinder CH. Retroperitoneal fibrosis. *J R Soc Med* 1979; 72:485-487.
26. Pierce JR, Trosle DC, Warner JJ. Propranolol and retroperitoneal fibrosis. *Ann Intern Med* 1981; 95:244.
27. Henri L, Groleau M. Retroperitoneal fibrosis after treatment with propranolol [letter]. *Drug Intell Clin Pharm* 1981; 15:696.
28. Goodwin RA, Nickell JA, Des Prez RM. Mediastinal fibrosis complicating healed primary histoplasmosis and tuberculosis. *Medicine* 1972; 51:227-246.
29. Ahmad M, Weinstein AJ, Hughes AJ, Cosgrove DE. Granulomatous mediastinitis due to *Aspergillus flavus* in a nonimmunosuppressed patient. *Am J Med* 1981; 70:887-890.
30. Puri S, Factor SM, Farmer P. Sclerosing mediastinitis. Presumed to be due to primary aspergilliosis. *NY State J Med* 1977; 77:1774-1777.
31. Schowengerdt CG, Suyemoto R, Main FB. Granulomatous and fibrous mediastinitis. A review and analysis of 180 cases. *J Thorac Cardiovasc Surg* 1969; 57:365-379.
32. Dines DE, Payne WS, Bernatz PE, Pairolero PC. Mediastinal granuloma and fibrosing mediastinitis. *Chest* 1979; 75:320-324.
33. Hache L, Woolner LB, Bernatz PE. Idiopathic fibrous mediastinitis. *Dis Chest* 1961; 41:9-25.
34. Morad N, Strongwater SL, Eypper S, Woda BA. Idiopathic retroperitoneal and mediastinal fibrosis mimicking connective tissue disease. *Am J Med* 1987; 82:363-366.
35. Loyd JE, Tillman BF, Atkinson JB, Des Prez RM. Mediastinal fibrosis complicating histoplasmosis. *Medicine* 1988; 67:295-310.
36. Dupont HL, Varco RL, Winchell CP. Chronic fibrous mediastinitis simulating pulmonic stenosis associated with inflammatory pseudotumor of the orbit. *Am J Med* 1968; 44:447-452.
37. Wieder S, White TJ III, Salazar J, Gold RE, Moinuddin M, Tonkin I. Pulmonary artery occlusion due to histoplasmosis. *Am J Roentgenol* 1982; 138:243-251.
38. Delbanco TL, Medina JR, Sadler TR Jr, Nelson WP. Bilateral pulmonary artery obstruction due to fibrosing mediastinitis: case report. *Milit Med* 1976; 141:335-339.
39. Edwards JE, Burchell HB. Multilobar pulmonary venous obstruction with pulmonary hypertension. *Arch Int Med* 1951; 87:372-378.
40. Clinicopathologic Conference (JHH 66 4434). *Johns Hopkins Hosp Bull* 1967; 119:288-297.
41. Nasser WK, Feigenbaum H, Fisch C. Clinical and hemodynamic diagnosis of pulmonary venous obstruction due to sclerosing mediastinitis. *Am J Cardiol* 1967; 20:725-729.
42. Trinkle JK. Fibrous mediastinitis presenting as mitral stenosis. *J Thorac Cardiovasc Surg* 1970; 62:161-162.
43. Botticelli JT, Schlueter DP, Lange RL. Pulmonary venous and arterial hypertension due to chronic fibrous mediastinitis: hemodynamics and pulmonary function. *Circulation* 1966; 33:862-871.
44. Moser KM, Daily PO, Peterson K, et al. Thromboendarterectomy for chronic, major-vessel thromboembolic pulmonary hypertension. *Ann Intern Med* 1987; 107:560-565.
45. Goodwin RA, Loyd JE, Des Prez RM. Histoplasmosis in normal hosts. *Medicine* 1981; 60:231-266.
46. Lochridge SK, Knibbe WP, Doty DB. Obstruction of the superior vena cava. *Surgery* 1979; 85:14-24.
47. Mitchinson MJ. Aortic disease in idiopathic retroperitoneal and mediastinal fibrosis. *J Clin Pathol* 1972; 25:287-293.
48. Mulder H, Botenga AS, van der Meiden C. Transpleural vascularization of pulmonary arteries in fibrous mediastinitis. Report of a case. *Radiol Clin* 1976; 45:175-182.
49. Prager RL, Burney P, Waterhouse G, Bender HW Jr. Pulmonary, mediastinal, and cardiac presentations of histoplasmosis. *Ann Thorac Surg* 1980; 30:385-390.
50. Hewlett TH, Steer A, Thomas DE. Progressive fibrosing mediastinitis. *Ann Thorac Surg* 1966; 2:345-357.
51. Mitchell IM, Saunders NR, Maher O, Lennox SC, Walker DR. Surgical treatment of idiopathic mediastinal fibrosis: report of five cases. *Thorax* 1986; 41:210-214.
52. Doty DB. Bypass of superior vena cava. Six years' experience with spiral vein graft for obstruction of superior vena cava due to benign and malignant disease. *J Thorac Cardiovasc Surg* 1982; 83:326-338.
53. Arrigoni MG, Bernatz PE, Donaghue FE. Broncholithiasis. *J Thorac Cardiovasc Surg* 1971; 62:231-237.
54. Cosio FG, Gobel FL, Harrington DP, Sako Y. Pulmonary arterial stenosis with wide splitting of the second heart sound due to mediastinal fibrosis. *Am J Cardiol* 1973; 31:372-376.
55. Hicks GL. Fibrosing mediastinitis causing pulmonary artery and vein obstruction with hemoptysis. *NY State J Med* 1983; 83:242-244.
56. Dye TE, Saab SB, Almond CH, Watson L. Sclerosing mediastinitis with occlusion of the pulmonary veins. *J Thorac and Cardiovasc Surg* 1977; 74:137-141.
57. Kunkle WM Jr, Clagett OT, McDonald JR. Mediastinal granulomas. *J Thorac Surg* 1954; 27:565-574.
58. Carton RW, Wong R. Multifocal fibrosclerosis manifested by vena caval obstructions and associated with vasculitis. *Ann Intern Med* 1969; 70:81-86.