

# Factitious anisocoria and orthostatic hypotension

OSITADIMMA A. ONYEKWERE, MD; HAROLD MORRIS, MD; RON VICTOR, MD; AND FETNAT M. FOUAD-TERAZI, MD

■ A 30-year-old woman employed by a veterinarian had many episodes of syncope. At presentation, she had anisocoria and premature ventricular beats. Hemodynamic workup revealed only moderate peripheral venous pooling. The circumstances of the fainting spells and eye examination led to the identification of medications which, if taken surreptitiously, will induce the perplexing clinical picture which the patient presented.

□ INDEX TERMS: ANISOCORIA; HYPOTENSION □ CLEVE CLIN J MED 1991; 58:229-233

**T**HE DIAGNOSIS of orthostatic hypotension is strongly suggested when a significant drop in blood pressure occurs as the patient changes position from sitting to standing, etc.<sup>1</sup> The drop in pressure may be predominantly systolic or diastolic, or it may be both. The specific component of blood pressure affected suggests the underlying etiology: systolic hypotension is usually associated with low cardiac output states such as hypovolemia occurring with or without excessive peripheral venous pooling; diastolic hypotension suggests a defect in peripheral systemic vascular resistance and is usually associated with significant autonomic neuropathy.

The symptoms of orthostatic hypotension may be disabling, and complications due to events such as falls or injuries involving bone fractures generate high medical costs and may incapacitate the patient for long periods of time. In order to precisely evaluate and diagnose these patients, we have developed a "stepped-care" work-up for orthostatic hypotension.<sup>2,3</sup> Patients referred for this work-up usually have had a full, nega-

tive neurologic assessment. In our hemodynamic laboratory we follow these steps: tilt test, blood volume determination, and assessment of hemodynamic indices such as cardiac output, systemic resistance, and venous tone.<sup>2,3</sup> Specific autonomic testing aids in the localization of a diagnosed autonomic dysfunction.<sup>4</sup> Specific therapy is initiated depending on the diagnosis.

In the following report, we describe a very unusual case of factitious anisocoria with associated orthostatic hypotension.

## CASE PRESENTATION

A 30-year-old white woman was referred for further evaluation of recurrent syncope. She was an employee of a veterinarian. In November 1988, she had an episode of syncope, reportedly with a pulse of 32 beats per minute. Subsequently, she had many episodes, as many as twice per week. The patient reported that a prodrome of tunnel vision sometimes occurred, but that the onset of many of these episodes was sudden and occurred without warning. In the 3 weeks before she presented to us, she had urinary incontinence with some of the episodes of fainting. She also reported that her syncopal episodes had occurred at any time of day or night, but seemed to occur more commonly in the morning and were not necessarily associated with instantaneous change in posture or with prolonged

From the Department of Heart and Hypertension Research (O.A.O., H.M., F.M.F.T.), and the University of Texas Southwestern Medical Center (R.V.).

Address reprint requests to F.M.F.T., The Cleveland Clinic Foundation, One Clinic Center/FF10-2b, 9500 Euclid Avenue, Cleveland, Ohio 44195.

TABLE  
HEMODYNAMIC DATA

	Supine	Upright (60° for 10 minutes)
Heart rate (bpm)	64	70
Systolic blood pressure (mm Hg)	107	114
Diastolic blood pressure (mm Hg)	74	76
Cardiac index (l/min/m <sup>2</sup> )	2.9	2.1
Stroke volume (mL)	74	48
Total peripheral resistance (units × m <sup>2</sup> )	29	42
Cardiopulmonary volume to total blood volume (%) (an index of venous tone)	17	10

periods of standing still. Some episodes were associated with palpitation. She reported other events that include occasional chest pain in the left axilla with associated shortness of breath. Previous electrocardiographic and Holter monitor studies revealed sinus arrhythmia and premature ventricular beats accompanied by occasional bigeminy. Echocardiography performed some four years earlier for an unrelated problem had suggested mitral valve prolapse at that time, but that diagnosis was not confirmed. The patient's history also included endometriosis, ovarian cyst, surgical resection of a benign breast lesion, and, during the year previous to her presentation to us, episodes of epistaxis. She denied currently taking medications, but had been treated previously with propranolol, quinidine, nadolol (Corgard), encainide (Enkaid), and scopolamine patch.

The patient's neurologic history consisted of childhood migraine headaches and a family history of migraine. Headaches had occurred in childhood but had not been a problem for several years. She reported that approximately 8 months before this evaluation she noted pupillary changes following a car accident: she reported that she awoke with her right pupil maximally dilated and had associated blurring of vision in her right eye. Three weeks after this dilation of her right pupil, she noticed that the left one also became dilated, but later it spontaneously returned to normal size. Computed tomography scanning of the head and magnetic resonance imaging of the brain performed at that time had revealed normal findings.

The patient was admitted to the hospital for evaluation of recurrent syncope and cardiac arrhythmia. She was 165 cm in height and weighed 59 kg; her pulse was irregularly irregular, at a rate of 62 bpm while sitting and 66 bpm while standing. Sitting blood pressure was 110 to 114/66 to 74, and standing blood pressure was

108/70. Her skin was freckled and tanned; she had no cutaneous track marks. Lungs were clear; cardiac examination revealed irregularly irregular rhythm, normal rate, and no murmurs, gallops, clicks, or rubs; abdominal examination was unremarkable. Her neurologic examination showed that her right pupil did not react directly or consensually to light and was 7 mm in diameter. Funduscopic examination was unremarkable, eye movements were fully intact, and the remainder of her examination was normal. Basic laboratory findings were normal, including: SMA-16, urinalysis, complete blood count, serum magnesium, and calcium levels.

The patient had several episodes of "syncope" and "near syncope" in the hospital. One episode started in the hospital lobby, where she had moved herself in a wheelchair. Other episodes occurred in the hospital bathroom. In the bed, she also had two episodes of unresponsiveness with stable vital signs. No activity resembling an ictal event was seen. Functional unresponsiveness was suspected. She also had some episodes of emesis and headache, as well as epistaxis, urinary incontinence, and one episode of biting her tongue bilaterally near the tip. Shortly after recovery from a "syncopal" attack, her left pupil was noted to be 7 mm in diameter and was unreactive directly or consensually. Eye movements remained fully normal in both eyes. Her gait was unsteady, and the clinical impression was that the gait disorder was a functional one. Neurologic impression was that the pupillary dilatation was secondary to an atropine-like medication. An ophthalmologic evaluation demonstrated visual acuity of 20/20 OD and 20/25 OS (corrected for distant vision with soft contact lenses and near vision of Jaeger 1; both eyes corrected for +2.75 diopters). Both pupils remained fully dilated despite instillation of a 1% pilocarpine solution, which proved that the pupils were dilated by an atropine-like agent.

An electroencephalogram was unremarkable. An electrocardiogram showed normal sinus rhythm with frequent ventricular premature beats. A 24-hour Holter monitor study revealed normal sinus rhythm accompanied by periods of sinus bradycardia (50 bpm) and sinus tachycardia (166 bpm), occasional ventricular premature beats with periods of ventricular bigeminy, and some atrial premature beats. Symptoms did not correlate with the occurrence of arrhythmias.

Hemodynamic studies revealed normal blood volume and cardiac output. Indices of cardiac performance were normal, but moderate peripheral venous pooling was noted when the patient was upright

(Table). Echocardiographic studies were normal, without mitral valve prolapse. Drug and toxicology screening of urine and blood revealed a serum digoxin level of 1.8 ng/mL and the presence of tetrahydrocannabinol, phenothiazines, and salicylates. Subsequently, a search of the patient's hospital room revealed digoxin tablets (0.25 mg), acepromazine (125 mg) (a phenothiazine sedative used in veterinary medicine), and five bottles of a clear, unmarked liquid. However, the identification of atropine-like agents could not be confirmed by laboratory analysis (high-performance liquid chromatography) of the clear liquid. Two of the bottles found during the search were apparently accidentally discarded and were not analyzed.

Physical therapy was instituted to improve the patient's muscle strength in the extremities. A psychiatric evaluation was recommended, but she wished to be discharged.

#### DISCUSSION

Extensive studies have characterized normal circulatory dynamics.<sup>1-5</sup> When a person stands up, as much as 500 mL of blood becomes trapped in the distensible veins below the level of the heart, resulting in a moderate reduction of cardiac output.<sup>5</sup> Compensatory vasoconstrictive mechanisms allow mean arterial blood pressure to be maintained. The sympathetic nervous system is activated by two separate routes: one via the high-pressure baroreceptor reflex, and the other via diminished stretch of sensors in the low-pressure cardiopulmonary receptor area.<sup>6</sup> The renin-angiotensin-aldosterone system is also activated.<sup>7</sup> When these compensatory mechanisms fail to function, orthostatic hypotension occurs, and syncope is the most dramatic manifestation of the phenomenon.

In general, isolated systolic orthostatic hypotension is most likely a non-neurogenic hemodynamic disturbance, whereas combined systolic and diastolic hypotension is associated with significant autonomic neuropathy. Specific and directed evaluation is usually employed to locate the site of the lesion. Our patient did not reveal evidence of autonomic insufficiency. Although her hemodynamic evaluation showed moderate accentuation of peripheral venous pooling upon assumption of upright posture, her episodes of unconsciousness did not represent vasovagal syncope. Indeed, many of her symptoms were atypical of any known syndromes of postural hypotension. Moreover, cardiac arrhythmia did not coincide with the episodes of fainting. Her anisocoria could not be related to any local or generalized neurologic dysfunction, nor could her symptoms be related to the possible systemic toxic effects of anticholinergic agents administered locally in the conjunctival sac.<sup>8</sup> All of these negative findings raised questions regarding the organic nature of her illness.

The morbidity associated with significant orthostatic hypotension can be disabling. The disease must be taken seriously, and all efforts should be made to identify the underlying pathophysiology to determine proper therapy. However, one should not be surprised to encounter some unusual cases in which symptoms and signs cannot be related to organic medical findings. Since dizziness and "fainting" are rather subjective, the physician should carefully strive to objectively document these events. In rare instances, patients may have access to medications and have sufficient medical knowledge to induce physical signs that can be perplexing to the physician. Such circumstances should be kept in mind in the investigation and treatment of syncope.

#### REFERENCES

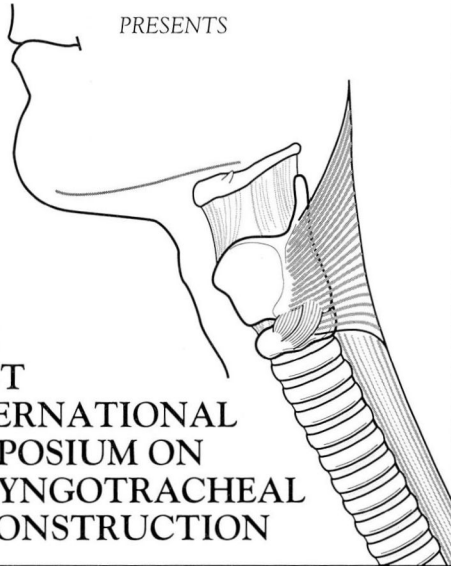
1. Tarazi RC, Fouad FM. Circulatory dynamics in progressive autonomic failure. In: Bannister R, ed. *Autonomic failure: a textbook of clinical disorders of the autonomic nervous system*. London: Oxford University Press, 1983:96-114.
2. Fouad FM, Maloney JD. Orthostatic hypotension: circulatory dynamics and clinical spectrum. In: Furlan AJ, ed. *The heart and stroke*. London: Springer Verlag Limited, 1987:235-248.
3. Fouad-Tarazi F. Cost-effective evaluation of orthostatic hypotension. *Cleve Clin J Med* 1988; 55:499-500.
4. Ibrahim MM, Tarazi RC, Dustan HP, Bravo EL. Idiopathic orthostatic hypotension: circulatory dynamics in chronic autonomic insufficiency. *Am J Cardiol* 1974; 34:288-294.
5. Milstein S, Reyes WJ, Benditt DG. Upright body tilt for evaluation of patients with recurrent, unexplained syncope. *PACE* 1989; 12:117-124.
6. Abboud FM, Eckberg DL, Johannsen UJ, Mark AL. Carotid and cardiopulmonary baroreceptor control of splanchnic and forearm vascular resistance during venous pooling in man. *J Physiol (Lond)* 1979; 286:173-184.
7. Reid JL. Central and peripheral autonomic control mechanisms. In: Bannister R, ed. *Autonomic failure: a textbook of clinical disorders of the autonomic nervous system*. London: Oxford University Press, 1983:173-35.
8. Weiner N. Atropine, scopolamine, and related antimuscarinic drugs. In: Goodman A, Goodman LS, Gilman A, eds. 6th ed. *New York: MacMillan Publishing Co.*, 1985:120-137.





**THE CLEVELAND CLINIC FOUNDATION**

**DEPARTMENT OF OTOLARYNGOLOGY-  
HEAD AND NECK SURGERY  
AND  
COMMUNICATIVE DISORDERS**



**THE  
FIRST  
INTERNATIONAL  
SYMPOSIUM ON  
LARYNGOTRACHEAL  
RECONSTRUCTION**

Stouffer Tower City Plaza Hotel  
August 23-27, 1991

This Symposium will be prepared by staff members of the Department of Otolaryngology and Communicative Disorders at The Cleveland Clinic Foundation together with a very distinguished international and national faculty and invited guests. An overview and tutorial precede the actual symposium in an attempt to cover the etiology, prevalence, pathophysiology and management of laryngotracheal stenosis.

The sessions of invited papers will provide the state of the art assessments of the various challenges that confront those involved in the management of stenotic lesions in the airway. Panel discussions will attempt to provide answers to controversial dilemmas. Free paper sessions and expansive poster sessions will complete the program.

**FOR FURTHER INFORMATION  
REGARDING THIS SYMPOSIUM, CONTACT:**

Department of Continuing Education  
The Cleveland Clinic Foundation  
P.O. Box 94977  
Cleveland, Ohio 44195-5241  
(216)444-5696-local 800-762-8173-other  
(216)445-9406-FAX

THE CLEVELAND CLINIC FOUNDATION

in joint sponsorship with

THE ASPEN MUSIC FESTIVAL AND SCHOOL,  
THE PERFORMING ARTS MEDICINE ASSOCIATION,  
AND  
DANCE ASPEN

*Present*

**THE NINTH ANNUAL SYMPOSIUM**

**ON**

**MEDICAL PROBLEMS OF MUSICIANS & DANCERS**

The Wheeler Opera House  
Aspen, Colorado

**August 1-4, 1991**

This Symposium is directed primarily toward physicians and other health care professionals who are interested in the diagnosis, treatment, and rehabilitation of health problems affecting performing artists. Musicians, dancers and teachers are also encouraged to attend. A special lecture will be presented by one of the foremost names in American dance, Jacques D'Amboise. The Symposium will also include lectures and case presentations on problems of instrumentalists. A master class in voice will be an integral part of this year's effort as well as an instrumental master class. A feature this year will be a joint session with a movement disorders course featuring three of the world's leaders in movement disorders who will join the faculty for a series of presentations on dystonia in musicians. The educational goals of this symposium are to bring together the performing artist, the teacher, and the health care practitioner for discussion and mutual enlightenment. This collaboration is especially critical at this time in the development of performing arts medicine.

For further information and a descriptive brochure,  
please write or call:

The Cleveland Clinic Foundation  
Department of Continuing Education  
P.O. Box 94977

Cleveland, OH 44195-5241

(216) 444-5696 (Local) 800-762-8173 (Other) (216) 445-9406 (FAX)