Aortico-left ventricular tunnel in a neonate

ELIOT R. ROSENKRANZ, MD AND DANIEL J. MURPHY, Jr, MD

■ Aortico-left ventricular tunnel is a rare paravalvular communication between the aorta and the left ventricle resulting in severe aortic regurgitation. It originates most frequently just superior to the right sinus of Valsalva and enters the left ventricle just inferior to the right aortic valve cusp traversing the infundibular or perimembranous ventricular septum. We report our experience with this lesion presenting in a neonate on the first day of life and describe its clinical presentation, noninvasive diagnosis, and surgical management.

□ INDEX TERMS: HEART DEFECTS, CONGENITAL; AORTIC VALVE INSUFFICIENCY; AORTA/ABNORMALITIES □ CLEVE CLIN J MED 1992; 59:87–90

AORTICO-LEFT VENTRICULAR tunnel is a rare paravalvular communication between the aorta and the left ventricle that produces severe aortic regurgitation.[1] This anomaly originates most frequently just superior to the right sinus of Valsalva and enters the left ventricle just inferior to the right aortic valve cusp, traversing the infundibular or perimembranous ventricular septum. Sixty cases of this lesion have been reported in the literature as of 1990, and 9 of these underwent surgical repair as neonates.[2,3] We report our experience with this lesion presenting in a neonate on the first day of life and describe its clinical presentation and our approach to noninvasive diagnosis and surgical management.

CASE REPORT

A 3.107-kg newborn boy was noted to have a loud continuous heart murmur on the first day of life and was referred to The Cleveland Clinic Foundation on the eighth day for evaluation of the murmur and mild tachypnea. The pregnancy was uneventful, and the boy was delivered by cesarean section because of cephalopelvic disproportion. Of note was a family history of congenital disorders, including anencephaly, Down's syndrome, and mental retardation.

On presentation, the patient was a well-developed neonate with tachypnea and subcostal retractions. An active precordial impulse was noted, as was a thrill palpable in the fifth intercostal space in the midclavicular line. A harsh grade 4/6 continuous heart murmur was noted at the left lower sternal border with radiation to the neck. The blood pressure was 75/35 mm Hg, and the peripheral pulses were accentuated and rapidly collapsing. The liver was not enlarged. Electrocardiography showed left ventricular hypertrophy with a strain pattern, and chest roentgenography revealed cardiomegaly. Two-dimensional (2-D) color-flow Doppler echocardiography showed a dilated left ventricle with normal systolic function. The ascending aorta was dilated with a paravalvular diastolic color-flow jet communicating with the left ventricular cavity via an aortico-left ventricular tunnel (*Figure 1*). The aortic valve was displaced posteriorly but did not have demonstrable stenosis or regurgitation (*Figure 2*). The ventricular septum was otherwise intact. The infant was managed medically, but repeat echocardiog-

From the Department of Thoracic and Cardiovascular Surgery and the Department of Pediatric Cardiology, The Cleveland Clinic Foundation.

Address reprint requests to E.R.R., Department of Thoracic and Cardiovascular Surgery, The Cleveland Clinic Foundation, 9500 Euclid Avenue, Cleveland, OH 44195.

Downloaded from www.ccjm.org on April 25, 2024. For personal use only. All other uses require permission.

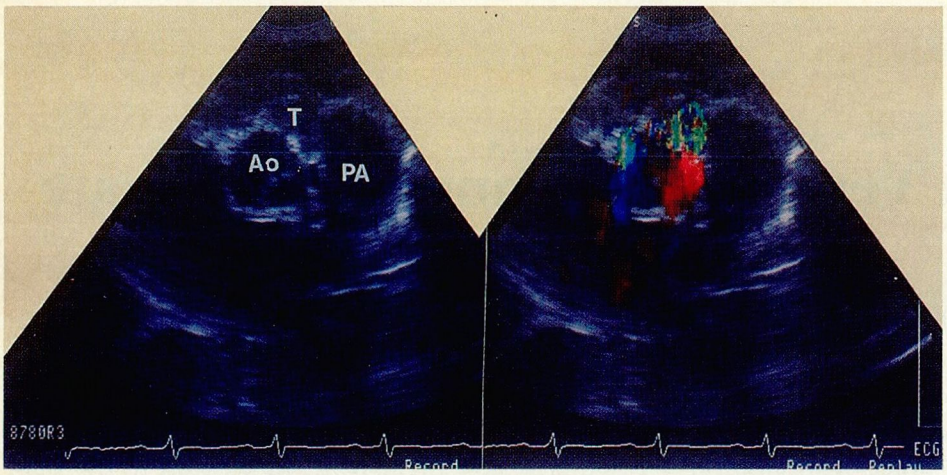

FIGURE 1. Two-dimensional color-flow echocardiography (parasternal short-axis) shows the anteromedial position of the aortico-left ventricular tunnel (T) relative to the ascending aorta (Ao). Turbulent blood flow in the aortico-ventricular tunnel is shown in green. (PA = pulmonary artery)

raphy demonstrated further left ventricular dilatation, and the patient was taken to the operating room on the 15th day of life.

The ascending aorta was markedly enlarged, with a distinct protrusion along the anteromedial wall adjacent to the right ventricular outflow tract. Palpation demonstrated a strong thrill that was obliterated with firm compression. This also resulted in a simultaneous narrowing of the arterial pulse pressure. Cardiopulmonary bypass was established, and the heart was stopped with cold-blood cardioplegia. The aortico-left ventricular tunnel was manually compressed during aortic root cardioplegic infusion to aid in coronary ostial perfusion and to prevent ventricular distension. Inspection of the aorta revealed a normal tri-leaflet aortic valve with a 5- × 7-mm defect superior to the commissure between the left and right sinuses of Valsalva. The coronary ostia were normal. The aortic end of the tunnel was closed with a glutaraldehyde-fixed patch of autologous pericardium sewn in place with continuous 7-0 nonabsorbable polypropylene suture. After weaning the patient from cardiopulmonary bypass, intraoperative 2-D color-flow echocardiography revealed no residual aortic regurgitation or stenosis. Postoperative recovery was uneventful, and the patient was dismissed from the hospital on the eighth postoperative day. At 10 months after surgery, the child remains asymptomatic without medications. Repeat echocardiography at 10 months revealed a normal left ventricular end-diastolic dimension of 25 mm (normal, 19 to 26 mm) and a normal left ventricular shortening fraction of 28%. Color-flow echocardiography at 10 months after surgery (*Figure 3*) showed no residual flow through the tunnel and normal aortic valve function.

DISCUSSION

Aortico-left ventricular tunnel is one of the rarest congenital cardiac lesions, estimated to account for approximately 0.1% of heart lesions in large series.[4] Our case represents the 61st reported in the literature and the 10th reported repair in a neonate. The original description of the lesion by Levy in 1963[1] was a tract originating in the ascending aorta and traversing the visceral pericardium to penetrate the ventricular septum. The tunnel then terminated in the left ventricle inferior to the aortic root. The etiology of this lesion is unknown. Theories have included a maldevelopment of a coronary artery,[1] malformation of the distal bulbus cordis at its junction with the truncus,[5] a Marfan's-like aortic dissection,[6] and a pre- or post-natal rupture of a sinus of Valsalva aneurysm.[7]

Anatomically, most reports have described the tunnel as originating from the aorta just above the right sinus of Valsalva, passing anteriorly and superiorly to the right coronary artery and entering the left ventricle just inferior to the right cusp of the aortic valve. However, several cases of aortico-left ventricular tunnel originating from the left sinus of Valsalva have also been reported. Although most often reported as an isolated lesion, it has also been seen in association with valvular pulmonic stenosis, right ventricular outflow tract obstruction secondary to a sinus of Valsalva aneurysm, valvular aortic stenosis, or atresia and ventricular septal defect.[1,7-9] The lesion is most often recognized clinically as a loud continuous murmur often present in the neonatal period. It is usually associated with left ventricular dilatation and congestive heart failure. Although aortico-left ventricular tunnel is a common cause for aortic insufficiency in newborns, the differential diagnosis of a continuous murmur at this age

Downloaded from www.ccjm.org on April 25, 2024. For personal use only. All other uses require permission.

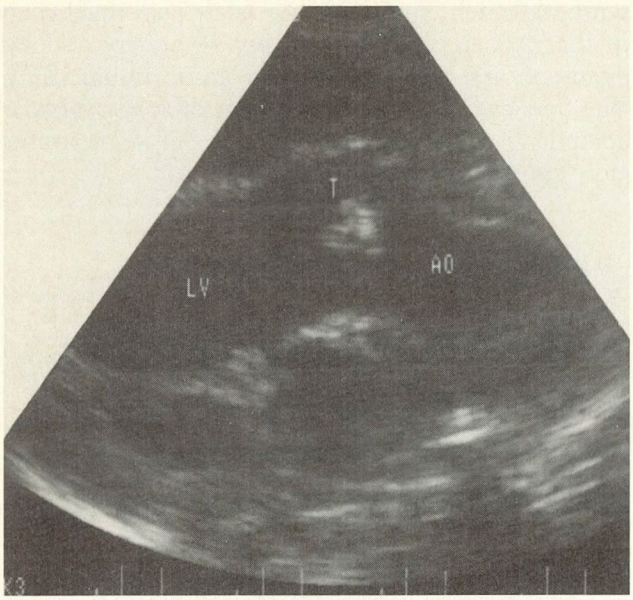

FIGURE 2. Two-dimensional echocardiography (parasternal long-axis view) demonstrates the aortico-ventricular tunnel (T) communicating between the aorta (Ao) and the left ventricular chamber (LV), separate from the posteriorly displaced aortic valve and aortic annulus.

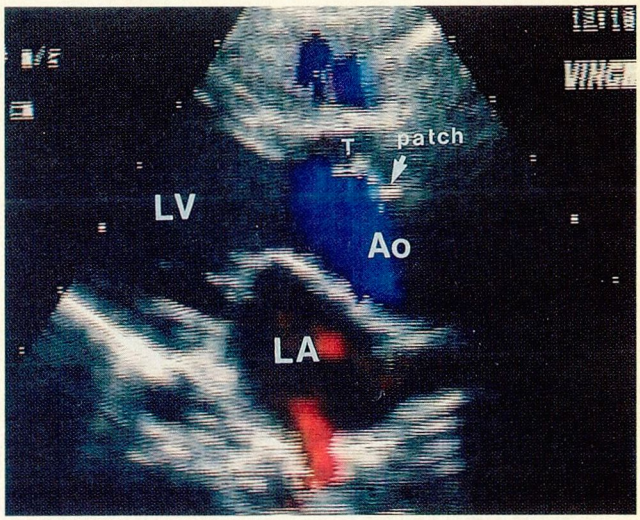

FIGURE 3. Two-dimensional color-flow echocardiography (parasternal long-axis view) at 10 months after surgical repair shows no residual flow through the tunnel (T) and no flow disturbance or regurgitation at the aortic valve (Ao).

also includes patent ductus arteriosus, aorto-pulmonary window, truncus arteriosus, ruptured sinus of Valsalva aneurysm, aortic insufficiency with ventricular septal defect or aortic stenosis, coronary arterial venous fistula, and tetralogy of Fallot with absent pulmonary valve. The diagnosis has traditionally been confirmed angiographically; however, 2-D color-flow echocardiography can confirm the lesion noninvasively,[10,11] as in this case. The demonstration of septal drop-out beneath the aortic valve along with the paravalvular tunnel structure adjacent to the ascending aorta on 2-D echocardiography describes the anatomy (*Figure 1*), and the presence of a color-flow diastolic jet in the tunnel helps distinguish aortico-ventricular tunnel from valvular aortic insufficiency (*Figure 2*). Magnetic resonance imaging (MRI) has also been used to diagnose the lesion and may provide an even better reconstruction of the relationships of the aortico-left ventricular tunnel to other intracardiac structures.[11]

Once the diagnosis has been made, prompt surgical repair is advised because of the uniform mortality in patients who do not undergo surgical repair, and because of the frequent development of valvular aortic insufficiency secondary to aortic annular dilatation. The methods of surgical repair have included direct suture closure of the aortic orifice which has been associated with early and late development of valvular aortic insufficiency,[12,13] frequently necessitating reoperation for aortic valve replacement. This is due to distortion of the aortic valve cusps by anatomically incorrect approximation of the tunnel orifice edges against the aortic wall. This results in central aortic incompetence and regurgitation. Bjork[14] suggested polyester (Dacron) patch closure of the aortic end of the tunnel orifice to stabilize the coronary cusps. This technique, or patch closure of both the aortic and ventricular ends of the tunnel, appears to have better early and late results, both by preventing aortic valvular insufficiency and by reducing perioperative mortality.[13]

Of the 60 previously reported cases of aortico-left ventricular tunnel, 52 underwent surgery, with a 21% perioperative mortality. Two thirds of these perioperative deaths occurred in patients who were under age 2. Of 9 patients undergoing repair as neonates, 2 died during the perioperative period. Long-term follow-up is limited but suggests progressive development of valvular aortic insufficiency, especially in patients who underwent primary tunnel closure without use of a prosthetic patch.[12]

SUMMARY

Aortico-left ventricular tunnel represents a rare congenital lesion of the aortic root, presenting clini-

Downloaded from www.ccjm.org on April 25, 2024. For personal use only. All other uses require permission.

cally in the neonatal patient as severe aortic insufficiency. It can be accurately diagnosed noninvasively by 2-D color-flow Doppler echocardiography or MRI, which may eliminate the need for cardiac catheterization unless other cardiac lesions are also present. Prompt surgical repair by single or double pericardial or synthetic patch closure may be safely performed even in the neonate and may prevent secondary annular dilatation and resultant valvular aortic insufficiency. The frequency of late development of aortic valvular complications is unknown and, therefore, warrants close clinical follow-up of these patients.

REFERENCES

1. Levy MJ, Lillehei CW, Anderson RC, Amplatz K, Edwards JE. Aortico-left ventricular tunnel. Circulation 1963; **27:**841–853.
2. Duveau D, Baron O, Michaud JL, Lefevre M, Laboux L, Dupon H. Aortico-left ventricular tunnel. Long-term follow-up, therapeutic implications. Arch Mal Coeur 1989; **82:**785–789.
3. Moron A, Maitre-Azcarate MJ, Rico-Gomez F, Brito-Perez JM, Quero-Jimenez M. Aortico-left ventricular tunnel. Presentation of two new cases. Usefulness of noninvasive study. Rev Esp Cardiol 1990; **43:**114–118.
4. Okoroma EO, Perry LW, Scott LP, McClenathan JE. Aortico-left ventricular tunnel. Clinical profile, diagnostic features, and surgical considerations. J Thorac Cardiovasc Surg 1976; **71:**238–244.
5. Sommerville J, English T, Ross DN. Aortico-left ventricular tunnel. Clinical features and surgical management. Br Heart J 1974; **36:**321–328.
6. Cooley RN, Harris LC, Rodin AE. Abnormal communication between the aorta and left ventricle. Aortico-left ventricular tunnel. Circulation 1965; **31:**564–568.
7. Turley K, Silverman NH, Teitel D, Mavroudis C, Snider R, Rudolph A. Repair of aortico-left ventricular tunnel in the neonate: surgical, anatomic, and echocardiographic considerations. Circulation 1982; **65:**1015–1020.
8. Levy MJ, Schachner A, Blieden LC. Aortico-left ventricular tunnel. Collective review. J Thorac Cardiovasc Surg 1982; **84:**102–109.
9. Llorens R, Arcas A, Herreros J. Aortico-left ventricular tunnel: a case report and review of the literature. Tex Heart Inst J 1982; **9:**169–173.
10. Fripp RR, Werner JC, Whitman V, Nordenberg A, Waldhausen JA. Pulsed Doppler and two-dimensional echocardiographic findings in aortico-left ventricular tunnel. J Am Coll Cardiol 1984; **4:**1012–1014.
11. Humes RA, Hagler DJ, Julsrud PR, Levy JM, Feldt RH, Schaff HV. Aortico-left ventricular tunnel: diagnosis based on two-dimensional echocardiography, color-flow Doppler imaging, and magnetic resonance imaging. Mayo Clin Proc 1986; **61:**901–907.
12. Serino W, Andrade JL, Ross D, deLeval M, Sommerville J. Aortico-left ventricular communication after closure. Late postoperative problems. Br Heart J 1983; **49:**501–506.
13. Hovaguimian H, Cobanoglu A, Starr A. Aortico-left ventricular tunnel: a clinical review and new surgical classification. Ann Thorac Surg 1988; **45:**106–112.
14. Bjork VO, Eklof O, Wallgren G, Zetterguist P. Successful surgical treatment of an aortico-left ventricular tunnel in a 4-month-old infant. J Thorac Cardiovasc Surg 1979; **78:**35–38

Downloaded from www.ccjm.org on April 25, 2024. For personal use only. All other uses require permission.