

# The phenomenal growth of laparoscopic cholecystectomy: a review

RAPHAEL S. CHUNG, MD, AND THOMAS A. BROUGHAN, MD,

■ The widespread use of laparoscopic cholecystectomy 2 years after its introduction suggests that the procedure is a viable therapeutic option for uncomplicated gallstone disease. Early results seem to support a shorter convalescence for this procedure compared to open cholecystectomy. However, the actual complication rate is unknown. The outcome appears to be highly dependent on the skill and experience of the surgeon. How this operation is ranked against the classical cholecystectomy remains to be assessed.

□ INDEX TERMS: CHOLECYSTECTOMY; GALLBLADDER DISEASES; CHOLELITHIASIS; PERITONEOSCOPY; PATIENT PARTICIPATION  
□ CLEVE CLIN J MED 1992; 59:186-190

Since the historic first case performed by Dr. Phillip Mouret in Lyons, France in 1987,<sup>1</sup> laparoscopic cholecystectomy has taken the United States by storm. Assuming conservatively that 2% to 5% of all cholecystectomies in 1990 were performed with this new technique, then between 10,000 and 25,000 laparoscopic cholecystectomies may have been performed that year. Before any controlled study could be undertaken, the operation was touted by surgeons who perform it, demanded by a public attracted by claims of reduced pain and fast recovery, and promoted by entrepreneurial instrument manufacturers for enhanced sales. Amidst the claims and counter-claims, what is the patient's advocate to do? In this review, the authors examine the evolutionary development of the operation and the technical issues that make the operation unique. An attempt is

made to put into perspective the rational use of the operation in the light of available information.

## BACKGROUND

Laparoscopic cholecystectomy is an example of therapeutic endoscopy: surgery by remote control through minimal access. Although the operation is just a little over 2 years old, the procedure is a product of evolutionary developments over many decades. Kelling was credited with the first successful inspection of the abdominal cavity with a cystoscope in 1901 in the dog,<sup>2</sup> and Jacobaeus published substantial clinical experience in 1911.<sup>3</sup> Kalb improved on the instruments and techniques and utilized laparoscopy extensively in studying diseases of the liver.<sup>4</sup> In the United States, the procedure was introduced by Ruddock, who reported on his series of over 500 cases between 1934 and 1937.<sup>5</sup> Even so, over the years, laparoscopy has received much less attention by surgeons in the United States than it has in France and Germany. Only in gynecology have great strides been made in the past decades by utilizing the technique in the diagnosis and treatment of pelvic disease.

From the Department of General Surgery, The Cleveland Clinic Foundation.

Address reprint requests to R.S.C., Department of General Surgery, The Cleveland Clinic Foundation, 9500 Euclid Avenue, Cleveland, OH 44195.

The modern laparoscope (based on the Hopkins rod-lens principle) was introduced in 1952,<sup>6</sup> but few general surgeons were aware of its utility. With improved resolution, simple procedures were first developed, mostly in the field of gynecology. Semm, a gynecologist, first performed appendectomy via the laparoscope in 1982.<sup>7</sup> With the use of videoendoscopy, precise coordination of surgeon and assistants became possible and more complicated procedures could be undertaken. The first laparoscopic cholecystectomy was performed by the French surgeon Mouret in 1987 but was not reported.<sup>1</sup> Within 2 years Dubois,<sup>8</sup> Perissat,<sup>9</sup> Reddick<sup>10</sup> and others<sup>11-13</sup> have reported their substantial experience with this procedure resulting in no mortality and low morbidity.

The rapid spread of laparoscopic cholecystectomy in this country is primarily driven by patients' demand. As viewed by the lay public, the laparoscopic procedure is less invasive than open cholecystectomy and promises rapid convalescence. Other factors at work include an entrepreneurial instrument industry whose interest in sales led to the proliferation of training courses for surgeons, and the surgeons themselves who were under pressure to learn and perform the new procedure so as not to lose patients to the competition.

Much of the popular appeal of laparoscopic cholecystectomy may be founded on the notion that a major incision is avoided. However, despite the markedly reduced size of incisions, the intra-abdominal component of laparoscopic cholecystectomy is identical to the conventional operation. Since the major postoperative symptom in cholecystectomy is incisional pain, the laparoscopic operation may result in less postoperative pain due to shorter incision length. A shorter convalescence may therefore be feasible, but this has not been confirmed by prospective data. The scars from the laparoscopic operation are allegedly more cosmetically acceptable, but this is largely a subjective issue, since four short incisions may be as objectionable to one patient as a single long incision is to another.

The patient must be informed that the trade-off for minimal access is that the operation takes about twice as long to perform and is technically more demanding, the results are more operator-dependent, and more things can go wrong. The published results do not represent the real risks since the number of reported cases is still small, and the skill of the surgeon weighs heavily in the outcome, much more so than the standard surgical operation.

**TABLE**  
CONTRAINDICATIONS FOR LAPAROSCOPIC  
CHOLECYSTECTOMY

---

|   |
|---|
| Previous upper abdominal operations   |
| Acute cholecystitis, empyema, mucocele  |
| Cholangitis with gross abnormality of the common bile duct  |
| Concomitant surgical pathology of the abdomen requiring operative treatment                                 |
| Morbid obesity  |
| Cirrhosis with evidence of portal hypertension  |
| Massive ascites   |
| Uncertain diagnosis: suspicion of malignancy  |
| Poor surgical risk: recent myocardial infarction, congestive heart failure, respiratory insufficiency, etc. |
| Pregnancy   |
| Asymptomatic gallstones   |

---



---

#### PATIENT SELECTION

---

Although endoscopy may provide good visibility, both manipulation and the number of instruments that can be used in the operative field are limited. Therefore, operations are safe only under conditions of good exposure (absence of adhesions or bleeding) and where prolonged anesthesia is allowable, namely, in low-risk or healthy patients.

The commonly accepted contraindications for laparoscopic cholecystectomy are listed in the *Table*. Most contraindications are probably relative, depending on the skill and experience of the surgeon. The patients deemed suitable for this technique should be free from previous upper abdominal operations or dense adhesions to the gallbladder due to repeated bouts of inflammation. Abnormal coagulation, increased vascularity from acute cholecystitis, and portal hypertension are known contraindications. Morbid obesity and the presence of marked ascites render the procedure difficult, if not impossible. Pregnancy, even during the mid-trimester, should be considered a contraindication simply because no safety data are available. Even though a few surgeons are performing the procedure for acute cholecystitis, the safety issue will require much more experience for assessment.

---

#### SURGEON QUALIFICATIONS

---

With the pressure to offer a new technique, many surgeons are rushing to learn laparoscopic cholecystectomy, which, unlike most new surgical operations, demands a new set of skills. In all published series,

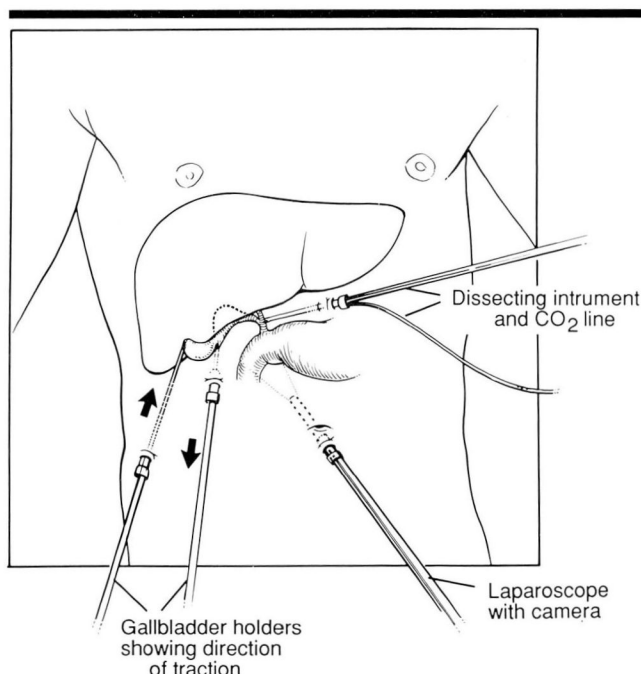


FIGURE 1. The position of the four trocars with instruments inserted for laparoscopic cholecystectomy.

complication rates are significantly higher in the beginning of the series.<sup>8-10,13</sup> Also, early in any given surgeon's experience, the operation takes longer<sup>13</sup> and is attended by a greater frequency of conversion to open cholecystectomy. This is the basis for the oft-quoted "steep learning curve" associated with the new operation.

The surgeon offering this operation should be well versed in conventional biliary surgery, therapeutic endoscopy (operations by remote control), and the use of the laparoscope. Surgeons accustomed to total control of the operating field under stereoscopic vision may feel handicapped by the monocular exposure via the laparoscope, but adaptation to this limitation of the procedure is rapid.

Training in laparoscopic cholecystectomy may begin with laboratory work, commonly using the swine as a model, or assistance at actual operations, graduating to performance under a preceptor. The amount of training required varies with the ability and the background of the trainee, and no accepted guideline exists at present.

Another important qualification, even more difficult to quantify, is the exercise of sound surgical judgment. Low morbidity depends not only on technique but on knowing when it is unsafe to persist with laparo-

scopic cholecystectomy. There is no justification to risk complications when the alternative operation has such a superior proven record.

#### SURGICAL TECHNIQUE

After induction of pneumoperitoneum, a 10-mm trocar is inserted into the peritoneal cavity at the umbilicus, through which the laparoscope and its attached camera are inserted. The table is tilted 30 degrees head-up to allow the transverse colon to move downwards, and two graspers are introduced via separate subcostal punctures (using smaller trocars) for traction on the gallbladder (*Figure 1*). A dissector (laser light guide, hook, electrocautery blade, scissors, or dissecting forceps) is inserted via a fourth cannula (11 mm) in the epigastric area.

The operation begins with careful identification of the anatomy. The cystic duct and artery are isolated using the dissector while traction is maintained on the gallbladder. If a cholangiogram is desired, the cystic duct is cannulated via one of the subcostal ports and secured with a clip or clamp. Contrast is then injected and operative cholangiograms are obtained in a manner similar to the conventional method. The cystic duct and cystic artery are ligated with clips. After severing these structures, the gallbladder is dissected from the liver by any of a number of instruments, including scissors, electrocautery, laser, or a combination.

Removal of the collapsed gallbladder from the peritoneal cavity is possible via the umbilical or epigastric dissection ports. Some surgeons routinely empty the gallbladder by aspiration before beginning dissection, but the bile and small stones may also be aspirated at the end of the dissection. If large stones are present, they may be crushed by inserting instruments inside the gallbladder, and then aspirated (*Figure 2*). If necessary, the epigastric or umbilical incision may also be enlarged to get the gallbladder out. If desired, a drain may be placed in the subhepatic space via one of the lateral ports for evacuation of minor bile leakage.

Postanesthesia recovery and immediate postoperative discomfort do not differ from the standard operation. Nausea, ileus, and abdominal pain are not eliminated, although the symptoms seem to resolve faster. Many patients are discharged after an overnight stay, but there must be flexibility depending on the potential for complications. Some surgeons have even proposed performing the procedure routinely in an outpatient setting, but the safety of this has yet to be studied.



## COMPLICATIONS

A number of complications from laparoscopic cholecystectomy have been reported, including bile leakage, accidental ligation of the right hepatic artery, hemorrhage, loss of stones, and wound complications. If a drain has been placed, bile leakage manifests as sustained bilious drainage, usually about 300 mL/day. A few (3% to 5%) patients return days after discharge with fever and evidence of a subhepatic fluid collection on CT scan. Following CT-guided drainage, persistent bile fistula may result. In many instances, this complication can be traced to inaccurate dissection of the gallbladder from the liver with open hepatic bile ductules requiring days or weeks to seal.

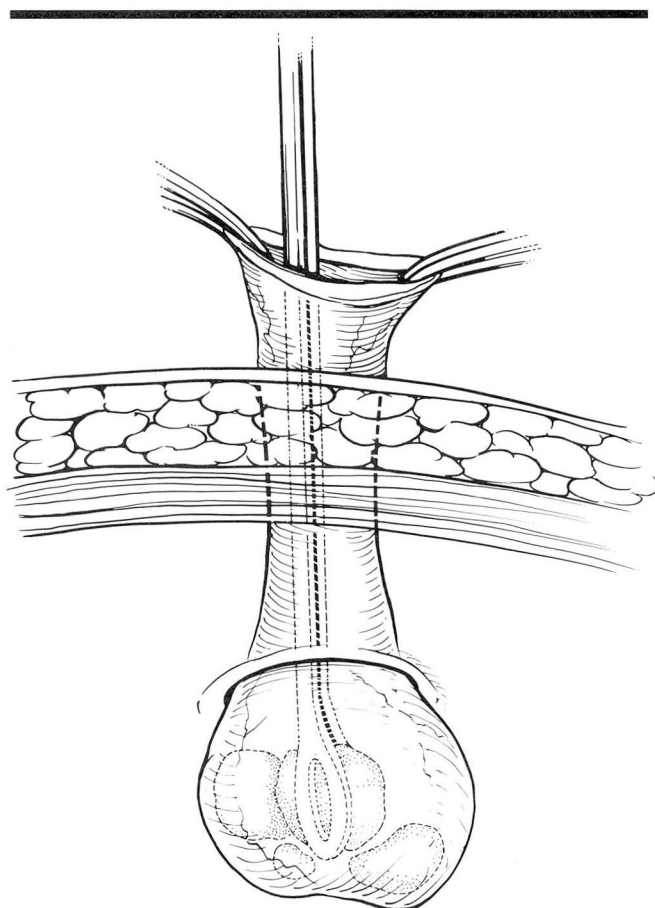
Insecure ligation of the cystic duct may result in bile peritonitis or major leak of bile into the abdomen. If this is not recognized at operation, endoscopic retrograde cholangiopancreatography will delineate the location of leakage. Internal endoscopic stenting by nasobiliary drain may promote closure, but some patients may require operative repair.

Common bile duct injury is potentially the most significant complication of the laparoscopic approach. It is possible to mistakenly ligate the common bile duct or the right hepatic duct in its bowed position due to traction on the gallbladder. Operative correction is mandatory. In one series, the incidence of this complication was 1%.<sup>14</sup>

Accidental ligation of the right hepatic artery is also possible. If the cystic artery is short, the right hepatic artery may be mistaken for it. In a healthy patient, no symptoms may develop, due to the dual circulation of the liver and the rapid development of collaterals. However, infarction of the liver has occurred (unpublished report).

Early hemorrhage may come from insecure ligation of the cystic artery or from the liver during dissection. In patients with portal hypertension, venous oozing may be troublesome due to high venous pressure. Delayed bleeding is often venous in nature. While hemostasis may appear adequate when pneumoperitoneum is maintained at 12 to 16 mm Hg, venous oozing may recur after the pressure is removed.

Stones and fragments may be lost into the peritoneal cavity if the gallbladder is not removed intact. In a gallbladder containing numerous small stones, loss of stones into the peritoneal cavity may follow inadvertent puncture of the gallbladder. Retrieval by laparoscopy may not be complete. The incidence of remote sequelae such as abscess and ad-



**FIGURE 2.** Part of the gallbladder is delivered into the trocar incision. A large stone is crushed to facilitate removal of the gallbladder through the incision.

hesions is unknown, although no adverse immediate effects have been observed.

As in any surgical procedure, wound complications may occur. Hematoma and infection can develop in the puncture wounds, particularly where infected material (stones, gallbladder) have contaminated them. Herniation at puncture sites has been reported.

Rare complications due to laparoscopy may also occur, such as air embolism and injuries of the bowel or the iliac artery or vein.

## RESULTS

In small series, no procedure-related mortality has been published so far. Isolated verbal accounts of deaths have circulated in surgical circles; however, as there is no centralized reporting system, it is impossible

to estimate the true mortality rate.

Total complications are less than 10% in all published reports,<sup>8-13</sup> but this figure reflects experience of surgeons who had done a large number of such operations. Classical cholecystectomy has a complication rate of <5%, but the difference in morbidity between the two procedures may decrease in the near future as surgeons gain experience with the laparoscopic procedure. One complication, bile duct injury, has already received editorial attention.<sup>14</sup> Bile duct injury during laparoscopic cholecystectomy occurs about 10 times more frequently (1%) than with the classical operation.

In one series, the operating time averaged 130 minutes in the beginning of the experience, but only 75 minutes after 50 cases.<sup>13</sup> Most uncomplicated open cholecystectomies can be accomplished in 45 minutes. Conversion to conventional operation due to unforeseen circumstances was not counted as a complication, and occurred mostly early in the series.<sup>8,9</sup>

Time of convalescence or time until return to full activity averaged 12.8 days in one report of 100 patients.<sup>13</sup> Early return to work is touted as a major virtue of this operation, and many other reports state this in terms of the number of days. Considering that this depends heavily on the patient's motivation and occupation, as well as preoperative psychological conditioning, such figures are always suspect. For many patients, the return to full work is hard to define.

#### CURRENT AND FUTURE ROLES

At many institutions, 80% of all cholecystectomies are now laparoscopic.<sup>14</sup> Even without controlled trials,

the number of procedures performed successfully nationally have clearly established the efficacy of the operation. The actual incidence of complications remains to be shown, and how the overall mortality and morbidity will compare with that for the classical operation remains to be seen.

In treating recurrent gallstone colic, laparoscopic cholecystectomy is clinically more effective than extracorporeal lithotripsy, but it is suitable only for patients who can withstand an open operation, should exigency so demand. Laparoscopic cholecystectomy may be extended to patients with choledocholithiasis when combined with endoscopic sphincterotomy and stone extraction. Particularly in centers with extensive experience, an endoscopic sphincterotomy with stone retrieval is more attractive than surgical exploration of the common bile duct, since an indwelling T-tube for several weeks is required following surgical exploration.

Operative choledochoscopy via laparoscopy is presently in the developmental stages.

In the light of available data, it is reasonable to recommend laparoscopic cholecystectomy for symptomatic patients without obvious contraindications, as long as it is performed by surgeons experienced in conventional biliary surgery and laparoscopic and/or endoscopic procedures.

Although the spectacular rise of laparoscopic cholecystectomy may be some indication of its efficacy, the current lack of controlled studies and accurate morbidity and mortality data are obstacles that may lead to abuse and may retard the future development of other laparoscopic procedures.

#### REFERENCES

- Cuschieri A, Berci G, ed. Introduction [In] *Laparoscopic Biliary Surgery*. Boston. Blackwell Scientific Publications. 1990; p8.
- Kelling G. Über die besichtigung der speiserohre und des magens mit biegsamen instrumenten. *Verhandlungen der Gesellschaft Deutscher Naturforscher Ärzte* 1902; 73:117.
- Jacobeus HC. Kurze Übersicht über meine erfahrungen mit der laparoskopie. *Munch Med Wochenschr* 1911; 58:2017.
- Kalk H. Erfahrung mit der laparoskopie (zugleich mit beschreibung eines neuen instrumentes) *Z Klin Med* 1929; 111:303-48.
- Ruddock JC. Peritoneoscopy. *Surg Gynecol Obstet* 1937; 65:623-7.
- Berci G, Morgenstern L, Panish JF, et al. The evaluation of a new peritoneoscope as a diagnostic aid to the surgeon. *Ann Surg* 1973; 178:37.
- Semm K. Endoscopic appendectomy. *Endoscopy* 1983; 15:59.
- Dubois F, Icard P, Berthelot G, et al. Coelioscopic cholecystectomy: preliminary report of 36 cases. *Ann Surg* 1990; 211:60.
- Perissat J, Collet D, Belliard R. Gallstones: laparoscopic treatment—cholecystectomy, cholecystostomy, and lithotripsy. *Surg Endosc* 1990; 4:1.
- Reddick E, Olsen D. Laparoscopic laser cholecystectomy: a comparison with minilap cholecystectomy. *Surg Endosc* 1989; 3:131.
- Buess G, Mentges B, Melzer A, et al. Laparoscopic microsurgical cholecystectomy in gallstone disease. *Surg Endosc* 1990; 4:55,32A.
- Ko ST, Airan MC. Technique and early experience of laparoscopic cholecystectomy and cholangiogram. *Surg Endosc* 1990; 4:58-59,49A.
- Peters J, Ellison EC, Innes JT, et al. Safety and efficacy of laparoscopic cholecystectomy: a prospective analysis of 100 initial patients. *Ann Surg* 1991; 213:3-12.
- Cameron JL, Gadacz TR. Laparoscopic cholecystectomy. *Ann Surg*