

Doppler echocardiographic assessment of aortic regurgitation: uses and limitations

ALLAN L. KLEIN, MD; MALCOLM B. DAVISON, MBBS; GALEN VONK, MD; A. JAMIL TAJIK, MD

■ Completely satisfactory standards for assessing the severity of aortic regurgitation have not yet been formulated. Invasive and noninvasive methodologies have inherent limitations that prevent any single procedure being considered as a gold standard. Nevertheless, Doppler echocardiography, using the full range of imaging modalities, including pulsed-wave and continuous-wave Doppler and Doppler color-flow mapping, may detect and semiquantify the severity of aortic regurgitation with a high degree of accuracy. This article describes the application, methodology, and limitations of the Doppler indices currently used to assess aortic regurgitation.

□ INDEX TERMS: ECHOCARDIOGRAPHY, DOPPLER; AORTIC VALVE INSUFFICIENCY □ CLEVE CLIN J MED 1992; 59:359-368

QUANTITATIVE assessment of the severity of aortic regurgitation—a turbulent, high-velocity flow disturbance in the left ventricular outflow tract (LVOT)—remains an important clinical challenge, a fact highlighted by the lack of a satisfactory “gold standard.”^{1,2}

Invasive assessment techniques include either qualitative (1+ to 4+) grading of regurgitation made at the time of aortic root angiography or quantitative calculation of the regurgitant fraction (using left ventriculography and Fick cardiac output).^{3,4} Unfortunately, the invasive nature of these techniques makes serial evaluations difficult, and accuracy may be adversely affected by technical factors such as catheter position and premature ventricular contractions.

From the Department of Cardiology, Division of Medicine, The Cleveland Clinic Foundation, and the Division of Cardiovascular Diseases and Internal Medicine, Mayo Clinic and Mayo Foundation, Rochester, Minnesota.

Address reprint requests to A.L.K., The Cleveland Clinic Foundation, Department of Cardiology, F15, 9500 Euclid Avenue, Cleveland, OH 44195-5064.

Among noninvasive methodologies, radionuclide angiography is limited by its use of ionizing radiation and by technical factors such as the overlap of cardiac structures.^{5,6} M-mode and two-dimensional echocardiography provide useful assessments of left ventricular size and function and can also define the mechanism of the aortic regurgitation; however, these techniques permit only indirect assessment of the severity of aortic regurgitation.⁷ Pulsed-wave and continuous-wave Doppler echocardiography complement M-mode and two-dimensional echocardiography by providing data on direction and velocity of blood flow.⁸

In recent years, several new and exciting Doppler echocardiographic techniques have been developed that permit semiquantitation of aortic regurgitation. These include Doppler color-flow mapping,⁹⁻¹⁴ calculation of the continuous-wave pressure half-time index,¹⁵⁻²⁰ detection of reverse diastolic flow in the descending aorta,²¹⁻²⁶ and calculation of regurgitant volumetric flow.^{4,27,28} The overall sensitivity and specificity of Doppler echocardiography in the detection of aortic regurgitation is between 90% and 100%,

TABLE
DOPPLER ECHOCARDIOGRAPHIC ASSESSMENT OF
AORTIC REGURGITATION

Qualitative	Regurgitant velocity waveform intensity and wave form.
Semiquantitative	Pulsed-wave Doppler mapping Color flow imaging Continuous-wave Doppler pressure half-time index Flow reversal in thoracic and descending aorta Left ventricular inflow indices
Quantitative	Regurgitant fraction
Newer methods	Transesophageal echocardiography Hydrodynamic properties (momentum)

and the technique is now considered by some to be a new standard in the diagnosis of aortic regurgitation.^{10,14} In this article, we describe the value and limitations of Doppler echocardiography in the assessment of aortic regurgitation.

QUALITATIVE DOPPLER ASSESSMENT

Qualitatively, there are certain important features of the aortic regurgitation Doppler profile. The typical "square-wave" pattern of aortic regurgitation can be detected using pulsed-wave Doppler, with the sample volume beneath the aortic valve. Features that indicate aortic regurgitation include diastolic flow commencing from aortic valve closure and high-velocity flow resulting from the high gradient between aortic diastolic and left ventricular diastolic pressures. The intensity of the spectral signal is directly proportional to the severity of regurgitation. Increased systolic forward flow is observed as the severity of aortic regurgitation increases, and the spectral envelope shape demonstrates a shorter pressure half-time due to an earlier rise in left ventricular diastolic pressure.²⁹

SEMIQUANTITATIVE DOPPLER ASSESSMENT

Several Doppler echocardiographic techniques can semiquantitatively assess aortic regurgitation. These include pulsed-wave Doppler mapping, Doppler color-flow mapping, calculation of the pressure half-time index, analysis of left ventricular diastolic inflow patterns, and identification of flow reversal in the descending thoracic and abdominal aortas (Table).

Pulsed-wave Doppler mapping

In 1982, Ciobanu et al assessed aortic regurgitation semiquantitatively by determining the longitudinal ex-

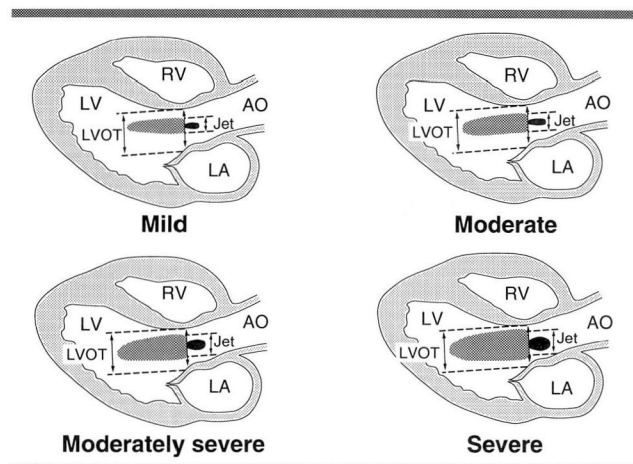


FIGURE 1. Aortic regurgitation (parasternal long-axis view) is graded by comparing the height of the aortic regurgitant jet (Jet) to the height of the left ventricular outflow tract (LVOT) in mild, moderate, moderately severe, and severe aortic regurgitation. AO indicates the aorta; LA, left atrium; LV, left ventricle; RV, right ventricle.

tent of the diastolic flow disturbance within the LVOT and the left ventricle. Using pulsed-wave Doppler in the parasternal long-axis view, they devised a 1+ to 3+ (mild to severe) grading system which correlated significantly with aortic root cine-angiography.³⁰

Current mapping techniques use the apical five-chamber and apical long-axis views. The sample volume is placed at the level of the LVOT and is moved progressively into the body of the left ventricle, mapping the area of flow disturbance. The degree of aortic regurgitation is determined when the regurgitant jet is detected. Regurgitation is rated as trivial if seen below the aortic valve, mild if in the LVOT, moderate if at the mitral valve leaflet tips, or severe if in the body of the left ventricle.^{4,14,29}

When using aortic root angiography as the comparative gold standard, pulsed-wave Doppler has a sensitivity of 95%, a specificity of 96%, a positive predictive value of 99%, and a negative predictive value of 89%.¹³ The high sensitivity of this technique is evident in its ability to detect aortic regurgitation in the 25% of cases which are clinically silent.³¹

Pulsed-wave Doppler mapping has several limitations, however. Aortic regurgitation may be obscured by coexistent diastolic flow disturbances related to mitral stenosis or mitral valve prostheses. Eccentric regurgitant jets directed towards the anterior mitral leaflet or ventricular septum are difficult to interrogate,

which can lead to underestimation of the severity of aortic regurgitation. On the other hand, high systemic afterload may lead to overestimation of the severity, as the jet will appear to extend further into the left ventricle. Pulsed-wave Doppler may also detect flow in an adjacent chamber, since the sample volume is three-dimensional, whereas the guiding echocardiogram is two-dimensional.^{11,13,14}

Color-flow mapping

Doppler color-flow mapping is a recently developed technique that uses simultaneous pulsed-wave Doppler sampling of an array of multiple points in a given plane. The various flow velocities are encoded as different colors, providing a rapid and precise two-dimensional map of physiologic and pathologic flow velocities (Figures 1–3).^{9–14} Multiple orthogonal views, including the parasternal long- and short-axis and apical five-chamber views, are necessary to define the three-dimensional distribution of the regurgitant jet.

The regurgitant orifice itself can be defined in cross section. Eccentric jets, which are difficult to assess with pulsed-wave Doppler mapping, are more readily assessed with Doppler color-flow mapping. Coexistent mitral valve stenosis or mitral valve prosthesis poses fewer problems with color-flow mapping than with pulsed-wave Doppler, since antegrade mitral and regurgitant aortic flow can be visually distinguished.¹²

Initial studies detected a good correlation between angiographic grading and Doppler color-flow imaging when the maximal length of the regurgitant jet was assessed.⁹ More recently, the width of the jet and the cross-sectional area of the jet, relative to the area of the

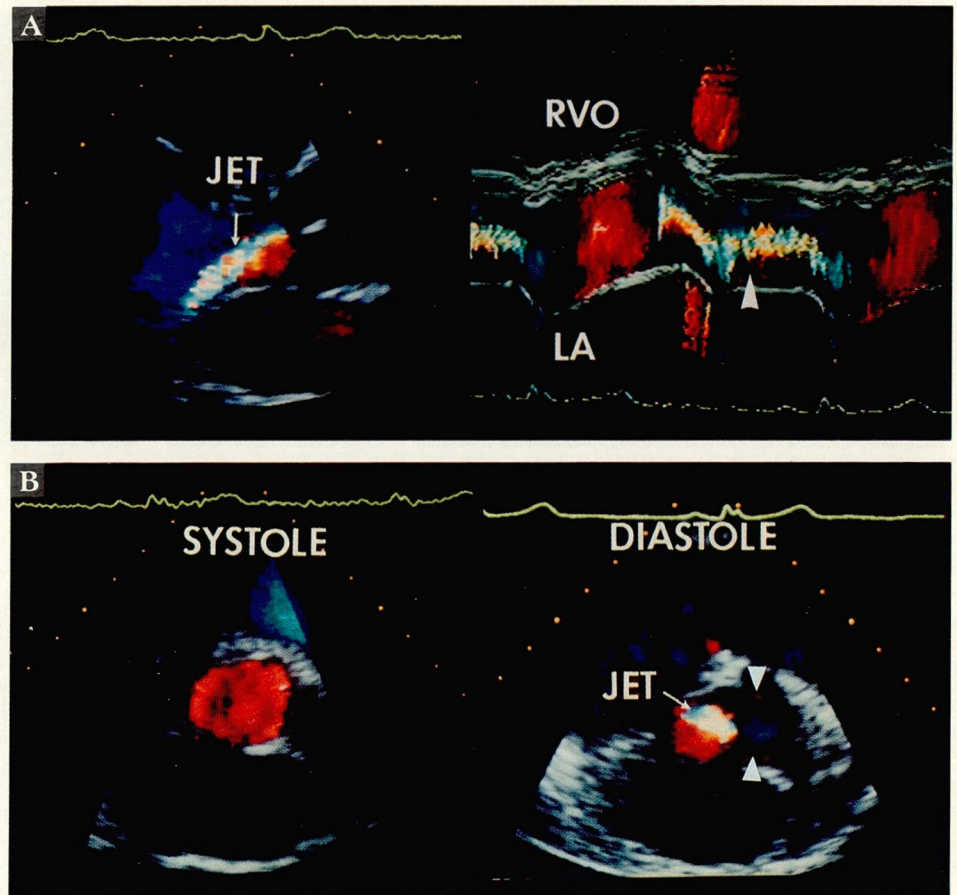


FIGURE 2. Color-flow imaging provided these two views of mild aortic regurgitation in the same patient. In A, the parasternal long-axis view, the aortic regurgitant jet (JET, arrow) is narrow in relation to the left ventricular outflow tract, and color-flow M-mode imaging records the narrow regurgitant signal (arrowhead). In B, the short-axis view of the aorta in systole (left) and diastole (right), a regurgitant jet area (arrow) is small in relation to the left ventricular outflow tract. RVO indicates the right ventricular outflow tract.

LVOT, correlate best with angiographic grading of regurgitation.¹² Color M-mode Doppler echocardiographic imaging is useful in measuring the jet diameter,^{32,33} especially during tachycardia, when standard color Doppler imaging proves more difficult to assess.

Pitfalls of this technique include the subjective nature of the assessment and associated interobserver variability. The color image is influenced by gain settings and built-in color map encoding parameters that may vary from machine to machine. On some machines, filter settings are adjustable, and the pulse repetition frequency which influences the color flow map is variable.

Recent studies have found a poor correlation be-

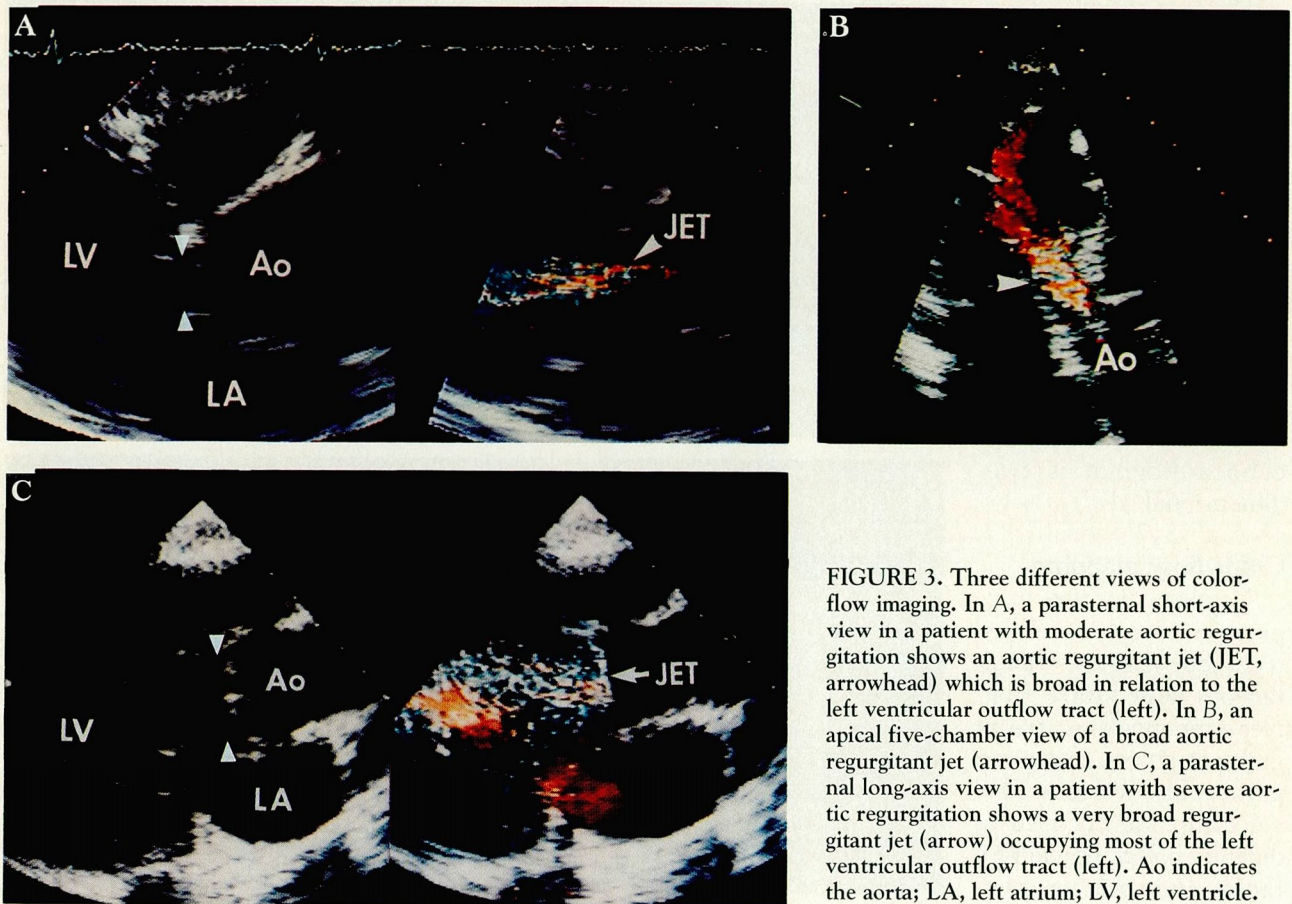


FIGURE 3. Three different views of color-flow imaging. In A, a parasternal short-axis view in a patient with moderate aortic regurgitation shows an aortic regurgitant jet (JET, arrowhead) which is broad in relation to the left ventricular outflow tract (left). In B, an apical five-chamber view of a broad aortic regurgitant jet (arrowhead). In C, a parasternal long-axis view in a patient with severe aortic regurgitation shows a very broad regurgitant jet (arrow) occupying most of the left ventricular outflow tract (left). Ao indicates the aorta; LA, left atrium; LV, left ventricle.

tween actual regurgitant volume and Doppler color jet length, width, and area, since these parameters are more dependent on flow rate or velocity than on actual volume.³⁴⁻³⁶ Also, the apparent proximal width of the regurgitant jet may mislead the interpreter to overestimate the size of the regurgitant orifice because of "entrainment" of blood outside the jet.¹⁴ Finally, the size of the regurgitant jet depicted on color Doppler is influenced not only by the size of the regurgitant orifice, but also by the aortic diastolic pressure and left ventricular compliance.³⁶

Continuous-wave Doppler pressure half-time index

Another method of assessing the severity of aortic regurgitation is to measure the aortic regurgitant pressure half-time by using continuous-wave Doppler¹⁵⁻²⁰ (Figure 4). The pressure half-time index represents the time for the pressure difference between aortic diastolic and left ventricular diastolic pressures to fall to 29% of its peak (since the velocity is related to the

square root of pressure).¹⁸ In patients with mild aortic regurgitation, the pressure half-time is long because of the slow decline in the pressure gradient between aorta and left ventricle during diastole. On the other hand, in patients with severe regurgitation, aortic diastolic pressure falls dramatically and left ventricular diastolic pressure rises rapidly with earlier equalization. This is reflected in a relatively rapid rate of decline of the diastolic aortic/left ventricular pressure gradient, and thus, a markedly shortened pressure half-time.¹⁵⁻²⁰

Initial investigation suggested a linear relationship between pressure half-time and the severity of aortic regurgitation. However, experience has shown this to be incorrect. It is currently felt that the best application of the pressure half-time index is in distinguishing severe regurgitation from other grades of severity.³⁷ Published reports differ as to the specific cut-off point, although a pressure half-time of less than 250 milliseconds is the point below which regurgitation is considered severe.²⁰

Measurement of the pressure half-time index has limitations. For instance, it may be difficult to obtain a complete continuous-wave Doppler envelope, without which measurement of the pressure half-time index may be flawed. Also, the method is sensitive to loading conditions, compliance of the ventricle, and associated valvular conditions (such as mitral stenosis).^{14,15-20}

Flow reversal in thoracic and descending aorta

In aortic regurgitation, forward systolic flow is proportional to the left ventricular stroke volume, while diastolic flow reversal is proportional to the regurgitant volume and aortic compliance.¹³ Boughner initially described the forward and reverse flow patterns in the proximal descending aorta in patients with aortic regurgitation using continuous-wave Doppler.²¹ Others using pulsed-wave Doppler have found a good correlation between flow reversal in the descending aorta and angiographic grading (Figure 5).²²⁻²⁶ Recently, color-flow imaging of the proximal thoracic descending aorta has been used to semiquantitatively assess the severity of aortic regurgitation (Figure 6).¹⁴

The degree of diastolic flow reversal in the aorta can be used to differentiate mild aortic regurgitation from moderate and severe aortic regurgitation. However, this assessment has several limitations. Normal patients have a small degree of flow reversal in the aorta secondary to compliance of the proximal aorta. Arteriovenous connections, aortopulmonary window, patent ductus arteriosus, or Blalock-Taussig anastomosis may produce findings similar to aortic regurgitation. Also, inaccuracies may occur because this method does not account for loss of forward flow within the aorta related to flow into the arch vessels and coronary arteries.²¹⁻²⁶

Left ventricular inflow indices

Recently, Doppler indices of left ventricular diastolic filling have been used to detect abnormal diastolic function.³⁸ Left ventricular (transmitral) inflow, constituting the early (E) and late (A) filling waves, represents the pressure gradient from the left atrium to the left ventricle during diastole.³⁹ In severe aortic regurgitation, there is a rapid rise in left ventricular diastolic pressure which is reflected by an increased left ventricular E and decreased A velocity, an increased E/A ratio, and a short E-wave deceleration time (Figure 7).^{40,41} Diastolic mitral regurgitation may also occur in severe aortic regurgitation and is a better indicator of severity than is premature mitral valve closure.⁴⁰

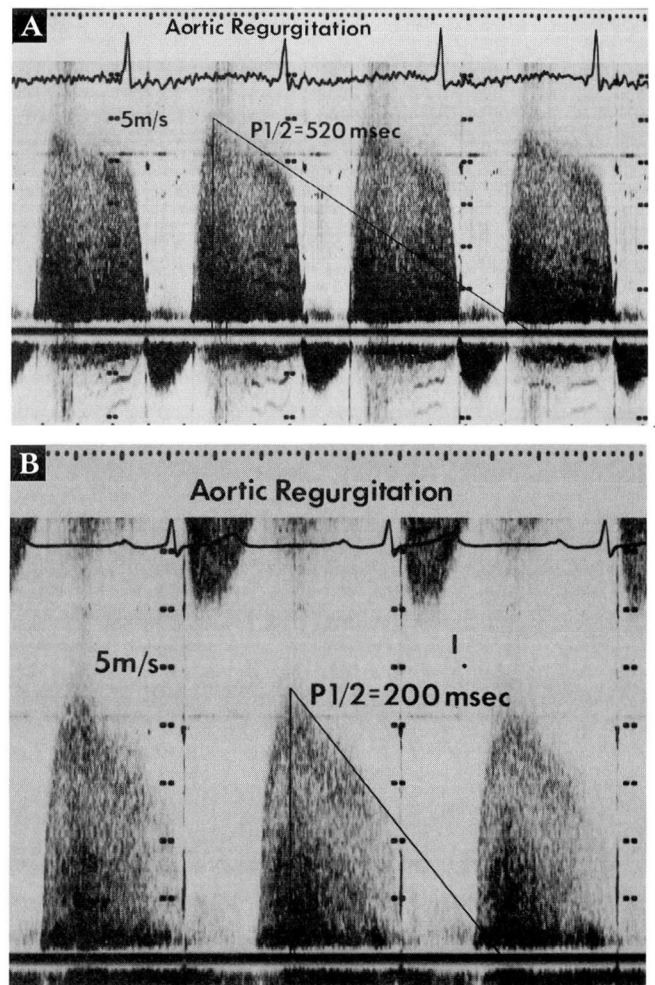


FIGURE 4. Continuous-wave Doppler echocardiography. In A, a recording of the aortic regurgitant signal in a patient with mild aortic regurgitation shows a mildly decreased pressure half-time index ($P1/2$) of 520 milliseconds. In B, a patient with severe aortic regurgitation, the pressure half-time index is markedly decreased (200 milliseconds).

QUANTITATIVE ASSESSMENT

Doppler-derived volumetric flow at various cardiac sites has been used to calculate a Doppler aortic regurgitant fraction (Figure 8) by means similar to those used at cardiac catheterization. This technique uses Doppler-derived volumetric flow and two-dimensional echocardiographic measurements.⁴² Lewis et al showed that Doppler-derived volumetric flow across the LVOT and mitral valve are equal.⁴² Calculation of the regurgitant fraction proceeds as follows:

The regurgitant stroke volume (RSV) is equal to the

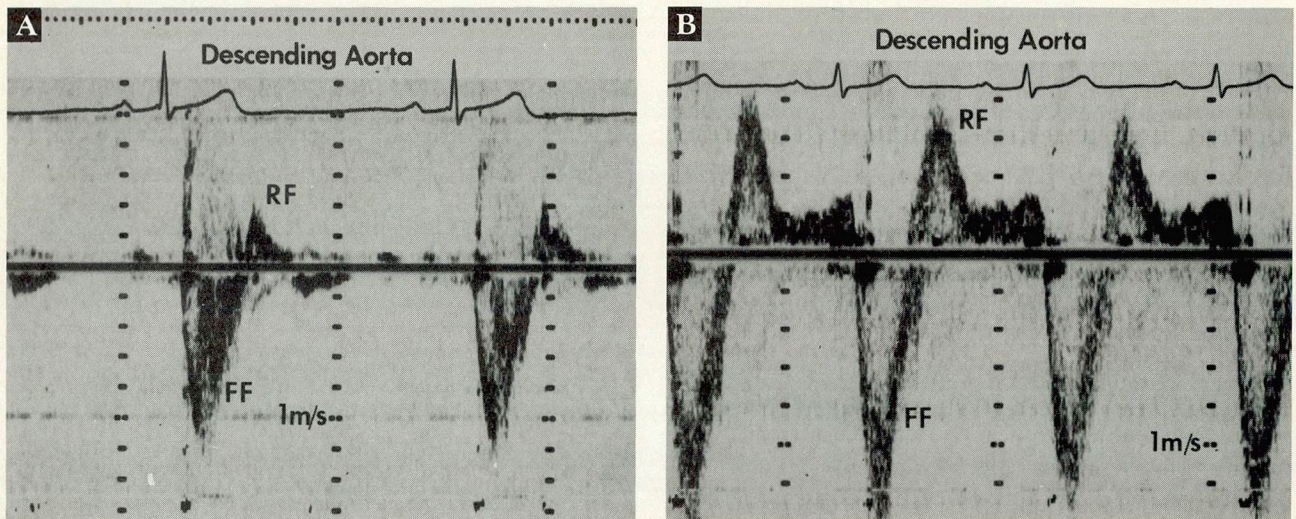


FIGURE 5. Pulsed-wave Doppler recordings. In A, the proximal descending aorta in a patient with mild aortic regurgitation; note the small and early diastolic retrograde flow (RF) relative to forward flow (FF). In B, the proximal descending aorta in a patient with severe aortic regurgitation; retrograde flow is increased and holodiastolic.

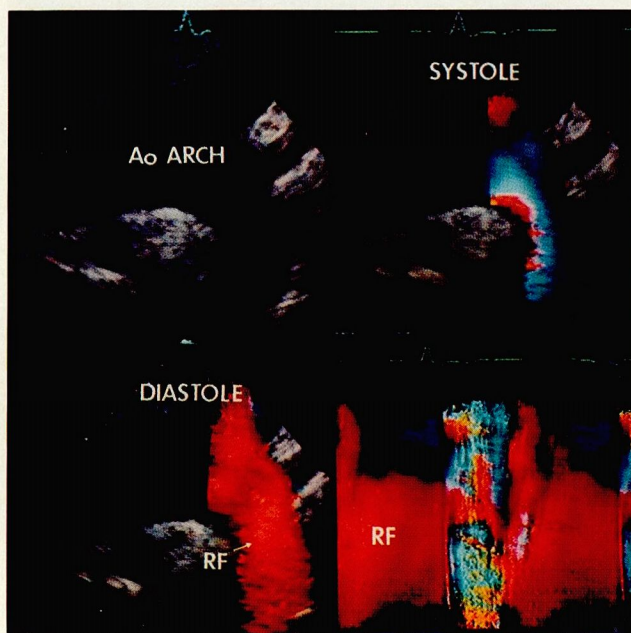


FIGURE 6. Color-flow imaging of the aortic arch (Ao ARCH) from the suprasternal long-axis view. A regurgitant jet is evident in systole (upper right), in diastole (lower left), and in color M-mode (lower right). The increased retrograde flow (RF) is represented by the orange color in diastole and color M-mode.

total angiographically determined left ventricular stroke volume (TSV) minus the forward stroke volume (FSV) as determined by the Fick or indicator-dilution

method.¹³ Therefore, as shown in Figure 8, RSV equals TSV minus FSV (equation 1), and the regurgitant fraction (RF) equals RSV divided by TSV (equation 2). Using Doppler, one can planimetrically measure the time/velocity integral (TVI) profile obtained from the LVOT. The LVOT diameter is measured by two-dimensional echocardiography and the cross-sectional area is calculated (equation 3). The TSV is then calculated as the product of these two parameters (equation 4). FSV is calculated by planimetry of the Doppler TVI profile of a competent valve—ie, pulmonic, tricuspid, or mitral (equation 5). Measurement of the orifice diameter is again performed by two-dimensional echocardiography and a cross-sectional area is calculated.¹⁴ Thus, RSV equals SV_{LVOT} minus SV_{MV} (equation 6). Finally, RF equals SV_{LVOT} minus SV_{MV} divided by SV_{LVOT} (equation 7).

Kitabatake et al²⁷ calculated an aortic regurgitant fraction derived from Doppler-determined aortic and pulmonary flows. They found that the Doppler-derived regurgitant fraction was proportional to angiographic grading. In comparing this technique with left ventriculography, an excellent correlation was found when aortic regurgitation occurred without mitral regurgitation; however, concomitant mitral regurgitation produced inaccuracies.²⁷ This discrepancy occurs because the regurgitant fraction calculated by ventriculography is actually the total regurgitant fraction for both aortic and mitral regurgitant flows,

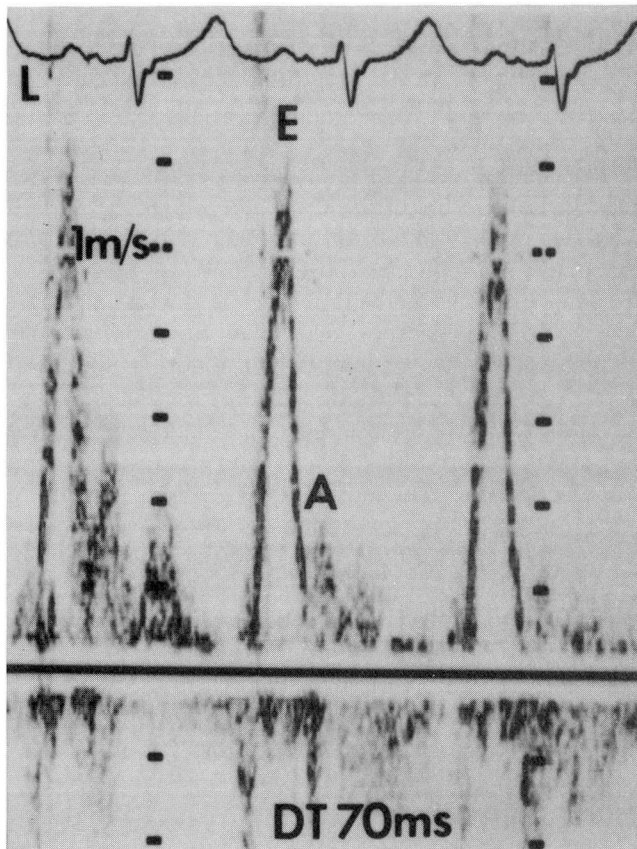


FIGURE 7. A pulsed-Doppler recording of the left ventricular inflow velocities in a patient with severe aortic regurgitation. The left ventricular inflow demonstrates a pattern of “restrictive physiology,” with an increased early (E)-to-late (A) filling wave ratio of 4.0 and a short deceleration time (DT) of 70 milliseconds.

whereas the Doppler technique allows for calculation of individual regurgitant fractions and volumes, as long as a competent valve is used to measure forward stroke volume.⁴ Similarly, Rokey et al, using mitral and aortic flows, found an excellent correlation between the Doppler regurgitant fraction and left ventriculography and thermodilution cardiac output, but the correlation was less strong between the Doppler regurgitant fraction and angiographic grading.⁴

A percentage of regurgitation, or regurgitant fraction, can be calculated by planimetry of the areas under the Doppler-derived diastolic and systolic time/velocity profiles, which correlate well with regurgitant fraction as determined by ventriculography (Figure 9, equations 8 and 9). A good correlation has been found between the regurgitant fraction calculated by Doppler echocardiography of the descending aorta and the regurgitant

Aortic valve		Mitral valve	
LVOT	> Aorta	LA	> LV
FSV + RSV	RSV	FSV (MV)	
(TSV _{LVOT})			

Using aortic and mitral valve flow:

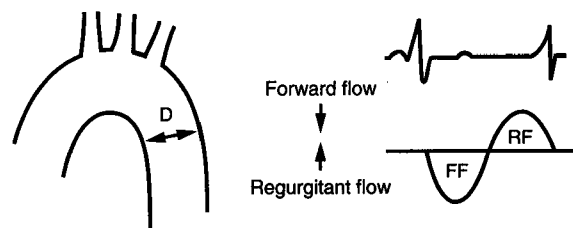
Equation

1. $RSV = TSV - FSV$
2. $RF = \frac{RSV}{TSV}$
3. $SV = TVI \times CSA$, where $CSA = \frac{\text{diameter}^2}{4}$
4. $TSV = TVI \times CSA_{LVOT}$
5. $FSV = TVI \times CSA_{MV}$
6. $RSV = SV_{LVOT} - SV_{MV}$
7. $RF = \frac{SV_{LVOT} - SV_{MV}}{SV_{LVOT}}$

FIGURE 8. Calculating the regurgitant fraction (RF). Equations 1 through 7 calculate the RF based on Doppler measurements of blood flow at the aortic and mitral valves. The regurgitant stroke volume (RSV) is equal to the total left ventricular stroke volume (TSV) minus the forward stroke volume (FSV) (equation 1), and $RF = RSV/TSV$ (equation 2). Stroke volume (SV) is the product of the time/velocity integral profile (TVI) and the cross-sectional area of the orifice (CSA) (equation 3). To calculate TSV, the TVI obtained from the LVOT by Doppler echocardiography is measured by planimetry, and the LVOT diameter is measured by two-dimensional echocardiography and the cross-sectional area is calculated as the square of the diameter divided by 4. TSV is the product of these two parameters (equations 3 and 4). Similarly, FSV can be calculated by planimetry of the TVI of a competent valve and by measuring the diameter of the orifice (equation 5). Thus, $RSV = SV_{LVOT} - SV_{MV}$ (equation 6), and the cross-sectional area is calculated as $RF = SV_{LVOT} - SV_{MV}/SV_{LVOT}$ (equation 7).

fraction as determined in cardiac catheterization.²⁴

Calculation of the regurgitant fraction by Doppler has several limitations. There is a high false-positive rate in normal patients, ranging from 9% to 18%. (This is also true of angiographically derived regurgitant fractions.) Error may be introduced when measuring the aortic, pulmonary, tricuspid, and mitral cross-sectional areas by two-dimensional echocardiography. Concomitant aortic stenosis and regurgitation results in higher velocities across the stenotic area and interferes with planimetry of the TSV. Intracardiac or extracardiac shunts affect the calculation of regurgitant fractions, as do arrhythmias such as atrial fibrillation with beat-to-beat variability.^{4,13,27,28}



Using the proximal descending aorta:

Equation

8.
$$\text{Regurgitant fraction} = \frac{\text{Regurgitant flow}}{\text{Forward Flow}}$$

$$= \frac{\text{TVI}_R \times \text{CSA}_R}{\text{TVI}_F \times \text{CSA}_F}$$

$$= \frac{\text{TVI}_R}{\text{TVI}_F}$$
9. Since D changes in systole (s) and diastole (d)
- $$= \frac{\text{TVI}_R \times \pi(\text{Dd})^2}{\text{TVI}_F \times \pi(\text{Ds})^2} = \frac{\text{TVI}_R \times (\text{Dd})^2}{\text{TVI}_F \times (\text{Ds})^2}$$

FIGURE 9. Equations 8 and 9 calculate the regurgitant fraction using the ratio of retrograde flow to forward flow in the proximal descending aorta. D, diameter.

TRANSESOPHAGEAL ECHOCARDIOGRAPHY

Transesophageal echocardiography is increasingly used to provide diagnostic information, particularly in patients with prosthetic valves or whenever transthoracic imaging is suboptimal.⁴³ Semiquantitative assessment of aortic regurgitation is possible using Doppler color-flow mapping in combination with pulsed-wave and, most recently, continuous-wave Doppler modalities. This assessment is usually made from the transesophageal five-chamber view. The diameter of the regurgitant jet on Doppler color-flow mapping, relative to the diameter of the LVOT, is the most frequently used means of semiquantitative assessment (Figure 10). Color M-mode echocardiography is particularly useful in this setting, especially during tachycardia when visual differentiation between systolic and diastolic flow within the LVOT is difficult. The length of the regurgitant jet seen on Doppler color-flow mapping may also be assessed from the five-chamber view or by using various short-axis views at the base, mid-ventricle, and apex.^{43,45} Recently, biplane

transesophageal echocardiography has shown promise in improving assessment of the severity of aortic regurgitation: the additional longitudinal plane provides an excellent image of the long and short axes of the aortic valve and LVOT.^{46,47}

Perhaps more important than assessing severity of regurgitation, the high-definition images obtained with this modality may permit precise definition of the mechanism of regurgitation (Figure 9). In many cases, this may expedite medical or surgical therapy. Prolapsing aortic valve cusps, aortic root dilatation, aortic dissection, prosthetic paravalvar regurgitation, and aortic valve endocarditis are pathologies frequently implicated by transesophageal echocardiography as causing aortic regurgitation.^{43,48} In the operating room, transesophageal echocardiography can also facilitate aortic valvuloplasty for prolapsing aortic valve cusps, since it permits localization of the regurgitant orifice and determination of the mechanism of regurgitation. Furthermore, the relative competency of the valve following surgery can be determined immediately upon cessation of cardiopulmonary bypass. If an unsatisfactory result is found, additional surgery may therefore be undertaken during the same operation.⁴⁹

TESTING NEW TECHNIQUES

A number of promising quantitative Doppler techniques developed during in vitro testing may be of use in quantitatively determining the area of regurgitant and stenotic orifices and the instantaneous volumetric flow through them.^{50,51} These techniques use measurements of momentum (the orifice velocity time multiplied by the jet flow rate) and the kinetic energy of stenotic or regurgitant jets.⁵² Whether these techniques will be applicable in the clinical setting awaits further study.

CONCLUSION

The severity of aortic regurgitation can be accurately assessed noninvasively by a variety of Doppler echocardiographic techniques. Each technique provides important information, and none should be used alone. The final determination of aortic regurgitation severity should involve a combination of the various Doppler techniques and the indices derived from them.

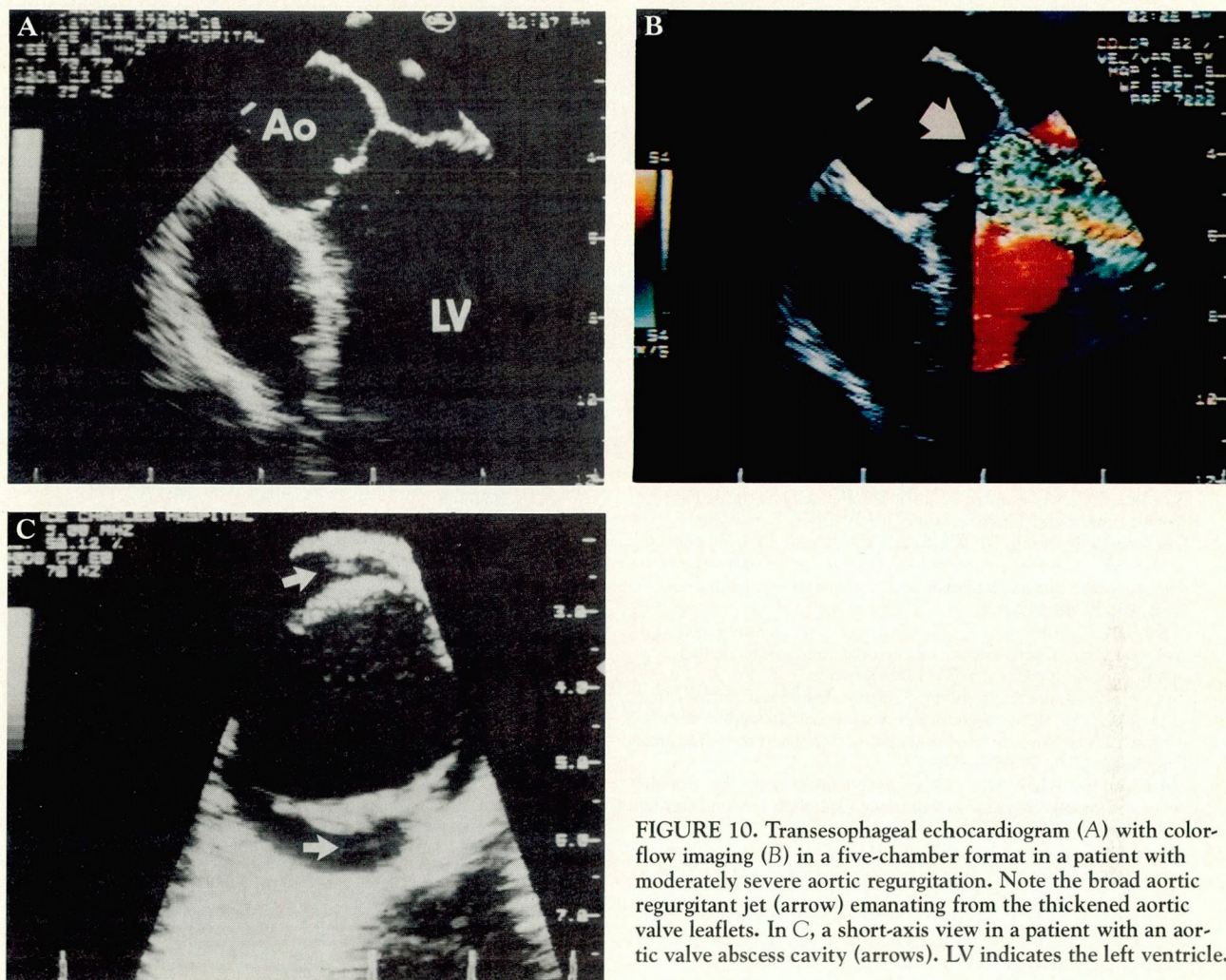


FIGURE 10. Transesophageal echocardiogram (A) with color-flow imaging (B) in a five-chamber format in a patient with moderately severe aortic regurgitation. Note the broad aortic regurgitant jet (arrow) emanating from the thickened aortic valve leaflets. In C, a short-axis view in a patient with an aortic valve abscess cavity (arrows). LV indicates the left ventricle.

REFERENCES

1. Bonow RO, Rosing DR, McIntosh CL, et al. The natural history of asymptomatic patients with aortic regurgitation and normal left ventricular function. *Circulation* 1983; **68**:509–517.
2. Henry WL, Bonow RO, Borer JS, et al. Observations on the optimum time for operative intervention for aortic regurgitation. I. Evaluation of the results of aortic valve replacement in symptomatic patients. *Circulation* 1980; **61**:471–483.
3. Rackley CE, Hood WP, Grossman W. Measurements of ventricular volume, mass and ejection fraction. In: Grossman W, ed. *Cardiac catheterization in angiography*. Philadelphia: Lea and Febiger, 1980:232–244.
4. Rokey R, Sterling LL, Zoghbi WA, et al. Determination of regurgitant fraction in isolated mitral or aortic regurgitation by pulsed Doppler two-dimensional echocardiography. *J Am Coll Cardiol* 1986; **7**:1273–1278.
5. Croft CH, Lipscomb K, Mathis K, et al. Limitations of qualitative angiographic grading in aortic or mitral regurgitation. *Am J Cardiol* 1984; **53**:1593–1598.
6. Urquhart J, Patterson RE, Packer M, et al. Quantification of valve regurgitation by radionuclide angiography before and after valve replacement surgery. *Am J Cardiol* 1981; **47**:287–291.
7. Feigenbaum H. Acquired valvular heart disease. In: Feigenbaum H, ed. *Echocardiography*. Philadelphia: Lea and Febiger, 1986:290–301.
8. Gross CM, Wann LS, Nanda NC. Doppler assessment of aortic regurgitation and dissection. In: Nanda NC, ed. *Doppler echocardiography*. New York: Igaku-Shoin, 1985:220–261.
9. Omoto R, Yokote Y, Takamoto S, et al. The development of real-time two-dimensional Doppler echocardiography and its clinical significance in acquired valvular diseases. *Jpn Heart J* 1984; **25**:325–340.
10. Miyatake K, Okamoto M, Kinoshita N, et al. Clinical applications of a new type of real-time two-dimensional Doppler flow imaging system. *Am J Cardiol* 1984; **54**:857–868.
11. Switzer DF, Nanda NC. Color Doppler evaluation of valvular regurgitation. *Echocardiography* 1985; **2**:533–543.
12. Perry GJ, Helmcke F, Nanda NC, Byard C, Soto B. Evaluation of aortic insufficiency by Doppler color flow mapping. *J Am Coll Cardiol* 1987; **9**:952–959.
13. Pearlman AS, Otto CM. Quantification of valvular regurgitation. *Echocardiography* 1987; **4**:271–287.
14. Kandath D, Nanda NC. Assessment of aortic regurgitation by non-invasive techniques. In: O'Rourke RA, ed. *Current problems in car-*

- diology. Yearbook. Chicago: Medical Publishers Inc., 1990:45-58.
15. Masuyama T, Kodama K, Kitabatake A, et al. Noninvasive evaluation of aortic regurgitation by continuous-wave Doppler echocardiography. *Circulation* 1986; 73:460-466.
16. Teague SM, Heivisimer JA, Anderson JL, et al. Quantification of aortic regurgitation using continuous wave Doppler ultrasound. *J Am Coll Cardiol* 1986; 8:592-599.
17. Labovitz AJ, Ferrara RP, Kern MJ, Brya RJ, Mrosek DG, William GA. Quantitative evaluation of aortic insufficiency by continuous wave Doppler echocardiography. *J Am Coll Cardiol* 1986; 8:1341-1347.
18. Grayburn PA, Handshoe R, Smith MD, Harrison MR, DeMaria AN. Quantitative assessment of the hemodynamic consequences of aortic regurgitation by means of continuous wave Doppler recordings. *J Am Coll Cardiol* 1987; 10:135-141.
19. Beyer RW, Ramirez M, Josephson MK, Shah PM. Correlation of continuous-wave Doppler assessment of chronic aortic regurgitation with hemodynamics and angiography. *Am J Cardiol* 1987; 60:852-856.
20. Samstad SA, Hegrenaes L, Skjaerpe T, Hatle L. Half time of the diastolic aortoventricular pressure difference by continuous wave Doppler ultrasound: a measure of the severity of aortic regurgitation? *Br Heart J* 1989; 61:336-343.
21. Boughner DR. Assessment of aortic insufficiency by transcutaneous Doppler ultrasound. *Circulation* 1975; 52:874-879.
22. Quinones MA, Young JB, Waggoner AD, Ostojic MC, Ribeiro LG, Miller RR. Assessment of pulsed Doppler echocardiography in detection and quantification of aortic and mitral regurgitation. *Br Heart J* 1980; 44:612-620.
23. Nakayama N, Yoshimura S, Hara M, et al. Non-invasive quantitative evaluation of aortic regurgitation using an ultrasonic pulsed Doppler flowmeter. *Jpn Circ J* 1983; 47:641-648.
24. Touche T, Prasquier R, Nitenberg A, et al. Assessment and follow-up of patients with aortic regurgitation by an updated Doppler echocardiographic measurement of the regurgitant fraction in the aortic arch. *Circulation* 1985; 72:819-824.
25. Goldberg SJ, Allen HD. Quantitative assessment by Doppler echocardiography of pulmonary or aortic regurgitation. *Am J Cardiol* 1985; 56:131-135.
26. Takenaka K, Dabestani A, Gardin JM, et al. A simple Doppler echocardiographic method for estimating severity of aortic regurgitation. *Am J Cardiol* 1986; 57:1340-1343.
27. Kitabatake A, Ito H, Inoue M, et al. A new approach to noninvasive evaluation of aortic regurgitant fraction by two-dimensional echocardiography. *Circulation* 1985; 72:523-529.
28. Zhang Y, Nitter HS, Ihlen H, et al. Measurement of aortic regurgitation by Doppler echocardiography. *Br Heart J* 1986; 55:32-38.
29. Hatle L, Angelsen B. Diagnosis and assessment of various heart lesions. In: *Doppler ultrasound in cardiology: physical principles and clinical applications*. Philadelphia: Lea and Febiger, 1982:339-343.
30. Ciobanu M, Abbasi AS, Allen M, Hermer A, Spellberg R. Pulsed Doppler echocardiography in the diagnosis and estimation of severity of aortic insufficiency. *Am J Cardiol* 1982; 49:339-343.
31. Grayburn PA, Smith MD, Handshoe R, Friedman BJ, DeMaria AV. Detection of aortic insufficiency by standard echocardiography, pulsed Doppler echocardiography and auscultation. A comparison of accuracies. *Ann Int Med* 1986; 104:599-605.
32. Raffoul H, Diebold B, Guglielmi JP, et al. Quantification of aortic regurgitation using Doppler imaging. *Int J Card Imaging* 1987; 2:145-150.
33. Diebold B, Touati R, Delouche A, et al. Doppler imaging of regurgitant jet in aortic insufficiency: experimental validation and preliminary clinical evaluation. *Eur Heart J* 1987; 8 Suppl C:45-52.
34. Switzer DF, Yoganathan AP, Nanda NC, Woo YR, Ridgway AJ. Calibration of color Doppler flow mapping during extreme hemodynamic conditions in vitro: a foundation for a reliable quantitative grading system for aortic incompetence. *Circulation* 1987; 75:837-846.
35. Bolger AF, Eigler NL, Pfaff JM, Resser KJ, Maurer G. Computer analysis of Doppler color flow mapping images for quantitative assessment of in vitro fluid jets. *J Am Coll Cardiol* 1988; 12:450-457.
36. Matsumura M, Wong M, Omoto R. Assessment of Doppler color flow mapping in quantification of aortic regurgitation—correlations and influencing factors. *Jpn Circ J* 1989; 53:735-746.
37. Slordahl SA, Piene H, Skjaerpe T. Pressure half-time in aortic regurgitation: evaluation with Doppler in a cardiovascular hydromechanical simulator and in a computer model. *J Am Soc Echo* 1990; 3:46-53.
38. Rokey R, Kuo LC, Zoghbi WA, Limacher MC, Quinones MA. Determination of parameters of left ventricular diastolic filling with pulsed Doppler echocardiography: comparison with cineangiography. *Circulation* 1985; 71:543-550.
39. Appleton CP, Hatle LK, Popp RL. Demonstration of restrictive ventricular physiology by Doppler echocardiography. *J Am Coll Cardiol* 1988; 11:757-768.
40. Oh JK, Hatle LK, Sinak LJ, Seward JB, Tajik AJ. Characteristic Doppler echocardiographic pattern of mitral inflow velocity in severe aortic regurgitation. *J Am Coll Cardiol* 1989; 14:1712-1717.
41. Levine RA, Thomas JD. Insights into the physiologic significance of the mitral inflow velocity pattern. *J Am Coll Cardiol* 1989; 14:1718-1720.
42. Lewis JF, Kuo LC, Nelson JG, Limacher MC, Quinones MA. Pulsed Doppler echocardiographic determination of stroke volume and cardiac output: clinical validation of two new methods using the apical window. *Circulation* 1984; 70:425-431.
43. Seward JB, Khandheria BK, Oh JK, et al. Transesophageal echocardiography: technique, anatomic correlations, implementation and clinical applications. *Mayo Clin Proc* 1988; 63:649-680.
44. Milchak MA, Plehn JF, Niles NW, Catherwood E. Transesophageal Doppler analysis of aortic regurgitation: comparison with aortography (abstract). *Circulation* 1990; 82(Suppl III):551.
45. Castello R, Fagan L, Lenzen P, Pearson AC, Labovitz AJ. Comparison of transthoracic and transesophageal echocardiography for assessment of left-sided valvular regurgitation. *Am J Cardiol* 1991; 68:1677-1680.
46. Bansal RC, Shakudo M, Shah PM. Biplane transesophageal echocardiography: technique, image orientation and preliminary experience in 131 patients. *J Am Soc Echo* 1990; 3:348-366.
47. Seward JB, Khandheria BK, Edwards WD, Oh JK, Freeman WK, Tajik AJ. Biplanar transesophageal echocardiography: anatomic correlations, image orientation, and clinical applications. *Mayo Clin Proc* 1990; 65:1193-1213.
48. Currie PJ. Transesophageal echocardiography: intraoperative applications. *Echocardiography* 1989; 6:403-414.
49. Stewart WJ, Currie PJ, Schiavone WA, Salcedo EE, Cosgrove DM. Intraoperative echocardiography in patients with left ventricle outflow tract obstruction. In: Maurer G, Mohl W, eds. *Echocardiography and doppler in cardiac surgery*. New York: Isaku-Shoin, 1989:331-345.
50. Reimold SC, Ganz P, Bittl JA, Plappert TJ, Lee RT. Aortic effective regurgitant orifice area: description of two methods based on the conservation of mass (abstract). *Circulation* 1990; 82(Suppl III):551.
51. Utsunomiya T, Doshi R, Patel D, Mehta K, Nguyen D, Gardin JM. Accuracy of regurgitant volume calculation using color Doppler "zero-baseline" shift proximal isovelocity surface area method [abstract]. *Circulation* 1990; 82(Suppl III):553.
52. Cape EG, Skoufis EG, Weyman AE, Yoganathan AP, Levine RA. A new method for noninvasive quantification of valvular regurgitation based on conservation of momentum. *Circulation* 1989; 79:1343-1353.