

PARKINSON'S DISEASE FOR THE GENERAL PRACTITIONER

Cleveland Clinic Foundation
Bunts Auditorium
December 2, 1992

About the Symposium

As a result of attending this course, the participant will be able to:

- More accurately diagnose Parkinson's Disease and separate it from other causes of Parkinsonism
- Understand current theories on the etiology of the disease
- Manage and treat their Parkinson's Disease patients and better utilize traditional symptomatic therapy
- Employ newer "neuroprotective" therapy strategies

Those interested in receiving further information may write or call:

The Cleveland Clinic Educational Foundation
Continuing Education Department
9500 Euclid Avenue, Room TT-31
Cleveland, Ohio 44195-5241

216-444-5696 (local) 1-800-762-8173 (other)
216-445-9406 (Fax)

THE CLEVELAND CLINIC
FOUNDATION



THYROID NODULES: WHICH SHOULD BE TREATED?

Thyroid nodules are very common—occurring in 5% to 10% of patients on physical examination. Yet the vast majority are benign and require no intervention unless the size causes cosmetic or pressure problems. When working up a nodule and thyroid tests are normal, the best diagnostic strategy is fine-needle aspiration biopsy. Radioactive iodine uptakes, various imaging scans, and ultrasound add to the cost with little diagnostic benefit. Suspicious lesions should be operated on—about 30% will be cancerous. Clinically, enlarged lymph nodes in conjunction with an isolated nodule indicate malignancy. Suppression of nodules via hormonal therapy is ineffective; one ultrasound study showed that patients followed for 6 months had no decrease in nodule size.

LARRY M. KOHSE, MD
Department of Endocrinology
The Cleveland Clinic Foundation

Correction

An error occurred in the Radiology Pathology Grand Rounds article entitled "Pelvic retroperitoneal mass in a 36-year-old man," published in the July/August issue of the *Cleveland Clinic Journal of Medicine* (1992;59[4]:429-433). On page 432, the arrow marker on Figure 7 should have been deleted, and the words "...A cleaved nucleus is visible...which could represent new mitosis" should have been deleted from the legend. The corrected figure and figure legend are printed below:

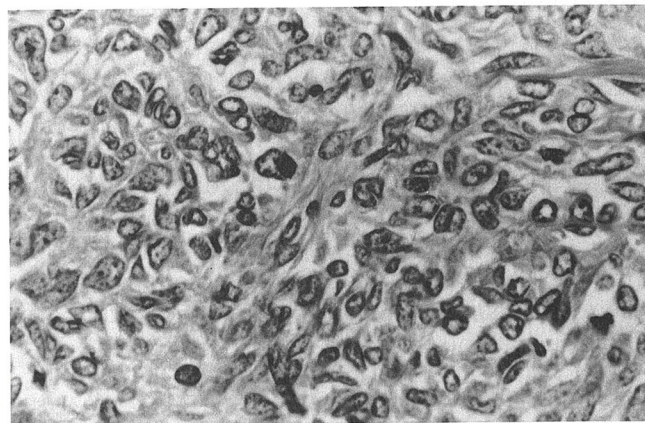


FIGURE 7. Photomicrograph showing hypercellularity, marked nuclear pleomorphism, and indistinct cytoplasmic borders (hematoxylin and eosin, $\times 550$).