

Aortic valve replacement in young patients: long-term follow-up

DOUGLAS S. MOODIE, MD; USAMA HANHAN, MD; RICHARD STERBA, MD; DANIEL J. MURPHY, Jr, MD;
ELIOT R. ROSENKRANZ, MD; ANDREA M. KOVACS, BS

■ Thirty-four young patients (28 male and 6 female) underwent aortic valve replacement between 1972 and 1988. Ages ranged from 11 to 20 years (mean 17.7 years). Including reimplantation in the follow-up period, 40 valves were implanted, among which were 17 (43%) St. Jude, 7 (16%) Bjork-Shiley, and 4 (10%) Carpentier-Edwards. Seven patients (18%) had tissue valve prostheses (4 Carpentier-Edwards, 3 Hancock valves). There was one hospital death (2.9%). Follow-up was obtained in 30 of the 33 hospital survivors, with a mean follow-up of 80 months. In the follow-up period, one patient (3%) had a major thromboembolic event and one patient (3%) had prosthetic valve endocarditis. Six patients (18%) required replacement of the implanted valve; three of these had received Hancock tissue valve prostheses. There were three late deaths, yielding 96% survival at 5 years and 84% at 10 years. Twenty-three of 30 survivors are currently New York Heart Association class I. Aortic valve replacement in young patients can be performed with low mortality and morbidity, and with excellent long-term results.

□ INDEX TERMS: HEART VALVE PROSTHESIS; CHILD; ADOLESCENCE; AORTIC VALVE INSUFFICIENCY; AORTIC VALVE STENOSIS
□ CLEVE CLIN J MED 1992; 59:473-478

ALTHOUGH CONSERVATIVE surgery is the preferred treatment for aortic valvular lesions in young patients, prosthetic valve replacement is sometimes inevitable,¹⁻³ particularly when leaflet thickening and calcification make valve reconstruction impossible.² For this reason, prosthetic valve replacement in young patients will continue to be a management option.

Relatively few studies have dealt with the long-term follow-up of a large number of younger patients follow-

ing aortic valve replacement (AVR),¹⁻¹⁴ and surgical results and survival rates among these studies have varied considerably. We report the surgical results and long-term follow-up of 34 young patients who underwent AVR at The Cleveland Clinic Foundation between 1972 and 1988.

METHODS

The medical records of all patients under age 20 who underwent AVR at The Cleveland Clinic Foundation from 1972 through 1988 were reviewed. Also included were patients who had an additional procedure or procedures performed (*Table*). Follow-up was performed by contacting the patients or by consulting

From the Department of Cardiology, The Cleveland Clinic Foundation.

Address reprint requests to D.S.M., Department of Cardiology, The Cleveland Clinic Foundation, 9500 Euclid Avenue, Cleveland, OH 44195.

TABLE
REASONS FOR AORTIC VALVE REPLACEMENT

Final valve size and type	Age at original surgery	Clinical description
#23 Bjork-Shiley	19	Congenital aortic stenosis
#29 Bjork-Shiley	18	Aortic insufficiency, undetermined
# 7 Bjork-Shiley	19	Mitral stenosis, dilated valve
#25 Bjork-Shiley	18	Congenital bicuspid
#23 Bjork-Shiley	19	Congenital aortic stenosis; #10 Starr-Edwards valve replaced after 5 years for prosthetic valve aortic obstruction
#25 Bjork-Shiley	16	Severe aortic regurgitation after aortic valvuloplasty and ventricular septal defect closure
#19 St. Jude	20	Congenital aortic stenosis; subcutaneous bacterial endocarditis
#25 St. Jude	20	Congenital bicuspid
#25 St. Jude	20	Aortic insufficiency; endocarditis
#21 St. Jude	19	Aortic insufficiency; subaortic abscess; subcutaneous bacterial endocarditis
#31 St. Jude	18	Congenital fused commissures; #12 Kaster valve replaced
#31 St. Jude	19	Mitral stenosis; aortic dissection
#25 St. Jude	14	Mitral stenosis
#29 St. Jude	17	Mitral stenosis; sinus of Valsalva aneurysm
#21 St. Jude	20	Rheumatic aortic stenosis, aortic insufficiency
#19 St. Jude	16	Subcutaneous bacterial endocarditis; aortic regurgitation; #21 Bjork-Shiley replaced after 4 years
#29 St. Jude	16	Congenital bicuspid
#29 St. Jude	20	Severe rheumatic aortic regurgitation; #27 Hancock
#29 St. Jude	18	Congenital aortic stenosis bicuspid; 2 aortic repairs after ventricular septal defect repair
#23 St. Jude	18	Prosthetic aortic stenosis; aortic insufficiency; subcutaneous bacterial endocarditis; #25 Hancock valve replaced after 8 years
#19 St. Jude	18	Subcutaneous bacterial endocarditis; aortic insufficiency
#25 St. Jude	16	Congenital aortic insufficiency; bicuspid
#21 St. Jude	15	Congenital bicuspid; 2 valvuloplasties; subcutaneous bacterial endocarditis
#12 Kaster	18	Congenital aortic stenosis
#16 Kaster	15	Congenital aortic stenosis and aortic insufficiency
#18 Kaster	18	Aortic insufficiency; sinus of Valsalva aneurysm
#14 Kaster	15	Congenital aortic stenosis
#27 Carpentier-Edwards	19	Congenital aortic stenosis
#25 Carpentier-Edwards	14	Severe aortic insufficiency
#27 Carpentier-Edwards	19	Congenital bicuspid aortic stenosis; aortic insufficiency; preoperative subcutaneous bacterial endocarditis; #27 Hancock, calcified
#25 Carpentier-Edwards	20	Congenital bicuspid
#21 Ionescu	20	Congenital bicuspid
# 9 Starr-Edwards	20	Rheumatic valvulitis
#10 Starr-Edwards	11	Subcutaneous bacterial endocarditis, aortic insufficiency

with the referring physicians and reviewing all hospital records. Actuarial survival curves were created with Kaplan-Meier estimates. All statistical analyses were done using the SAS statistical software package.

PATIENTS

Thirty-four patients ranging in age from 11 to 20 (mean 17.7 years) underwent AVR between 1972 and 1988. There were 28 (82%) males and 6 (18%) females.

The most common presenting symptoms were fatigue in 20 patients (59%), shortness of breath in 18 patients (53%), and dyspnea on exertion in 16 (47%).

At the time of surgery, seven patients (21%) were in New York Heart Association (NYHA) functional class III or IV, and 27 patients were in NYHA class I or II.

Thirty-three patients (97%) had a systolic murmur at presentation, 29 (85%) had a diastolic murmur. Electrocardiography revealed left ventricular hypertrophy in 23 patients (68%), and 24 (71%) had cardiomegaly on chest radiography.

The predominant valvular lesions were aortic insufficiency (21 patients, or 62%), aortic stenosis (6 patients, or 18%), and combined aortic insufficiency and aortic stenosis (7 patients, or 20%). AVR was an isolated procedure in 22 of the 34 patients; 12 patients had a total of 14 concomitant procedures, including aortic root replacement (4 patients), ventricular septal defect closure (3 patients), enlargement of the aortic outflow tract (3 patients), mitral valve replacement (2 patients), patch closure of a subaortic abscess (1

patient), and tricuspid valve annuloplasty (1 patient). Previous cardiac surgical procedures had been performed in 12 patients (5 aortic valvulotomy, 4 coarctation repair, 1 AVR, 1 ventricular septal defect, and 1 patent ductus closure.

Preoperative assessments of left ventricular function during cardiac catheterization were available for 30 of 34 patients. Of these 30 patients, 10 (33%) had normal left ventricular function (ejection fraction $\geq 50\%$), 8 (27%) had mild impairment (ejection fraction 40% to 50%), and 12 (40%) had moderate impairment (ejection fraction 35% to 40%). No patient had severe impairment (ejection fraction $<35\%$).

Including reimplantations during the follow-up period, a total of 40 valves were implanted in 34 patients. The valves used most commonly were the St. Jude (17) and the Bjork-Shiley (7). Seven patients (20%) received a tissue valve prosthesis.

RESULTS

The following results are listed according to the recent guidelines described by Edmunds et al¹⁵ for reporting morbidity and mortality after cardiac valve operations.

Mortality

One patient died shortly after surgery, for an operative mortality rate of 2.9%. This patient presented with severe aortic regurgitation and moderate mitral regurgitation, a sinus of Valsalva aneurysm, and moderately to severely impaired left ventricular function. He had undergone six previous open heart surgeries and was NYHA class IV. He expired within 24 hours of surgery with low cardiac output syndrome and ventricular arrhythmia.

Three of 33 hospital survivors (10%) expired. One of these had presented with severe aortic stenosis with mild aortic insufficiency and had received a #16 Lillehei-Kaster prosthesis; the patient expired suddenly 3 years later, possibly from a rhythm disturbance (however, this was not documented). The second patient had presented with severe aortic insufficiency with moderately impaired left ventricular function and had received a #27 Carpentier-Edwards prosthesis; this patient expired 6 years later from rupture of the prosthetic aortic valve secondary to endocarditis, with subsequent severe hypotension. The third patient had presented with valvular and supra-avalvular aortic stenosis, a hypoplastic supra-avalvular segment of the ascending aorta, moderate aortic insufficiency, and mitral insufficiency. He underwent a Kono procedure with a #25 Bjork-Shiley valve and annuloplasty. This patient died 7 years later of cardiopulmonary arrest secondary to biventricular failure and severe mitral insufficiency.

Long-term follow-up

Follow-up was performed for 30 of the 34 patients (89%). The follow-up period ranged from 1 to 204 months (mean 80 months). Ages of the patients at the time of follow-up ranged from 15 to 35 years (mean 24 years). Survival for all the patients was 96% at 5 years and 84% at 10 years (Figure 1). NYHA classification

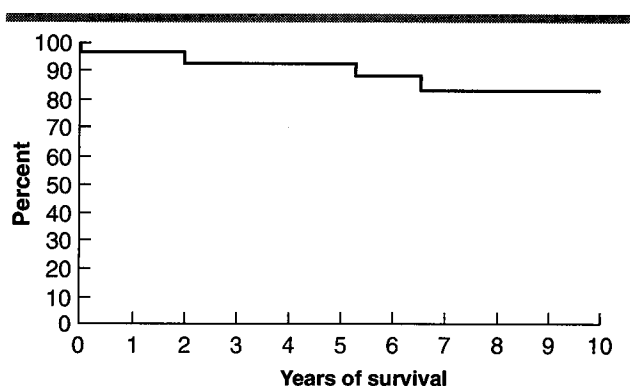


FIGURE 1. Actuarial survival curve for all patients, including hospital deaths, showing 95% survival at 5 years and 84% at 10 years.

data were available for 27 of the 30 survivors: of these 27, 23 (85%) are class I, 3 (11%) are class II, and 1 (4%) is class III. Almost all survivors are now leading normal lives, with no restrictions on their activities.

Complications and morbidity

Structural valvular deterioration. Six patients required reoperation. Three patients had a Hancock porcine valve which required replacement 7 to 10 years later (mean 8.3). All three Hancock valves showed degenerative calcification on pathological examination. Three additional patients had mechanical valve dysfunction: one patient had a Lillehei-Kaster prosthesis replaced with a St. Jude valve after 12 years because of valve failure. Another patient underwent replacement of a Starr-Edwards valve with a Bjork-Shiley after 5 years. A third patient underwent replacement of a Bjork-Shiley valve with a St. Jude valve 4 years postoperatively.

Thromboembolism. Long-term therapy with warfarin was prescribed in 27 of 34 patients; antiplatelet therapy consisting of aspirin and dipyridamole was used in the remaining 7 patients. No patient developed anticoagulant-related hemorrhage, but there was one thromboembolic event. The patient had received a #29 St. Jude valve with aortic root replacement and closure of a ventricular septal defect. Because of difficulty in controlling the prothrombin time, warfarin treatment had been stopped, and the patient was maintained on aspirin and dipyridamole. At age 20, 2.5 years postoperatively, the patient developed left hemiparesis. This solitary occurrence represents an incidence of thromboembolic events of 0.5% per 100 patient years.

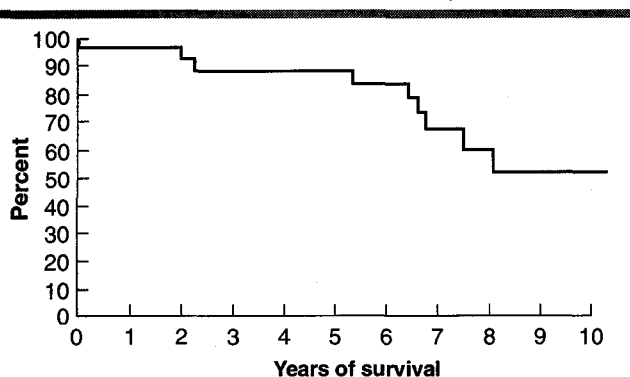


FIGURE 2. Event-free survival for all patients, including hospital deaths, showing 91% event-free survival at 5 years and 61% at 10 years.

Prosthetic valve endocarditis. Four patients had experienced preoperative episodes of endocarditis. One patient with moderately severe aortic stenosis secondary to a congenital bicuspid aortic valve developed preoperative endocarditis with severe aortic valve insufficiency. This patient underwent AVR with a #27 Carpentier-Edwards valve at age 19. Another patient with congenital aortic stenosis had one documented episode of preoperative endocarditis. A third patient developed endocarditis with subsequent severe aortic regurgitation and a subaortic abscess requiring replacement of the aortic valve with a #21 St. Jude valve. A fourth patient with a congenital bicuspid aortic valve developed endocarditis after two previous valvuloplasties. He subsequently underwent valve replacement with a #21 St. Jude valve.

There was one case of prosthetic valve endocarditis. The patient had initially undergone prosthetic valve replacement of a dysplastic aortic valve with aortic insufficiency and aortic stenosis. A #25 Hancock valve was used in that procedure. The patient developed prosthetic valve endocarditis with resultant prosthetic valve stenosis and insufficiency. Eight years after the initial implantation the patient underwent re-replacement of the infected prosthetic valve with a #23 St. Jude valve. "Burned-out" vegetations were noted on the prosthetic valve cusp at the time of reoperation.

Pregnancy. Of the six females in our population, three were nulliparous. The three remaining females had a total of seven children; of these, one had congenital heart disease (ie, transposition of the great vessels). None of the patients was noted to have any problems during pregnancy.

Postoperative arrhythmias and congestive heart failure. Four patients were noted to have cardiac symptoms or arrhythmias documented by 12-lead electrocardiography following cardiac surgery. Three patients had palpitations with no documented arrhythmias. One patient had infrequent premature ventricular contractions. No patient developed late congestive heart failure.

Event-free survival. Cardiac events in the follow-up period were defined as when the patient was readmitted for cardiac cause; underwent repeat cardiac catheterization because of a concern over valvular heart function; developed thromboembolism or endocarditis; required reoperation; or died. By these criteria, event-free survival for all the patients was 91% at 5 years and 61% at 10 years (Figure 2).

DISCUSSION

Valve replacement in young patients carries specific risks in addition to the usual problems with valvular prostheses encountered in adults. Valve replacement in childhood commits the patient to dependence on a prosthesis of unknown durability; moreover, the patient may outgrow the prosthesis as somatic growth continues. Of our 34 patients, 31 were over age 14 and probably had attained most of their adult size at the time of valve replacement. Of the remaining 3 patients, 2 were age 14 and 1 was age 11. All 3 of these younger patients received valves as large as, or larger than, those in other patients 19 to 20 years old. The additional difficulty of anticoagulant control in very active young patients is further complicated in female patients of childbearing age.^{4,8} For these and other reasons, most thoracic surgeons agree that every effort should be made to preserve the native valve in childhood; however, valvular prosthesis is sometimes unavoidable.^{3,7} In addition, one could consider a homograft valve as an alternative.

Reports of long-term follow-up and survival of young patients undergoing valvular prosthesis have varied considerably with geography and time.¹⁻⁴ Results have varied depending on the nature of the underlying disease, the characteristics of the prosthetic valve used, and the site of insertion,¹ with the most favorable results seen in isolated mechanical valvular insertion in the aortic position.^{5,7}

Our results agree with other reports indicating that AVR can be performed with low mortality and morbidity in younger patients and with a satisfactory long-term survival.^{2,5} Our series had one operative death, yielding an early mortality rate of 2.9%. Other early

mortality rates range from 0.0% to 8.0%.^{3,6,9} Reports on late mortality following AVR also have varied.^{5,9} Cornish and colleagues reported no late deaths in 17 patients with AVR followed for up to 5 years.⁹ Milano et al reported 7 late deaths in 53 patients following AVR; the 7-year survival rates were 66% for patients with bioprosthetic valves and 77% for patients with mechanical valves.⁵ Of the three late deaths in our series, two were of unknown causes and one was related to severe mitral insufficiency.

The development of bioprosthetic valves was seen as a major advance for children needing valve replacement because it was felt that postsurgical anticoagulation therapy would not be necessary.¹ However, this early enthusiasm was soon dampened by reports of high failure rates and degenerative calcification.^{1,10,11} Of the seven tissue valves inserted in our patients, three (all Hancock porcine) had to be replaced 7 to 10 years later because of degenerative calcification. This is similar to the experience of others.^{6,9,11}

Because of these high failure rates, we share the opinion of others that xenograft aortic bioprostheses are not recommended in younger patients. Recent reports on the use of low-profile mechanical valves in children are promising.^{4,7,9} Half of our patients received St. Jude medical valves, which have gained widespread acceptance since their introduction in 1977.⁶ However, until long-term comparative studies of the different mechanical prostheses are available, the most suitable prosthesis for use in young patients remains to be determined.

The need for anticoagulation therapy in young patients has recently received adequate consideration. Cornish et al,⁹ in their experience with the St. Jude valve, compared groups receiving warfarin, aspirin, or no therapy. They found no difference in complication rates and concluded that anticoagulation might not be essential in valve replacement using the St. Jude valve in mitral-aortic positions.⁹

McGrath and co-workers^{13,14} noted seven throm-

botic events and one case of valve thrombosis in 27 patients under age 20 who were treated with acetylsalicylic acid (ASA) and dipyridamole. They now recommend full anticoagulation with warfarin.^{13,14}

Ilbawi and Asses,¹² in a follow-up of patients with the St. Jude valve who were treated with ASA and dipyridamole, found significantly lower complication rates in the left vs the right side of the circulation.¹² Their results showed thromboembolic events in 8 of 14 patients (57%) with the valve in the right (pulmonary) side and in 3 of 26 patients (12%) with the valve in the left (systemic) side of the circulation.

We recommend full anticoagulation therapy with warfarin for most patients with a mechanical valve prosthesis, including the St. Jude valve, because most reports indicating the safety of using aspirin and dipyridamole are only short- or intermediate-term, and most of the thromboembolic events are time-related.

Our data are similar to a recent report from our institution by Lytle et al¹⁵ demonstrating that although AVR can be performed with a low operative mortality and morbidity in both adults and children, many patients will experience cardiac events in the 10 years following valve replacement. In Lytle's study,¹⁶ in-hospital mortality from AVR in adults was only 3.4%, but only 43% of the patients survived 10 years without a major cardiac event. Our data show a similar operative mortality (2.9%) and 10-year event-free survival (61%) in young patients. None of our surviving patients had late postoperative congestive heart failure. Thus, both pediatric and adult patients require close cardiovascular follow-up. AVR is not an anatomic cure, and one half to two thirds of all pediatric and adult patients will suffer a cardiac event within 10 years following AVR.

In conclusion, our data suggest that AVR can be performed with low operative mortality and morbidity in young patients, but that close serial follow-up is necessary through late childhood and adulthood because of long-term cardiovascular complications.

REFERENCES

1. Elliott MJ, De Leval M. Valve replacement in children. *World J Surg* 1985; **9**:568-578.
2. El Makhlof A, Friedli B, Oberhansli I, Rouge JC, Faidutti B. Prosthetic heart valve replacement in children. *J Thorac Cardiovasc Surg* 1987; **93**:80-85.
3. Robbins RC, Frederick O, Bowman JR, Malm J. Cardiac valve replacement in children: A twenty-year series. *Ann Thorac Surg* 1988; **45**:56-61.
4. Iyer KS, Reddy KS, Rao IN, Venugopal P, Bhatia ML, Gopinath N. Valve replacement in children under twenty years of age. *J Thorac Cardiovasc Surg* 1984; **88**:217-224.
5. Milano A, Vouhe PR, Vernant FB, et al. Late results after left-sided cardiac valve replacement in children. *J Thorac Cardiovasc Surg* 1986; **92**:218-225.
6. Williams WB, Pollack JC, Geiss DM, Trusley GA, Fowler RS. Experience with aortic and mitral valve replacement in children. *J Thorac Cardiovasc Surg* 1981; **81**:326-333.
7. Borkon AM, Soule L, Reitz BA, Gott VL, Gardner TJ. Five year follow-up after valve replacement with the St. Jude medical valve in infants and children. *Circulation* 1986; **74**(Suppl 1):110-115.
8. Freed MD, Bernhard WF. Prosthetic valve replacement in children. *Prog Cardiovasc Dis* 1975; **17**:475-87.
9. Cornish EM, Human DG, deMoore MA, et al. Valve replacement in

- children. *J Thorac Cardiovasc Surg* 1987; **35**:176–179.
10. Rupprath G, Franke F, Vogt J, DeVinic EK. Long-term results after mitral and aortic valve replacement in childhood and adolescence. *Z Kardiol* 1986; **75**(Suppl 2):312–316.
 11. Williams DB, Danielson GK, McGoon DC, Puga FJ, Mair DD, Edwards WD. Porcine heterograft valve replacement in children. *J Thorac Cardiovasc Surg* 1982; **84**:446–450.
 12. Ilbawi MN, Idriss FS, DeLeon SY, et al. Valve replacement in children: Guidelines for selection of prosthesis and timing of surgical intervention. *Ann Thorac Surg* 1987; **44**:398–403.
 13. Hartz RS, LoCicero J, Kucich V, et al. Comparative study of warfarin versus antiplatelet therapy in patients with a St. Jude medical valve in the aortic position. *J Thorac Cardiovasc Surg* 1986; **92**:684–690.
 14. McGrath LB, Gonzalez-Lavin L, Eldredge WJ, et al. Thromboembolic and other events following valve replacement in a pediatric population without anticoagulation. *Circulation* 1985; **72**(Suppl 3):149.
 15. Edmunds LH Jr, Clark RE, Cohn LH, Miller DC, Weisel RD. Guidelines for reporting morbidity and mortality after cardiac valvular operations. *J Thorac Cardiovasc Surg* 1988; **96**:351–353.
 16. Lytle BW, Cosgrove DM, Taylor PC, et al. *J Thorac Cardiovasc Surg* 1989; **97**:675–694.

