

Transient osteoporosis of the hip: clinical and imaging features

JEAN SCHILS, MD; DAVID PIRAINO, MD; BRADFORD J. RICHMOND, MD; BERNARD STULBERG, MD;
GEORGE H. BELHOBOK, MD; ANGELO A. LICATA, MD

■ Transient osteoporosis of the hip is a form of reflex sympathetic dystrophy characterized by pain, limping, limitation of hip joint motion, and delayed radiographic patchy osteoporosis of the proximal femur. Spontaneous resolution is usually paralleled by radiographic recovery, usually within a few months. We present clinical and imaging features in seven cases of unilateral transient osteoporosis of the hip. In the appropriate clinical setting, conventional radiography will support the diagnosis. The role of more sensitive imaging techniques such as bone scintigraphy and magnetic resonance imaging in the early diagnosis of this disease has yet to be defined.

□ INDEX TERMS: REFLEX SYMPATHETIC DYSTROPHY; OSTEOPOROSIS; HIP JOINT □ CLEVE CLIN J MED 1992; 59:483-488

TRANSIENT OSTEOPOROSIS of the hip (TOH), a self-limited form of reflex sympathetic dystrophy, is characterized by pain, limping, and limitation of hip joint motion. The exact incidence of TOH is unknown because its clinical features can be confused with several other hip diseases, and because radiographic anomalies associated with the condition are sometimes subtle and their appearance is delayed. Recently, the use of scintigraphy and more advanced imaging techniques such as magnetic resonance imaging (MRI) has been advocated.

Failure to recognize this unusual cause of pain in the hip will result in delayed or mistaken diagnosis and can

lead to unnecessary diagnostic and therapeutic measures. Misdiagnosis of this condition in several of our patients prompted us to investigate the clinical and imaging characteristics of TOH.

METHODS

Over a 2-year period, we saw seven patients with evidence of unilateral TOH. The diagnosis of TOH was made initially in only two patients; the other five patients were initially misdiagnosed with osteonecrosis of the femoral head (three patients), stress fracture of the femoral neck (one patient), and muscle tear (one patient). All patients were given various analgesic and nonsteroidal anti-inflammatory agents, and all underwent physiotherapy. One patient was treated with calcitonin. The final diagnosis of TOH was based on clinical features, including progression of disease, and on imaging tests (conventional radiography and MRI in seven patients, and scintigraphy in five patients). We reviewed the histories of these patients from the

From the Departments of Diagnostic Radiology (J.S., D.P, B.J.R., G.H.B.), and Endocrinology (A.L.), The Cleveland Clinic Foundation, and the Department of Orthopedic Surgery, University Hospitals of Cleveland (B.S.).

Address reprint requests to J.S., Department of Diagnostic Radiology, A21, The Cleveland Clinic Foundation, 9500 Euclid Avenue, Cleveland, OH 44195.

TABLE
TRANSIENT OSTEOPOROSIS OF THE HIP IN SEVEN PATIENTS

Patient	Age (years)	Sex	Side	Precipitating factors	Symptoms	Duration of symptoms (months)	Time from onset of symptoms to positive radiography (weeks)
1	41	M	Left	Rotation of the hip	Pain radiates to the knee; limping	7	10
2	51	M	Right	None	Pain; limping	6	4
3	51	F	Left	Twisted ankle	Pain (including night pain) radiates to the knee; limping	4	2
4	63	M	Left	None	Pain; limping	6	12
5	47	M	Right	Rotation of the hip	Pain; limping	5	4
6	64	F	Right	None	Pain; limping	4	4
7	32	F	Left	None	Pain; limping	5	5

time they initially presented with acute symptoms to their most recent follow-up examination.

RESULTS

Symptoms

All seven patients had pain and limping (Table). The symptoms were mild to moderate and their intensity increased progressively, peaking 3 to 4 weeks after onset. Clinical improvement ensued, and full clinical recovery occurred in 4 to 7 months (mean 5 months).

The focus of pain was consistently the groin area and the anterior aspect of the thigh; in two patients the pain radiated to the knee. Pain at night was noted in only one patient. Three patients had tenderness of the trochanteric region, and one had tenderness of the pubic and ischial bones.

The physical examination revealed normal but painful range of motion in six patients; in one patient, internal rotation of the hip was reduced. The affected limbs showed no trophic changes.

Precipitating factors were absent in four patients; in three patients TOH was brought on by unusual muscular exertions.

Radiographic findings

In five patients, conventional radiography showed regional osteoporosis of the femoral head, with no joint space narrowing or subchondral erosions at 2 to 5 weeks after the onset of symptoms (Figure 1, A and B). At the same time, scintigraphy showed increased radiopharmaceutical uptake in the femoral head (Figure 1, C). Subsequently, MRI in those five patients showed diffuse decreased signal intensity in the femoral head and part of the femoral neck on T1-weighted images, and increased signal intensity in the same area on T2-weighted images (Figure 1, D and E).

In the other two patients, radiographic findings of regional osteoporosis were delayed until 10 and 12 weeks after onset of symptoms, and scintigraphy and MRI showed abnormal findings in these patients before conventional radiography did (Figure 2, A and B). One patient had extension of the disease into the proximal femoral diaphysis, and the other showed increased uptake in the knee.

Because the patients had a final diagnosis of TOH and favorable clinical outcome, complete imaging follow-up until full clinical recovery (at 7 months) was obtained for only one patient. In this patient, MRI at 12 weeks showed normal appearance of the femoral head (Figure 3, A and B); conventional radiographs obtained at the time of clinical recovery demonstrated nearly normal radiographic density of the femoral head (Figure 3, C and D).

DISCUSSION

TOH is a self-limited disease characterized by pain and limping, with the typical radiographic finding of patchy osteoporosis of the proximal femur.¹⁻⁶ Although Curtiss and Kincaid first described TOH in 1957,¹ the condition is poorly recognized because the clinical findings are transient and can be confused with several other hip diseases, and because the radiographic findings are delayed and sometimes quite subtle.

Since the first description, several investigators have defined TOH as a form of reflex sympathetic dystrophy. However, in a recent study of 56 cases of transient regional osteoporosis involving the lower limbs, Lakhanpal et al showed that TOH may be clinically distinct from reflex sympathetic dystrophy.⁵ TOH has had many names, including transient osteoporosis, transitory demineralization, migratory osteolysis, and algodystrophy.¹⁻⁸

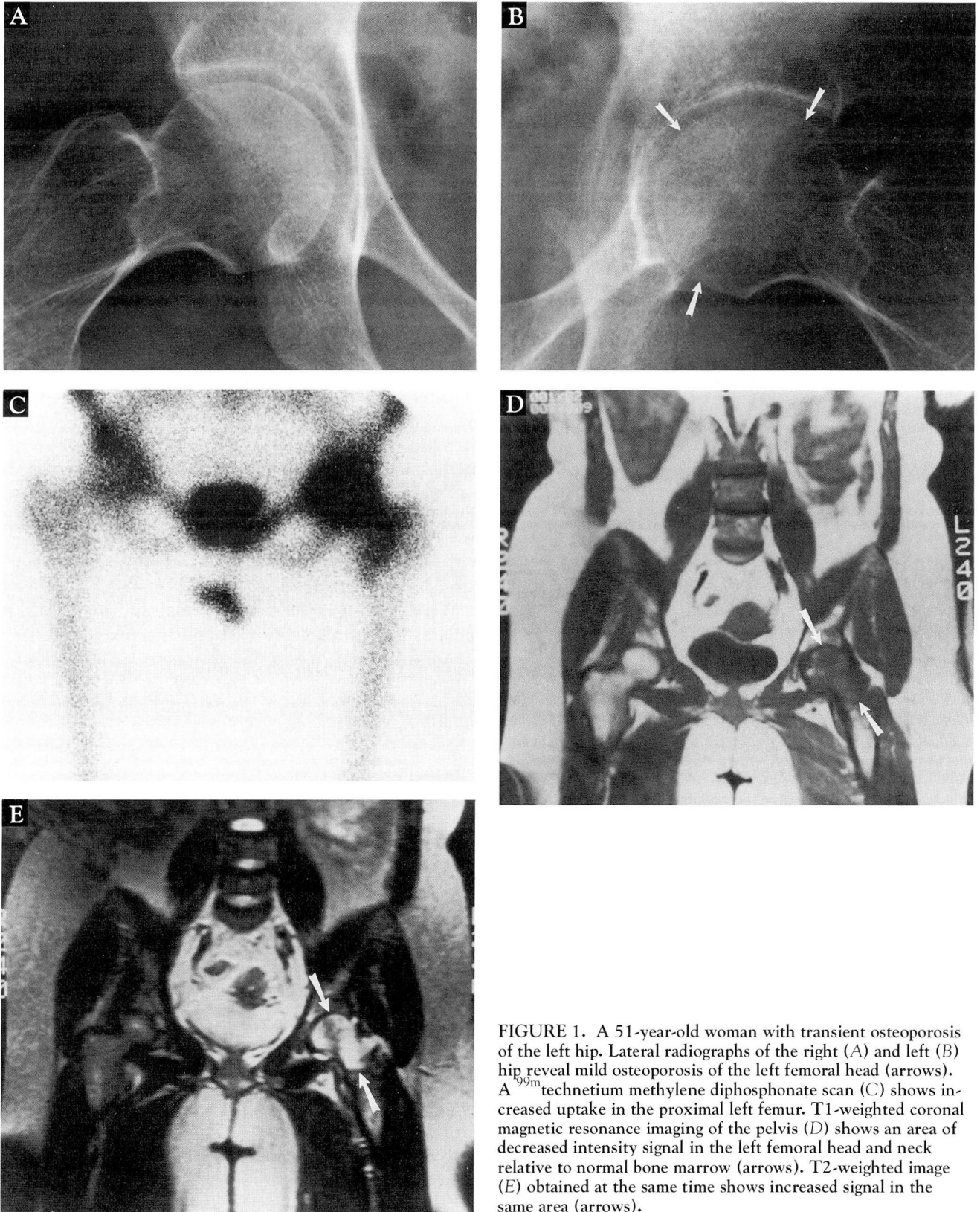


FIGURE 1. A 51-year-old woman with transient osteoporosis of the left hip. Lateral radiographs of the right (A) and left (B) hip reveal mild osteoporosis of the left femoral head (arrows). A ^{99m}Tc methylene diphosphonate scan (C) shows increased uptake in the proximal left femur. T1-weighted coronal magnetic resonance imaging of the pelvis (D) shows an area of decreased intensity signal in the left femoral head and neck relative to normal bone marrow (arrows). T2-weighted image (E) obtained at the same time shows increased signal in the same area (arrows).

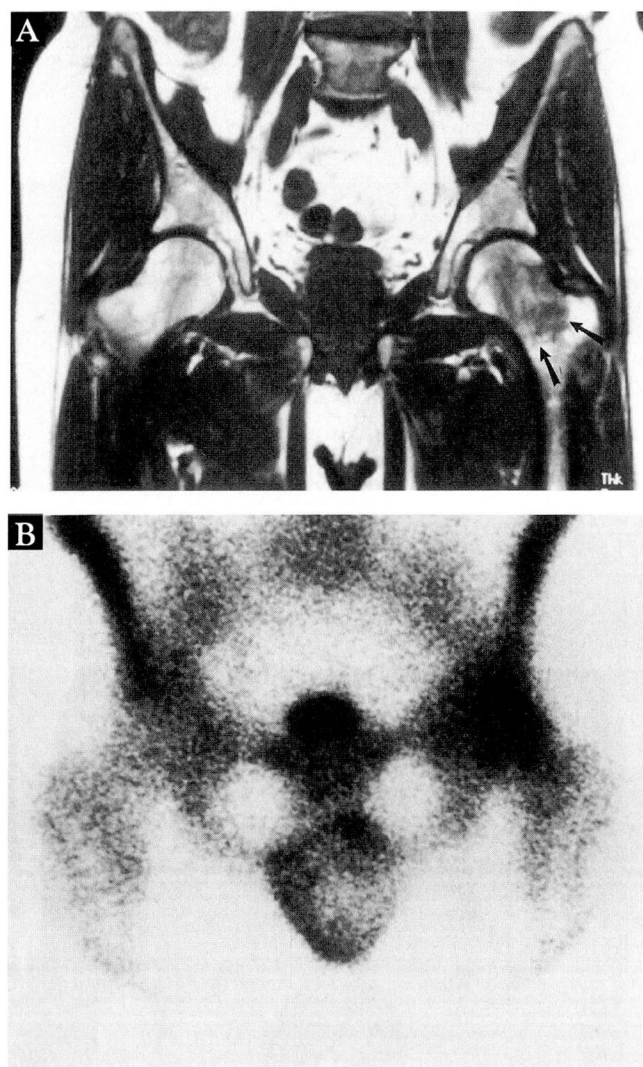


FIGURE 2. A 63-year-old man with transient osteoporosis of the left hip. Coronal T1-weighted magnetic resonance image of the pelvis (A) shows decreased signal intensity relative to normal bone marrow, extending from the femoral head into the intertrochanteric region (arrows). A ^{99m}Tc methylene diphosphonate scan (B) shows increased uptake in the same area.

The incidence of TOH is probably underestimated, since many cases are not recognized.⁶ The patient distribution in our small series, comprising four men and three women ages 32 to 64, is slightly different from some other reports, where young or middle-aged men ages 35 to 50 were predominantly affected.⁴

Etiology

The exact etiology of TOH is still unclear. The condition is believed to be a form of reflex sympathetic

dystrophy.^{2,4} TOH gradually improves over a few months, and trophic changes are rarely present; these characteristics distinguish it from Sudeck's atrophy, which is characterized by pain, swelling, limitation of motion, and patchy demineralization affecting an entire limb (arm or leg), or only the distal portion (hand or foot).⁹

Factors that may precipitate TOH include minor trauma, surgery involving the lumbar spine or the pelvis, lumbosciatica, and pregnancy; however, no single cause or precipitating factor can be found in at least 50% of cases.⁴⁻⁶ This experience is consistent with our series.

Although Arlet and Ficat proved a close histological connection between osteonecrosis and TOH, no one has proved that TOH represents a transient form of osteonecrosis.⁴ Hunder and Kelly performed an arthrotomy in all of their cases and noted nonspecific increased synovial fluid and thickening of the synovial membrane.³ One study obtained biopsies of the head and neck of the femur in nine cases of TOH; stasis, fibrosis, and small areas of necrosis were seen.¹⁰ No specific laboratory signs of inflammation are associated with TOH.⁴⁻⁶ In our study, laboratory features were not consistently seen.

While most cases have typical findings, TOH remains at least partially a diagnosis of exclusion. Inflammatory arthritis, infection (specifically tuberculosis), stress fracture of the femoral neck, and osteonecrosis of the femoral head should be considered in the differential diagnosis of TOH.

Clinical course

Pain and limping are the two well-recognized symptoms of TOH^{2,4,5}; they were noted in all seven patients. In this series, the relatively swift progression of the symptoms reached a peak at 4 weeks in all seven patients. The other significant characteristic is that the pain is mechanical: all patients had pain with use of the affected hip. One patient also had nocturnal pain. Lequesne mentioned that the disability in patients with TOH is significantly disproportionate to the moderate pain^{2,4}; however, we did not estimate this specific criterion in our series. Most patients recover within 2 to 7 months.

The only complication of TOH is fracture of the femoral neck, and this has been reported only in pregnant women.^{1,11}

Recurrence of similar lesions involving another segment of the lower extremities or (more rarely) the same hip is characteristic of TOH.^{4,5,7} The period of

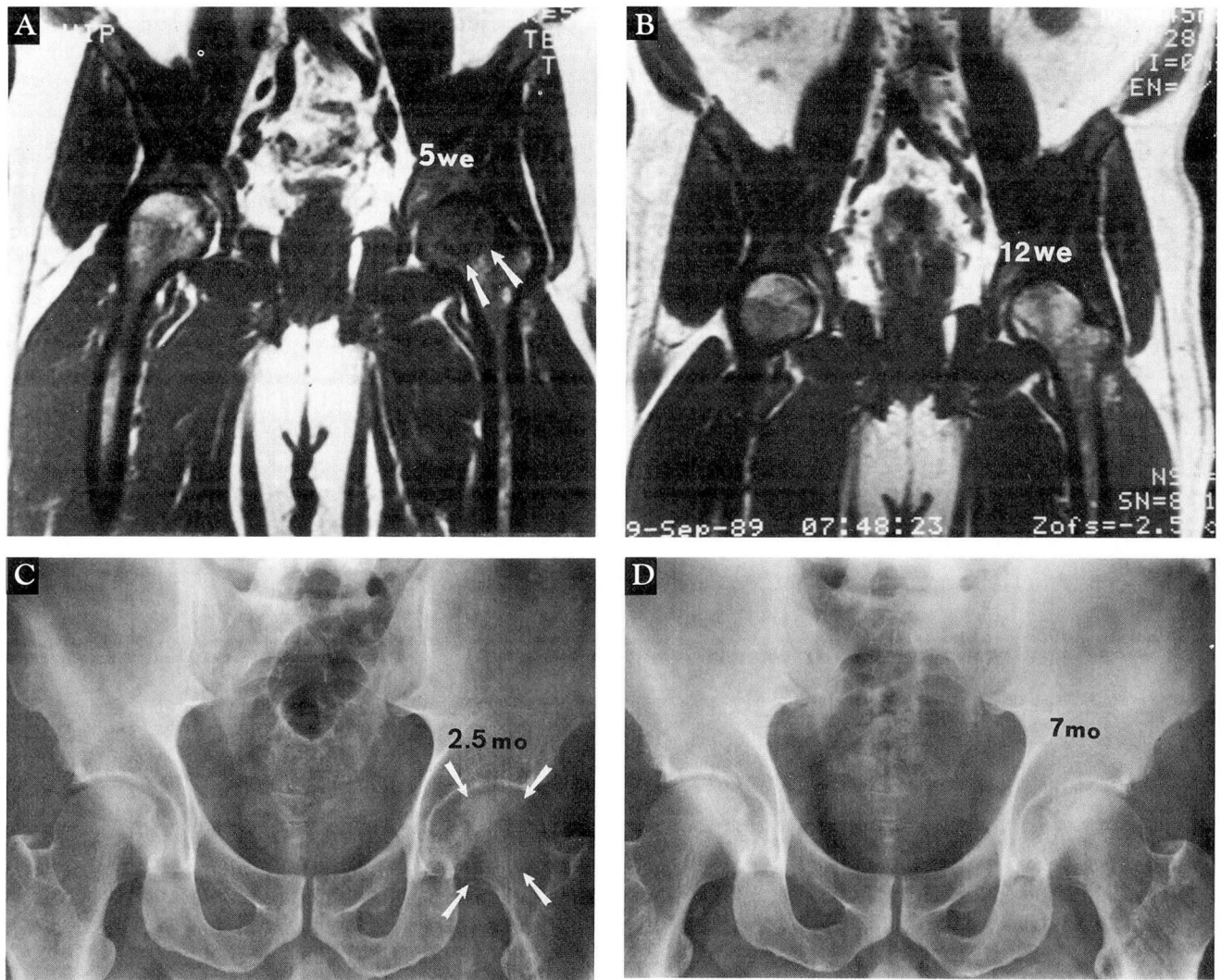


FIGURE 3. A 41-year-old man with transient osteoporosis of the left hip. At 5 weeks, coronal T1-weighted magnetic resonance image of the pelvis (A) shows decreased signal intensity in the left femoral head (arrows). Imaging at 12 weeks (B) shows complete remission of the abnormal signal. At 2.5 months, a frontal radiograph (C) shows transient osteoporosis of the left femoral head. A radiograph taken at 7 months (D), shows the osteoporosis almost completely resolved.

observation of our study was too short to assess this important feature. (Authors' note: After completion of this study, one of the patients developed symptoms of migratory osteoporosis in the contralateral hip. This was confirmed by both scintigraphy and MRI.)

Radiographic characteristics

Delay between symptoms and radiographic findings is persistent throughout the process of TOH, and it is common to continue to see radiographic lesions after a patient becomes asymptomatic.^{4,5} Eventually, radiog-

raphy will show complete recovery, as will bone scintigraphy and MRI.¹²⁻¹⁴

Conventional radiography. The radiographic appearance of TOH is fairly characteristic.^{2,4,5} Radiographic criteria of TOH include decreased density of the femoral head, sometimes giving a mottled appearance. The femoral neck and the acetabulum may be involved in the process; however, joint-space narrowing, bony erosion, and subchondral collapse are not seen.

Radiographic diagnosis can be reached relatively

early in the clinical course (between 3 and 6 weeks), as in five of our seven patients. It requires a technically excellent examination including both hips. In the appropriate clinical setting, the diagnosis of TOH can be made relatively easily from conventional radiographs.

Scintigraphy. Intense homogenous radioisotope uptake increases before radiographic changes are evident.^{4,5,12} The increased uptake involves the femoral head, extending to the acetabulum and the femoral neck, and sometimes to the femoral shaft. Its intensity can be greater in TOH than in any other hip disease; however, the variability is high, and differentiating TOH from osteonecrosis on the basis of scintigraphy is difficult in some cases.¹² Scintigraphy of both lower extremities is needed to evaluate the painful hip and to detect increased uptake in other extremities (which may remain quiescent or become symptomatic after several weeks).⁴

MRI. Recently, several investigators have emphasized the use of MRI in the diagnosis of TOH.^{13,14} Like bone scintigraphy, MRI is very sensitive in detecting transient edema of the marrow in the early stages of TOH. However, transient edema of the proximal femur is also seen in patients who will develop avascular necrosis of the femoral head.¹⁵ Furthermore, MRI can fail to detect reflex sympathetic dystrophy of the upper and lower extremities.¹⁶

CONCLUSION

With early diagnosis, appropriate treatment for TOH can be started without delay, and unnecessary, sometimes invasive, diagnostic tests (such as core decompression of the femoral head) can be avoided. The exact role of bone scintigraphy and MRI in the early diagnosis of this disease has yet to be defined.

REFERENCES

1. Curtiss PH, Kincaid WE. Transitory demineralization of the hip in pregnancy. *J Bone Joint Surg Am* 1959; **41A**:1327-1333.
2. Lequesne M. Transient osteoporosis of the hip: a non-traumatic variety of Sudeck's atrophy. *Ann Rheum Dis* 1968; **27**:463-471.
3. Hunder GG, Kelly PJ. Roentgenologic transient osteoporosis of the hip: a clinical syndrome? *Ann Intern Med* 1968; **68**:539-552.
4. Lequesne M, Mauger B. Cent algodystrophies decalcifiantes de la hanche chez 74 malades. *Revue du Rhumatisme* 1982; **49**:787-792.
5. Lakhanpal S, Ginsburg WW, Luthra HS, Hunder GG. Transient regional osteoporosis: a study of 56 cases and review of the literature. *Ann Intern Med* 1987; **106**:444-450.
6. Doury P. Algodystrophy. Reflex sympathetic dystrophy syndrome. *Clin Rheumatol* 1988; **7**:173-180.
7. Duncan H, Frame B, Frost HM, Arnstein AR. Migratory osteolysis of the lower extremities. *Ann Intern Med* 1967; **66**:1165-1173.
8. Rosen RA. Transitory demineralization of the femoral head. *Radiology* 1970; **94**:509-512.
9. Kozin F, Genant HK, Bekerman C, McCarty DJ. The reflex sympathetic dystrophy syndrome: II roentgenographic and scintigraphic evidence of bilaterality and of periarticular accentuation. *Am J Med* 1976; **60**:332-338.
10. Arlet J, Ficat P, Durroux R, Theallier JP, Mazieres B, Bouteiller G. Histopathologie des lesions osseuses dans 9 cas d'algodytrophie de la hanche. *Revue du Rhumatisme* 1978; **45**:691-698.
11. Shifrin LZ, Reis ND, Zinman H, Besser ML. Idiopathic transient osteoporosis of the hip. *J Bone Joint Surg Br* 1987; **69B**:769-773.
12. Gaucher A, Colomb JN, Naoun A, Faure G, Netter P. The diagnostic value of 99m Tc-diphosphonate bone imaging in transient osteoporosis of the hip. *J Rheumatol* 1979; **6**:574-583.
13. Bloem JL. Transient osteoporosis of the hip: MR imaging. *Radiology* 1988; **167**:753-755.
14. Wilson AJ, Murphy WA, Hardy DC, Totty WG. Transient osteoporosis: transient bone marrow edema? *Radiology* 1988; **167**:757-760.
15. Turner DA, Templeton AC, Selzer PM, Rosenberg AG, Petasnick JP. Femoral capital osteonecrosis: MR findings of diffuse marrow abnormalities without focal lesions. *Radiology* 1989; **171**:135-140.
16. Koch E, Hofer HO, Sialer G, Marincek B, von Schulthess GK. Failure of MR imaging to detect reflex sympathetic dystrophy of the extremities. *AJR Am J Roentgenol* 1991; **156**:113-115.